“ I APPRECIATE THE FACT THAT I’VE COME SO FAR. RIGHT NOW, I WANT TO LIVE MY LIFE AND ENJOY IT WITH MY FAMILY.”

— INGRID GURZYNSKI

Seize the Day

On December 2, 2003, Ingrid Gurzynski of Locust Valley, New York, her husband, Walter, and their sons, Wally, 11, and Nicholas, 9, spent the day in Manhattan, delighting in the holiday season. On December 2, 2002, Ms. Gurzynski was in a New York-area hospital undergoing surgery so that a biopsy could be taken of a tumor in her brain. What a difference a year makes. . .

It all began in the summer of 2002, with mild headaches. Her father had recently suffered a stroke, and Ms. Gurzynski, 37, a kindergarten teacher, thought the headaches might be stress-related. "But when I returned to school in September, I began having more of them," Ms. Gurzynski recalls. "And it was strange. When I had one, it was almost like it paralyzed me for a second. I wasn't able to concentrate." Her primary care physician suggested that she see a neurologist. However, Ms. Gurzynski carried on with her busy life. It wasn't until she began to experience double vision and sensations of vertigo that she made an appointment. Finally, in November, an MRI (magnetic resonance imaging) scan revealed a growth in her brain. Ms. Gurzynski went in for a surgical biopsy almost immediately. "I scheduled it for the following week — I'm not one to sit and dwell on

things." The biopsy confirmed that there was a serious problem: Ms. Gurzynski had an oligodendroglioma, a rare primary brain tumor.

Oligodendroglioma is a type of brain tumor composed of cells that resemble oligodendrocytes, one of the many different kinds of cells in the brain. The principal function of oligodendrocytes is to provide the myelin sheath, or insulation, around what are called axons, long extensions of nerve cells along which electrical impulses travel from cell to cell. [To read more about an MSKCC researcher's efforts to understand brain tumors, see the sidebar on page 27.]

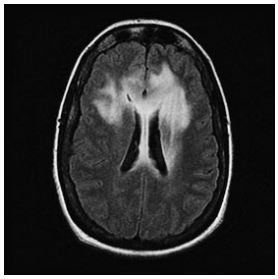

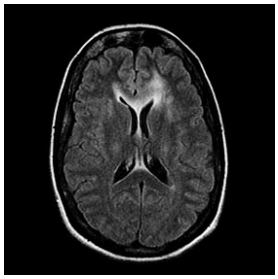

TOP: Magnetic resonance image (MRI) of Ms. Gurzynski's brain before treatment began. The white area is the oligodendroglioma. **BOTTOM:** MRI of Ms. Gurzunski's brain ten months after treatment. Very little tumor is now visible.

Upon learning of the diagnosis, Ms. Gurzynski's brother, an internist and infectious disease specialist in New York, insisted that she should be treated at MSKCC. Ms. Gurzynski agreed. "I said to myself, 'People come from around the world to Memorial Sloan-Kettering and I'm an hour away. There's no way I would go anywhere else.'" She met with the Chairman of MSKCC's Department of Neurology, Lisa M. DeAngelis, on January 2, 2003.

"All primary brain tumors exist on a spectrum of malignancy, which we usually describe as low grade to high grade," says Dr. DeAngelis. "Ingrid's tumor is low grade." (Low-grade tumors are characterized by slow growth and fewer numbers of abnormal — or highly malignant — cells.) Brain tumors are most often local diseases, staying within the brain without metastasizing to other parts of the body. "But they can do considerable damage there," Dr. DeAngelis notes, "so the treatment is first to control symptoms, and then to control tumor growth. In the case of a low-grade tumor, what we want to do is delay the time when it progresses to a higher-grade tumor. Optimally, of course, we want to prevent the tumor from ever progressing to a higher grade, and this is where current research is focused."

Sometimes, if brain tumors are confined to one region, surgeons can remove them entirely. In other cases, such as Ms. Gurzynski's, in which a tumor involves a wide area of the brain, surgeons can take only a sample, called a biopsy, to obtain a diagnosis. However, brain tumors can be very heterogeneous, meaning that there may be areas of high-grade and low-grade tumor in different regions of the same tumor. Because they are graded on the basis of the highest grade, "you could take out the whole tumor and find that ninety percent of it is low grade but ten percent is high grade — and so we'd classify it as high grade," Dr. DeAngelis explains. "If you miss a low-grade component, it doesn't matter. But if you miss a high-grade component, it does — it has an impact on your treatment decision."

In Ms. Gurzynski's situation — as is often the case with brain tumors — the tumor could not be completely removed, so Dr. DeAngelis ordered an MRI scan of Ms. Gurzynski's brain. She received a scan with and without contrast material (used to highlight organs in the body or to highlight abnormalities). "If you see prominent 'contrast-enhanced' areas on the MRI you have a concern that it represents a focus of high-grade tumor, so you'd biopsy those areas," says Dr. DeAngelis. Ms. Gurzynski had no enhancement, nothing to

When Ingrid Gurzynski was diagnosed with a rare brain tumor in 2002, her brother, a physician, insisted that she come to MSKCC. **LISA DEANGELIS,** Chairman of the Department of Neurology, is taking care of her.

suggest she had any areas of high-grade tumor. Even so, Dr. DeAngelis ordered a PET (positron emission tomography) scan because the tumor was so large, growing on both sides of the brain. "We wanted to do everything possible to make sure that we hadn't missed something that was higher grade, because it would definitely affect treatment." Fortunately, the PET scan indicated that the entire tumor was low grade.

Yet reaching a treatment decision required further consideration. Approximately 15 years ago, it was first observed that oligodendrogliomas were sensitive to chemotherapy. (Generally, brain tumors are very resistant to chemotherapy.) The observation was studied in a series of clinical trials, and MSKCC reported the first experience of seeing a low-grade oligodendroglioma that responded to chemotherapy. "Then people began to look for the 'why,' and it was observed that there are unique chromosome deletions that seem to characterize the oligodendroglioma," Dr. DeAngelis says. "These are the loss of 1p and 19q chromosome segments."

The term "chromosome deletion" refers to a form of mutation in which portions of one of the tumor cell's chromosomes are lost, such that all of the cells that then derive from that first tumor cell — the one with the mutation — carry the same loss. Each chromosome is divided into two unequal parts, or "arms" — the shorter "p arm" and the longer "q arm." "In the case of oligodendrogliomas, the losses involve major segments of the chromosome," explains Marc K. Rosenblum, Chairman of MSKCC's Pathology Department. "Virtually the entire p arm of chromosome 1 is lost, and major segments of 19q are lost. And the supposition is that among the genes that are lost in these deletions are genes that work as tumor suppressors." (Tumor suppressor genes normally block cell growth but, when missing or inactivated by mutations, allow cells to grow uncontrolled.) However, oligodendroglioma patients whose tumor cells show these deletions are likely to have better outcomes when treated with chemotherapy. "Deletions of 1p and 19q tend to be predictors of chemosensitivity," Dr. Rosenblum says. It also may be that the presence of 1p and 19q deletions in low-grade oligodendrogliomas is a marker for prolonged disease-free survival. "Patients may actually survive for many years after surgery alone when they have low-grade tumors with these deletions," explains Dr. Rosenblum. "It also may be that tumors with the deletions are much more indolent to begin with," adds Dr. DeAngelis, "and more sensitive to any kind of treatment, not just chemotherapy." (MSKCC is currently the only institution in the New York area that offers the 1p and 19q chromosome deletion test for patients with oligodendroglioma.)

But as it turned out, Ms. Gurzynski's tumor did not have the chromosome deletions. Nevertheless, the decision was made to treat her with an oral chemotherapeutic agent called Temodar® (temozolomide). "We don't use the 1p, 19q analysis as an absolute indicator for selecting treatment," Dr. DeAngelis elaborates. "It is probably a measure of the overall prognosis of the tumor

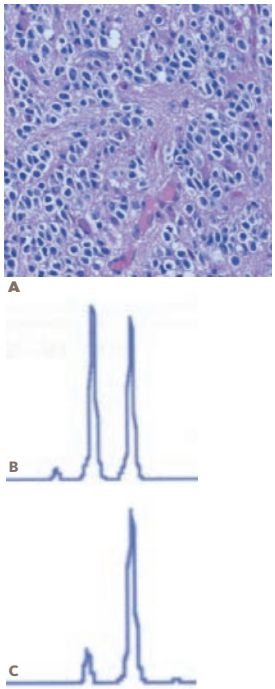

The MSKCC Laboratory of Diagnostic Molecular Pathology performs testing for the detection of specific chromosomal losses in brain tumors known as oligodendrogliomas. **IMAGE A:** An example of the type of cells a pathologist might see under the microscope. **IMAGE B:** In this example from a patient with oligodendroglioma, an assay based on the polymerase chain reaction was used to distinguish the two copies of the short arm of chromosome 1 in the patient's normal cells. The size of the peaks reflects the amount of each copy. **IMAGE C:** In this tumor, one of the two copies is lost. The small remaining peak is derived from the few normal cells present in the tumor tissue such as blood vessels. MSKCC clinicians are using this molecular testing to guide the selection of the most effective treatments for patients with this type of brain tumor.

ERIC HOLLAND (RIGHT), shown with **YELENA LYUSTIKMAN**, a graduate student who works in his laboratory.

A Mosaic: Working to Understand Brain Tumors

In his laboratory, neurosurgeon-scientist Eric C. Holland focuses primarily on understanding the molecular mechanisms that underlie the development of central nervous system tumors and on developing models of these cancers in mice. While working as a postdoctoral fellow at the National Institutes of Health (NIH) in the laboratory of Harold Varmus (former director of NIH and now President of MSKCC), Dr. Holland helped develop a technique of gene transfer that has been important for creating mouse models of glioma — a type of cancer of the glial cells, or supportive tissue of the brain. Such models are essential to making the transition from scientific concept to understanding a human tumor. Dr. Holland holds appointments in both MSKCC's Department of Neurology and the Neurosurgery Service in the Department of Surgery, and is an Associate Member in the new Cancer Biology and Genetics Program at the Sloan-Kettering Institute.

He uses a technique that employs a virus normally found only in birds as a gene delivery system in mice. While this avian virus is harmless in mice, the mice can be genetically altered to produce a receptor for the virus in certain cell types — brain cells, for example. The cancer gene is packaged into the virus, which carries it to the target cells, where tumors then form. "Human tumors have a lot of genetic abnormalities in them — and the question is, which of these abnormalities might actually cause the disease? Because if you knew that, they would be great targets for therapy," explains Dr. Holland. "So how do you show it? You design a system where you can take those abnormalities from the human disease and put them in a different species [in this case mice] and try to grow a similar tumor."

Although the number of people who develop gliomas is low, the biologic pathways that cause these types of tumors in the brain are the same pathways that cause other kinds of cancer. "In fact, if we are to do something substantial against gliomas — whatever drugs or drug combinations are used — these are likely to be useful in other cancer types. Therefore, investigators interested in other cancers are very interested in what we learn in the brain about gliomas, because this happens to be a great model," says Dr. Holland.

But what Dr. Holland does in the laboratory isn't simply to look for drugs that will kill brain tumors in mice, with an eye to giving these drugs to humans. "There's a huge drive to take what we have now and apply it to patients," Dr. Holland says. "And it's very understandable why you'd want to do that. But it's not just asking questions about how a tumor responds to a given drug. It's much more complicated than that. A tumor is a three-dimensional structure. It's got blood vessels. It's got various regions that behave differently. Understanding how each of these regions responds is a science in and of itself."

Dr. Holland compares basic science research to a mosaic. "It's like going into a Greek church and seeing a huge picture made out of these tiny tiles. Ultimately, our collective understanding of how the big picture works is built of all these small pieces. Mouse models are, in a sense, a good definition of translational science: It's not translating basic science into a treatment, but trying to define what part of the mosaic actually matters and in what context."

— but this is still a work in progress, an area of very active investigation." The standard treatment for oligodendroglioma is radiation. However, because Ms. Gurzynski's tumor involved both frontal lobes of her brain, the areas that control the highest order of cognitive thinking — and physicians expect her to live for many years — she could be vulnerable to the cognitive problems that may follow radiation therapy. "We elected to try chemotherapy based on the rationale that some patients with intact chromosomes 1p and 19q still respond to treatment. If the chemotherapy didn't work, then radiotherapy remained an option," Dr. DeAngelis says.

"We are finally understanding the basic biology of these tumors and, in parallel, are developing more and better therapies."

— LISA DEANGELIS, *Chairman, Department of Neurology*

Chemotherapy began. And something happened that wasn't necessarily predicted: Ms. Gurzynski's tumor started shrinking — in spite of the fact that her tumor cells lacked the chromosome deletions linked to better response to chemotherapy. [See samples of Ms. Gurzynski's MRI scans on page 24.] Ms. Gurzynski continues in treatment with Temodar® today, which she is able to take at home. "She's doing very well," says Dr. DeAngelis. "The only side effects she reports are some feelings of fatigue and 'intestinal issues.'" Ms. Gurzynski adds, "I'm thrilled — because I can do everything I did before."

"Brain tumor research is at a really exciting point," Dr. DeAngelis says. "In the past several years it's become so much more hopeful, because we are finally understanding the basic biology of these tumors and, in parallel, are also developing more and better therapies. We are just getting to the point where the two are going to intertwine, where we're going to be able to develop therapies and regimens that really target the biology. And actually, a lot of these biology-targeted drugs are in clinical trials right now — many of them at Memorial."

Meanwhile, back in Locust Valley, Ingrid Gurzynski gets up every morning to teach school and care for her family. Once a month she returns to MSKCC for a checkup, and every eight weeks she has an MRI to evaluate the tumor. "I appreciate the fact that I've come so far," she says. This summer, the Gurzynskis are traveling to Australia and New Zealand. "My husband asked, 'Are you sure you want to do it?' And I replied, 'Why are we waiting?' I know that the nature of brain tumors is that they change and can grow again. If that happens, we'll deal with it then. Right now, I want to live my life and enjoy it with my family. It's like I knew I wanted to come into the city on December 2nd — a year to the day after my surgery. I needed to create a new memory for myself. We had the most wonderful time. And today," she gazes into the adjoining room where Wally and Nicholas are getting help with their homework from their father, "today, we're together."