THYROID
Volume 26, Number 1, 2016
© American Thyroid Association
© Mary Ann Liebert, Inc.
DOI: 10.1089/thy.2015.0020

SPECIAL ARTICLE

2015 American Thyroid Association Management Guidelines for Adult Patients with Thyroid Nodules and Differentiated Thyroid Cancer

The American Thyroid Association Guidelines Task Force on Thyroid Nodules and Differentiated Thyroid Cancer

Bryan R. Haugen,[1,*] Erik K. Alexander,[2] Keith C. Bible,[3] Gerard M. Doherty,[4] Susan J. Mandel,[5] Yuri E. Nikiforov,[6] Furio Pacini,[7] Gregory W. Randolph,[8] Anna M. Sawka,[9] Martin Schlumberger,[10] Kathryn G. Schuff,[11] Steven I. Sherman,[12] Julie Ann Sosa,[13] David L. Steward,[14] R. Michael Tuttle,[15] and Leonard Wartofsky[16]

Downloaded by Memorial Sloan Kettering from www.liebertpub.com at 08/14/19. For personal use only.

Background: Thyroid nodules are a common clinical problem, and differentiated thyroid cancer is becoming increasingly prevalent. Since the American Thyroid Association's (ATA's) guidelines for the management of these disorders were revised in 2009, significant scientific advances have occurred in the field. The aim of these guidelines is to inform clinicians, patients, researchers, and health policy makers on published evidence relating to the diagnosis and management of thyroid nodules and differentiated thyroid cancer.

Methods: The specific clinical questions addressed in these guidelines were based on prior versions of the guidelines, stakeholder input, and input of task force members. Task force panel members were educated on knowledge synthesis methods, including electronic database searching, review and selection of relevant citations, and critical appraisal of selected studies. Published English language articles on adults were eligible for inclusion. The American College of Physicians Guideline Grading System was used for critical appraisal of evidence and grading strength of recommendations for therapeutic interventions. We developed a similarly formatted system to appraise the quality of such studies and resultant recommendations. The guideline panel had complete editorial independence from the ATA. Competing interests of guideline task force members were regularly updated, managed, and communicated to the ATA and task force members.

Results: The revised guidelines for the management of thyroid nodules include recommendations regarding initial evaluation, clinical and ultrasound criteria for fine-needle aspiration biopsy, interpretation of fine-needle aspiration biopsy results, use of molecular markers, and management of benign thyroid nodules. Recommendations regarding the initial management of thyroid cancer include those relating to screening for thyroid cancer, staging and risk assessment, surgical management, radioiodine remnant ablation and therapy, and thyrotropin suppression therapy using levothyroxine. Recommendations related to long-term management

[1]University of Colorado School of Medicine, Aurora, Colorado.
[2]Brigham and Women's Hospital, Harvard Medical School, Boston, Massachusetts.
[3]The Mayo Clinic, Rochester, Minnesota.
[4]Boston Medical Center, Boston, Massachusetts.
[5]Perelman School of Medicine, University of Pennsylvania, Philadelphia, Pennsylvania.
[6]University of Pittsburgh Medical Center, Pittsburgh, Pennsylvania.
[7]The University of Siena, Siena, Italy.
[8]Massachusetts Eye and Ear Infirmary, Massachusetts General Hospital, Harvard Medical School, Boston, Massachusetts.
[9]University Health Network, University of Toronto, Toronto, Ontario, Canada.
[10]Institute Gustave Roussy and University Paris Sud, Villejuif, France.
[11]Oregon Health and Science University, Portland, Oregon.
[12]University of Texas M.D. Anderson Cancer Center, Houston, Texas.
[13]Duke University School of Medicine, Durham, North Carolina.
[14]University of Cincinnati Medical Center, Cincinnati, Ohio.
[15]Memorial Sloan Kettering Cancer Center, New York, New York.
[16]MedStar Washington Hospital Center, Washington, DC.
*Chair.

Authors are listed in alphabetical order and were appointed by ATA to independently formulate the content of this manuscript. None of the scientific or medical content of the manuscript was dictated by the ATA.

of differentiated thyroid cancer include those related to surveillance for recurrent disease using imaging and serum thyroglobulin, thyroid hormone therapy, management of recurrent and metastatic disease, consideration for clinical trials and targeted therapy, as well as directions for future research.

Conclusions: We have developed evidence-based recommendations to inform clinical decision-making in the management of thyroid nodules and differentiated thyroid cancer. They represent, in our opinion, contemporary optimal care for patients with these disorders.

INTRODUCTION

Thyroid nodules are a common clinical problem. Epidemiologic studies have shown the prevalence of palpable thyroid nodules to be approximately 5% in women and 1% in men living in iodine-sufficient parts of the world (1,2). In contrast, high-resolution ultrasound (US) can detect thyroid nodules in 19%–68% of randomly selected individuals, with higher frequencies in women and the elderly (3,4). The clinical importance of thyroid nodules rests with the need to exclude thyroid cancer, which occurs in 7%–15% of cases depending on age, sex, radiation exposure history, family history, and other factors (5,6). Differentiated thyroid cancer (DTC), which includes papillary and follicular cancer, comprises the vast majority (>90%) of all thyroid cancers (7). In the United States, approximately 63,000 new cases of thyroid cancer were predicted to be diagnosed in 2014 (8) compared with 37,200 in 2009 when the last ATA guidelines were published. The yearly incidence has nearly tripled from 4.9 per 100,000 in 1975 to 14.3 per 100,000 in 2009 (9). Almost the entire change has been attributed to an increase in the incidence of papillary thyroid cancer (PTC). Moreover, 25% of the new thyroid cancers diagnosed in 1988–1989 were ≤1 cm compared with 39% of the new thyroid cancer diagnoses in 2008–2009 (9). This tumor shift may be due to the increasing use of neck ultrasonography or other imaging and early diagnosis and treatment (10), trends that are changing the initial treatment and follow-up for many patients with thyroid cancer. A recent population-based study from Olmsted County reported the doubling of thyroid cancer incidence from 2000 to 2012 compared to the prior decade as entirely attributable to clinically occult cancers detected incidentally on imaging or pathology (11). By 2019, one study predicts that PTC will become the third most common cancer in women at a cost of $19–21 billion in the United States (12). Optimization of long-term health outcomes and education about potential prognosis for individuals with thyroid neoplasms is critically important.

In 1996, the American Thyroid Association (ATA) published treatment guidelines for patients with thyroid nodules and DTC (13). Over the last 15–20 years, there have been many advances in the diagnosis and therapy of both thyroid nodules and DTC, but clinical controversy exists in many areas. A long history of insufficient peer-reviewed research funding for high-quality clinical trials in the field of thyroid neoplasia may be an important contributing factor to existing clinical uncertainties (12). Methodologic limitations or conflicting findings of older studies present a significant challenge to modern-day medical decision-making in many aspects of thyroid neoplasia. Although they are not a specific focus of these guidelines, we recognize that feasibility and cost considerations of various diagnostic and therapeutic options also present important clinical challenges in many clinical practice settings.

AIM AND TARGET AUDIENCE

Our objective in these guidelines is to inform clinicians, patients, researchers, and health policy makers about the best available evidence (and its limitations), relating to the diagnosis and treatment of adult patients with thyroid nodules and DTC. These guidelines should not be applied to children (<18–20 years old); recent ATA guidelines for children with thyroid nodules and DTC were published in 2015 (14). This document is intended to inform clinical decision-making. A major goal of these guidelines is to minimize potential harm from overtreatment in a majority of patients at low risk for disease-specific mortality and morbidity, while appropriately treating and monitoring those patients at higher risk. These guidelines should not be interpreted as a replacement for clinical judgement and should be used to complement informed, shared patient–health care provider deliberation on complex issues. It is important to note that national clinical practice guidelines may not necessarily constitute a legal standard of care in all jurisdictions (15). If important differences in practice settings present barriers to meaningful implementation of the recommendations of these guidelines, interested physicians or groups (in or outside of the United States) may consider adapting the guidelines using established methods (16,17) (ADAPTE Collaboration, 2009; www.g-i-n.net). The ADAPTE Collaboration is an international group of researchers, guideline developers, and guideline implementers who aim to promote the development and use of clinical practice guidelines through the adaption of existing guidelines. Because our primary focus was reviewing the quality of evidence related to health outcomes and diagnostic testing, we decided *a priori* not to focus on economic resource implications in these guidelines. As part of our review, we identified some knowledge gaps in the field, with associated future research priorities.

Other groups have previously developed clinical practice guidelines, including the American Association of Clinical Endocrinologists, Associazione Medici Endocrinologi, and the European Thyroid Association (18), the British Thyroid Association and The Royal College of Physicians (19), and the National Comprehensive Cancer Network (www.nccn.org). The European Thyroid Association has published consensus guidelines for postoperative US in the management of DTC (20). The Society for Nuclear Medicine and Molecular Imaging (21) and the European Association of Nuclear Medicine have also published guidelines for radioiodine (RAI) therapy of DTC (22). The Japanese Society of Thyroid Surgeons and the Japanese Association of Endocrine Surgeons

Downloaded by Memorial Sloan Kettering from www.liebertpub.com at 08/14/19. For personal use only.

Table 1. Interpretation of the American College of Physicians' Guideline Grading System (for Therapeutic Interventions)

Recommendation	*Clarity of risk/benefit*	*Implications*
Strong recommendation	Benefits clearly outweigh harms and burdens, or vice versa.	**Patients:** Most would want course of action; a person should request discussion if an intervention is not offered. **Clinicians:** Most patients should receive the recommended course of action. **Policymakers:** The recommendation can be adopted as policy in most circumstances.
Weak recommendation	Benefits closely balanced with harms and burdens.	**Patients:** Many would want course of action, but some may not; the decision may depend on individual circumstances. **Clinicians:** Different choices will be appropriate for different patients; the management decision should be consistent with patients' preferences and circumstances. **Policymakers:** Policymaking will require careful consideration and stakeholder input.
No recommendation	Balance of benefits and risks cannot be determined.	Decisions based on evidence cannot be made.

have recently revised guidelines on treatment of patients with thyroid tumors (23). Given the existing controversies in the field, differences in critical appraisal approaches for existing evidence, and differences in clinical practice patterns across geographic regions and physician specialties, it should not be surprising that the organizational guidelines are not in complete agreement for all issues. Such differences highlight the importance of clarifying evidence uncertainties with future high quality clinical research.

METHODS

ATA Thyroid Nodules and Differentiated Thyroid Cancer guidelines were published in 2006 (24) and revised in 2009 (25). Because of the rapid growth of the literature on this topic, plans for revising the guidelines within approximately 4 years of publication were made at the inception of the project. A task force chair was appointed by the ATA President with approval of the Board. A task force of specialists with complementary expertise (endocrinology, surgery, nuclear medicine, radiology, pathology, oncology, molecular diagnostics, and epidemiology) was appointed. In order to have broad specialty and geographic representation, as well as fresh perspectives, one-third of the task force is replaced for each iteration of the guidelines, per ATA policy. Upon discussion among the panel members and the Chair with other Chairs of other ATA guideline committees, the American College of Physicians' (ACP) Grading System was adopted

Table 2. Recommendations (for Therapeutic Interventions) Based on Strength of Evidence

Recommendation and evidence quality	*Description of supporting evidence*[a]	*Interpretation*
Strong recommendation		
High-quality evidence	RCT without important limitations or overwhelming evidence from observational studies	Can apply to most patients in most circumstances without reservation
Moderate-quality evidence	RCT with important limitations or strong evidence from observational studies	Can apply to most patients in most circumstances without reservation
Low-quality evidence	Observational studies/case studies	May change when higher-quality evidence becomes available
Weak recommendation		
High-quality evidence	RCT without important limitations or overwhelming evidence from observational studies	Best action may differ based on circumstances or patients' values
Moderate-quality evidence	RCT with important limitations or strong evidence from observational studies	Best action may differ based on circumstances or patients' values
Low-quality evidence	Observational studies/case studies	Other alternatives may be equally reasonable
Insufficient	Evidence is conflicting, of poor quality, or lacking	Insufficient evidence to recommend for or against

[a]This description of supporting evidence refers to therapy, therapeutic strategy, or prevention studies. The description of supporting evidence is different for diagnostic accuracy studies.
RCT, randomized controlled trial.

Downloaded by Memorial Sloan Kettering from www.liebertpub.com at 08/14/19. For personal use only.

Table 3. Interpretation of the American Thyroid Association Guideline Grading System for Diagnostic Tests

Recommendation	*Accuracy of diagnostic information versus risks and burden of testing*[a]	*Implications*
Strong recommendation	Knowledge of the diagnostic test result clearly outweighs risks and burden of testing or vice versa.	**Patients:** In the case of an accurate test for which benefits outweigh risks/burden, most would want the diagnostic to be offered (with appropriate counseling). A patient should request discussion of the test if it is not offered. In contrast, for a test in which risks and burden outweigh the benefits, most patients should not expect the test to be offered. **Clinicians:** In the case of an accurate test for which benefits outweigh risks/burden, most patients should be offered the diagnostic test (and provided relevant counseling). Counseling about the test should include a discussion of the risks, benefits, and uncertainties related to testing (as applicable), as well as the implications of the test result. In contrast, for a test in which risks and burden outweigh the perceived benefits, most patients should not be offered the test, or if the test is discussed, the rationale against the test should, for the particular clinical situation, be explained. **Policymakers:** In the case of an accurate test for which benefits outweigh risks/burden, availability of the diagnostic test should be adopted in health policy. In contrast, for a test in which risks and burden outweigh the perceived benefits, some restrictions on circumstances for test use may need to be considered.
Weak recommendation	Knowledge of the diagnostic test result is closely balanced with risks and burden of testing.	**Patients:** Most would want to be informed about the diagnostic test, but some would not want to seriously consider undergoing the test; a decision may depend on the individual circumstances (e.g., risk of disease, comorbidities, or other), the practice environment, feasibility of optimal execution of the test, and consideration of other available options. **Clinicians:** Different choices will be appropriate for different patients, and counseling about the test (if being considered) should include a discussion of the risks, benefits, and uncertainties related to testing (as applicable), as well as the implications of the test result. The decision to perform the test should include consideration of the patients' values, preferences, feasibility, and the specific circumstances. Counseling the patient on why the test may be helpful or not, in her/his specific circumstance, may be very valuable in the decision-making process. **Policymakers:** Policymaking decisions on the availability of the test will require discussion and stakeholder involvement.
No recommendation	Balance of knowledge of the diagnostic test result cannot be determined.	Decisions on the use of the test based on evidence from scientific studies cannot be made.

[a]Frequently in these guidelines, the accuracy of the diagnosis of thyroid cancer (relative to a histologic gold standard) was the diagnostic outcome unless otherwise specified. However, prognostic, disease staging, or risk stratification studies were also included in the grading scheme of diagnostic studies. For disease staging systems, the implication for use would be on the part of the clinician, in reporting results in the medical record and communicating them to the patient (at the applicable time point in disease or follow-up trajectory), as opposed to offering a specific choice of staging/risk stratification system to the patient.

for use in these guidelines, relating to critical appraisal and recommendations on therapeutic interventions (26) (Tables 1 and 2). An important component of these guidelines was judged to be critical appraisal of studies of diagnostic tests; however, the ACP Guideline Grading System is not designed for this purpose. We reviewed a number of appraisal systems for diagnostic tests, but some of the complexity and the time-consuming nature of some systems limited their feasibility for implementation in our group (27–31). We drafted, revised, and piloted the use of a newly developed diagnostic test appraisal system that was acceptable to panel members. This system included consideration of the following

Downloaded by Memorial Sloan Kettering from www.liebertpub.com at 08/14/19. For personal use only.

Table 4. Recommendations (for Diagnostic Interventions) Based on Strength of Evidence

Recommendation and evidence quality	*Methodologic quality of supporting evidence*	*Interpretation*
Strong recommendation		
High-quality evidence	Evidence from one or more well-designed nonrandomized diagnostic accuracy studies (i.e., observational—cross-sectional or cohort) or systematic reviews/meta-analyses of such observational studies (with no concern about internal validity or external generalizability of the results)	Implies the test can be offered to most patients in most applicable circumstances without reservation.
Moderate-quality evidence	Evidence from nonrandomized diagnostic accuracy studies (cross-sectional or cohort), with one or more possible limitations causing minor concern about internal validity or external generalizability of the results	Implies the test can be offered to most patients in most applicable circumstances without reservation.
Low-quality evidence	Evidence from nonrandomized diagnostic accuracy studies with one or more important limitations causing serious concern about internal validity or external generalizability of the results	Implies the test can be offered to most patients in most applicable circumstances, but the utilization of the test may change when higher-quality evidence becomes available.
Weak recommendation		
High-quality evidence	Evidence from one or more well-designed nonrandomized diagnostic accuracy studies (i.e., observational—cross-sectional or cohort) or systematic reviews/meta-analyses of such observational studies (with no concern about internal validity or external generalizability of the results)	The degree to which the diagnostic test is seriously considered may differ depending on circumstances or patients' or societal values.
Moderate-quality evidence	Evidence from nonrandomized diagnostic accuracy studies (cross-sectional or cohort), with one or more possible limitations causing minor concern about internal validity or external generalizability of the results	The degree to which the diagnostic test is seriously considered may differ depending on individual patients'/ practice circumstances or patients' or societal values.
Low-quality evidence	Evidence from nonrandomized diagnostic accuracy studies with one or more important limitations causing serious concern about internal validity or external generalizability of the results.	Alternative options may be equally reasonable.
Insufficient	Evidence may be of such poor quality, conflicting, lacking (i.e., studies not done), or not externally generalizable to the target clinical population such that the estimate of the true effect of the test is uncertain and does not permit a reasonable conclusion to be made.	Insufficient evidence exists to recommend for or against routinely offering the diagnostic test.

Downloaded by Memorial Sloan Kettering from www.liebertpub.com at 08/14/19. For personal use only.

methodologic elements: consecutive recruitment of patients representative of clinical practice, use of an appropriate reference gold standard, directness of evidence (e.g., target population of interest, testing procedures representative of clinical practice, and relevant outcomes), precision of diagnostic accuracy measures (e.g., width of confidence intervals for estimates such as sensitivity, specificity), and consistency of results among studies using the same test (Tables 3 and 4). In the majority of circumstances (unless otherwise specified), the outcome of interest for the diagnostic test was the diagnosis of thyroid cancer (relative to a histologic gold standard). However, prognostic studies were also graded using the diagnostic study critical appraisal framework. In terms of strength of recommendation for use of diagnostic studies, we modeled our approach on the ACP system for therapeutic studies, as previously described, but the target outcome was the accuracy in establishing a definitive diagnosis, largely relating to the diagnosis of new or recurrent malignancy (unless otherwise specified). Diagnostic tests or risk stratification systems used for estimation of prognosis were also appraised using the diagnostic test grading system. An important limitation of our diagnostic test appraisal system is that it does not specifically examine the clinical utility of a test in improving long-term health outcomes by execution of the test as part of an intended therapeutic strategy (unless specifically noted). However, as much as possible, we tried to separate recommendations on the diagnostic accuracy of a test from therapeutic management based on the test result, with the latter grading being more rigorous and based on longer term outcomes (whenever possible). It is important to note that according to our diagnostic test grading system, a body of well-executed nonrandomized diagnostic accuracy

Downloaded by Memorial Sloan Kettering from www.liebertpub.com at 08/14/19. For personal use only.

studies could be considered high-quality evidence; yet, a therapeutic strategy incorporating the use of the diagnostic test would require one or more well-executed randomized controlled trials (RCTs) to be considered high-quality evidence. In developing and applying our diagnostic test critical appraisal system, we considered American societal values, relating to the importance of informing patients about potentially helpful tests developed for their clinical situation (with counseling on relevant limitations) and the role of patients in informed, shared decision-making relating to diagnostic and therapeutic strategies. Such input was based on thoughtful consideration of stakeholder input, including input from physician stakeholders who were committee members. Because this was a preliminary pilot utilization of this diagnostic test critical appraisal system by our group, we have labeled recommendations using this system in the manuscript (diagnostic test recommendation). Moreover, we anticipate that the future iterations of these guidelines will likely incorporate further refinements to the system, or even possible adoption of another system, if it is superior and feasible to execute by contributing physicians.

Prior to initiating the reviews, all task force members were provided written and verbal group advice on conducting electronic literature searches, critical appraisal of articles, and rationale for formulating strength of recommendations from a panel member with epidemiology and systematic review expertise (via e-mail documents, a teleconference meeting on February 21, 2012). For each question, a primary reviewer performed a literature search, appraised relevant literature, generated recommendations, accompanying text, and a relevant bibliography. This was then reviewed by the secondary reviewer, revised as needed, and presented for review by the entire panel. Feedback and suggestions for revisions from the Chair and panel members were obtained via e-mail, regularly scheduled teleconferences, and face-to-face meetings held in conjunction with scientific meetings. Once the manuscript was drafted, all suggestions for revisions were regularly reviewed by all panel members in the form of a tracked changes draft manuscript and teleconferences. The draft document continued to be revised until no further suggestions for further revisions were requested by any panel members. Thus, general consensus on acceptability of recommendations and manuscript text was achieved, with the fundamental understanding that not all recommendations may be feasible in all practice settings.

Formal stakeholder input in development of these guidelines was sought from ATA membership in an online survey distributed in October 2011. Thyroid cancer survivor group leadership input was sought from three North American thyroid cancer groups via e-mail correspondence in January to March of 2012. We also reviewed any letters, editorials, or reviews of the 2009 iteration of the guidelines (25) that were collected by the current Chair of the committee. Prepublication verbal feedback on some of the key guideline recommendations was received at a formal Satellite Symposium held in conjunction with the Endocrine Society meeting in Chicago on June 19, 2014. The guideline manuscript was reviewed and approved by the ATA Board of Directors, then made available to the ATA membership for review and comments in September 2014. Substantive comments were received from 33 members representing endocrinology, surgery, pathology, and nuclear medicine. Feedback and suggestions were formally discussed by the panel, and revisions were made to the manuscript prior to journal submission. The organization of management guideline recommendations is shown in Table 5.

The medical opinions expressed here are those of the authors, and the committee had complete editorial independence from the ATA in writing the guidelines. No funding was received by individual committee members from the ATA or industry for work on these guidelines. Competing interests of all committee members were reviewed at inception of the group, yearly, and upon completion of the guidelines and are included with this document.

Table 5. Organization of the 2015 ATA Guidelines for Thyroid Nodules and Differentiated Thyroid Cancer

Page	*Location key*	*Sections and subsections*	*Item*[a]
10	[A1]	**THYROID NODULE GUIDELINES**	
10	[A2]	**What is the role of thyroid cancer screening in people with familial follicular cell–derived DTC?**[b]	R1[b]
10	[A3]	**What is the appropriate laboratory and imaging evaluation for patients with clinically or incidentally discovered thyroid nodules?**	
10	[A4]	Serum thyrotropin measurement	R2
11	[A5]	Serum thyroglobulin measurement	R3
11	[A6]	Serum calcitonin measurement	R4
11	[A7]	[18F]Fluorodeoxyglucose positron emission tomography[b]	R5[b]
12	[A8]	Thyroid sonography	R6
12	[A9]	US for FNA decision-making	R7
12	[A10]	Recommendations for diagnostic FNA of a thyroid nodule based on sonographic pattern[c]	R8[c] F1[c], F2[c], T6[c]
16	[A11]	**What is the role of FNA, cytology interpretation, and molecular testing in patients with thyroid nodules?**[c]	R9[c], F1[c], T7[c]
17	[A12]	Nondiagnostic cytology	R10
17	[A13]	Benign cytology	R11
18	[A14]	Malignant cytology	R12
19	[A15]	Indeterminate cytology (AUS/FLUS, FN, SUSP)[c]	

(*continued*)

Table 5. (Continued)

Page	*Location key*	*Sections and subsections*	*Item*[a]
19	[A16]	**What are the principles of the molecular testing of FNA samples?**[b]	R13–14
21	[A17]	AUS/FLUS cytology[c]	R15[c]
22	[A18]	Follicular neoplasm/suspicious for follicular neoplasm cytology [c]	R16[c]
23	[A19]	Suspicious for malignancy cytology[c]	R17[c]
23	[A20]	**What is the utility of ^{18}FDG -PET scanning to predict malignant or benign disease when FNA cytology is indeterminate (AUS/FLUS, FN, SUSP)?**[b]	R18[b]
23	[A21]	**What is the appropriate operation for cytologically indeterminate thyroid nodules?**[c]	R19–20[c]
25	[A22]	**How should multinodular thyroid glands (i.e., two or more clinically relevant nodules) be evaluated for malignancy?**	R21–22
25	[A23]	**What are the best methods for long-term follow-up of patients with thyroid nodules?**	
25	[A24]	Recommendations for initial follow-up of nodules with benign FNA cytology[c]	R23A–C[c]
25	[A25]	Recommendation for follow-up of nodules with two benign FNA cytology results[b]	R23D[b]
26	[A26]	Follow-up for nodules that do not meet FNA criteria[b]	R24[b]
27	[A27]	**What is the role of medical or surgical therapy for benign thyroid nodules?**	R25–29
27	[A28]	**How should thyroid nodules in pregnant women be managed?**	
27	[A29]	FNA for thyroid nodules discovered during pregnancy	R30
28	[A30]	Approaches to pregnant patients with malignant or indeterminate cytology	R31
28	[B1]	**DIFFERENTIATED THYROID CANCER: INITIAL MANAGEMENT GUIDELINES**	
29	[B2]	Goals of initial therapy of DTC	
29	[B3]	**What is the role of preoperative staging with diagnostic imaging and laboratory tests?**	
29	[B4]	Neck imaging—ultrasound	R32 F3, T6, T8[b]
30	[B5]	Neck imaging—CT/MRI/PET[c]	R33[c]
31	[B6]	Measurement of serum Tg and anti-Tg antibodies	R34
31	[B7]	Operative approach for a biopsy diagnostic for follicular cell–derived malignancy[c]	R35[c]
33	[B8]	Lymph node dissection	R36–37, F3
35	[B9]	Completion thyroidectomy	R38
35	[B10]	**What is the appropriate perioperative approach to voice and parathyroid issues?**[b]	
35	[B11]	Preoperative care communication[b]	R39[b]
35	[B12]	Preoperative voice assessment[b]	R40–41[b], T9[b]
36	[B13]	Intraoperative voice and parathyroid management[b]	R42–43[b]
37	[B14]	Postoperative care[b]	R44–45[b]
37	[B15]	**What are the basic principles of histopathologic evaluation of thyroidectomy samples?**[b]	R46[b]
40	[B16]	**What is the role of postoperative staging systems and risk stratification in the management of DTC?**	
40	[B17]	Postoperative staging	R47
40	[B18]	AJCC/UICC TNM staging	T10
41	[B19]	**What initial stratification system should be used to estimate the risk of persistent/recurrent disease?**[c]	R48[c], T11[b], T12[c]
43	[B20]	Potential impact of specific clinico-pathologic features on the risk estimates in PTC[b]	
44	[B21]	Potential impact of *BRAF*^{V600E} and other mutations on risk of estimates in PTC[b]	
45	[B22]	Potential impact of postoperative serum Tg on risk estimates[b]	
46	[B23]	Proposed modifications to the 2009 ATA initial risk stratification system[b]	T12[c]
46	[B24]	Risk of recurrence as a continuum of risk[b]	F4[b]
46	[B25]	**How should initial risk estimates be modified over time?**[b]	R49
47	[B26]	Proposed terminology to classify response to therapy and clinical	

(*continued*)

Downloaded by Memorial Sloan Kettering from www.liebertpub.com at 08/14/19. For personal use only.

Table 5. (Continued)

Page	*Location key*	*Sections and subsections*	*Item*[a]
		implications[b]	
47	[B27]	Excellent response: no clinical, biochemical, or structural evidence of disease after initial therapy (remission, NED)[b]	T13[b]
50	[B28]	Biochemical incomplete response: abnormal Tg values in the absence of localizable disease[b]	T13[b]
51	[B29]	Structural incomplete response: persistent or newly identified loco-regional or distant metastases[b]	T13[b]
52	[B30]	Indeterminate response: biochemical or structural findings that cannot be classified as either benign or malignant (acceptable response)[b]	T13[b]
52	[B31]	Using risk stratification to guide disease surveillance and therapeutic management decisions[b]	
53	[B32]	**Should postoperative disease status be considered in decision-making for RAI therapy for patients with DTC?**	R50
53	[B33]	Utility of postoperative serum Tg in clinical decision-making	
54	[B34]	Potential role of postoperative US in conjunction with postoperative serum Tg in clinical decision-making	
54	[B35]	Role of postoperative radioisotope diagnostic scanning in clinical decision-making	
55	[B36]	**What is the role of RAI (including remnant ablation, adjuvant therapy, or therapy persistent disease) after thyroidectomy in the primary management of differentiated thyroid cancer?**	R51 T14
58	[B37]	What is the role of molecular marker status in therapeutic RAI decision-making?[b]	R52[b]
58	[B38]	**How long does thyroid hormone need to be withdrawn in preparation for RAI remnant ablation/treatment or diagnostic scanning?**	R53
59	[B39]	**Can rhTSH (Thyrogen) be used as an alternative to thyroxine withdrawal for remnant ablation or adjuvant therapy in patients who have undergone near-total or total thyroidectomy?**	R54
60	[B40]	**What activity of ^{131}I should be used for remnant ablation or adjuvant therapy?**[c]	R55–56[c]
63	[B41]	**Is a low-iodine diet necessary before remnant ablation?**	R57
63	[B42]	**Should a posttherapy scan be performed following remnant ablation or adjuvant therapy?**	R58
64	[B43]	Early management of DTC after initial therapy	
64	[B44]	**What is the appropriate degree of initial TSH suppression?**	R59
65	[B45]	**Is there a role for adjunctive external beam radiation or chemotherapy?**	
65	[B46]	External beam radiation	R60
65	[B47]	Systemic adjuvant therapy	R61
65	[C1]	**DTC: LONG-TERM MANAGEMENT AND ADVANCED CANCER MANAGEMENT GUIDELINES**	
65	[C2]	**What are the appropriate features of long-term management?**	
66	[C3]	**What are the criteria for absence of persistent tumor (excellent response)?**	
66	[C4]	**What are the appropriate methods for following patients after initial therapy?**	
66	[C5]	**What is the role of serum Tg measurement in the follow-up of DTC?**[c]	R62–63[c]
66	[C6]	Serum Tg measurement and clinical utility	
68	[C7]	Anti-Tg antibodies	
68	[C8]	**What is the role of serum Tg measurement in patients who have not undergone RAI remnant ablation?**	R64
69	[C9]	**What is the role of US and other imaging techniques (RAI SPECT/CT, CT, MRI, PET-CT) during follow-up?**	
69	[C10]	Cervical ultrasonography	R65
69	[C11]	Diagnostic whole-body RAI scans	R66–67
70	[C12]	^{18}FDG-PET scanning	R68
71	[C13]	CT and MRI[b]	R69[b]
72	[C14]	Using ongoing risk stratification (response to therapy) to guide disease long-term surveillance and therapeutic management decisions[b]	

(*continued*)

Downloaded by Memorial Sloan Kettering from www.liebertpub.com at 08/14/19. For personal use only.

Table 5. (Continued)

Page	*Location key*	*Sections and subsections*	*Item*[a]
72	[C15]	**What is the role of TSH suppression during thyroid hormone therapy in the long-term follow-up of DTC?**[c]	R70[c] T15[b]
74	[C16]	**What is the most appropriate management of DTC patients with metastatic disease?**	
74	[C17]	**What is the optimal directed approach to patients with suspected structural neck recurrence?**	R71
74	[C18]	Nodal size threshold	
75	[C19]	Extent of nodal surgery	
75	[C20]	Ethanol injection[b]	
75	[C21]	Radiofrequency or laser ablation[b]	
75	[C22]	Other therapeutic options[b]	
76	[C23]	**What is the surgical management of aerodigestive invasion?**	R72
76	[C24]	**How should RAI therapy be considered for loco-regional or distant metastatic disease?**	
76	[C25]	Administered activity of ^{131}I for loco-regional or metastatic disease[c]	R73[c]
77	[C26]	Use of rhTSH (Thyrogen) to prepare patients for ^{131}I therapy for loco-regional or metastatic disease	R74–75
77	[C27]	Use of lithium in ^{131}I therapy	R76
77	[C28]	**How should distant metastatic disease to various organs be treated?**	
78	[C29]	Treatment of pulmonary metastases	R77–78
78	[C30]	RAI treatment of bone metastases	R79
79	[C31]	**When should empiric RAI therapy be considered for Tg-positive, RAI diagnostic scan–negative patients?**	R80–82
79	[C32]	**What is the management of complications of RAI therapy?**	R83–85
80	[C33]	**How should patients who have received RAI therapy be monitored for risk of secondary malignancies?**	R86
80	[C34]	**What other testing should patients receiving RAI therapy undergo?**	R87
80	[C35]	**How should patients be counseled about RAI therapy and pregnancy, breastfeeding, and gonadal function?**	R88–90
81	[C36]	**How is RAI-refractory DTC classified?**[b]	R91[b]
82	[C37]	**Which patients with metastatic thyroid cancer can be followed without additional therapy?**[b]	R92[b]
82	[C38]	**What is the role for directed therapy in advanced thyroid cancer?**[c]	R93[c]
84	[C39]	Treatment of brain metastases	R94
84	[C40]	**Who should be considered for clinical trials?**[b]	R95[b]
84	[C41]	**What is the role of systemic therapy (kinase inhibitors, other selective therapies, conventional chemotherapy, bisphosphonates) in treating metastatic DTC?**[c]	
85	[C42]	Kinase inhibitors[b]	R96[b], T16[b]
87	[C43]	Patients for whom first-line kinase inhibitor therapy fails[b]	R97[b]
87	[C44]	Management of toxicities from kinase inhibitor therapy[b]	R98[b], T17[b]
87	[C45]	Other novel agents[b]	R99
87	[C46]	Cytotoxic chemotherapy	R100
88	[C47]	Bone-directed agents[c]	R101[c]
89	[D1]	**DIRECTIONS FOR FUTURE RESEARCH**	
89	[D2]	Optimizing molecular markers for diagnosis, prognosis, and therapeutic targets	
89	[D3]	Active surveillance of DTC primary tumors	
90	[D4]	Improved risk stratification	
90	[D5]	Improving our understanding of the risks and benefits of DTC treatments and optimal implementation/utilization	
90	[D6]	Issues with measurement of Tg and anti-Tg antibodies	
90	[D7]	Management of metastatic cervical adenopathy detected on US	
91	[D8]	Novel therapies for systemic RAI-refractory disease	
91	[D9]	Survivorship care	

[a]F, figure; R, recommendation; T, table.
[b]New section/recommendation.
[c]Substantially changed recommendation compared with 2009.

ATA, American Thyroid Association; AUS/FLUS, atypia of undetermined significance/follicular lesion of undetermined significance; CT, computed tomography; DTC, differentiated thyroid cancer; FN, follicular neoplasm; FNA, fine-needle aspiration; ^{18}FDG-PET, [^{18}F]fluorodeoxyglucose positron emission tomography; MRI, magnetic resonance imaging; NED, no evidence of disease; PET, positron emission tomography; RAI, radioactive iodine (radioiodine); rhTSH, recombinant human thyrotropin; SPECT/CT, single photon emission computed tomography–computed tomography; SUSP, suspicious for malignancy; Tg, thyroglobulin; TSH, thyrotropin; US, ultrasound.

Downloaded by Memorial Sloan Kettering from www.liebertpub.com at 08/14/19. For personal use only.

[A1] THYROID NODULE GUIDELINES

A thyroid nodule is a discrete lesion within the thyroid gland that is radiologically distinct from the surrounding thyroid parenchyma. Some palpable lesions may not correspond to distinct radiologic abnormalities (32). Such abnormalities do not meet the strict definition for thyroid nodules. Nonpalpable nodules detected on US or other anatomic imaging studies are termed incidentally discovered nodules or ''incidentalomas.'' Nonpalpable nodules have the same risk of malignancy as do sonographically confirmed palpable nodules of the same size (33). Generally, only nodules >1 cm should be evaluated, since they have a greater potential to be clinically significant cancers. Occasionally, there may be nodules <1 cm that require further evaluation because of clinical symptoms or associated lymphadenopathy. In very rare cases, some nodules <1 cm lack these sonographic and clinical warning signs yet may nonetheless cause future morbidity and mortality. This remains highly unlikely, and given the unfavorable cost/benefit considerations, attempts to diagnose and treat all such small thyroid cancers in an effort to prevent exceedingly rare outcomes is deemed to cause more harm than good. In general, the guiding clinical strategy acknowledges that most thyroid nodules are low risk, and many thyroid cancers pose minimal risk to human health and can be effectively treated.

[A2] What is the role of thyroid cancer screening in people with familial follicular cell–derived DTC?

■ **RECOMMENDATION 1**

Screening people with familial follicular cell–derived DTC may lead to an earlier diagnosis of thyroid cancer, but the panel cannot recommend for or against US screening since there is no evidence that this would lead to reduced morbidity or mortality.

(No recommendation, Insufficient evidence)

Screening programs for patients at risk of oncological disease are usually advocated based on the following evidence: (a) a clear demonstration that the patient is indeed at risk; (b) demonstration that screening allows the detection of the disease at an earlier stage; (c) early diagnosis has an impact on subsequent outcome, both recurrence and survival.

Family members of patients with nonmedullary DTC may be considered at risk based on epidemiological evidence showing that 5%–10% of DTCs have a familial occurrence. However, in most of the pedigrees only two members are affected. There is controversy on whether two family members are sufficient to define a real familial disease rather than a fortuitous association. The probability estimates reported by Charkes (34) suggests that when only two first-degree family members are affected, the probability that the disease is sporadic is 62%. This probability decreases when the number of affected family members is three or more. In contrast, the study by Capezzone *et al.* (35), which was statistically adjusted to minimize risk of ''insufficient follow-up bias,'' demonstrates that even when only two family members are affected, the disease displays the features of ''genetic anticipation'' (occurrence of the disease at an earlier age and with more aggressive presentation in the subsequent generation compared with the first generation), which is considered good evidence for a distinct clinical entity possibly representing true familial disease. Appearance of the disease at an earlier age has also been found by Moses *et al.* (36). More advanced disease at presentation and slightly worse outcomes have been reported in familial cases by Capezzone *et al.* (35). More frequent multicentricity has been reported by Ito *et al.* (37), but disease-free and overall survival were similar to sporadic cases. In the study by Park *et al.* (38), familial follicular cell–derived DTC patients with parent–offspring relationship were found to have a higher recurrence rate compared with sporadic cases and the second generation had even higher rates compared with the first generation. Mazeh *et al.* (39) found that familial DTC patients had more aggressive disease compared with sporadic cases regardless of the number of family members affected. In contrast, Robenshtok *et al.* (40) found that staging at diagnosis and outcomes were not different in familial DTC patients compared with sporadic DTC patients. Syndromes associated with DTC (e.g., PTEN [phosphatase and tensin homolog] hamartoma tumor syndrome [Cowden's disease], familial adenomatous polyposis [FAP], Carney complex, multiple endocrine neoplasia [MEN] 2, Werner syndrome/progeria) in a first-degree relative, warrant screening based on various components of that syndrome (41).

It is not possible to speculate on the impact of screening in preventing or reducing recurrence and deaths, since no interventional screening programs have ever been reported in at-risk family members. Patients with familial DTC should have a careful history and directed neck examination as a part of routine health maintenance. One should also consider thyroid cancer syndromes as noted above (41).

[A3] What is the appropriate laboratory and imaging evaluation for patients with clinically or incidentally discovered thyroid nodules?

[A4] Serum thyrotropin measurement

■ **RECOMMENDATION 2**

(A) Serum thyrotropin (TSH) should be measured during the initial evaluation of a patient with a thyroid nodule.

(Strong recommendation, Moderate-quality evidence)

(B) If the serum TSH is subnormal, a radionuclide (preferably ^{123}I) thyroid scan should be performed. **(Strong recommendation, Moderate-quality evidence)**

(C) If the serum TSH is normal or elevated, a radionuclide scan should not be performed as the initial imaging evaluation.

(Strong recommendation, Moderate-quality evidence)

With the discovery of a thyroid nodule, a complete history and physical examination focusing on the thyroid gland and adjacent cervical lymph nodes should be performed. Pertinent historical factors predicting malignancy include a history of childhood head and neck radiation therapy, total body radiation for bone marrow transplantation (42), exposure to ionizing radiation from fallout in childhood or adolescence (43), familial thyroid carcinoma, or thyroid cancer syndrome (e.g., PTEN hamartoma tumor syndrome [Cowden's disease], FAP, Carney complex, Werner syndrome/progeria, or MEN 2, a risk for medullary thyroid cancer [MTC]) in a first-degree relative, rapid nodule growth, and/or hoarseness.

Downloaded by Memorial Sloan Kettering from www.liebertpub.com at 08/14/19. For personal use only.

Pertinent physical findings suggesting possible malignancy include vocal cord paralysis, cervical lymphadenopathy, and fixation of the nodule to surrounding tissue.

With the discovery of a thyroid nodule >1 cm in any diameter, a serum TSH level should be obtained. If the serum TSH is subnormal, a radionuclide thyroid scan should be obtained to document whether the nodule is hyperfunctioning (''hot,'' i.e., tracer uptake is greater than the surrounding normal thyroid), isofunctioning (''warm,'' i.e., tracer uptake is equal to the surrounding thyroid), or nonfunctioning (''cold,'' i.e., has uptake less than the surrounding thyroid tissue) (44). Since hyperfunctioning nodules rarely harbor malignancy, if one is found that corresponds to the nodule in question, no cytologic evaluation is necessary. If overt or subclinical hyperthyroidism is present, additional evaluation is required. A higher serum TSH level, even within the upper part of the reference range, is associated with increased risk of malignancy in a thyroid nodule, as well as more advanced stage thyroid cancer (45,46).

[A5] Serum thyroglobulin measurement

■ **RECOMMENDATION 3**

Routine measurement of serum thyroglobulin (Tg) for initial evaluation of thyroid nodules is not recommended.

(Strong recommendation, Moderate-quality evidence)

Serum Tg levels can be elevated in most thyroid diseases and are an insensitive and nonspecific test for thyroid cancer (47–49).

[A6] Serum calcitonin measurement

■ **RECOMMENDATION 4**

The panel cannot recommend either for or against routine measurement of serum calcitonin in patients with thyroid nodules.

(No recommendation, Insufficient evidence)

The utility of serum calcitonin has been evaluated in a series of prospective, nonrandomized studies (50–54). These data suggest that the use of routine serum calcitonin for screening may detect C-cell hyperplasia and MTC at an earlier stage, and overall survival consequently may be improved. However, most studies relied on pentagastrin stimulation testing to increase specificity. This drug is not available in the United States, Canada, and some other countries, and there remain unresolved issues of sensitivity, specificity, assay performance, cut-offs using calcium stimulation (55), and cost effectiveness. Two retrospective studies have shown improved survival in patients diagnosed with MTC after routine calcitonin testing compared with historical controls (53,56), but they were unable to show a decreased number of MTC-related deaths. A cost-effectiveness analysis suggested that calcitonin screening would be cost effective in the United States (57). However, prevalence estimates of MTC in this analysis included patients with C-cell hyperplasia and microMTC, which have uncertain clinical significance. Based on the retrospective nature of the survival data, unresolved issues of assay performance, lack of availability of pentagastrin in North America, and potential biases in the cost-effective analysis, the task force cannot recommend for or against the routine measurement of serum calcitonin as a screening test in patients with thyroid nodules, although there was not uniform agreement on this recommendation. There was, however, agreement that serum calcitonin may be considered in the subgroup of patients in whom an elevated calcitonin may change the diagnostic or surgical approach (i.e., patients considered for less than total thyroidectomy, patients with suspicious cytology not consistent with PTC). If the unstimulated serum calcitonin determination has been obtained and the level is greater than 50–100 pg/mL, a diagnosis of MTC is common (58).

There is emerging evidence that a calcitonin measurement from a thyroid nodule fine-needle aspiration (FNA) washout may be helpful in the preoperative evaluation of patients with a modestly elevated basal serum calcitonin (20–100 pg/mL) (59).

[A7] [^{18}F]Fluorodeoxyglucose positron emission tomography scan

■ **RECOMMENDATION 5**

(A) Focal [^{18}F]fluorodeoxyglucose positron emission tomography (^{18}FDG-PET) uptake within a sonographically confirmed thyroid nodule conveys an increased risk of thyroid cancer, and FNA is recommended for those nodules ≥1 cm.

(Strong recommendation, Moderate-quality evidence)

B) Diffuse ^{18}FDG-PET uptake, in conjunction with sonographic and clinical evidence of chronic lymphocytic thyroiditis, does not require further imaging or FNA.

(Strong recommendation, Moderate-quality evidence)

^{18}FDG-PET is increasingly performed during the evaluation of patients with both malignant and nonmalignant illness. While ^{18}FDG-PET imaging is not recommended for the evaluation of patients with newly detected thyroid nodules or thyroidal illness, the incidental detection of abnormal thyroid uptake may nonetheless be encountered. Importantly, incidental ^{18}FDG-PET uptake in the thyroid gland can be either focal or diffuse. Focal ^{18}FDG-PET uptake in the thyroid is incidentally detected in 1%–2% of patients, while an additional 2% of patients demonstrate diffuse thyroid uptake (60–62).

Focal thyroid uptake most often corresponds to a clinically relevant thyroid nodule, and US examination is thus recommended to define thyroid anatomy. Importantly, focal ^{18}FDG-PET uptake increases malignancy risk in an affected nodule, and therefore clinical evaluation and FNA of nodules ≥1 cm is recommended. ^{18}FDG-PET positive thyroid nodules <1 cm that do not meet FNA criteria (see Recommendation 8) can be monitored similarly to thyroid nodules with high-risk sonographic patterns that do not meet FNA criteria (see Recommendation 24A). A recent meta-analysis confirmed that approximately one in three (~35%) ^{18}FDG-PET positive thyroid nodules proved to be cancerous (60), with higher mean maximum standardized uptake value in malignant compared to benign nodules (6.9 vs. 4.8, $p < 0.001$). In contrast, diffuse thyroid uptake most often represents benign disease corresponding to inflammatory uptake in the setting

Downloaded by Memorial Sloan Kettering from www.liebertpub.com at 08/14/19. For personal use only.

of Hashimoto's disease or other diffuse thyroidal illness. However, if detected, diffuse ^{18}FDG-PET uptake in the thyroid should also prompt sonographic examination to ensure there is no evidence of clinically relevant nodularity. Most patients with diffuse ^{18}FDG-PET uptake demonstrate diffuse heterogeneity on sonographic examination, and no further intervention or FNA is required. It is appropriate to evaluate thyroid function in these patients.

[A8] Thyroid sonography

■ **RECOMMENDATION 6**

Thyroid sonography with survey of the cervical lymph nodes should be performed in all patients with known or suspected thyroid nodules.

(Strong recommendation, High-quality evidence)

Diagnostic thyroid/neck US should be performed in all patients with a suspected thyroid nodule, nodular goiter, or radiographic abnormality suggesting a thyroid nodule incidentally detected on another imaging study (e.g., computed tomography [CT] or magnetic resonance imaging [MRI] or thyroidal uptake on ^{18}FDG-PET scan) (www.aium.org/resources/guidelines/thyroid.pdf). Thyroid US can answer the following questions: Is there truly a nodule that corresponds to an identified abnormality? How large is the nodule? What is the nodule's pattern of US imaging characteristics? Is suspicious cervical lymphadenopathy present? Is the nodule greater than 50% cystic? Is the nodule located posteriorly in the thyroid gland? These last two features might decrease the accuracy of FNA biopsy performed with palpation (63,64).

Ultrasound should evaluate the following: thyroid parenchyma (homogeneous or heterogeneous) and gland size; size, location, zand sonographic characteristics of any nodule(s); the presence or absence of any suspicious cervical lymph nodes in the central or lateral compartments. The US report should convey nodule size (in three dimensions) and location (e.g., right upper lobe) and a description of the nodule's sonographic features including composition (solid, cystic proportion, or spongiform), echogenicity, margins, presence and type of calcifications, and shape if taller than wide, and vascularity. The pattern of sonographic features associated with a nodule confers a risk of malignancy, and combined with nodule size, guides FNA decision-making (65,66) (see Recommendation 8).

In the subset of patients with low serum TSH levels who have undergone radionuclide thyroid scintigraphy suggesting nodularity, US should also be performed to evaluate both the presence of nodules concordant with the hyperfunctioning areas on the scan, which do not require FNA, as well as other nonfunctioning nodules that meet sonographic criteria for FNA (67).

[A9] US for FNA decision-making

■ **RECOMMENDATION 7**

FNA is the procedure of choice in the evaluation of thyroid nodules, when clinically indicated.

(Strong recommendation, High-quality evidence)

FNA is the most accurate and cost-effective method for evaluating thyroid nodules. Retrospective studies have reported lower rates of both nondiagnostic and false-negative cytology from FNA procedures performed using US guidance compared to palpation (68,69). Therefore, for nodules with a higher likelihood of either a nondiagnostic cytology (>25%–50% cystic component) (64) or sampling error (difficult to palpate or posteriorly located nodules), US-guided FNA is preferred. If the diagnostic US confirms the presence of a predominantly solid nodule corresponding to what is palpated, the FNA may be performed using palpation or US guidance.

[A10] Recommendations for diagnostic FNA of a thyroid nodule based on sonographic pattern

Figure 1 provides an algorithm for evaluation and management of patients with thyroid nodules based on sonographic pattern and FNA cytology, which is discussed in subsequent sections.

■ **RECOMMENDATION 8**

I. Thyroid nodule diagnostic FNA is recommended for (Fig. 2, Table 6):

(A) Nodules ≥1 cm in greatest dimension with high suspicion sonographic pattern.

(Strong recommendation, Moderate-quality evidence)

(B) Nodules ≥1 cm in greatest dimension with intermediate suspicion sonographic pattern.

(Strong recommendation, Low-quality evidence)

(C) Nodules ≥1.5 cm in greatest dimension with low suspicion sonographic pattern.

(Weak recommendation, Low-quality evidence)

II. Thyroid nodule diagnostic FNA may be considered for (Fig. 2, Table 6):

(D) Nodules ≥2 cm in greatest dimension with very low suspicion sonographic pattern (e.g., spongiform). Observation without FNA is also a reasonable option.

(Weak recommendation, Moderate-quality evidence)

III. Thyroid nodule diagnostic FNA is not required for (Fig. 2, Table 6):

(E) Nodules that do not meet the above criteria.

(Strong recommendation, Moderate-quality evidence)

(F) Nodules that are purely cystic.

(Strong recommendation, Moderate-quality evidence)

Thyroid US has been widely used to stratify the risk of malignancy in thyroid nodules, and aid decision-making about whether FNA is indicated. Studies consistently report that several US gray scale features in multivariate analyses are associated with thyroid cancer, the majority of which are PTC. These include the presence of microcalcifications, nodule hypoechogenicity compared with the surrounding thyroid or strap muscles, irregular margins (defined as either infiltrative, microlobulated, or spiculated), and a shape taller than wide measured on a transverse view. Features with the highest specificities (median >90%) for thyroid cancer are microcalcifications, irregular margins, and tall shape,

Downloaded by Memorial Sloan Kettering from www.liebertpub.com at 08/14/19. For personal use only.

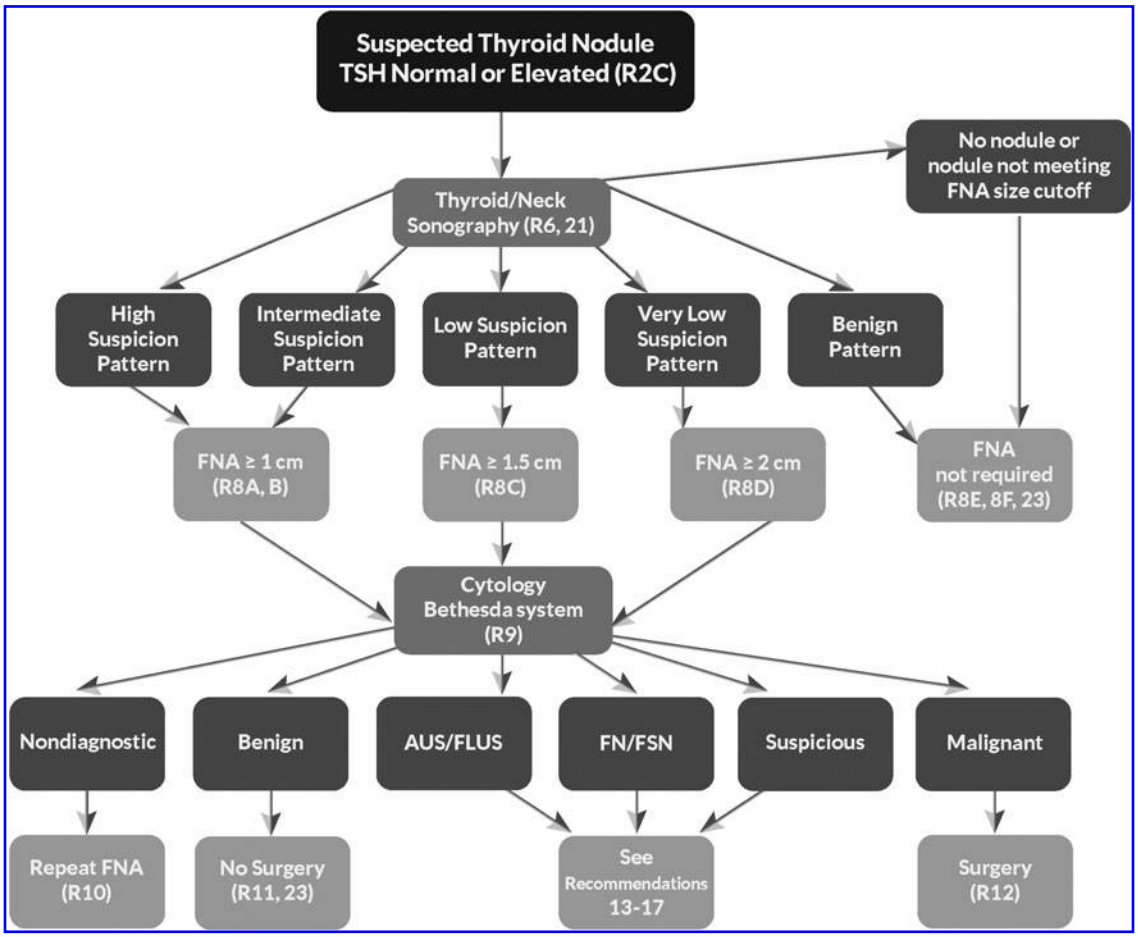

FIG. 1. Algorithm for evaluation and management of patients with thyroid nodules based on US pattern and FNA cytology. R, recommendation in text.

although the sensitivities are significantly lower for any single feature (70–77). It is important to note that poorly defined margins, meaning the sonographic interface between the nodule and the surrounding thyroid parenchyma is difficult to delineate, are not equivalent to irregular margins. An irregular margin indicates the demarcation between nodule and parenchyma is clearly visible but demonstrates an irregular, infiltrative or spiculated course. Up to 55% of benign nodules are hypoechoic compared to thyroid parenchyma, making nodule hypoechogenicity less specific. In addition, subcentimeter benign nodules are more likely to be hypoechoic than larger nodules (71). Multivariable analyses confirm that the probability of cancer is higher for nodules with either microlobulated margins or microcalcifications than for hypoechoic solid nodules lacking these features (70). Macrocalcifications within a nodule, if combined with microcalcifications, confer the same malignancy risk as microcalcifications alone (70,74). However, the presence of this type of intranodular macrocalcification alone is not consistently associated with thyroid cancer (78). On the other hand, a nodule that has interrupted peripheral calcifications, in association with a soft tissue rim outside the calcification, is highly likely to be malignant, and the associated pathology may demonstrate tumor invasion in the area of disrupted calcification (79,80).

In a recent study where 98% of the cancers were PTC, intranodular vascularity did not have independent predictive value for malignancy in multivariate logistic regression model including gray-scale features (72). Two other studies and a meta-analysis with higher proportions of follicular thyroid cancer (FTC) (10%–22%) have shown that intranodular vascularity was correlated with malignancy (66,74,81). FTC exhibits other differences in sonographic features compared to PTC. These tumors are more likely to be iso- to hyperechoic, noncalcified, round (width greater than anterioposterior dimension) nodules with regular smooth margins (82). Similarly, the follicular variant of papillary cancer (FVPTC) is also more likely than conventional PTC to have this same appearance as FTC (79). Distant metastases are rarely observed arising from follicular cancers <2 cm in diameter, which therefore justifies a higher size cutoff for hyperechoic nodules (83).

The vast majority (82%–91%) of thyroid cancers are solid (70,73,75,77,84). Of 360 consecutively surgically removed thyroid cancers at the Mayo clinic, 88% were solid or minimally cystic (<5%), 9% were <50% cystic, and only 3% were more than 50% cystic (85). Therefore, FNA decision-making for partially cystic thyroid nodules must be tempered by their lower malignant risk. In addition, evidence linking sonographic features with malignancy in this subgroup of nodules is less robust, originating from univariate rather than multivariate analyses. However, an eccentric rather than concentric position of the solid component along the cyst wall, an acute rather than obtuse angle interface of the

Downloaded by Memorial Sloan Kettering from www.liebertpub.com at 08/14/19. For personal use only.

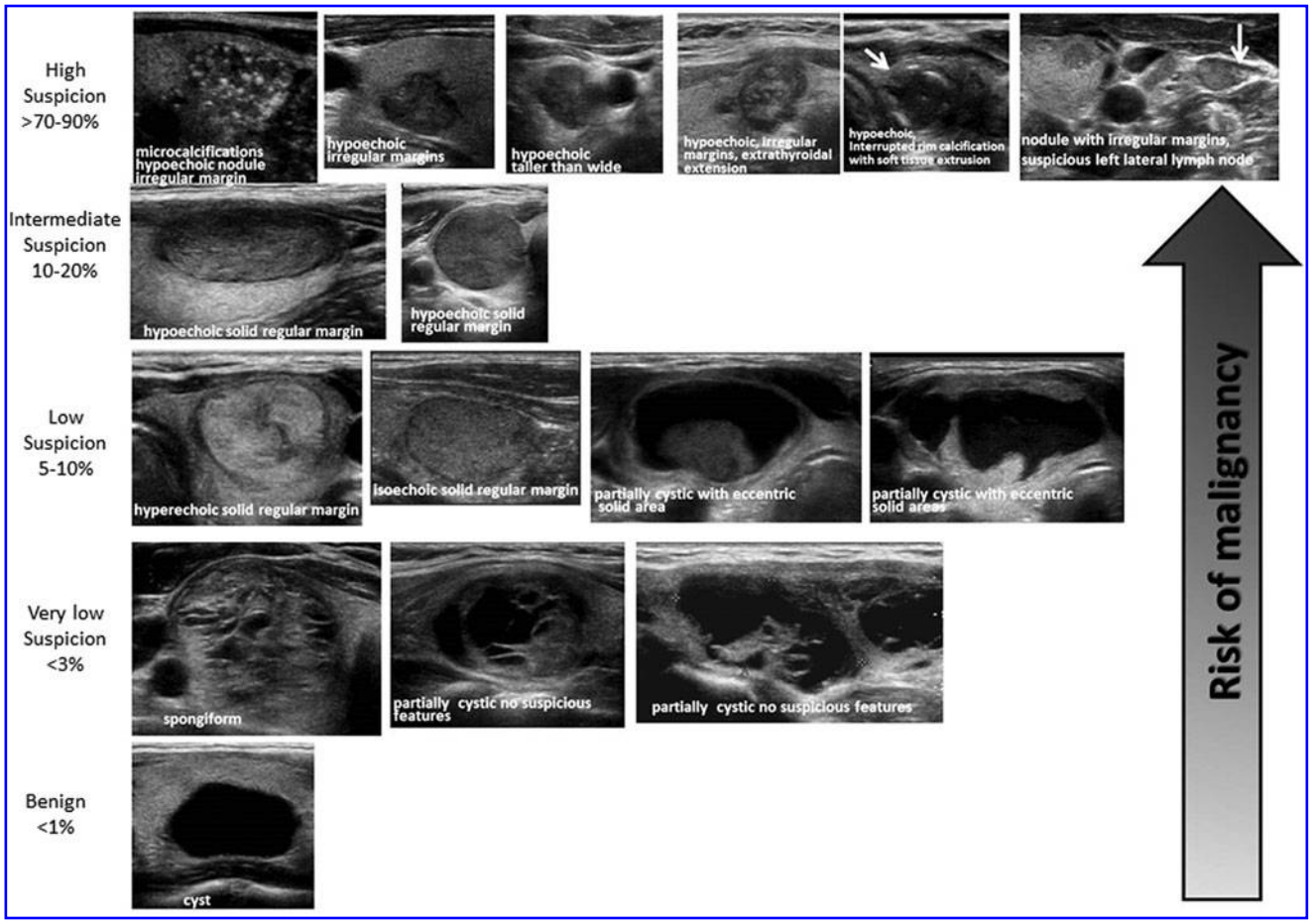

FIG. 2. ATA nodule sonographic patterns and risk of malignancy.

TABLE 6. SONOGRAPHIC PATTERNS, ESTIMATED RISK OF MALIGNANCY, AND FINE-NEEDLE ASPIRATION GUIDANCE FOR THYROID NODULES

Sonographic pattern	*US features*	*Estimated risk of malignancy, %*	*FNA size cutoff (largest dimension)*
High suspicion	Solid hypoechoic nodule or solid hypoechoic component of a partially cystic nodule ***with*** one or more of the following features: irregular margins (infiltrative, microlobulated), microcalcifications, taller than wide shape, rim calcifications with small extrusive soft tissue component, evidence of ETE	>70–90[a]	Recommend FNA at ≥1 cm
Intermediate suspicion	Hypoechoic solid nodule with smooth margins ***without*** microcalcifications, ETE, or taller than wide shape	10–20	Recommend FNA at ≥1 cm
Low suspicion	Isoechoic or hyperechoic solid nodule, or partially cystic nodule with eccentric solid areas, ***without*** microcalcification, irregular margin or ETE, or taller than wide shape.	5–10	Recommend FNA at ≥1.5 cm
Very low suspicion	Spongiform or partially cystic nodules ***without*** any of the sonographic features described in low, intermediate, or high suspicion patterns	<3	Consider FNA at ≥2 cm Observation without FNA is also a reasonable option
Benign	Purely cystic nodules (no solid component)	<1	No biopsy[b]

US-guided FNA is recommended for cervical lymph nodes that are sonographically suspicious for thyroid cancer (see Table 7).
[a]The estimate is derived from high volume centers, the overall risk of malignancy may be lower given the interobserver variability in sonography.
[b]Aspiration of the cyst may be considered for symptomatic or cosmetic drainage.
ETE, extrathyroidal extension.

Downloaded by Memorial Sloan Kettering from www.liebertpub.com at 08/14/19. For personal use only.

solid component and cyst, and the presence of microcalcifications consistently confer a higher risk of malignancy (85–87). Other findings such as lobulated margins or increased vascularity of the solid portion are risk factors that are not as robust (86,87). However, a spongiform appearance of mixed cystic solid nodules is strongly correlated with benignity (66,70,71,88). A spongiform appearance is defined as the aggregation of multiple microcystic components in more than 50% of the volume of the nodule (71). Spongiform and other mixed cystic solid nodules may exhibit bright reflectors on US imaging, caused by colloid crystals or posterior acoustic enhancement of the back wall of a microcystic area. These may be confused with microcalcifications by less proficient sonographers, and a recent meta-analysis confirmed that operator experience is correlated with accurate evaluation of internal calcifications (66). Therefore, because of potential for misclassification, FNA may still be considered for nodules interpreted as spongiform, but with a higher size cutoff. Lastly, pure cysts, although rare (<2% of thyroid lesions), are highly likely to be benign (66,89,90).

Given the nuances in sonographic appearances of different thyroid cancer histologies, as well as the challenges posed by partially cystic nodules, some authors have suggested risk stratification based upon a constellation of sonographic features (89–91). In the absence of sonographically suspicious cervical lymph nodes, features associated with the highest risk for thyroid cancer can be used to triage smaller nodules for fine-needle biopsy, whereas nodules with sonographic appearance suggesting lower risk might be considered for fine-needle biopsy at a larger size as determined by maximal diameter (Figs. 1 and 2, Table 6). The sonographic appearance for the vast majority of thyroid nodules can be generally classified in the following categories of US patterns, which combine several individual sonographic characteristics. Since the interobserver variability in reporting individual characteristics is moderate even within controlled studies (72), the use of patterns exhibiting correlated sonographic features is more robust. Two recent studies have reported substantial interobserver correlation for identification for nodule sonographic patterns (multirater kappa statistics >0.6) (92,93).

High suspicion [malignancy risk >70%–90% (89,90,94)]. High suspicion of malignancy is warranted with a solid hypoechoic nodule or a solid hypoechoic component in a partially cystic nodule with one or more of the following features: irregular margins (specifically defined as infiltrative, microlobulated, or spiculated), microcalcifications, taller than wide shape, disrupted rim calcifications with small extrusive hypoechoic soft tissue component, or evidence of extrathyroidal extension (Fig. 2, Table 6). A nodule demonstrating this US pattern is highly likely to be a PTC. Nodules with the high suspicion pattern and measuring ≥1 cm should undergo diagnostic fine-needle biopsy to refute or confirm malignancy. However, in the absence of evidence of extrathyroidal extension, metastatic cervical lymph nodes, or distant metastases, micropapillary thyroid cancers (<1 cm) often have an indolent course, but this may depend upon patient age (95). Although no distant metastases or deaths occurred in a recent observational series of 1235 Japanese patients with biopsy-proven PTC, tumor growth and new appearance of lymph node metastases occurred more frequently in patients younger than 40 years of age compared with those over age 60 (5.9% vs. 2.2% for size increase; 5.3% vs. 0.4% for new nodal metastases, $p < 0.05$). Thus although a sonographically suspicious subcentimeter thyroid nodule without evidence of extrathyroidal extension or sonographically suspicious lymph nodes may be observed with close sonographic follow-up of the nodule and cervical lymph nodes, rather than pursuing immediate FNA, patient age and preference may modify decision-making (95).

Intermediate suspicion [malignancy risk 10%–20% (89,90,94)]. Intermediate suspicion of malignancy is attached to a hypoechoic solid nodule with a smooth regular margin, but without microcalcifications, extrathyroidal extension, or taller than wide shape (Fig. 2, Table 6). This appearance has the highest sensitivity (60%–80%) for PTC, but a lower specificity than the preceding high suspicion pattern, and fine-needle biopsy should be considered for these nodules ≥1 cm to refute malignancy.

Low suspicion [malignancy risk 5%–10% (89,90,94)]. Isoechoic or hyperechoic solid nodule, or partially cystic nodule with eccentric uniformly solid areas without microcalcifications, irregular margin or extrathyroidal extension, or taller than wide shape prompts low suspicion for malignancy (Fig. 2, Table 6). Only about 15%–20% of thyroid cancers are iso- or hyperechoic on US, and these are generally the follicular variant of PTC or FTCs (71). Fewer than 20% of these nodules are partially cystic. Therefore, these appearances are associated with a lower probability of malignancy and observation may be warranted until the size is ≥1.5 cm.

Very low suspicion [≤3% (66,89,90,94)]. Spongiform or partially cystic nodules without any of the sonographic features described in the low, intermediate, or high suspicion patterns have a low risk of malignancy (<3%). If FNA is performed, the nodule should be at least 2 cm. Observation without FNA may also be considered for nodules ≥2 cm (Fig. 2, Table 6).

Benign [≤1% (89,90,94)]. Purely cystic nodules are very unlikely to be malignant, and fine-needle biopsy is not indicated for diagnostic purposes (Fig. 2, Table 6). Aspiration with or without ethanol ablation may be considered as a therapeutic intervention if a cyst is large and symptomatic; cytology should be performed if aspiration is done.

Sonographic evaluation of the anterior cervical lymph node compartments (central and lateral) should be performed whenever thyroid nodules are detected. If US detects cervical lymph nodes that are sonographically suspicious for thyroid cancer (Table 7), FNA of the suspicious lymph node should be performed for cytology and washout for Tg measurement if indicated. In addition, this scenario also warrants US-guided FNA of a subcentimeter nodule that is likely to represent the primary tumor based upon sonographic features.

Although there are several known clinical risk factors for thyroid cancer in patients with thyroid nodules including immobility with swallowing, pain, cough, voice change, growth, lymphadenopathy, and a history of childhood radiation therapy (either therapeutic, such as cranial radiation in childhood leukemia, or for benign conditions, such as enlarged thymus or tonsils) or familial thyroid cancer (96), these have not been incrementally included in multivariate analyses of gray-scale sonographic features and thyroid

Downloaded by Memorial Sloan Kettering from www.liebertpub.com at 08/14/19. For personal use only.

Table 7. Ultrasound Features of Lymph Nodes Predictive of Malignant Involvement[a]

Sign	*Reported sensitivity, %*	*Reported specificity, %*
Microcalcifications	5–69	93–100
Cystic aspect	10–34	91–100
Peripheral vascularity	40–86	57–93
Hyperechogenicity	30–87	43–95
Round shape	37	70

[a]Adapted with permission from the European Thyroid Association guidelines for cervical ultrasound (20).

cancer risk. However, given the higher pretest likelihood of thyroid cancer associated with these clinical risk factors, FNA can be considered at lower size cutoffs for all of the sonographic appearances described above.

Ultrasound elastography (USE) has similarly been investigated for its ability to modify thyroid cancer risk assessment among clinically relevant thyroid nodules. Elastography is a measurement of tissue stiffness. Performance requires an US machine, as well as an elastography computational module that most often must be purchased separately. An initial prospective study of 92 selected, nonrandomized patients suggested positive and negative predictive values (NPVs) near 100% (97). However, more recently, larger trials have reported substantially different results. Moon and colleagues retrospectively studied 703 thyroid nodules in comparison to gray-scale US (78). Performance of USE was inferior to that of gray-scale US assessment. The largest prospective study of 706 patients with 912 thyroid nodules was recently published by Azizi *et al.* (98). In this study, the positive predictive value (PPV) of USE was only 36%, comparable to that of microcalcifications. The NPV of USE was 97% in a population with cancer prevalence of 9%. Thus, while USE holds promise as a means by which to noninvasively assess cancer risk, its performance is highly variable and operator dependent. Perhaps most importantly, USE can only be effectively applied to solid nodules, thus excluding its utility for cystic or partially cystic nodules. Furthermore, to be amenable to direct pressure and determination of tissue strain, the index nodule must not overlap with other nodules in the anterioposterior plane. Obese patients, those with multinodular goiters and coalescent nodules, or patients in whom the nodule is posterior or inferior are not candidates for USE. Thus, at present, USE cannot be widely applied to all thyroid nodules in a similar fashion to gray-scale or Doppler US examination. The committee therefore believes USE (when available) may prove to be a helpful tool for preoperative risk assessment in those patients in whom accurate assessment can be performed. However, the committee cannot presently recommend its universal use or widespread adoption. Importantly, the ability to perform (or not perform) USE should not modify the recommendation for traditional gray-scale sonographic evaluation.

Finally, while most thyroid nodules meeting the preceding sonographic patterns and sizes should undergo FNA, we acknowledge that a conservative approach of active surveillance management may be appropriate as an alternative to FNA in selected patients. These may include patients with very low-risk tumors (e.g., no clinical or radiographic evidence of invasion or metastases), patients at high surgical risk, or those with a relatively short life span expectancy in whom the benefits of intervention may be unrealized.

[A11] What is the role of FNA, cytology interpretation, and molecular testing in patients with thyroid nodules?

■ **RECOMMENDATION 9**

Thyroid nodule FNA cytology should be reported using diagnostic groups outlined in the Bethesda System for Reporting Thyroid Cytopathology.

(Strong recommendation, Moderate-quality evidence)

To address a significant variability in the reporting of cytological findings in thyroid FNA samples, the 2007 National Cancer Institute Thyroid Fine-Needle Aspiration State of the Science Conference provided consensus recommendations known as the Bethesda System for Reporting Thyroid Cytopathology (99,100). The Bethesda system recognizes six diagnostic categories and provides an estimation of cancer risk within each category based upon literature review and expert

Table 8. The Bethesda System for Reporting Thyroid Cytopathology: Diagnostic Categories and Risk of Malignancy[a]

Diagnostic category	*Estimated/predicted risk of malignancy by the Bethesda system, %*[a]	*Actual risk of malignancy in nodules surgically excised, % median (range)*[b]
Nondiagnostic or unsatisfactory	1–4	20 (9–32)
Benign	0–3	2.5 (1–10)
Atypia of undetermined significance or follicular lesion of undetermined significance	5–15	14 (6–48)
Follicular neoplasm or suspicious for a follicular neoplasm	15–30	25 (14–34)
Suspicious for malignancy	60–75	70 (53–97)
Malignant	97–99	99 (94–100)

[a]As reported in The Bethesda System by Cibas and Ali (1076).
[b]Based on the meta-analysis of eight studies reported by Bongiovanni *et al.* (103). The risk was calculated based on the portion of nodules in each diagnostic category that underwent surgical excision and likely is not representative of the entire population, particularly of nondiagnostic and benign diagnostic categories.

Downloaded by Memorial Sloan Kettering from www.liebertpub.com at 08/14/19. For personal use only.

Downloaded by Memorial Sloan Kettering from www.liebertpub.com at 08/14/19. For personal use only.

opinion (Fig. 1, Table 8). These categories are (i) nondiagnostic/unsatisfactory; (ii) benign; (iii) atypia of undetermined significance/follicular lesion of undetermined significance (AUS/FLUS); (iv) follicular neoplasm/suspicious for follicular neoplasm (FN/SFN), a category that also encompasses the diagnosis of Hürthle cell neoplasm/suspicious for Hürthle cell neoplasm; (v) suspicious for malignancy (SUSP), and (vi) malignant. Recent studies that applied the criteria and terminology of the Bethesda System to a large series of patients have shown a relatively good concordance in reporting FNA cytology, with 89%–95% of samples being satisfactory for interpretation and 55%–74% reported as definitively benign and 2%–5% as definitively malignant (101–104). The remaining samples are cytologically indeterminate, including AUS/FLUS in 2%–18% of nodules, FN in 2%–25%, and SUSP in 1%–6%. In these studies, the probability of malignancy for each Bethesda category demonstrated significant variability, but was overall compatible with the range predicted by the Bethesda System, with the exception of the AUS/FLUS diagnosis, for which the risk of malignant outcome in some studies was significantly higher than predicted (Table 8) (103,105). Recently, a blinded prospective evaluation of inter-observer concordance using Bethesda classification was performed. These data confirm an inherent limitation to the reproducibility of interpreting any cytology specimen (106). Specimens diagnosed as AUS/FLUS and SUSP were associated with the highest discordance rates. Some studies suggest that the AUS/FLUS category should be further subdivided into AUS with cytologic atypia (higher risk for malignancy) and FLUS with architectural atypia (lower risk for malignancy), but this has not yet been widely adopted (107). Nonetheless, classification using the Bethesda system has proven highly beneficial, allowing practitioners to speak with the same terminology and better convey malignant risk. The risk of malignancy in each of the six diagnostic categories should be independently defined at each cytology center or institution to guide clinicians on risk estimates and help choose appropriate molecular testing for patients with indeterminate cytology.

[A12] Nondiagnostic cytology

■ **RECOMMENDATION 10**

(A) For a nodule with an initial nondiagnostic cytology result, FNA should be repeated with US guidance and, if available, on-site cytologic evaluation

(Strong recommendation, Moderate-quality evidence)

(B) Repeatedly nondiagnostic nodules without a high suspicion sonographic pattern require close observation or surgical excision for histopathologic diagnosis

(Weak recommendation, Low-quality evidence)

(C) Surgery should be considered for histopathologic diagnosis if the cytologically nondiagnostic nodule has a high suspicion sonographic pattern, growth of the nodule (>20% in two dimensions) is detected during US surveillance, or clinical risk factors for malignancy are present

(Weak recommendation, Low-quality evidence)

Nondiagnostic or unsatisfactory FNA biopsies are those that fail to meet the established quantitative or qualitative criteria for cytologic adequacy (i.e., the presence of at least six groups of well-visualized follicular cells, each group containing at least 10 well-preserved epithelial cells, preferably on a single slide) (99,108). Although an FNA specimen found to have abundant colloid and few epithelial cells may be considered nondiagnostic by the above criteria, this is also likely a benign biopsy. After an initial nondiagnostic cytology result, repeat FNA with US guidance and, if available, on-site cytologic evaluation, will substantially increase the rate of specimen adequacy (109–113). It has been suggested that repeat FNA should be performed no sooner than 3 months after the initial FNA to prevent false-positive interpretation due to biopsy-induced reactive/reparative changes (114). Two recent studies have questioned the necessity for a 3-month waiting period after the first FNA because they did not find a correlation between the diagnostic yield/accuracy of repeated FNA and the waiting time between the procedures (115,116). A 3-month waiting period after a nondiagnostic biopsy is likely not necessary. If clinical and US features are suspicious for malignancy, a shorter waiting period may be appropriate. Repeat FNA with US guidance will yield a diagnostic cytology specimen in 60%–80% of nodules, particularly when the cystic component is <50% (64,112,117). Nodules with larger cystic portion have a higher chance to yield nondiagnostic samples on the initial and repeated FNA.

Most nodules with a nondiagnostic cytology interpretation are benign. In large series of patients classified based on the Bethesda System, nondiagnostic samples constituted 2%–16% of all FNA samples, of which 7%–26% were eventually resected (101–103). The frequency of malignancy among all initially nondiagnostic samples was 2%–4% and among those nondiagnostic samples that were eventually resected was 9%–32%.

Sonographic features are also useful for identifying which nodules with repeat nondiagnostic FNA cytology results are more likely to be malignant. Of 104 nodules with two nondiagnostic cytology results, thyroid cancer was found in 25% of those with microcalcifications, irregular margins, a taller than wide shape, or hypoechogenicity, but in only 4% lacking these features (118).

In some studies, the use of thyroid core-needle biopsy (119) and molecular testing for *BRAF* (120,121) or a panel of mutations (122) helped to facilitate appropriate management of these patients, although the full clinical impact of these approaches for nodules with nondiagnostic cytology remains unknown. Some studies have found that core biopsy offers a higher adequacy rate, but may be less sensitive for the detection of papillary cancer (123,124). Mutational testing may be informative in samples considered inadequate by qualitative criteria (i.e., due to poor preparation or poor staining of cells) but is unlikely to be contributory in samples with insufficient quantity of cells.

[A13] Benign cytology

■ **RECOMMENDATION 11**

If the nodule is benign on cytology, further immediate diagnostic studies or treatment are not required

(Strong recommendation, High-quality evidence)

Accurate FNA cytology diagnosis depends upon a number of factors including the skill of the operator, FNA technique, specimen preparation, and cytology interpretation.

Ultrasound-guided FNA with real-time visualization of needle placement in the target nodule decreases the false-negative rate of a benign cytology diagnosis (68,69,126,128). Although prospective studies are lacking, malignancy rates of only 1%–2% have been reported in large retrospective series that analyzed the utility of systematic repeat FNA in nodules with prior benign cytology results (129–133). A pooled analysis of 12 studies by Tee *et al.* (134) showed that of 4055 patients with benign cytology who underwent surgery, the rate of malignancy was 3.2%.

Studies have also attempted to correlate nodule size with accuracy of FNA cytology. Several surgical series have reported higher malignancy rates in nodules >3–4 cm, but these suffer from both selection bias (only a subset of patients underwent preoperative FNA) and potential sampling error (FNA performed by palpation) (135,136). A recent study evaluated the accuracy of FNA and US features in patients with thyroid nodules ≥4 cm (137). This was a single-center study in which the practice is to offer thyroidectomy or lobectomy to all patients with nodules ≥4 cm. The investigators identified thyroid cancer in 22% of 382 nodules. A subset of thyroid nodules underwent preoperative FNA, and of the 125 cytologically benign nodules, 10.4% were malignant on final histopathology. The investigators further showed that individual US characteristics were not predictive for malignancy, although they did not look at sonographic patterns. Two other recent reports of consecutive US-guided FNA evaluations in over 1400 nodules >3 cm with initial benign cytology followed for a mean of 3 years confirmed a lower false-negative rate of <1.5% (138,139). Interestingly, in both these studies 66% of the missed cancers were found in nodules with high suspicion sonographic pattern, despite initial benign cytology. A recent retrospective study analyzed the long-term follow-up of 2010 cytologically benign nodules from 1369 patients. Over a mean follow-up of 8.5 years 18 false-negative malignancies were detected. However, no deaths attributable to thyroid cancer were identified in this cohort. These data confirm that an initially benign FNA confers negligible mortality risk during long-term follow-up despite a low but real risk of false negatives in this cytologic category (140). Based on the evidence, it is still unclear if patients with thyroid nodules ≥4 cm and benign cytology carry a higher risk of malignancy and should be managed differently than those with smaller nodules.

Follow-up for patients with benign cytology is discussed in section [A24] and Recommendation 23.

[A14] Malignant cytology

■ **RECOMMENDATION 12**

If a cytology result is diagnostic for primary thyroid malignancy, surgery is generally recommended.

(Strong recommendation, Moderate-quality evidence)

A cytology diagnostic for a primary thyroid malignancy will almost always lead to thyroid surgery. However, an active surveillance management approach can be considered as an alternative to immediate surgery in

(A) patients with very low risk tumors (e.g., papillary microcarcinomas without clinically evident metastases or local invasion, and no convincing cytologic evidence of aggressive disease),
(B) patients at high surgical risk because of comorbid conditions,
(C) patients expected to have a relatively short remaining life span (e.g., serious cardiopulmonary disease, other malignancies, very advanced age), or
(D) patients with concurrent medical or surgical issues that need to be addressed prior to thyroid surgery.

Following thyroid surgery for papillary thyroid microcarcinoma (PTMC), defined as a tumor 1 cm or less in size, disease-specific mortality rates have been reported to be <1%, loco-regional recurrence rates are 2%–6%, and distant recurrence rates are 1%–2% (141,142). It is quite likely that these excellent outcomes are more related to the indolent nature of the disease rather than to the effectiveness of treatment, since two prospective clinical studies of active surveillance from Japan reported similar clinical outcomes in 1465 patients with biopsy-proven PTMC that were not surgically removed and were followed for up to 15 years (average 5–6 years, range 1–17 years) (95,143). In the study by Ito *et al.* (95), observation was offered to 1235 patients with PTMC that did not have (i) location adjacent to the trachea or on the dorsal surface of the lobe close to the recurrent laryngeal nerve, (ii) FNA findings suggestive of high-grade malignancy; (iii) presence of regional lymph node metastases; or (iv) signs of progression during follow-up. Of those, most patients showed stable tumor size on average follow-up of 60 months (range 18–227 months), whereas 5% showed tumor enlargement (>3 mm) by US on 5-year follow-up, and 8% on 10-year follow-up. Furthermore, 1.7% and 3.8% of patients at 5-year and 10-year follow-up showed evidence for lymph node metastases. Of 1235 patients, 191 underwent surgical treatment after observation, including those with tumor enlargement and new lymph node metastases. These patients have been followed an average of 75 months (range 1–246 months) after the surgical intervention. Only one of the patients treated with surgery after observation developed tumor recurrence. In the study by Sugitani *et al.* (143), 230 patients with asymptomatic PTMC were followed for 5 years on average. Of those patients, tumor size enlargement was observed in 7%, and 1% developed apparent lymph node metastasis. Seven percent of patients underwent surgery after 1–12 years of follow-up, and no recurrences were identified in those on limited follow-up, suggesting that the delayed surgery did not affect the outcome. A more recent study by Ito and colleagues followed 1235 patients with PTMC under active surveillance for an average of 60 months (95). Only 43 patients (3.5%) had clinical progression of disease by their stated criteria (tumor growing to >12 mm or appearance of new lymph node metastases). Interestingly, the younger patients (<40 years old) had an 8.9% rate of clinical progression, while those 40–60 years old had a 3.5% rate of progression and those >60 years old had the lowest rate of clinical progression (1.6%).

Despite the evidence that cautious observation is a safe and effective alternative to immediate surgical resection, very few PTMC patients outside of those two centers in Japan are given the option of an active surveillance approach. This is in part due to reports in the literature of a small percentage of patients with PTMC presenting with clinically significant regional or distant metastases (141,142,144). Unfortunately, no clinical features (145–151) can reliably differentiate the relatively small number

Downloaded by Memorial Sloan Kettering from www.liebertpub.com at 08/14/19. For personal use only.

of PTMC patients destined to develop clinically significant progression from the larger population of people that harbor indolent PTMCs that will not cause significant disease.

Similarly, well-known thyroid cancer oncogenes, such as *BRAF*, when taken in isolation, are not able to specifically identify the microcarcinomas that will progress and spread outside of the thyroid. The prevalence of $BRAF^{V600E}$ mutations in PTMC with lymph node metastases and tumor recurrence is higher than PTMC without LN metastases or recurrence, and in some studies the presence of a *BRAF* mutation was associated with lymph node metastasis from PTMC on multivariate analysis (150,152,153). These studies showed that although the presence of a $BRAF^{V600E}$ mutation identifies 65%–77% of patients with PTMC that develop lymph node metastases, the *BRAF* status taken in isolation has a low PPV for detecting PTMC with extrathyroidal spread and therefore has a limited role for guiding patient management. However, recent data suggest that specific molecular profiles, such as the coexistence of *BRAF* with other oncogenic mutations (such as *PIK3CA*, *AKT1*), *TERT* promoter, or *TP53* mutations may serve as more specific markers of less favorable outcome of PTC. Therefore, it is likely that finding of one of these genetic profiles in a small tumor would suggest that it represents an early stage of a clinically relevant PTC (154–157). Future studies are expected to establish the impact of molecular profiling involving multiple mutations or other genetic alterations on clinical management of patients with PTMC.

*[A15] Indeterminate cytology (AUS/FLUS, FN, SUSP)**

[A16] What are the principles of the molecular testing of FNA samples?

Molecular markers may be classified according to intended use; that is, diagnostic (classification of a disease state), prognostic, or predictive purposes (providing information on the estimated probability of therapeutic benefit or harm of a specific therapy) (158). Furthermore, companion use of predictive molecular markers involves the identification of patient subgroups in which a therapeutic intervention is proven to be either beneficial or harmful, with intended implications for appropriate clinical stratification of therapies (158). Validation studies of molecular marker tests may include examination of (a) analytic validity (including test accuracy and reproducibility in ascertaining the molecular event), (b) clinical validity (the performance of the test in distinguishing different groups of patients, based on biology or expected disease outcome, including measures of sensitivity and specificity or predictive values), and (c) clinical utility (examination of the test's ability to improve outcomes, with direct clinical decision-making implications) (158). Furthermore, an NCCN Tumor Marker Task Force has indicated that the clinical utility of a molecular test should be founded in strong evidence proving that use of the marker ''improves patient outcomes sufficiently to justify its incorporation into routine clinical practice.''†

The principal proposed use of molecular markers in indeterminate thyroid FNA specimens is diagnostic (ruling out or in the presence of thyroid malignancy), with the implication of a companion use to inform decision-making on primary surgical treatment (i.e., the decision to perform surgery and if so, the extent of surgery). However, the focus of this section is restricted to the clinical validity of molecular testing of indeterminate FNA specimens. It is important to note that long-term outcome data on companion use of molecular marker status to guide therapeutic decision-making is currently lacking, and therefore we do not know if implementation of molecular marker use in routine clinical practice would result in a significant overall benefit in health outcomes in patients with thyroid nodules. Surgical decision-making on indeterminate FNA specimens is reviewed in another section of these guidelines, with some reference to molecular marker testing (if performed). As summarized in a Disease State Commentary from the AACE Thyroid Scientific Committee and a consensus statement from the ATA Surgical Affairs Committee, use of molecular marker testing on indeterminate FNA specimens should not be intended to replace other sources of information or clinical judgment (159,160). The pretest probability of malignancy (based on clinical risk factors, cytology, US findings), feasibility considerations, and patient preferences are some additional factors that need to be considered in decision-making related to molecular marker testing of FNA specimens. Because this is a rapidly evolving field of investigation, it will be important to perform interval evaluations of the published evidence to ensure that recommendations remain contemporary.

A number of molecular approaches have been studied in the clinical setting of indeterminate FNA cytologic interpretation (161). One could surmise that an ideal ''rule-in'' test would have a PPV for histopathologically proven malignancy similar to a malignant cytologic diagnosis (98.6%), and an ideal ''rule-out'' test would have a NPV similar to a benign cytologic diagnosis (96.3%) (predictive value estimates based on a recent meta-analysis of performance of the Bethesda system) (103), and these would hold true with a reasonable degree of precision and reproducibility.

■ **RECOMMENDATION 13**

If molecular testing is being considered, patients should be counseled regarding the potential benefits and limitations of testing and about the possible uncertainties in the therapeutic and long-term clinical implications of results.

(Strong recommendation, Low-quality evidence)

The largest studies of preoperative molecular markers in patients with indeterminate FNA cytology have respectively evaluated a seven-gene panel of genetic mutations and rearrangements (*BRAF*, *RAS*, *RET/PTC*, *PAX8/PPARγ*) (162), a gene expression classifier (167 GEC; mRNA expression of 167 genes) (163), and galectin-3 immunohistochemistry (cell blocks) (164). These respective studies have been subject to various degrees of blinding of outcome assessment (162–164).

Mutational testing has been proposed for use as a rule-in test because of relatively high reported specificity (86%–100%)

*The final draft for the sections (A15–A19) and recommendations (13–17) were revised and approved by a subgroup of seven members of the task force with no perceived conflicts or competing interests in this area.

†From the NCCN Biomarkers Compendium (www.nccn.org/professionals/biomarkers/default.aspx).

Downloaded by Memorial Sloan Kettering from www.liebertpub.com at 08/14/19. For personal use only.

and PPV (84%–100%) (105,122,162,165–168). Although *BRAF*^{V600E} single mutation testing has been estimated to have a specificity of approximately 99% (pooled data from 1117 nodules with histopathologic confirmation from multiple studies), the sensitivity has been deemed to be too low to reliably rule out the presence of malignancy (169). Therefore, mutational panels have been expanded to include multiple mutations/translocations including *BRAF*, *NRAS*, *HRAS*, and *KRAS* point mutations, as well as *RET/PTC1* and *RET/PTC3*, with or without *PAX8/PPARγ* rearrangements (105,122,162, 165–168) and other gene rearrangements (170). In indeterminate cytology thyroid nodules, the sensitivity of the seven-gene mutational panel testing is variable, with reports ranging from 44% to 100% (162,165,167). The reported variability in sensitivity of mutational analysis with the seven-gene panel in indeterminate nodules suggests that traditional limited mutation panels may not reliably rule out malignancy with a negative test in this population. Next-generation sequencing of an expanded panel of point mutations, single base insertions/deletions (indels), and gene rearrangements has been reported to have a sensitivity of 90% for FN/SFN FNA cytology specimens from a single-center study (170). A limitation was that the pathologists evaluating the gold standard surgical pathology specimens were aware of the results of earlier generation molecular tests previously conducted on the FNAs (170). It is not known to what extent differences in techniques used to perform mutational testing by various groups (162,167,170) may affect test performance, and direct, head-to-head comparisons of these tests within the same population are lacking. The currently available seven-gene mutational panels have been proposed to be most useful when surgery is favored. However, this is based on the assumption that the surgical approach would be altered with a positive test, and long-term outcome data proving the overall benefit of this therapeutic strategy are needed. It is important to acknowledge that algorithms employing seven-gene mutational testing as a means to inform decision-making on extent of primary thyroid surgery (i.e., lobectomy or total thyroidectomy) (162) were developed at a time when the ATA guidelines favored total thyroidectomy for most PTCs >1 cm in diameter (25). However, this does not reflect recommendations in these guidelines (see Recommendation 35 on surgical management of malignant cytology nodules). Furthermore, long-term outcome data from a strategy of using molecular markers in indeterminate FNA specimens to stratify surgical approach are currently lacking.

Use of a 167 GEC has been proposed as a rule-out test due to relatively high sensitivity (92%) and NPV (93%), as reported in a prospective multicenter study (163). The relatively low specificity of the 167 GEC test (mean values 48%–53% in indeterminate nodules subject to histopathologic confirmation) suggests that the test cannot definitively rule-in malignancy in indeterminate nodules. In a retrospective analysis of 167 GEC results from five institutions, Alexander *et al.* (171) reported that the prevalence of 167 GEC benign readings by institution varied up to 29%, which was not statistically significant. The distribution of recruitment from each of the five study sites was highly variable (total $n = 339$ nodules), with two sites contributing only 30 and 37 patients, and the other three sites accounting for the majority of the study population. The prevalence of malignancy confirmed by histopathology in 167 GEC ''suspicious'' nodules ranged from 33% to 80% in the 48 nodules in the AUS/FLUS group across institutions (no 95% confidence interval [95% CI] reported, $p = 0.11$), and from 33% to 67% in the 65 nodules in the FN cytology group (no 95% CI reported, $p = 0.87$) (171). For the 174 patients with 167 GEC ''benign'' readings, four patients were advised to undergo surgery (2%), and 41% (71 patients) of this group had short documented follow-up for a mean of 8.5 months (median 8 months, range 1–24 months); ultimately, 6% of patients in this group (11/174) had surgery, with one histopathologically confirmed malignancy (171). The reproducibility of 167 GEC NPV measures in different populations of patients with indeterminate cytology thyroid nodules has recently been questioned in three smaller, independent, unblinded studies (172–174). None of these studies reported any degree of blinding. Furthermore, 95% CI of predictive estimates in indeterminate cytology nodules were not reported in two single-center studies (172,173), and one multi-center study was reported to be a retrospective analysis (174), making it difficult to interpret the findings. However, such data highlight the need for additional independent research examining the reproducibility of diagnostic efficacy of the 167 GEC in more institutions, and the importance of reporting precision estimates for diagnostic accuracy measures. Furthermore, as in the case of other molecular-based diagnostic tests in the field, long-term outcome data from clinical utility studies are needed to inform potential future clinical practice implications of the 167 GEC.

Immunohistochemical stains such as galectin-3 and HBME-1 have been examined in multiple studies of histologically confirmed thyroid FNA samples with indeterminate cytology, with reports of relatively high rates of specificity, but low sensitivity, for cancer detection (164,175,176). Two of these studies were reported to be prospective (164,175), but only one of the studies reported any degree of blinding (blind central histopathologic review) (164). Immunohistochemical stains require the availability of a cell block to perform the staining. Additional diagnostic molecular marker strategies are also under development. Specifically, mRNA markers (177–179), as well as miRNA markers (180–185), have shown initial diagnostic utility in FNA samples with indeterminate cytological diagnoses, but they have not been thoroughly validated. A recent study combining seven-gene mutational testing with expression of a set of 10 miRNA genes on preoperative FNA sampling from 109 patients with AUS/FLUS or FN cytology, showed 89% sensitivity, 85% specificity, with a 73% PPV and 94% NPV on this group with a 32% prevalence of malignancy (186). Finally, peripheral blood TSH receptor mRNA assay has been reported to have a 90% PPV and 39% NPV in FNA-based assessment of thyroid nodules with atypical or suspicious cytology in a single-center, prospective validation study (187).

In summary, there is currently no single optimal molecular test that can definitively rule in or rule out malignancy in all cases of indeterminate cytology, and long-term outcome data proving clinical utility are needed.

■ RECOMMENDATION 14

If intended for clinical use, molecular testing should be performed in Clinical Laboratory Improvement Amendments/College of American Pathologists (CLIA/CAP)-certified molecular laboratories, or the international equivalent,

Downloaded by Memorial Sloan Kettering from www.liebertpub.com at 08/14/19. For personal use only.

because reported quality assurance practices may be superior compared to other settings.

(Strong recommendation, Low-quality evidence)

Many molecular marker tests are available in hospital-based molecular pathology laboratories and in reference laboratories. Importantly, all molecular marker tests intended for clinical use should be performed only in CLIA/CAP-certified molecular laboratories after appropriate analytical and clinical validation of all assays in each laboratory (158). In a survey of American molecular genetic testing laboratory directors, laboratory process quality assurance score (for multiple relevant domains) was associated with the presence of CLIA certification (188). In a large, international survey of medical genetic testing laboratory directors, accreditation of the laboratory was associated with a higher quality assurance index score (189).

[A17] AUS/FLUS cytology

■ RECOMMENDATION 15

(A) For nodules with AUS/FLUS cytology, after consideration of worrisome clinical and sonographic features, investigations such as repeat FNA or molecular testing may be used to supplement malignancy risk assessment in lieu of proceeding directly with a strategy of either surveillance or diagnostic surgery. Informed patient preference and feasibility should be considered in clinical decision-making.

(Weak recommendation, Moderate-quality evidence)

(B) If repeat FNA cytology, molecular testing, or both are not performed or inconclusive, either surveillance or diagnostic surgical excision may be performed for an AUS/FLUS thyroid nodule, depending on clinical risk factors, sonographic pattern, and patient preference.

(Strong recommendation, Low-quality evidence)

Based on the Bethesda System, this diagnostic category is reserved for specimens that contain cells with architectural and/or nuclear atypia that is more pronounced than expected for benign changes but not sufficient to be placed in one of the higher risk diagnostic categories (99,190). Although this diagnostic category has been recommended for limited use and has an expected frequency in the range of 7%, recent reports based on the Bethesda System have found this cytologic diagnosis to be used in 1%–27% of all thyroid FNA samples (105,191). In studies that utilized the criteria established by the Bethesda System, the risk of cancer for patients with AUS/FLUS nodules who underwent surgery was 6%–48%, with a mean risk of 16% (191).

A second opinion review of the cytopathology slides by a high-volume cytopathologist may be considered for patients with AUS/FLUS cytology. There is some evidence that this approach may reclassify many of these patients into the benign and nondiagnostic categories (106,192). Furthermore, the overall diagnostic accuracy may be improved. Unfortunately, there is a relatively high intra-observer variability in this difficult diagnostic category (106).

A repeat FNA yields a more definitive cytologic diagnosis in many cases, whereas 10%–30% of nodules are repeatedly AUS/FLUS (104,193–195). The rate of malignancy on surgical follow-up has been shown to be similar for patients with a single AUS/FLUS diagnosis (37/90, 41%), two successive AUS/FLUS diagnoses (22/51, 43%), and patients with a benign cytologic interpretation following the initial AUS/FLUS diagnosis (2/7, 29%) (196). Use of thyroid core-needle biopsy was reported by some to be more informative than repeated FNA for sampling nodules that were AUS/FLUS on initial FNA (119), and it is reasonably well-tolerated (197).

The refinement of risk stratification of nodules with AUS/FLUS cytology using molecular testing has been examined in multiple studies. The interpretation of molecular testing is complex, however, and its utility is strongly influenced by the prevalence of cancer in the tested population of nodules. Only two molecular tests have been separately evaluated and validated for the individual AUS/FLUS, FN, and SUSP categories. Mutational testing for *BRAF* in AUS/FLUS samples has high specificity for cancer, but low sensitivity (198,199). Testing for a panel of mutations (*BRAF*, *NRAS*, *HRAS*, *KRAS, RET/PTC1*, *RET/PTC3*, *PAX8/PPARγ*) offers a significantly higher sensitivity of 63%–80% (162,165). In the largest prospective study to date of nodules with AUS/FLUS cytology (653 consecutive nodules, of which 247 had surgical follow-up) from a single institution, detection of any of these mutations using RT-PCR with fluorescent melting curve analysis was reported to convey an 88% risk of cancer among nodules with surgical follow-up; 63% of cancers on final histopathology were identified with a positive mutation preoperatively (22 of 35), and 94% of nodules that were negative on mutation analysis had a benign final histopathology (209 of 222) (162). Positive testing for *BRAF, RET/PTC* or *PAX8/PPARγ* was specific for a malignant outcome in 100% of cases, whereas *RAS* mutations had an 84% risk of cancer and a 16% chance of benign follicular adenoma. A recent study utilizing RT-PCR with liquid bead array flow cytometry with the seven-gene mutation panel reported on 11 AUS/FLUS cytology nodules that had malignant histopathologic confirmation, of which seven had a negative molecular test and four had a positive test (167). There were also 11 AUS/FLUS cytology nodules, which were benign on histopathologic evaluation; 9 of 11 had a negative molecular test result and 2 of 11 had a positive result. Interpretation of results from the AUS/FLUS subgroup is limited by the small reported sample size (167).

Molecular testing using the 167 GEC has been studied for its diagnostic use in nodules with AUS/FLUS cytology. A multi-institutional study of 129 FNA samples with AUS/FLUS cytology and surgical follow-up reported a 90% sensitivity [95% CI 74%–98%] and 95% NPV [95% CI 85%–99%], but only a 53% specificity [95% CI 43%–63%] and 38% PPV [95% CI 27%–50%] for cancer (163). Although the specificity of the 167 GEC was low (53% [95% CI 43%–63%]), the negative test result was reported to decrease the risk estimate of malignancy in AUS/FLUS nodules in this study from 24% to 5%. This observation has led to a clinical extrapolation suggesting that nodules that have a negative 167 GEC test results may be followed without surgery (163). In a recent single-center retrospective study including 68 cases of AUS/FLUS nodules, 16 AUS/FLUS cases were reported to have a 167 GEC suspicious result, and the PPV was 61% (11 of 18) for those with surgical pathology confirmation (200). There were insufficient data to confirm the NPV of the 167 GEC test for AUS/FLUS cytology, since the vast majority of patients with a benign 167 GEC test did not undergo surgery, and no long-term follow-up of such cases was reported

Downloaded by Memorial Sloan Kettering from www.liebertpub.com at 08/14/19. For personal use only.

(200). In three other recent studies, there were insufficient data for analysis in the AUS/FLUS subgroup to draw any meaningful conclusion on 167 GEC test performance in that subgroup (172–174). In addition, published follow-up for the 167 GEC is currently limited to a mean of 8.5 months in a subgroup of 71 patients (171), hence long-term outcome data are needed to ensure durability of benign 167 GEC findings with correlation to clinical and histologic outcomes.

Several recent studies (201–205) have examined the feasibility of using sonographic features to estimate risk of malignancy in nodules with AUS/FLUS cytology. The PPV of suspicious sonographic features has been estimated to range from 60% to 100% depending on the pretest probability of malignancy of AUS/FLUS cytology and the specific sonographic criteria selected in respective studies. A limitation of all of these studies is that a gold-standard surgical excisional diagnosis was not required for confirmation of malignancy and long-term follow-up data were generally lacking. The prevalence of suspicious sonographic features among studies of AUS/FLUS cytology nodules ranged from 18% to 50%, assuming that one or more suspicious features were deemed to be sufficient to be categorized as a sonographically suspicious nodule. The findings of these studies must be interpreted in the context of each study's overall risk of malignancy for this cytology classification because of its effect on the PPVs obtained by subsequent application of sonographic features to cytologically AUS/FLUS nodules. From the four Korean studies (overall malignancy rate 40%–55%), the reported cancer risk in AUS/FLUS nodules with the high suspicion sonographic pattern is 90%–100% (201–204), and the presence of even one suspicious US feature (irregular margins, taller than wide shape, marked hypoechogenicity or microcalcifications) increases the cancer risk to 60%–90%. However, when the reported cancer rate in AUS/FLUS nodules is lower [e.g., 23% in a study from Brazil (205)], the high suspicion sonographic pattern still raises the risk of malignancy, but the PPV is lower at 70%. Nonetheless, the incidence of cancer in AUS/FLUS nodules with either the high suspicion pattern US or just one suspicious US feature is significantly higher than that generally accepted for this cytology category. In a secondary analysis of a retrospective single-center study of indeterminate FNA specimens subject to 167 GEC testing, Lastra *et al.* studied whether reexamining US characteristics could assist in distinguishing malignancy in indeterminate cytology nodules with a 167 GEC suspicious result (200). The presence of ''nodular calcifications'' or hyper- versus hypo-echogenicity did not alter the prediction of malignancy. It is unclear whether this study was adequately powered because the analysis was limited to a subgroup of 48 cases for analysis of microcalcifications and 20 cases for analysis of echogenicity (200). Further research is needed to examine the impact of considering clinical and sonographic features on the potential utility and interpretation of molecular testing of FNA specimens.

[A18] Follicular neoplasm/suspicious for follicular neoplasm cytology

■ RECOMMENDATION 16

(A) Diagnostic surgical excision is the long-established standard of care for the management of FN/SFN cytology nodules. However, after consideration of clinical and sonographic features, molecular testing may be used to supplement malignancy risk assessment data in lieu of proceeding directly with surgery. Informed patient preference and feasibility should be considered in clinical decision-making.

(Weak recommendation, Moderate-quality evidence)

(B) If molecular testing is either not performed or inconclusive, surgical excision may be considered for removal and definitive diagnosis of an FN/SFN thyroid nodule.

(Strong recommendation, Low-quality evidence)

This diagnostic category of the Bethesda System is used for cellular aspirates (i) comprised of follicular cells arranged in an altered architectural pattern characterized by cell crowding and/or microfollicle formation and lacking nuclear features of papillary carcinoma or (ii) comprised almost exclusively of oncocytic (Hürthle) cells (99,206,207). This is an intermediate risk category in the Bethesda System, with a 15%–30% estimated risk of malignancy. Studies that applied the Bethesda System reported the use of this diagnostic category in 1%–25% (mean, 10%) of all thyroid FNA samples, with the risk of cancer on surgery found to range from 14% to 33% (mean, 26%) (191).

The refinement of risk stratification of nodules with FN/SFN/Hürthle cell neoplasm cytology has been examined using ancillary molecular testing. Testing for a seven-gene panel of mutations (including *BRAF*, *RAS*, *RET/PTC*, and/*PPARγ*) in nodules with follicular or Hürthle cell neoplasm or SFN has been reported to be associated with a sensitivity of 57%–75%, specificity of 97%–100%, PPV of 87%–100%, and NPV of 79%–86% (162,165). Many of these benign tumors are follicular adenomas driven by oncogenic *RAS* mutation with uncertain malignant potential (208). Nodules lacking all of these mutations still have a substantial cancer risk, which is due to the presence of a subset of tumors that lack any of the mutations tested by this seven-gene panel (162). Expansion of the current panels to include additional mutations and gene rearrangements with this next-generation sequencing assay was associated with a sensitivity of 90% [95% CI 80%–99%], specificity of 93% [95% CI 88%–98%], PPV of 83% [95% CI 72%–95%], and NPV of 96% [95% CI 92%–100%] in a recent single-center study of 143 consecutive FN/SFN FNA specimens with known surgical outcomes. In this study (170), retrospective ($n = 91$) and prospective data ($n = 52$) were combined. A limitation was that the pathologists reviewing the surgical specimens were aware of earlier generation molecular marker seven-gene panel test results, although they were blinded to results of the next-generation mutation panel (162,170). Given the overlap of some of the markers detected in earlier and later generation assays, there is a potential for bias (170), and the results need to be replicated in other studies.

Molecular testing using the GEC was reported to have a 94% NPV [95% CI 79%–99%], and a 37% PPV [95% CI 23%–52%] in the FN/SFN/Hürthle cell neoplasm Bethesda subgroup (163). A recent unblinded study from the Mayo Clinic utilizing a prospective patient registry reported the following diagnostic accuracy estimates in a subgroup of 31 indeterminate nodules from the same Bethesda subgroup that were subject to histopathologic confirmation: sensitivity 80% (four of five nodules), specificity 12% (3 of 26 nodules), PPV

Downloaded by Memorial Sloan Kettering from www.liebertpub.com at 08/14/19. For personal use only.

15% (4 of 27), and NPV 75% (three of four) (173). In a single-center retrospective study including 64 nodules subjected to 167 GEC testing and a cytology read as FN/FN with oncocytic features, the PPV for a suspicious GEC result was 37% (11 of 30), although the PPV was significantly higher in the FN group (53%) compared with the FN with oncocytic features group (15%) (200). There were insufficient numbers of patients with benign 167 GEC results who underwent surgery to draw conclusions on NPV; moreover, no long-term follow-up data were reported (200). The relatively small number of indeterminate nodules is an important limitation. Furthermore, precision estimates (95% CIs) for the diagnostic accuracy measures were not reported but could be assumed to be relatively wide given the small sample size (173,200).

[A19] Suspicious for malignancy cytology

■ **RECOMMENDATION 17**

(A) If the cytology is reported as suspicious for papillary carcinoma (SUSP), surgical management should be similar to that of malignant cytology, depending on clinical risk factors, sonographic features, patient preference, and possibly results of mutational testing (if performed).

(Strong recommendation, Low-quality evidence)

(B) After consideration of clinical and sonographic features, mutational testing for *BRAF* or the seven-gene mutation marker panel (*BRAF*, *RAS*, *RET/PTC*, *PAX8/PPARγ*) may be considered in nodules with SUSP cytology if such data would be expected to alter surgical decision-making.

(Weak recommendation, Moderate-quality evidence)

This diagnostic category of the Bethesda System is reserved for aspirates with cytologic features that raise a strong suspicion for malignancy (mainly for PTC) but are not sufficient for a conclusive diagnosis (99,209). This is the highest risk category of indeterminate cytology in the Bethesda System, with an estimated cancer risk of 60%–75% (209). Studies that utilize the Bethesda System have reported this cytologic diagnosis in 1%–6% of thyroid FNAs and found malignancy after surgery in 53%–87% (mean, 75%) of these nodules (191). Due to the high risk of cancer, the diagnosis of suspicious for papillary carcinoma is an indication for surgery.

Mutational testing has been proposed to refine risk prior to surgery, assuming that surgical management would change based on a positive test result. *BRAF* mutations have been reported to confer close to 100% probability of malignancy (162,198,210,211). Testing for *BRAF* mutations in nodules suspicious for malignancy has been reported to have a sensitivity of 36% (10 of 28) and specificity of 100% (24 of 24) in a single-center retrospective study (162). In another single center retrospective study in which FNA slides deemed to be suspicious for PTC were tested after surgery, the sensitivity of *BRAF* testing for PTC was 45.5% (15 of 33), and specificity was 85.7% (12 of 14) (212). Testing for a seven-gene panel of mutations (including *BRAF*, *RAS*, *RET/PTC*, with or without *PAX8/PPARγ*) in nodules with cytology suspicious for malignancy is associated with a sensitivity of 50%–68%, specificity of 86%–96%, PPV of 80%–95%, and NPV of 72%–75% in respective single-center studies (162,165,168). Molecular testing using the 167 GEC has a PPV that is similar to cytology alone (76%) and a NPV of 85% (163), and it is therefore not indicated in patients with this cytologic diagnosis.

[A20] What is the utility of ^{18}FDG-PET scanning to predict malignant or benign disease when FNA cytology is indeterminate (AUS/FLUS, FN, SUSP)?

■ **RECOMMENDATION 18**

^{18}FDG-PET imaging is not routinely recommended for the evaluation of thyroid nodules with indeterminate cytology.

(Weak recommendation, Moderate-quality evidence)

Eight studies have been performed and are the subject of two meta-analyses (213–222). While early data suggested a high NPV for ^{18}FDG-PET in this setting, most studies failed to use the Bethesda System for Reporting Thyroid Cytopathology and included numerous small nodules <1 cm in diameter (221). A recent meta-analysis included seven studies, of which five were prospective (222). The cancer prevalence was 26% inclusive of all combined data, confirming a typical study cohort. Sensitivity and specificity of ^{18}FDG-PET were 89% and 55%, respectively, resulting in a 41% PPV and 93% NPV, which is similar to the performance of the 167 GEC. Vriens *et al.* (223) performed a cost-effectiveness analysis using ^{18}FDG-PET performance data from their own meta-analysis and 2012 reimbursement rates of the Dutch system. They showed that ^{18}FDG-PET was more cost effective than surgery, the 167 GEC, or mutational testing. A recent prospective analysis of 56 nodules with indeterminate FNA cytology used both ^{18}FDG-PET and thyroid US to further evaluate the nodules (220). In a multivariate analysis, the authors demonstrated no additional diagnostic benefit or improved risk assessment when adding ^{18}FDG-PET to that already obtained from thyroid US, bringing into question the incremental benefit of PET imaging in patients with cytologically indeterminate thyroid nodules.

[A21] What is the appropriate operation for cytologically indeterminate thyroid nodules?

■ **RECOMMENDATION 19**

When surgery is considered for patients with a solitary, cytologically indeterminate nodule, thyroid lobectomy is the recommended initial surgical approach. This approach may be modified based on clinical or sonographic characteristics, patient preference, and/or molecular testing when performed (see Recommendations 13–16).

(Strong recommendation, Moderate-quality evidence)

■ **RECOMMENDATION 20**

(A) Because of increased risk for malignancy, total thyroidectomy may be preferred in patients with indeterminate nodules that are cytologically suspicious for malignancy, positive for known mutations specific for carcinoma, sonographically suspicious, or large (>4 cm), or in patients with familial thyroid carcinoma or history of radiation exposure, if completion thyroidectomy would be

Downloaded by Memorial Sloan Kettering from www.liebertpub.com at 08/14/19. For personal use only.

recommended based on the indeterminate nodule being malignant following lobectomy.

(Strong recommendation, Moderate-quality evidence)

(B) Patients with indeterminate nodules who have bilateral nodular disease, those with significant medical comorbidities, or those who prefer to undergo bilateral thyroidectomy to avoid the possibility of requiring a future surgery on the contralateral lobe, may undergo total or near-total thyroidectomy, assuming completion thyroidectomy would be recommended if the indeterminate nodule proved malignant following lobectomy.

(Weak recommendation, Low-quality evidence)

The primary goal of thyroid surgery for a thyroid nodule that is cytologically indeterminate (AUS/FLUS or FN or SUSP) is to establish a histological diagnosis and definitive removal, while reducing the risks associated with remedial surgery in the previously operated field if the nodule proves to be malignant. Surgical options to address the nodule should be limited to lobectomy (hemithyroidectomy) with or without isthmusectomy, near-total thyroidectomy (removal of all grossly visible thyroid tissue, leaving only a small amount [<1 g] of tissue adjacent to the recurrent laryngeal nerve near the ligament of Berry), or total thyroidectomy (removal of all grossly visible thyroid tissue). Removal of the nodule alone, partial lobectomy, and subtotal thyroidectomy, leaving >1 g of tissue with the posterior capsule on the uninvolved side, are inappropriate operations for possible thyroid cancer (224).

Decisions regarding the extent of surgery for indeterminate thyroid nodules are influenced by several factors (225), including the estimated presurgical likelihood of malignancy based upon clinical risk factors (>4 cm, family history, and/or history of radiation) (226–229), sonographic pattern (Table 6, Fig. 2) (202–203), cytologic category (Table 8), and ancillary test findings (see molecular testing section [A15–19]). These risk factors, as well as patient preference, presence of contralateral nodularity or coexistent hyperthyroidism, and medical comorbidities, impact decisions regarding thyroid lobectomy with the possible need for subsequent completion thyroidectomy versus total thyroidectomy up front.

Nodules that are cytologically classified as AUS/FLUS or FN and benign using the 167 GEC, or AUS/FLUS and negative using the seven-gene mutation panel have an estimated 5%–6% risk of malignancy (162,163). Nodules that are cytologically classified as FN and negative using the seven-gene mutation panel have an estimated 14% risk of malignancy, which is slightly lower than the risk based upon the Bethesda classification alone (162).

Nodules that are cytologically classified as AUS/FLUS or FN and as suspicious using the 167 GEC have an estimated 37%–44% risk of malignancy, which is slightly higher than the risk based upon the Bethesda classification alone (Table 8) (163,171).

Nodules that are cytologically classified as SUSP cytology and benign using the 167 GEC or negative using the mutation seven-gene panel, also have an estimated 15%–28% risk of malignancy.

In contrast, nodules that are cytologically classified as AUS/FLUS or FN and that are positive for known *RAS* mutations associated with thyroid carcinoma have an estimated 84% risk of malignancy and should be considered in a similar risk category to cytologically suspicious for malignancy (Table 8) (103,230). Nodules that are cytologically classified as AUS/FLUS or FN or SUSP and that are positive for known $BRAF^{V600E}$, *RET/PTC*, or *PAX8/PPARγ* mutations have an estimated risk of malignancy of >95% and should be considered in a similar category to cytologically diagnosed thyroid carcinoma (198,210,211).

Sonographic pattern of nodules with AUS/FLUS cytology may aid in risk stratification and management. In one study, sonographically benign or seemingly very low risk nodules with AUS/FLUS cytology were noted to be malignant in only 8% of cases, compared to 58% when sonographic suspicious was low or intermediate, and 100% when sonographic suspicion of malignancy was high (203). Another study supported this finding with sonographic findings highly suspicious for malignancy (taller than wide shape, irregular borders, and/or marked hypoechogenicity) having >90% specificity and PPV for malignancy (202).

The risks of total thyroidectomy are significantly greater than that for thyroid lobectomy, with a recent meta-analysis suggesting a pooled relative risk (RR) significantly greater for all complications, including recurrent laryngeal nerve injury (transient RR = 1.7, permanent RR = 1.9), hypocalcemia (transient RR = 10.7, permanent RR = 3.2), and hemorrhage/hematoma (RR = 2.6) (231). Further, total thyroidectomy is associated with the rare but potential risk of bilateral recurrent laryngeal nerve injury necessitating tracheostomy. Surgeon experience likely influences the risks of thyroidectomy, with higher volume surgeons having lower complication rates (232,233).

Total thyroidectomy necessitates thyroid hormone replacement, while lobectomy is associated with an incidence of postoperative biochemical hypothyroidism estimated at 22%, with clinical or overt hypothyroidism estimated at 4% (234). A significantly increased risk of hypothyroidism following lobectomy has been reported in the presence of autoimmune thyroid disease (e.g., as reflected by the presence of thyroid antibodies) or high normal/elevated TSH (231,234). Hypothyroidism is not an indication for thyroidectomy, and its use as justification for total thyroidectomy over lobectomy should be weighed against the higher risks associated with total thyroidectomy. In contrast, coexistent hyperthyroidism may be an indication for total thyroidectomy depending upon the etiology.

Thyroid lobectomy (hemithyroidectomy) provides definitive histological diagnosis and complete tumor removal for cytologically indeterminate nodules with a lower risk of complications compared to total thyroidectomy and may be sufficient for smaller, solitary intrathyroidal nodules that ultimately prove malignant. As the likelihood of malignancy increases, the potential need for a second operation also increases, if the cytologically indeterminate nodule ultimately proves malignant and if completion thyroidectomy would be recommended. Intraoperative evaluation, with or without frozen section, can occasionally confirm malignancy at the time of lobectomy allowing for conversion to total thyroidectomy if indicated. Frozen section is most helpful if the histopathologic diagnosis is classic PTC, whereas its impact is low in follicular variant of PTC and FTC. The individual patient must weigh the relative advantages and disadvantages of thyroid lobectomy with possible total thyroidectomy or

Downloaded by Memorial Sloan Kettering from www.liebertpub.com at 08/14/19. For personal use only.

subsequent completion thyroidectomy versus initial total thyroidectomy.

[A22] How should multinodular thyroid glands (i.e., two or more clinically relevant nodules) be evaluated for malignancy?

■ **RECOMMENDATION 21**

(A) Patients with multiple thyroid nodules ≥1 cm should be evaluated in the same fashion as patients with a solitary nodule ≥1 cm, excepting that each nodule that is >1 cm carries an independent risk of malignancy and therefore multiple nodules may require FNA.

(Strong recommendation, Moderate-quality evidence)

(B) When multiple nodules ≥1 cm are present, FNA should be performed preferentially based upon nodule sonographic pattern and respective size cutoff (Table 6, Fig. 2).

(Strong recommendation, Moderate-quality evidence)

(C) If none of the nodules has a high or moderate suspicion sonographic pattern, and multiple sonographically similar very low or low suspicion pattern nodules coalesce with no intervening normal parenchyma, the likelihood of malignancy is low and it is reasonable to aspirate the largest nodules (≥2 cm) or continue surveillance without FNA.

(Weak recommendation, Low-quality evidence)

■ **RECOMMENDATION 22**

A low or low-normal serum TSH concentration in patients with multiple nodules may suggest that some nodule(s) may be autonomous. In such cases, a radionuclide (preferably ^{123}I) thyroid scan should be considered and directly compared to the US images to determine functionality of each nodule ≥1 cm. FNA should then be considered only for those isofunctioning or nonfunctioning nodules, among which those with high suspicion sonographic pattern should be aspirated preferentially.

(Weak recommendation, Low-quality evidence)

Patients with multiple thyroid nodules have the same risk of malignancy as those with solitary nodules (32,74). However, when evaluating the risk of cancer per individual nodule, one large study found that a solitary nodule had a higher likelihood of malignancy than did a nonsolitary nodule ($p < 0.01$), although in agreement with the other studies the risk of malignancy per patient was the same and independent of the number of nodules (77). A recent systematic review and meta-analysis confirmed the slightly higher risk of malignancy in a solitary nodule compared with an individual nodule in a MNG. However, this appeared to hold true mostly outside of the United States and in iodine-deficient populations (235). A diagnostic US should be performed to evaluate the sonographic risk pattern of each nodule, but if only the ''dominant'' or largest nodule is aspirated, the thyroid cancer may be missed (74). Therefore, multiple thyroid nodules ≥1 cm may require aspiration, based on sonographic pattern (Recommendation 8, Table 6, Fig. 2) to fully exclude clinically relevant thyroid cancer. Radionuclide scanning may also be considered in patients with multiple thyroid nodules with the goal of identifying and aspirating appropriate hypofunctioning nodules. Such imaging may prove especially useful when the serum TSH is below or in the low-normal range. Similarly, sonographic risk assessment of each nodule can assist in identifying those nodules with the highest likelihood of cancer (see section [A10]).

[A23] What are the best methods for long-term follow-up of patients with thyroid nodules?

[A24] Recommendations for initial follow-up of nodules with benign FNA cytology

■ **RECOMMENDATION 23**

Given the low false-negative rate of US-guided FNA cytology and the higher yield of missed malignancies based upon nodule sonographic pattern rather than growth, the follow-up of thyroid nodules with benign cytology diagnoses should be determined by risk stratification based upon US pattern.

(A) Nodules with high suspicion US pattern: repeat US and US-guided FNA within 12 months.

(Strong recommendation, Moderate-quality evidence)

(B) Nodules with low to intermediate suspicion US pattern: repeat US at 12–24 months. If sonographic evidence of growth (20% increase in at least two nodule dimensions with a minimal increase of 2 mm or more than a 50% change in volume) or development of new suspicious sonographic features, the FNA could be repeated or observation continued with repeat US, with repeat FNA in case of continued growth.

(Weak recommendation, Low-quality evidence)

(C) Nodules with very low suspicion US pattern (including spongiform nodules): the utility of surveillance US and assessment of nodule growth as an indicator for repeat FNA to detect a missed malignancy is limited. If US is repeated, it should be done at ≥24 months.

(Weak recommendation, Low-quality evidence)

[A25] Recommendation for follow-up of nodules with two benign FNA cytology results

(D) If a nodule has undergone repeat US-guided FNA with a second benign cytology result, US surveillance for this nodule for continued risk of malignancy is no longer indicated.

(Strong recommendation, Moderate-quality evidence)

Given that there is a low but discrete false-negative rate for nodules with benign FNA cytology results, is there an optimal way to identify these missed malignancies? Although the risk of malignancy after two benign cytology results is virtually zero (129–133,236), routine rebiopsy is not a viable or cost-effective option because of the low false-negative rate of an US-guided FNA benign cytology result. Prior guidelines have recommended repeat FNA for nodules that grow during serial sonographic observation. However, nodule growth can be variably defined. Because of interobserver variation, Brauer *et al.* (237) reported a 50% increase in nodule volume as the minimally significant reproducibly recorded change in

Downloaded by Memorial Sloan Kettering from www.liebertpub.com at 08/14/19. For personal use only.

nodule size, which is equivalent to a 20% increase in two of the three nodule dimensions. If a 50% volume increase cutoff is applied, only 4%–10% of nodules were reported to be larger at a mean of 18 months (133,238). However, using cutoffs of a 15% volume increase based upon internally assessed interobserver coefficients of variation, published series report that 32%–50% of nodules increase in size over a 4–5 year period (239,240). Because of the stringent methodology of these studies, adoption of a 15% volume increase as statistically significant is not practically applicable.

A recent 5-year prospective multicenter study evaluated outcomes of 1597 nodules from 992 patients with either cytologically or sonographically benign nodules (241). Nodules 1 cm or larger underwent US-guided FNA and subcentimeter nodules were defined as sonographically benign based upon imaging characteristics equivalent to the ATA low or very low suspicion US patterns. All nodules were followed by annual US exams. The false-negative rate of a benign cytology diagnosis was 1.1%. Of the four missed cancers, on baseline US imaging three were hypoechoic and solid and one was isoechoic with microcalcifications; none was spongiform or mixed cystic solid and noncalcified (ATA very low suspicion pattern). During sonographic surveillance, repeat FNA was prompted by either growth (two nodules) or development of a new suspicious sonographic feature (two nodules). In addition, the shortest time interval to detect change and repeat the FNA was 2 years. Another critical observation from this study was that only one cancer was detected in 5 years among the 852 subcentimeter nodules classified as sonographicially benign at baseline. This cancer was identified on the 5-year follow-up US, when its composition changed from mixed cystic/solid to hypoechoic solid with irregular margins prompting FNA (241). Currently, there are no follow-up studies of nodule growth that extend observation beyond 5 years to help inform decision-making about long-term surveillance. Additional research would be valuable because indefinite follow-up of nodules with benign cytology is costly and may be unnecessary.

Recent investigations of repeat US-guided FNA in nodules with initial benign cytology show higher detection rates for missed malignancy for those nodules with a high suspicion sonographic pattern rather than size increase (236,242). Kwak *et al.* (236) reported a significantly higher malignancy rate of 20.4% in nodules with benign cytology that exhibited either marked hypoechogenicity, irregular borders, microcalcifications, or a taller than wide shape versus a 1.4% risk in those that exhibited a 15% volume increase but lacked these US features. Importantly, the low risk of malignancy did not differ between US negative nodules that grew and those that demonstrated no interval size change (1.4% vs. 0.5%, $p = 0.18$). Similarly, Rosario *et al.* (242) detected cancer in 17.4% of nodules with benign cytologic diagnoses and suspicious US features versus 1.3% of those without suspicious characteristic that grew, using criteria of a 50% volume increase. These studies indicate that the use of suspicious US characteristics rather than nodule growth should be the indication for repeat FNA despite an initial benign cytology diagnosis. Repeat US and FNA should be repeated within 12 months as guided by clinical judgement. Given the low false-negative rate of US-guided FNA cytology and the higher yield of missed malignancies based upon nodule sonographic pattern rather than growth, the follow-up of thyroid nodules with benign cytology diagnoses should be determined by risk stratification based upon US pattern as defined in Recommendation 8. If follow-up US for surveillance is performed and the nodule size is stable, the utility of subsequent US imaging for detection of potential malignancy by nodule growth assessment is very low and if performed, the time interval for any additional US exam should be at least as long that between the initial benign FNA cytology result and first follow-up. However, even if a repeat US is not indicated based on a benign cytology, US pattern, or stability in nodule size, larger nodules may require monitoring for growth that could result in symptoms and thus prompt surgical intervention despite benign cytology.

One recent study evaluated the long-term consequences of a false-negative benign cytology (140). A total of 1369 patients with 2010 cytologically benign thyroid nodules were followed for a mean of 8.5 years. Eighteen false-negative cases were identified, although only a subset of patients underwent repeat FNA or thyroid surgery. Thirty deaths were documented in the entire cohort over this time period and none were attributable to thyroid cancer. These data support that an initial benign cytology conveys an overall excellent prognosis and a conservative follow-up strategy is reasonable.

[A26] Follow-up for nodules that do not meet FNA criteria

■ RECOMMENDATION 24

Nodules may be detected on US that do not meet criteria for FNA at initial imaging (Recommendation 8). The strategy for sonographic follow-up of these nodules should be based upon the nodule's sonographic pattern.

(A) Nodules with high suspicion US pattern: repeat US in 6–12 months.

(Weak recommendation, Low-quality evidence)

(B) Nodules with low to intermediate suspicion US pattern: consider repeat US at 12–24 months.

(Weak recommendation, Low-quality evidence)

(C) Nodules >1 cm with very low suspicion US pattern (including spongiform nodules) and pure cyst: the utility and time interval of surveillance US for risk of malignancy is not known. If US is repeated, it should be at ≥24 months.

(No recommendation, Insufficient evidence)

(D) Nodules ≤1 cm with very low suspicion US pattern (including spongiform nodules) and pure cysts do not require routine sonographic follow-up.

(Weak recommendation, Low-quality evidence)

Ultrasound studies demonstrate that up to 50% of adults have thyroid nodules. The vast majority of these are subcentimeter, and FNA evaluation is generally not indicated. In addition, based upon both sonographic pattern and size cutoffs (Recommendation 8), many nodules >1 cm may also be followed without FNA. Although no prospective studies address the optimal cost-effective surveillance strategy for these nodules that have not undergone FNA, a recent study by Durante *et al.* (241) confirms that subcentimeter thyroid nodules corresponding to the ATA very low suspicion risk pattern are highly

Downloaded by Memorial Sloan Kettering from www.liebertpub.com at 08/14/19. For personal use only.

unlikely to change during 5-year sonographic follow-up, and the risk of malignancy is exceedingly low. The findings from studies correlating sonographic features and malignancy risk in aspirated nodules can be extrapolated to inform a follow-up strategy for this group of nodules that do not meet FNA criteria at the time of their initial detection. For example, the interval for follow-up sonography for a nodule that is hypoechoic and taller than wide should be shorter than that for an isoechoic solid nodule with smooth borders.

US-guided FNA should be performed based upon follow-up US imaging if the nodule subsequently meets criteria based upon Recommendation 8.

[A27] What is the role of medical or surgical therapy for benign thyroid nodules?

■ **RECOMMENDATION 25**

Routine TSH suppression therapy for benign thyroid nodules in iodine sufficient populations is not recommended. Though modest responses to therapy can be detected, the potential harm outweighs benefit for most patients.

(Strong recommendation, High-quality evidence)

■ **RECOMMENDATION 26**

Individual patients with benign, solid, or mostly solid nodules should have adequate iodine intake. If inadequate dietary intake is found or suspected, a daily supplement (containing 150 μg iodine) is recommended.

(Strong recommendation, Moderate-quality evidence)

■ **RECOMMENDATION 27**

(A) Surgery may be considered for growing nodules that are benign after repeat FNA if they are large (>4 cm), causing compressive or structural symptoms, or based upon clinical concern.

(Weak recommendation, Low-quality evidence)

(B) Patients with growing nodules that are benign after FNA should be regularly monitored. Most asymptomatic nodules demonstrating modest growth should be followed without intervention.

(Strong recommendation, Low-quality evidence)

■ **RECOMMENDATION 28**

Recurrent cystic thyroid nodules with benign cytology should be considered for surgical removal or percutaneous ethanol injection (PEI) based on compressive symptoms and cosmetic concerns. Asymptomatic cystic nodules may be followed conservatively.

(Weak recommendation, Low-quality evidence)

■ **RECOMMENDATION 29**

There are no data to guide recommendations on the use of thyroid hormone therapy in patients with growing nodules that are benign on cytology.

(No recommendation, Insufficient evidence)

Evidence from multiple prospective, RCTs, and from three meta-analyses suggest that thyroid hormone supplementation in doses that suppress the serum TSH to subnormal levels may result in a decrease in nodule size and may prevent the appearance of new nodules in regions of the world with borderline low iodine intake (239,243–245). However, the effect is modest, with most studies suggesting an average 5%–15% reduction in nodule volume when treated with suppressive levothyroxine (LT_4) therapy for 6–18 months. Two high-quality meta-analyses confirm that six to eight patients will require suppressive LT_4 therapy to achieve one successful treatment response (246,247). The extent of TSH suppression achieved in high-quality studies is variable, though the majority suppressed TSH to <0.2 mIU/L, with many to <0.1 mIU/L. Hyperthyroidism to this degree has been significantly associated with an increased risk of cardiac arrhythmias and osteoporosis, as well as adverse symptomatology. Together, these data confirm that LT_4 suppressive therapy demonstrates modest (though usually clinically insignificant) efficacy in nodule volume reduction, but increases the risk of adverse consequences related to iatrogenic thyrotoxicosis. One large prospective, randomized trial demonstrated that sufficient dietary iodine intake (150 μg daily) also reduced nodule size slightly more than placebo (248). The consumption of adequate dietary iodine is recommended for all adults and is without harm when not excessive. Data supporting LT_4 therapy in non–TSH-suppressive doses for prevention of thyroid nodule growth are incomplete. One recent cohort analysis suggested non-suppressive doses of LT_4 therapy conferred protection from nodule growth over time (249). However, the nonblinded, non-randomized nature of the trial precludes broad translation of the data, and the efficacy of nonsuppressive LT_4 remains unproven.

Cystic nodules that are cytologically benign can be monitored for recurrence (fluid reaccumulation), which can be seen in 60%–90% of patients (250,251). For those patients with subsequent recurrent symptomatic cystic fluid accumulation, surgical removal, generally by hemithyroidectomy, or PEI are both reasonable strategies. Four controlled studies demonstrated a 75%–85% success rate after PEI compared with a 7%–38% success rate in controls treated by simple cyst evacuation or saline injection. Success was achieved after an average of two PEI treatments. Complications included mild to moderate local pain, flushing, dizziness, and dysphonia (250–253). Surgery may be considered for growing solid nodules that are benign on repeat cytology if they are large (>4 cm), causing compressive or structural symptoms, or based upon clinical concern (254,255).

[A28] How should thyroid nodules in pregnant women be managed?

[A29] FNA for thyroid nodules discovered during pregnancy

■ **RECOMMENDATION 30**

(A) FNA of clinically relevant thyroid nodules (refer to section [A10]) should be performed in euthyroid and hypothyroid pregnant women.

(Strong recommendation, Moderate-quality evidence)

(B) For women with suppressed serum TSH levels that persist beyond 16 weeks gestation, FNA may be deferred until after pregnancy and cessation of lactation. At that

Downloaded by Memorial Sloan Kettering from www.liebertpub.com at 08/14/19. For personal use only.

time, a radionuclide scan can be performed to evaluate nodule function if the serum TSH remains suppressed.

(Strong recommendation, Moderate-quality evidence)

It is uncertain if thyroid nodules discovered in pregnant women are more likely to be malignant than those found in nonpregnant women, since there are no population-based studies to address this question. Pregnancy does not appear to modify microscopic cellular appearance, thus standard diagnostic criteria should be applied for cytologic evaluation (256). Serial evaluation of nodules throughout pregnancy has demonstrated that thyroid nodules will enlarge slightly throughout gestation, though this does not imply malignant transformation (257). The recommended evaluation of a clinically relevant nodule in a pregnant patient is thus the same as for a nonpregnant patient, with the exception that a radionuclide scan is contraindicated. In addition, for patients with nodules diagnosed as DTC by FNA during pregnancy, delaying surgery until after delivery does not affect outcome (258). Surgery performed during pregnancy is associated with greater risk of complications, longer hospital stays, and higher costs (259).

[A30] Approaches to pregnant patients with malignant or indeterminate cytology

■ **RECOMMENDATION 31**

PTC discovered by cytology in early pregnancy should be monitored sonographically. If it grows substantially (as defined in section [A24]) before 24–26 weeks gestation, or if US reveals cervical lymph nodes that are suspicious for metastatic disease, surgery should be considered during pregnancy. However, if the disease remains stable by midgestation, or if it is diagnosed in the second half of pregnancy, surgery may be deferred until after delivery.

(Weak recommendation, Low-quality evidence)

If FNA cytology is consistent with PTC, surgery is generally recommended. However, the decision to perform such surgery either during pregnancy or after delivery must be individualized. If surgery is not performed, the utility of thyroid hormone therapy targeted to lower serum TSH levels to improve the prognosis of thyroid cancer diagnosed during gestation is not known. Because higher serum TSH levels may be correlated with a more advanced stage of cancer at surgery (260), if the patient's serum TSH is >2 mU/L, it may be reasonable to initiate thyroid hormone therapy to maintain the TSH between 0.3 to 2.0 mU/L for the remainder of gestation.

Most data confirm that the prognosis of women with well-differentiated thyroid cancer identified but not treated during pregnancy is similar to that of nonpregnant patients. Because of this, surgery in most pregnant patients is deferred until postpartum (258,261), and no further testing is required. However, some studies differ from these findings. Two Italian cohort studies have investigated women diagnosed with DTC in relation to the timing of pregnancy. Messuti *et al.* (262) noted a statistically higher rate of persistence/recurrence when DTC was diagnosed during pregnancy or within 2 years postpartum. However, the stimulated Tg was found to be >10 ng/mL during ^{131}I ablation in many cases, suggesting the extent of thyroidectomy and/or tumor resection may have been limited in this cohort and therefore contributed to biochemical persistence of disease. Vannucchi *et al.* (263) followed a small cohort of 10 patients with DTC during pregnancy or within 1 year post partum, again noting a large rate of persistent disease (60%) compared to nonpregnant controls (4.2%–13.1%). Similarly, the majority of cases with persistent disease were attributable to biochemical elevations in Tg or anti-Tg antibodies, again raising the question of whether the extent of initial resection was limited in comparison to nonpregnant controls. Given the likelihood that biochemical persistence could be attributable to an increased size of remnant tissue or incomplete surgical resection in both studies, these data should not refute previous, larger analyses showing no increased recurrence rates when DTC is diagnosed during pregnancy.

Theoretically, molecular marker analysis could be helpful in the evaluation of DTC or clinically relevant, cytologically indeterminate thyroid nodules detected during pregnancy. However, the application of molecular testing in pregnant women with indeterminate cytology remains uncertain. There are no published data validating the performance of any molecular marker in this population. Therefore, the committee cannot recommend for or against their use in pregnant women. However, it is theoretically possible that changes in a nodule's RNA expression may occur during gestation altering performance of the 167 GEC while the seven-gene mutational panel (*BRAF*, *RAS*, *PAX8/PPARγ*, *RET/PTC*) would be more likely to demonstrate similar performance to that of a nonpregnant population.

When surgery is advised during pregnancy, it is most often because of high-risk clinical or sonographic findings, nodule growth, or change over short duration follow-up or it is based upon physician judgement. To minimize the risk of miscarriage, surgery during pregnancy should be done in the second trimester before 24 weeks gestation (264). However, PTC discovered during pregnancy does not behave more aggressively than that diagnosed in a similar-aged group of nonpregnant women (258,265). A retrospective study of pregnant women with DTC found no difference in either recurrence or survival rates between women operated during or after pregnancy (258). Further, retrospective data suggest that treatment delays of <1 year from the time of thyroid cancer discovery do not adversely affect patient outcome (266). A separate study reported a higher rate of complications in pregnant women undergoing thyroid surgery compared with nonpregnant women (267). If FNA cytology is indeterminate, monitoring may be considered with further evaluation may be delayed until after delivery. Some experts recommend thyroid hormone suppression therapy for pregnant women with FNA suspicious for or diagnostic of PTC, if surgery is deferred until the postpartum period (259).

[B1] DIFFERENTIATED THYROID CANCER: INITIAL MANAGEMENT GUIDELINES

Differentiated thyroid cancer, arising from thyroid follicular epithelial cells, accounts for the vast majority of thyroid cancers. Of the differentiated cancers, papillary cancer comprises about 85% of cases compared to about 12% that have follicular histology, including conventional and oncocytic (Hürthle cell) carcinomas, and <3% that are poorly

Downloaded by Memorial Sloan Kettering from www.liebertpub.com at 08/14/19. For personal use only.

differentiated tumors (268). In general, stage for stage, the prognoses of PTC and follicular cancer are similar (266,269).

[B2] Goals of initial therapy of DTC

The basic goals of initial therapy for patients with DTC are to improve overall and disease-specific survival, reduce the risk of persistent/recurrent disease and associated morbidity, and permit accurate disease staging and risk stratification, while minimizing treatment-related morbidity and unnecessary therapy. The specific goals of initial therapy are to

1. Remove the primary tumor, disease that has extended beyond the thyroid capsule, and clinically significant lymph node metastases. Completeness of surgical resection is an important determinant of outcome, while residual metastatic lymph nodes represent the most common site of disease persistence/recurrence (270–272).
2. Minimize the risk of disease recurrence and metastatic spread. Adequate surgery is the most important treatment variable influencing prognosis, while RAI treatment, TSH suppression, and other treatments each play adjunctive roles in at least some patients (273–275).
3. Facilitate postoperative treatment with RAI, where appropriate. For patients undergoing RAI remnant ablation, or RAI treatment of presumed (adjuvant therapy) or known (therapy) residual or metastatic disease, removal of all normal thyroid tissue is an important element of initial surgery (276).
4. Permit accurate staging and risk stratification of the disease. Because disease staging and risk stratification should be used to guide initial prognostication, disease management, and follow-up strategies, accurate postoperative risk assessment is a crucial element in the management of patients with DTC (277,278).
5. Permit accurate long-term surveillance for disease recurrence.
6. Minimize treatment-related morbidity. The extent of surgery and the experience of the surgeon both play important roles in determining the risk of surgical complications (232,233,279,280).

[B3] What is the role of preoperative staging with diagnostic imaging and laboratory tests?

[B4] Neck imaging—ultrasound

■ RECOMMENDATION 32

(A) Preoperative neck US for cervical (central and especially lateral neck compartments) lymph nodes is recommended for all patients undergoing thyroidectomy for malignant or suspicious for malignancy cytologic or molecular findings.

(Strong recommendation, Moderate-quality evidence)

(B) US-guided FNA of sonographically suspicious lymph nodes ≥8–10 mm in the smallest diameter should be performed to confirm malignancy if this would change management.

(Strong recommendation, Moderate-quality evidence)

(C) The addition of FNA-Tg washout in the evaluation of suspicious cervical lymph nodes is appropriate in select patients, but interpretation may be difficult in patients with an intact thyroid gland.

(Weak recommendation, Low-quality evidence)

Differentiated thyroid carcinoma (particularly papillary carcinoma) involves cervical lymph node metastases in 20%–50% of patients in most series using standard pathologic techniques (84,145,281–283), and it may be present even when the primary tumor is small and intrathyroidal (284). The frequency of micrometastases (<2 mm) may approach 90%, depending on the sensitivity of the detection method (285,286). However, the clinical implications of micrometastases are likely less significant compared to macrometastases. Preoperative US identifies suspicious cervical adenopathy in 20%–31% of cases, potentially altering the surgical approach (287,288) in as many as 20% of patients (289–291). However, preoperative US identifies only half of the lymph nodes found at surgery, due to the presence of the overlying thyroid gland (292).

Sonographic features suggestive of abnormal metastatic lymph nodes include enlargement, loss of the fatty hilum, a rounded rather than oval shape, hyperechogenicity, cystic change, calcifications, and peripheral vascularity (Table 7). No single sonographic feature is adequately sensitive for detection of lymph nodes with metastatic thyroid cancer. One study correlated the sonographic features acquired 4 days preoperatively directly with the histology of 56 cervical lymph nodes identified in 19 patients. Some of the most specific criteria were short axis >5 mm (96%), presence of cystic areas (100%), presence of hyperechogenic punctuations representing either colloid or microcalcifications (100%), and peripheral vascularity (82%). Of these, the only one with sufficient sensitivity was peripheral vascularity (86%). The others had sensitivities of <60% and would not be adequate to use as a single criterion for identification of malignant involvement (292). As shown by earlier studies (293,294), the ultrasonographic feature with the highest sensitivity is absence of a hilum (100%), but this has a low specificity of 29%. Microcalcifications have the highest specificity; any lymph nodes with microcalcifications should be considered abnormal (292) (Table 7).

The location of the lymph nodes may also be useful for decision-making. Malignant lymph nodes are much more likely to occur in levels III, IV, and VI than in level II (Fig. 3) (292,294), although this may not be true for PTC tumors arising in the upper pole of the thyroid, which have a higher propensity to demonstrate skip metastases to levels III and II (295). Figure 3 illustrates the delineation of cervical lymph node levels I through VI.

Confirmation of malignancy in lymph nodes with a suspicious sonographic appearance is achieved by US-guided FNA aspiration for cytology and/or measurement of Tg in the needle washout. A Tg concentration <1 ng/mL is reassuring, and the probability of N1 disease increases with higher Tg levels (296). This FNA measurement of Tg is likely valid even in patients with circulating anti-Tg autoantibodies (297,298), although one study challenges the validity of this measurement in patients with anti-Tg autoantibodies (299). Tg washout may be helpful, particularly in cases in which the lymph nodes are cystic, cytologic evaluation of the lymph node is inadequate, or the cytologic and sonographic evaluations are divergent (i.e., normal cytologic biopsy of

Downloaded by Memorial Sloan Kettering from www.liebertpub.com at 08/14/19. For personal use only.

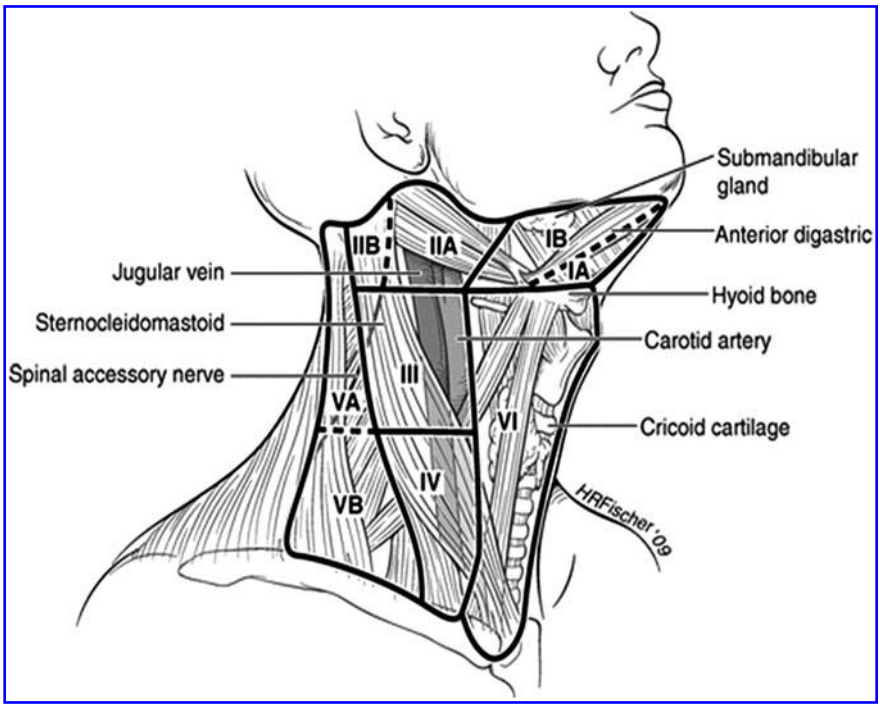

FIG. 3. Lymph node compartments separated into levels and sublevels. Level VI contains the thyroid gland, and the adjacent nodes bordered superiorly by the hyoid bone, inferiorly by the innominate (brachiocephalic) artery, and laterally on each side by the carotid sheaths. The level II, III, and IV nodes are arrayed along the jugular veins on each side, bordered anteromedially by level VI and laterally by the posterior border of the sternocleidomastoid muscle. The level III nodes are bounded superiorly by the level of the hyoid bone and inferiorly by the cricoid cartilage; levels II and IV are above and below level III, respectively. The level I node compartment includes the submental and submandibular nodes, above the hyoid bone, and anterior to the posterior edge of the submandibular gland. Finally, the level V nodes are in the posterior triangle, lateral to the lateral edge of the sternocleidomastoid muscle. Levels I, II, and V can be further subdivided as noted in the figure. The inferior extent of level VI is defined as the suprasternal notch. Many authors also include the pretracheal and paratracheal superior mediastinal lymph nodes above the level of the innominate artery (sometimes referred to as level VII) in central neck dissection (341).

a large lymph node with microcalcifications) (300). In a retrospective study of 241 lymph nodes in 220 patients who underwent US-guided FNA with Tg in FNA (FNA-Tg) washout fluid measurements for suspicious lymph nodes, additional FNA-Tg helped to diagnose a metastatic lymph node with one or two suspicious US features but did not offer incremental benefit for those lymph nodes with highly suspicious US features in which FNA alone was sufficient for diagnosis. Two recent systematic reviews showed that false-positive Tg washout may occur, particularly in lymph nodes in the central compartment when the thyroid gland is still present (301,302). The review by Pak *et al.* (302) suggests that an FNA-Tg cutoff of 32 ng/mL has the best sensitivity and specificity in patients with an intact thyroid gland. Others have suggested interpreting the FNA-Tg in context of the serum Tg and TSH in these patients (303,304). There is no standardization of FNA-Tg procedures or assays to date, which makes this additional diagnostic tool sometimes difficult to interpret (305). Future standardization including matrix type (phosphate-buffered saline, Tg-free serum, etc.) and volume of diluent matrix would help with interpretation of a Tg washout.

Accurate staging is important in determining the prognosis and tailoring treatment for patients with DTC. However, unlike many tumor types, the presence of metastatic disease does not obviate the need for surgical excision of the primary tumor in DTC (306). Because metastatic disease may respond to RAI therapy, removal of the thyroid as well as the primary tumor and accessible loco-regional disease remains an important component of initial treatment even in most patients with metastatic disease.

[B5] Neck imaging—CT/MRI/PET

■ RECOMMENDATION 33

(A) Preoperative use of cross-sectional imaging studies (CT, MRI) with intravenous (IV) contrast is recommended as an adjunct to US for patients with clinical suspicion for advanced disease, including invasive primary tumor, or clinically apparent multiple or bulky lymph node involvement.

(Strong recommendation, Low-quality evidence)

(B) Routine preoperative ^{18}FDG-PET scanning is not recommended.

(Strong recommendation, Low-quality evidence)

Since US evaluation is operator dependent and cannot always adequately image deep anatomic structures and those acoustically shadowed by bone or air, alternative imaging procedures may be preferable or useful as an adjunct in

Downloaded by Memorial Sloan Kettering from www.liebertpub.com at 08/14/19. For personal use only.

Downloaded by Memorial Sloan Kettering from www.liebertpub.com at 08/14/19. For personal use only.

some clinical settings. Patients displaying bulky or widely distributed nodal disease on initial US examination may present with involvement of nodal regions beyond typical cervical regions, some of which maybe difficult to visualize on routine preoperative US, including the mediastinum, infraclavicular, retropharyngeal, and parapharyngeal regions. In a study of 37 consecutive patients who had preoperative CT and US and subsequently underwent total thyroidectomy and neck dissection, the sensitivity of CT was better than US for the evaluation central and lateral compartment lymph nodes examined together (77% vs 62%, $p = 0.002$), but there were no differences between the two imaging modalities when the central and lateral compartments were examined separately (307). In a series of 299 consecutively registered patients with pathologically proven PTC who underwent preoperative CT and US, US was more accurate than CT in predicting extrathyroidal tumor extension and multifocal bilobar disease ($p < 0.05$). The accuracy of staging was better overall with US ($p < 0.01$), and US had greater sensitivity than CT at predicting lateral compartment metastases ($p = 0.041$) (308). However, another study showed that combined preoperative mapping with US and CT was superior to US alone in the preoperative detection of nodal disease, especially in the central neck (309). The sensitivities of MRI and PET for the detection of cervical lymph node metastases are relatively low (30%–40%) (310). PET can also detect inflammatory lymph nodes, which reduces the specificity of this test in many patients with DTC. MRI can be used in the detection of cervical nodal metastasis. MRI is affected by respiratory artifacts and may be more difficult to interpret than CT scanning by surgeons in the operating room for low-volume nodal disease (311).

Invasive DTC has been reported to occur in 10%–15% of patients at the time of diagnosis (312). For this group of patients, cross-sectional imaging can also be a useful supplement for preoperative planning to accurately delineate the extent of laryngeal, tracheal, esophageal, or vascular involvement (309,313). Endoscopy of the trachea and or esophagus, with or without ultrasonography, at the beginning of the initial operation looking for evidence of intraluminal extension can also be helpful in cases of suspected areodigestive tract invasion.

Locally invasive primary tumors may be associated with characteristic signs and symptoms including progressive dysphagia, respiratory compromise, hemoptysis, rapid tumor enlargement, significant voice change or the finding of vocal cord paralysis, and mass fixation to the airway or neck structures. Certain sonographic features of the primary tumor, including extrathyroidal extension especially with posterior capsular extension and extension into the mediastinum, may also prompt axial imaging (307). Chest CT is useful in defining the inferior border of disease and in determining the extent to which mediastinal structures are involved in cases with significant caudal spread. CT findings may influence management by indicating the need for sternotomy and/or tracheal or laryngeal resection/reconstruction, which would likely require assembling additional resources and personnel in preparation for surgery. Neck CT with contrast can therefore be useful in delineating the extent of laryngeal, tracheal, and/or esophageal involvement in tumors displaying aggressive local invasion, as well as delineating bulky nodal disease, which may harbor significant extranodal extension that involves muscle and/or blood vessels. Preoperative knowledge of these features of the primary tumor or metastases could significantly influence the surgical plan (314). ^{18}FDG-PET scanning may be sensitive in some patients for neck or mediastinal involvement and may reveal distant metastases as well.

When cross-sectional imaging is performed, use of IV contrast is an important adjunct because it helps to delineate the anatomic relationship between the primary tumor or metastatic disease and these other structures. Iodine is generally cleared within 4–8 weeks in most patients, so concern about iodine burden from IV contrast causing a clinically significant delay in subsequent whole-body scans (WBSs) or RAI treatment after the imaging followed by surgery is generally unfounded (315). The benefit gained from improved anatomic imaging generally outweighs any potential risk of a several week delay in RAI imaging or therapy. When there is concern, a urinary iodine to creatinine ratio can be measured.

[B6] Measurement of serum Tg and anti-Tg antibodies

■ **RECOMMENDATION 34**

Routine preoperative measurement of serum Tg or anti-Tg antibodies is not recommended.

(Weak recommendation, Low-quality evidence)

Data from a systematic review and meta-analysis suggested that high preoperative concentrations of serum Tg may predict a higher sensitivity for postoperative surveillance with serum Tg (316). Preoperative anti-Tg antibodies do not appear to be an independent preoperative predictor of stage in patients with DTC, but the evidence is limited. In a cross-sectional analysis of 1770 patients with perioperative anti-Tg antibodies status data in the National Thyroid Cancer Treatment Cooperative Study (a large thyroid cancer registry that included 11 North American centers and enrolled patients between 1987 and 2011), serum anti-Tg antibody status was not significantly associated with stage of disease on multivariate analysis, or with disease-free or overall survival on univariate or multivariate analyses (317). Evidence that preoperative measurement of serum Tg impacts patient management or outcomes is not yet available.

[B7] Operative approach for a biopsy diagnostic for follicular cell–derived malignancy

■ **RECOMMENDATION 35**

(A) For patients with thyroid cancer >4 cm, or with gross extrathyroidal extension (clinical T4), or clinically apparent metastatic disease to nodes (clinical N1) or distant sites (clinical M1), the initial surgical procedure should include a near-total or total thyroidectomy and gross removal of all primary tumor unless there are contraindications to this procedure.

(Strong recommendation, Moderate-quality evidence)

(B) For patients with thyroid cancer >1 cm and <4 cm without extrathyroidal extension, and without clinical evidence of any lymph node metastases (cN0), the initial surgical procedure can be either a bilateral procedure (near-total or total thyroidectomy) or a unilateral procedure

(lobectomy). Thyroid lobectomy alone may be sufficient initial treatment for low-risk papillary and follicular carcinomas; however, the treatment team may choose total thyroidectomy to enable RAI therapy or to enhance follow-up based upon disease features and/or patient preferences.

(Strong recommendation, Moderate-quality evidence)

(C) If surgery is chosen for patients with thyroid cancer <1 cm without extrathyroidal extension and cN0, the initial surgical procedure should be a thyroid lobectomy unless there are clear indications to remove the contralateral lobe. Thyroid lobectomy alone is sufficient treatment for small, unifocal, intrathyroidal carcinomas in the absence of prior head and neck radiation, familial thyroid carcinoma, or clinically detectable cervical nodal metastases.

(Strong recommendation, Moderate-quality evidence)

Downloaded by Memorial Sloan Kettering from www.liebertpub.com at 08/14/19. For personal use only.

Surgery for thyroid cancer is an important element of a multifaceted treatment approach. The operation must be compatible with the overall treatment strategy and follow-up plan recommended by the managing team. Consideration should be given to referring patients with high-risk features (clinical N1 disease, concern for recurrent laryngeal nerve [RLN] involvement, or grossly invasive disease) to experienced surgeons, as both completeness of surgery and experience of the surgeon can have a significant impact on clinical outcomes and complication rates (232,233,279,280). Previous guidelines have endorsed total thyroidectomy as the primary initial surgical treatment option for nearly all DTCs >1 cm with or without evidence of loco-regional or distant metastases (25). This was based on retrospective data suggesting that a bilateral surgical procedure would improve survival (318), decrease recurrence rates (319–321), allow for routine use of RAI remnant ablation, and facilitate detection of recurrent/persistent disease during follow-up. However, recent data have demonstrated that in properly selected patients, clinical outcomes are very similar following unilateral or bilateral thyroid surgery (322–326). Furthermore, since the requirement for routine use of RAI ablation was one of the major reasons given in support of total thyroidectomy in low to intermediate risk patients, our current more selective approach to RAI ablation in these patients requires a critical reassessment of this indication. In some patients, the presence of the remaining lobe of the gland may obviate the lifelong need for exogenous thyroid hormone therapy. Finally, as our follow-up management paradigm has moved away from diagnostic whole body RAI scanning and toward a greater reliance on neck ultrasonography and serial serum Tg measurements (even in patients that did not receive RAI remnant ablation), we must also question whether total thyroidectomy and RAI remnant ablation is required to facilitate follow-up in low to intermediate risk patients.

In an analysis of 52,173 PTC patients diagnosed between 1985 and 1998 from the National Cancer Data Base (43,227 receiving total thyroidectomy, 8946 undergoing lobectomy), Bilimoria *et al.* (318) demonstrated a slightly higher 10-year relative overall survival for total thyroidectomy as opposed to thyroid lobectomy (98.4% vs. 97.1%, respectively, $p < 0.05$) and a slightly lower 10-year recurrence rate (7.7% vs. 9.8%, respectively, $p < 0.05$). When analyzed by size of the primary tumor, statistically significant differences in survival and recurrence were seen for all sizes >1 cm based on the extent of initial surgery. However, data on extrathyroidal extension, completeness of resection, and other comorbid conditions, which could have had a major impact on survival and recurrence risk, were not available. Therefore, it is unclear how often lobectomy was done based on proper selection of low to intermediate risk patients versus how often lobectomy was done in high-risk patients because of comorbid conditions, inability to obtain a complete resection, or status of the contralateral RLN. This is an important distinction because thyroid lobectomy patients were found to have extrathyroidal extension in 7% of cases (325), underwent external beam radiation therapy (EBRT) in 1%–2% (324), and RAI therapy in 12%–18% (318,325), and high-risk features were present in 8% (325). Given the small magnitude of differences reported for survival and recurrence between the total thyroidectomy and the lobectomy patients, it is quite possible that the slightly poorer outcomes seen in the lobectomy group could have been influenced by lobectomy patients with concurrent high risk features. Adam *et al.* (327) performed an updated analysis of 61,775 patients in the National Cancer Database who underwent thyroid surgery between 1998 and 2006. The researchers demonstrated that the overall survival advantage seen for patients with 1–4 cm PTC who underwent thyroidectomy in the study by Bilimoria *et al.* (318) disappeared when further adjustment was made for additional variables related to complexity and severity of illness. This lack of overall survival advantage was also seen when the group was subdivided into patients with 1–2 cm and 2–4 cm PTC.

Previously, Haigh *et al.* (325) had analyzed 5432 PTC patients from the SEER database (4612 receiving total thyroidectomy and 820 undergoing lobectomy) and found no difference in 10-year overall survival between total thyroidectomy and thyroid lobectomy when risk stratified by the AMES classification system. Interestingly, patients selected for thyroid lobectomy included 7% with extrathyroidal extension, 1% with distant metastases, and 5% with primary tumors >5 cm, and 8% were classified as having high risk based on AMES.

More recently, two additional studies have analyzed the SEER database, and both have failed to demonstrate a significant difference in survival when comparing total thyroidectomy with thyroid lobectomy (323,324). Barney *et al.* (323) included 23,605 DTC patients diagnosed between 1983 and 2002 (12,598 with total thyroidectomy, 3266 with lobectomy) and found no difference in 10-year overall survival (90.4% for total thyroidectomy vs. 90.8% for lobectomy) or 10-year cause-specific survival (96.8% for total thyroidectomy vs. 98.6% for lobectomy). Furthermore, in a multivariate analysis that included age, T, N, M, sex, year of diagnosis, extent of surgery, and RAI use, no difference in overall survival or cause specific survival was seen with respect to the extent of initial surgery. Mendelsohn *et al.* (324) analyzed 22,724 PTC patients diagnosed between 1998 and 2001 (16,760 with total thyroidectomy, 5964 with lobectomy) and found no differences in overall survival or disease-specific survival in a comparison of total thyroidectomy with lobectomy. Interestingly, of the patients that had lobectomy, 1.6% received external beam radiation therapy, 16% had extrathryoidal extension, 9% of tumors were >4 cm, and 20% received RAI ablation (once again indicating that lobectomy was done in some high-risk patients).

Downloaded by Memorial Sloan Kettering from www.liebertpub.com at 08/14/19. For personal use only.

Consistent with the SEER data analyses, two single-center studies also confirmed that lobectomy is associated with excellent survival in properly selected patients (322,326). After a median follow-up of 8 years, only one disease-specific death was seen in a cohort of 889 PTC patients with T1–T2 tumors treated with either total thyroidectomy ($n = 528$) or lobectomy ($n = 361$) (326). Furthermore, Matsuzu *et al.* (322) reported a cause-specific survival rate of 98% after a median of 17 years of follow-up in properly select PTC patients treated with lobectomy and ipsilateral neck dissection.

Given the propensity for PTC to be multifocal (often involving both lobes), it is not surprising that some studies have demonstrated a lower risk of loco-regional disease recurrence following total thyroidectomy as compared to thyroid lobectomy (319–321). However, with proper patient selection, loco-regional recurrence rates of less than 1%–4% and completion thyroidectomy rates of <10% can be achieved following thyroid lobectomy (326,328). Furthermore, the few recurrences that develop during long-term follow-up are readily detected and appropriately treated with no impact on survival (322,326,328).

Therefore, we conclude that in properly selected low- to intermediate-risk patients (patients with unifocal tumors <4 cm, and no evidence of extrathyroidal extension or lymph node metastases by examination or imaging), the extent of initial thyroid surgery probably has little impact on disease-specific survival. While recurrence rates can be quite low in these patients, it is likely that the lowest rates of recurrence during long-term follow-up would be associated with a total thyroidectomy. But since salvage therapy is quite effective in the few patients that recur after thyroid lobectomy, a conservative management approach to completion surgery, accepting a slightly higher risk of loco-regional recurrence, is a reasonable management strategy. Finally, a more selective use of RAI coupled with a greater reliance on neck US and serial serum Tg measurements for detection of recurrent disease is likely to significantly decrease the mandate for total thyroidectomies in low- and intermediate-risk patients done solely to facilitate RAI remnant ablation and follow-up.

Near-total or total thyroidectomy is necessary if the overall strategy is to include RAI therapy postoperatively, and thus is recommended if the primary thyroid carcinoma is >4 cm, if there is gross extrathyroidal extension, or if regional or distant metastases are clinically present. For tumors that are between 1 and 4 cm in size, either a bilateral thyroidectomy (total or near-total) or a unilateral procedure (thyroid lobectomy) may be suitable as treatment plan. Older age (>45 years), contralateral thyroid nodules, a personal history of radiation therapy to the head and neck, and familial DTC may be criteria for recommending a bilateral procedure because of plans for RAI therapy or to facilitate follow-up strategies or address suspicions of bilateral disease (270,278,322,326).

The relationship between surgeon volume and patient outcomes has been studied extensively over the last 20 years. Institutional studies examining outcomes following thyroidectomy by high-volume surgeons have been published demonstrating overall safety. In one of the first studies examining the relationship between surgeon volume and thyroidectomy outcomes at a state level, Sosa *et al.* (232) found a strong association between higher surgeon volume and favorable patient outcomes, especially with regard to RLN injury and wound complications. This was especially pronounced for patients undergoing total thyroidectomy for thyroid cancer. Others have made similar observations (233,329,330). In a recent study of patients undergoing thyroidectomy in the Health Care Utilization Project Nationwide Inpatient Sample (HCUP-NIS), surgeons were divided into categories of low (<10 cases/year; encompassing 6072 surgeons), intermediate (10–100 cases/year; 11,544 surgeons), and high volume (>100 cases/year; 4009 surgeons) (331). Over 80% of thyroid resections were performed by low- and intermediate-volume surgeons. On average, high-volume surgeons had the lowest complication rates for patients who underwent total thyroidectomy for cancer at 7.5%; intermediate-volume surgeons had a rate of 13.4%, and low-volume surgeons, 18.9% ($p < 0.001$).

From robust population-level data such as these, it can be concluded that referral of patients to high-volume thyroid surgeons is associated, on average, with superior outcomes. However, such referral is not always possible, given the relative scarcity of high-volume surgeons and their geographic distribution. In addition, there are some data suggesting that other factors, such as surgeon age, should be considered (332). Therefore, conclusions at a population level cannot always be applied to individual surgeons and patient circumstances. It may, however, be reasonable to consider sending patients with more extensive disease and concern for grossly invasive disease to a high-volume surgeon experienced in the management of advanced thyroid cancer.

It is worth noting that even high-volume surgeons have a higher overall postoperative complication rate when performing total thyroidectomy compared with lobectomy (333). Using the HCUP-NIS, these authors found that high-volume thyroid surgeons had a complication rate of 7.6% following thyroid lobectomy but a rate of 14.5% following total thyroidectomy. For low-volume surgeons, the complication rates were 11.8% and 24.1%, respectively. Therefore, patients should carefully weigh the relative benefits and risks of total thyroidectomy versus thyroid lobectomy, even when surgery is performed by high-volume surgeons.

[B8] Lymph node dissection

■ RECOMMENDATION 36

(A) Therapeutic central-compartment (level VI) neck dissection for patients with clinically involved central nodes should accompany total thyroidectomy to provide clearance of disease from the central neck.

(Strong recommendation, Moderate-quality evidence)

(B) Prophylactic central-compartment neck dissection (ipsilateral or bilateral) should be considered in patients with papillary thyroid carcinoma with clinically uninvolved central neck lymph nodes (cN0) who have advanced primary tumors (T3 or T4) or clinically involved lateral neck nodes (cN1b), or if the information will be used to plan further steps in therapy.

(Weak recommendation, Low-quality evidence)

(C) Thyroidectomy without prophylactic central neck dissection is appropriate for small (T1 or T2), noninvasive,

clinically node-negative PTC (cN0) and for most follicular cancers.

(Strong recommendation, Moderate-quality evidence)

■ RECOMMENDATION 37

Therapeutic lateral neck compartmental lymph node dissection should be performed for patients with biopsy-proven metastatic lateral cervical lymphadenopathy.

(Strong recommendation, Moderate-quality evidence)

Regional lymph node metastases are present at the time of diagnosis in a majority of patients with papillary carcinomas and a lesser proportion of patients with follicular carcinomas (290,334,335). Although PTC lymph node metastases are reported by some to have no clinically important effect on outcome in low risk patients, a study of the SEER database found, among 9904 patients with PTC, that lymph node metastases, age >45 years, distant metastasis, and large tumor size significantly predicted poor overall survival outcome in a multivariate analysis (336). All-cause survival at 14 years was 82% for PTC without lymph node metastases and 79% with nodal metastases ($p < 0.05$). Another SEER registry study concluded that cervical lymph node metastases conferred an independent risk of decreased survival, but only in patients with follicular cancer and patients with papillary cancer over age 45 years (337). However, characteristics of the lymph node metastases can further discriminate the risk of recurrence to the patient, especially in patients with clinically evident metastasis, multiple metastases, larger metastases, and/or extracapsular nodal extension (338,339), compared with those with more limited microscopic nodal disease (335). A recent comprehensive analysis of the National Cancer Data Base and SEER, however, showed a small but significantly increased risk of death for patients younger than 45 years with lymph node metastases compared with younger patients without involved lymph nodes, and that having incrementally more metastatic lymph nodes up to six involved nodes confers additional mortality risk in this age group (340). This study underlines the importance of rigorous preoperative screening for nodal metastases and potentially raises questions about current thyroid cancer staging systems. Common to all of these studies is the conclusion that the effect of the presence or absence of lymph node metastases on overall survival, if present, is small.

The cervical node sites are well-defined (341), and the most common site of nodal metastases is in the central neck, which is cervical level VI (Fig. 3). A recent consensus conference statement describes the relevant anatomy of the central neck compartment, delineates the nodal subgroups within the central compartment commonly involved with thyroid cancer, and defines the terminology relevant to central compartment neck dissection (342). In many patients, lymph node metastases in this area do not appear abnormal on preoperative imaging (289,334,343–345) or by inspection at the time of surgery (335), defining a cN0 group.

The role of therapeutic lymph node dissection for treatment of thyroid cancer nodal metastases is well accepted for cN1 disease (336,346–348). However, the value of routine prophylactic level VI (central) neck dissection for cN0 disease remains unclear. Central compartment dissection (therapeutic or prophylactic) can be achieved with low morbidity by experienced thyroid surgeons (349–351). The value for an individual patient depends upon the utility of the staging information to the treatment team in specific patient circumstances (351,352). Based on limited and imperfect data, prophylactic dissection has been suggested to improve disease-specific survival (353), local recurrence (345,354), and post-treatment Tg levels (345,355). It has also been used to inform the use of adjuvant RAI (344,347,350,356) and improve the accuracy of the estimates of risk of recurrence (356–358). However, in several studies, prophylactic dissection has shown no improvement in long-term patient outcome, while increasing the likelihood of temporary morbidity, including hypocalcemia, although prophylactic dissection may decrease the need for repeated RAI treatments (334,346,347,349,359–364).

The removal of cN0 level VI lymph nodes detects a substantial number of patients with pN1 disease; however, the direct effect of this on long-term outcome is small at best (365,366). The use of staging information for the planning of adjuvant therapy depends upon whether this information will affect the team-based decision-making for the individual patient. For these reasons, groups may elect to include prophylactic dissection for patients with some prognostic features associated with an increased risk of metastasis and recurrence (older or very young age, larger tumor size, multifocal disease, extrathyroidal extension, known lateral node metastases) to contribute to decision-making and disease control (345,351,355). Alternatively, some groups may apply prophylactic level VI dissection to patients with better prognostic features if the patient is to have a bilateral thyroidectomy, and if the nodal staging information will be used to inform the decision regarding use of adjuvant therapy (344,350,356). Finally, for some groups it appears reasonable to use a selective approach that applies level VI lymph node dissection at the time of initial operation only to patients with clinically evident disease based on preoperative physical exam, preoperative radiographic evaluation, or intraoperative demonstration of detectable disease (cN1) (335,359,367).

The information from prophylactic central neck dissection must be used cautiously for staging information. Since microscopic nodal positivity occurs frequently, prophylactic dissection often converts patients from clinical N0 to pathologic N1a, upstaging many patients over age 45 from American Joint Committee on Cancer (AJCC) stage I to stage III (334,344–347). However, microscopic nodal positivity does not carry the recurrence risk of macroscopic clinically detectable disease (335). Thus microscopic nodal upstaging may lead to excess RAI utilization and patient follow-up. Alternatively, the demonstration of uninvolved lymph nodes by prophylactic dissection may decrease the use of RAI for some groups (344,350,356). These effects may account for some of the existing extreme variability in utilization of RAI for thyroid cancer (368).

Studies of the $BRAF^{V600E}$ mutation have suggested an association between presence of the mutation and the risk of nodal disease (369–371), although results across all patients with papillary thyroid carcinoma are mixed (372–375). However, the presence of a $BRAF^{V600E}$ mutation has a limited PPV for recurrence and therefore, $BRAF^{V600E}$ mutation status in the primary tumor should not impact the decision for prophylactic central neck dissection (376).

Downloaded by Memorial Sloan Kettering from www.liebertpub.com at 08/14/19. For personal use only.

The preceding recommendations should be interpreted in light of available surgical expertise. For patients with small, noninvasive, cN0 tumors, the balance of risk and benefit may favor thyroid lobectomy and close intraoperative inspection of the central compartment, with the plan adjusted to total thyroidectomy with compartmental dissection only in the presence of involved lymph nodes.

Lymph nodes in the lateral neck (compartments II–V, Fig. 3), level VII (anterior mediastinum), and rarely in level I may also be involved by thyroid cancer (282,335,377,378). For patients in whom nodal disease is evident clinically on preoperative US and nodal FNA cytology or Tg washout measurement or at the time of surgery, surgical resection by compartmental node dissection may reduce the risk of recurrence and possibly mortality (379–381).

[B9] Completion thyroidectomy

■ **RECOMMENDATION 38**

(A) Completion thyroidectomy should be offered to patients for whom a bilateral thyroidectomy would have been recommended had the diagnosis been available before the initial surgery. Therapeutic central neck lymph node dissection should be included if the lymph nodes are clinically involved. Thyroid lobectomy alone may be sufficient treatment for low-risk papillary and follicular carcinomas.

(Strong recommendation, Moderate-quality evidence)

(B) RAI ablation in lieu of completion thyroidectomy is not recommended routinely; however, it may be used to ablate the remnant lobe in selected cases.

(Weak recommendation, Low-quality evidence)

Completion thyroidectomy may be necessary when the diagnosis of malignancy is made following lobectomy for an indeterminate or nondiagnostic biopsy. In addition, some patients with malignancy may require completion thyroidectomy to provide complete resection of multicentric disease and to allow for efficient RAI therapy. However, since intrathyroidal PTC or low-risk FTC can be managed with either lobectomy or total thyroidectomy (see Recommendation 35B), a completion thyroidectomy is not always required. The surgical risks of two-stage thyroidectomy (lobectomy followed by completion thyroidectomy) are similar to those of a near-total or total thyroidectomy (382–384). The marginal utility of prophylactic lymph node dissection for cN0 disease argues against its application in re-operations.

Ablation of the remaining lobe with RAI has been used as an alternative to completion thyroidectomy (385,386). There are limited data regarding the long-term outcomes of this approach. The data suggest similar clinical outcomes with a slightly higher proportion of patients with persistent detectable Tg. This approach may be helpful in patients for whom completion thyroidectomy carries some increased risk and for whom a delay in the length of time required to achieve destruction of the normal thyroid, which follows RAI (as opposed to surgical resection), is acceptable. In one unblinded, multicenter, randomized controlled equivalence trial comparing dose activities in achieving successful ablation of a remaining lobe in patients with T1b or T2 primary tumors, who had surgical contraindications or declined completion thyroidectomy, the remnant ablation success rate was significantly higher using 100 mCi (75% success rate; 1 mCi = 37 MBq), compared with 30 mCi (54%), although mild to moderate short-term neck pain was more frequently reported in the high-dose group (66%) compared with the low-dose group (51%) (387). Prednisone treatment for neck pain was used more frequently in the high-dose group (36% of patients) than in the low-dose group.

[B10] What is the appropriate perioperative approach to voice and parathyroid issues?

[B11] Preoperative care communication

■ **RECOMMENDATION 39**

Prior to surgery, the surgeon should communicate with the patient regarding surgical risks, including nerve and parathyroid injury, through the informed consent process and communicate with associated physicians, including anesthesia personnel, regarding important findings elicited during the preoperative workup.

(Strong recommendation, Moderate-quality evidence)

The preoperative consent process should include explicit discussion of the potential for temporary or permanent nerve injury (and its clinical sequelae, including voice change, swallowing disability, risk of aspiration, and tracheostomy) as well as hypoparathyroidism, bleeding, scarring, disease recurrence, need for additional postoperative treatment, and need for thyroid hormone and surveillance thyroid function tests. The conversation should be informed by the operating surgeon's own rates of complications. Results of the preoperative evaluation regarding extent of disease, risk stratification, and integrity of the airway should include results from imaging, cytology, and physical examination (388–392).

[B12] Preoperative voice assessment

■ **RECOMMENDATION 40**

All patients undergoing thyroid surgery should have preoperative voice assessment as part of their preoperative physical examination. This should include the patient's description of vocal changes, as well as the physician's assessment of voice.

(Strong recommendation, Moderate-quality evidence)

■ **RECOMMENDATION 41**

Preoperative laryngeal exam should be performed in all patients with

(A) Preoperative voice abnormalities

(Strong recommendation, Moderate-quality evidence)

(B) History of cervical or upper chest surgery, which places the RLN or vagus nerve at risk

(Strong recommendation, Moderate-quality evidence)

(C) Known thyroid cancer with posterior extrathyroidal extension or extensive central nodal metastases

(Strong recommendation, Low-quality evidence)

Downloaded by Memorial Sloan Kettering from www.liebertpub.com at 08/14/19. For personal use only.

Downloaded by Memorial Sloan Kettering from www.liebertpub.com at 08/14/19. For personal use only.

Voice alteration is an important complication of thyroid surgery affecting patients' quality of life (with regard to voice, swallowing, and airway domains), and it can have medico-legal and cost implications (393–401).

Preoperative assessment provides a necessary baseline reference from which to establish perioperative expectations (402). Also, preoperative voice assessment may lead one to identify preoperative vocal cord paralysis or paresis, which provides presumptive evidence of invasive thyroid malignancy and is important in planning the extent of surgery and in perioperative airway management (403–405). Contralateral nerve injury at surgery in such patients could cause bilateral cord paralysis with airway implications.

Preoperative voice assessment should include the patient's historical subjective response to questions regarding voice abnormalities or changes, as well as the physician's objective assessment of voice, and should be documented in the medical record (Table 9) (406). Voice and laryngeal function may be further assessed through laryngoscopy, and the application of validated quality of life and auditory perceptual assessment voice instruments (402). It is important to appreciate that vocal cord paralysis, especially when chronic, may not be associated with significant vocal symptoms due to a variety of mechanisms, including contralateral vocal cord compensation. Voice assessment alone may not identify such individuals (402).

Incidence rates for preoperative vocal cord paresis or paralysis for patients with benign thyroid disease at preoperative laryngoscopy range from 0% to 3.5% and up to 8% in patients with thyroid cancer (407–411). Finding vocal cord paralysis on preoperative examination strongly suggests the presence of locally invasive disease. Approximately 10%–15% of thyroid cancers present with extrathyroidal extension, with the most common structures involved including strap muscle (53%), the RLN (47%), trachea (30%), esophagus (21%), and larynx (12%) (405,412–414).

Undiagnosed preoperative laryngeal nerve dysfunction conveys greater risk during total thyroidectomy of postoperative bilateral nerve paralysis, respiratory distress, and need for tracheostomy. Also, preoperative identification of vocal cord paralysis is important because surgical algorithms in the management of the invaded nerve incorporate nerve functional status (415).

A laryngeal exam should be performed if the voice is abnormal during preoperative evaluation. In addition, a patient should have a laryngeal exam even if the voice is normal if he or she has a history of neck surgery that placed at risk either the RLN (such as past thyroid or parathyroid surgery) or the vagus nerve (such as carotid endarterectomy, cervical esophagectomy, and anterior approach to the cervical spine) or a history of prior external beam radiation to the neck. Correlation between vocal symptoms and actual vocal cord function is poor given the potential for variation in paralytic cord position, degree of partial nerve function, and contralateral cord function/compensation; therefore, vocal symptoms may be absent in patients with vocal cord paralysis. Vocal cord paralysis may be present in 1.5% to 30% of such postsurgical patients; it can be asymptomatic in up to one-third (403,416–422).

A laryngeal exam is recommended in patients with the preoperative diagnosis of thyroid cancer if there is evidence for gross extrathyroidal extension of cancer posteriorly or extensive nodal involvement, even if the voice is normal. The laryngeal exam should be performed in the previously noted high-risk settings, but it can be performed in other patients based on the surgeon's judgment.

Table 9. Preoperative Factors Which May Be Associated with Laryngeal Nerve Dysfunction

Factor	*Symptoms/signs*
History	Voice abnormality, dysphagia, airway symptoms, hemoptysis, pain, rapid progression, prior operation in neck or upper chest
Physical exam	Extensive, firm mass fixed to the larynx or trachea
Imaging	Mass extending to/beyond periphery of thyroid lobe posteriorly and/or tracheoesophageal infiltration, or bulky cervical adenopathy along the course of the RLN or vagus nerve

[B13] Intraoperative voice and parathyroid management

■ RECOMMENDATION 42

(A) Visual identification of the RLN during dissection is required in all cases. Steps should also be taken to preserve the external branch of the superior laryngeal nerve (EBSLN) during dissection of the superior pole of the thyroid gland.

(Strong recommendation, Moderate-quality evidence)

(B) Intraoperative neural stimulation (with or without monitoring) may be considered to facilitate nerve identification and confirm neural function.

(Weak recommendation, Low-quality evidence)

■ RECOMMENDATION 43

The parathyroid glands and their blood supply should be preserved during thyroid surgery.

(Strong recommendation, Moderate-quality evidence)

RLN injury rates are lower when the nerve is routinely visualized in comparison with surgeries in which the nerve is simply avoided (402,416,423). If the EBSLN can be visualized and preserved, that is ideal. If the EBSLN cannot be visually identified, steps should be taken to avoid the nerve; this can be done by staying close to the thyroid capsule at the superior pole and by skeletonizing the superior vascular pedicle. Intraoperative nerve monitoring can be used to facilitate this dissection (419). Studies with or without intraoperative nerve monitoring demonstrate similar patient outcomes with regard to nerve injury rates (420), but studies likely have been underpowered to detect statistically significant differences (413,424). A recent systematic meta-analysis of 20 randomized and nonrandomized prospective and retrospective studies suggested no statistically significant benefit of intraoperative neuromonitoring compared to visualization alone during thyroidectomy for the outcomes of overall, transient, or permanent RLN palsy when analyzed per nerve at risk or per patient (425). However, secondary subgroup analyses of high-risk patients (including those

with thyroid cancer) suggested statistically significant heterogeneity (variability) in treatment effect for overall and transient RLN injury, when analyzed per nerve at risk. Several studies show that intraoperative nerve monitoring is more commonly utilized by higher volume surgeons to facilitate nerve management, and several studies show improved rates of nerve paralysis with the use of neural monitoring in reoperative and complex thyroid surgery (401,426–430). Neural stimulation at the completion of lobectomy can be used as a test to determine the safety of contralateral surgery with avoidance of bilateral vocal cord paralysis, and it has been associated with a reduction of bilateral paralysis when loss of signal occurs on the first side (428,431–433). Given the complexity of monitoring systems, training and observation of existing monitoring standards are important to provide optimal benefit (424,434).

Typically, parathyroid gland preservation is optimized by gland identification via meticulous dissection (435,436). If the parathyroid(s) cannot be located, the surgeon should attempt to dissect on the thyroid capsule and ligate the inferior thyroid artery very close to the thyroid, since the majority of parathyroid glands receive their blood supply from this vessel. There are exceptions to this rule; for example, superior glands in particular may receive blood supply from the superior thyroid artery. If the parathyroid glands are inadvertently or unavoidably removed (e.g., they are intrathyroidal, or require removal during a central lymph node dissection) or devascularized, confirmation of cancer-free parathyroid tissue should be performed, and then the glands can be autotransplanted into the strap or sternocleidomastoid muscles. It is important to inspect the thyroidectomy and/or central lymphadenectomy specimen when removed and before sending it to pathology to look for parathyroid glands that can be rescued.

[B14] Postoperative care

■ **RECOMMENDATION 44**

Patients should have their voice assessed in the postoperative period. Formal laryngeal exam should be performed if the voice is abnormal

(Strong recommendation, Moderate-quality evidence)

■ **RECOMMENDATION 45**

Important intraoperative findings and details of postoperative care should be communicated by the surgeon to the patient and other physicians who are important in the patient's postoperative care.

(Strong recommendation, Low-quality evidence)

Voice assessment should occur after surgery and should be based on the patient's subjective report and physician's objective assessment of voice in the office (409). Typically this assessment can be performed at 2 weeks to 2 months after surgery. Early detection of vocal cord motion abnormalities after thyroidectomy is important for facilitating prompt intervention (typically through early injection vocal cord medialization), which is associated with better long-term outcome, including a lower rate of formal open thyroplasty repair (437–439). Many options exist for the management of RLN paralysis, including voice therapy, vocal cord injection techniques, and open vocal cord medialization. Rates of vocal cord paralysis after thyroid surgery can only be assessed by laryngeal exam postoperatively.

Communication of intraoperative findings and postoperative care from the surgeon to other members of the patient's thyroid cancer care team is critical to subsequent therapy and monitoring approaches. Important elements of communication include (i) surgical anatomic findings, including RLN and parathyroid status (including nerve monitoring loss of signal information if monitoring is employed); (ii) surgical disease findings, including evidence for extrathyroidal spread, completeness of tumor resection, presence and distribution of nodal disease; and (iii) postoperative status, including voice/laryngeal exam, laboratory data regarding calcium/parathyroid hormone levels and need for calcium and/or vitamin D supplementation, and the surgical pathology report (440). The surgeon should remain engaged in the patient's pursuant care to facilitate appropriate communication and may remain engaged subsequent to endocrinologic consultation depending on regional practice patterns.

[B15] What are the basic principles of histopathologic evaluation of thyroidectomy samples?

■ **RECOMMENDATION 46**

(A) In addition to the basic tumor features required for AJCC/UICC thyroid cancer staging including status of resection margins, pathology reports should contain additional information helpful for risk assessment, such as the presence of vascular invasion and the number of invaded vessels, number of lymph nodes examined and involved with tumor, size of the largest metastatic focus to the lymph node, and presence or absence of extranodal extension of the metastatic tumor.

(Strong recommendation, Moderate-quality evidence)

(B) Histopathologic variants of thyroid carcinoma associated with more unfavorable outcomes (e.g., tall cell, columnar cell, and hobnail variants of PTC; widely invasive FTC; poorly differentiated carcinoma) or more favorable outcomes (e.g., encapsulated follicular variant of PTC without invasion, minimally invasive FTC) should be identified during histopathologic examination and reported.

(Strong recommendation, Low-quality evidence)

(C) Histopathologic variants associated with familial syndromes (cribriform-morular variant of papillary carcinoma often associated with FAP, follicular or papillary carcinoma associated with PTEN-hamartoma tumor syndrome) should be identified during histopathologic examination and reported.

(Weak recommendation, Low-quality evidence)

Pathologic examination of thyroid samples establishes the diagnosis and provides important information for risk stratification of cancer and postsurgical patient management. Histopathologically, papillary carcinoma is a well-differentiated malignant tumor of thyroid follicular cells that demonstrates characteristic microscopic nuclear features. Although a papillary growth pattern is frequently seen, it is not required for the diagnosis. Follicular carcinoma is a

Downloaded by Memorial Sloan Kettering from www.liebertpub.com at 08/14/19. For personal use only.

well-differentiated malignant tumor of thyroid follicular cells that shows transcapsular and/or vascular invasion and lacks the diagnostic nuclear features of papillary carcinoma. Oncocytic (Hürthle cell) follicular carcinoma shows the follicular growth pattern but is composed of cells with abundant granular eosinophilic cytoplasm, which has this appearance because of accumulation of innumerable mitochondria. This tumor is currently designated by the World Health Organization as a histopathologic variant of follicular carcinoma (441). However, oncocytic follicular carcinoma tumors have some differences in biological behavior as compared to the conventional type follicular carcinoma, such as the ability to metastasize to lymph nodes and a possibly higher rate of recurrence and tumor-related mortality (269,442,443). Moreover, a growing body of genetic evidence suggests that oncocytic tumors develop via unique molecular mechanisms and therefore represent a distinct type of well-differentiated thyroid cancer (444).

Traditionally, follicular carcinomas have been subdivided into minimally invasive (encapsulated) and widely invasive. In this classification scheme, minimally invasive carcinomas are fully encapsulated tumors with microscopically identifiable foci of capsular or vascular invasion, whereas widely invasive carcinomas are tumors with extensive vascular and/or extrathyroidal, invasion. More recent approaches consider encapsulated tumors with only microscopic capsular invasion as minimally invasive, whereas angioinvasive tumors are placed into a separate category (445–447). Such an approach is preferable because it distinguishes encapsulated tumors with capsular invasion and no vascular invasion, which are highly indolent tumors with a mortality <5%, from angioinvasive follicular carcinomas, which have a mortality ranging from 5% to 30%, depending on the number of invaded blood vessels (448).

In addition to establishing a diagnosis for each nodule in a thyroidectomy or lobectomy specimen, the pathology report must provide characteristics required for AJCC/UICC TNM staging, such as tumor size and presence of extrathyroidal extension and lymph node metastasis. Extrathyroidal extension is defined as tumor extension into the adjacent tissues. It is subdivided into *minimal*, which is invasion into immediate perithyroidal soft tissues or sternothyroid muscle typically detected only microscopically (T3 tumors), and *extensive*, which is tumor invasion into subcutaneous soft tissues, larynx, trachea, esophagus, or RLN (T4a tumors). The status of the resection (inked) margins should be reported as ''involved'' or ''uninvolved'' with tumor, since positive margins are generally associated with intermediate or high risk for recurrence.

The size of the metastatic focus in a lymph node (335) and tumor extension beyond the capsule of a lymph node (338,449,450) affect cancer risk. Therefore, the pathology report should indicate the size of the largest metastatic focus to the lymph node and the presence or absence of extranodal tumor extension, as well as the number of examined and involved lymph nodes.

Additionally, the presence of vascular (blood vessel) invasion is an unfavorable prognostic factor (451–453) and should be evaluated and reported. Vascular invasion is diagnosed as direct tumor extension into the blood vessel lumen or a tumor aggregate present within the vessel lumen, typically attached to the wall and covered by a layer of endothelial cells. More rigid criteria for vascular invasion proposed by some authors also require the presence of a fibrin thrombus attached to the intravascular tumor cells (453). The invaded blood vessels should not be located within the tumor nodule parenchyma, but rather in the tumor capsule or outside of it. Invasion of multiple (four or more) blood vessels appears to entail poorer outcomes, particularly in follicular carcinomas (454–456). Therefore, the number of invaded blood vessels (less than four or more) should be stated in the pathology report.

More than 10 microscopic variants of papillary carcinoma have been documented (457). Some of them are associated with more aggressive or conversely more indolent tumor behavior and can contribute to risk stratification. The variants with more unfavorable outcomes are the tall cell, columnar cell, and hobnail variants. The tall cell variant is characterized by predominance (>50%) of tall columnar tumor cells whose height is at least three times their width. These tumors present at an older age and more advanced stage than classic papillary carcinoma (458–461) and demonstrate a higher recurrence rate and decreased disease-specific survival (458–460,462,463). Some studies found a higher rate of lymph node metastasis and poorer survival in patients with tall cell variant as compared to classic papillary carcinoma even in tumors without extrathyroidal extension, and this was independent of patient age and tumor size and stage (464,465). The $BRAF^{V600E}$ mutation is found in $\sim$80% of these tumors (156,466).

The columnar cell variant of papillary carcinoma is characterized by predominance of columnar cells with pronounced nuclear stratification (467,468). These tumors have a higher risk of distant metastases and tumor-related mortality, the latter seen mostly in patients with an advanced disease stage at presentation (467–470). The $BRAF^{V600E}$ mutation is found in one-third of these tumors (467).

Papillary carcinoma with prominent hobnail features is a rare, recently described variant characterized by the predominance of cells with a hobnail appearance with apically placed nuclei and bulging of the apical cell surface (471,472). The $BRAF^{V600E}$ mutation is frequently found in these tumors (471,473). This variant of papillary carcinoma appears to be associated with frequent distant metastases (typically to lung) and increased risk of tumor-related death (471).

Other variants of papillary carcinoma, such as the solid variant and diffuse sclerosing variant, may be associated with a less favorable outcome, although the data remain conflicting. The solid variant tumors appear to be more frequently associated with distant metastases that are present in about 15% of cases, and with a slightly higher mortality rate, which was 10%–12% in two studies with 10 and 19 years mean follow-up (474,475). However, among children and adolescents with post-Chernobyl papillary carcinomas, which frequently were of the solid variant, the mortality was very low (<1%) during the first 10 years of follow-up (476,477). Importantly, the solid variant of papillary carcinoma should be distinguished from poorly differentiated thyroid carcinoma, with which it shares the insular, solid, and trabecular growth patterns. The distinction is based primarily on the preservation of nuclear features and lack of necrosis and high mitotic activity in the solid variant, as outlined by the Turin diagnostic criteria for poorly differentiated thyroid carcinoma (478). It is important to make the distinction because poorly differentiated thyroid carcinoma has a much poorer prognosis, with the 5-year survival of 72% and 10-year survival of

Downloaded by Memorial Sloan Kettering from www.liebertpub.com at 08/14/19. For personal use only.

46% in a series of 152 patients diagnosed using the Turin criteria (479).

The prognostic implication of the diffuse sclerosing variant of papillary cancer remains controversial. This variant is characterized by diffuse involvement of the thyroid gland and a higher rate of local and distant metastases at presentation, and it has lower disease-free survival than classic papillary carcinoma (480–482). The frequency of distant metastases, predominantly affecting the lung, varies between reported series and is 10%–15% based on almost 100 published cases summarized by Lam and Lo in 2006 (483) and more recent reports. Nevertheless, the overall mortality appears to be low, with a disease-specific survival of approximately 93% at 10 years of follow-up. The diffuse sclerosing variant tends to be found in younger patients in whom response to treatment is high.

The encapsulated follicular variant of papillary carcinoma is, in contrast, associated with a low risk of recurrence, particularly in the absence of capsular or vascular invasion. This variant is characterized by a follicular growth pattern with no papillae formation and total tumor encapsulation, and the diagnosis rests on the finding of characteristic nuclear features of papillary carcinoma. Although the encapsulated follicular variant of PTC shares the follicular growth pattern with the infiltrative, nonencapsulated follicular variant of PTC, these tumors differ in their molecular profiles and biological properties. The encapsulated follicular variant tumors frequently have *RAS* mutations, whereas nonencapsulated follicular variants frequently harbor $BRAF^{V600E}$ mutations, similar to classic papillary carcinomas (484,485). Most of the encapsulated follicular variant papillary carcinomas show no invasive growth, whereas in about one-third of cases tumor capsule invasion, vascular invasion, or both are found (486,487). Whereas in the past the encapsulated follicular variant was relatively rare, at the present time half to two-thirds of all follicular variant papillary carcinomas belong to this subtype (488). The behavior of these tumors is usually quite indolent. A summary of six studies that reported 107 cases of encapsulated follicular variant revealed 25% with lymph node metastases and 1% with distant metastases (489). Among these 107 patients, one died of disease and two were alive with disease, whereas the rest (97%) of the patients were alive and well with various follow-up periods. In a study of 61 cases of encapsulated follicular variant, lymph node metastases were observed in 5%, and there was no distant metastasis (486). With median follow-up of 11 years, one patient developed tumor recurrence, and this tumor had invasion. No adverse events were found in any of the encapsulated and noninvasive tumors, including 31 patients treated with lobectomy only. Similarly, no evidence of recurrence was found in 61 out of 62 encapsulated or well-circumscribed follicular variant of PTC in another series of patients with a median follow-up of 9.2 years, and the only case that developed recurrence had a positive resection margin after initial surgery (490). In another study of a cohort of thyroid tumors followed on average for 12 years, none of 66 patients with encapsulated follicular variant of papillary carcinoma died of disease (487). Despite a low probability, some patients with encapsulated follicular variants may present with distant metastases, particularly to the bones, or develop metastasis on follow-up (491,492). Tumors prone to metastatic behavior often have a thick capsule and significant intratumoral fibrosis, and virtually all of them reveal vascular invasion or invasion of the tumor capsule. Therefore, pathologic evaluation of these tumors should include microscopic examination of the entire tumor capsule to rule out invasion, as well as careful evaluation of the tumor to rule out the presence of poorly differentiated carcinoma areas or other unfavorable diagnostic features such as tumor necrosis or high (≥3 per 10 high-power fields) mitotic activity (493). In the absence of these features, a completely excised noninvasive encapsulated follicular variant of papillary carcinoma is expected to have a very low risk of recurrence or extrathyroidal spread, even in patients treated by lobectomy.

Similarly, excellent clinical outcomes are seen in FTCs that manifest only capsular invasion without vascular invasion (494–496). When vascular invasion is present, the tumor should no longer be designated as minimally invasive. However, some studies (456,494,497–500), although not all (496,501), suggest that only those follicular carcinomas that have a greater extent of vascular invasion (more than four foci of vascular invasion, or extracapsular vascular invasion) are associated with poorer outcomes.

Some histopathologic variants of thyroid carcinomas are important to recognize because of their association with familial tumor syndromes (41,502). The cribriform-morular variant of papillary carcinoma is frequently seen in patients with FAP due to a germline mutation in the adenomatous polyposis coli (*APC*) gene (503,504). It is characterized by a prominent cribriform architecture and formation of whorls or morules composed of spindle cells. The presence of aberrant β-catenin immunoreactivity provides a strong evidence for this tumor variant (505–507). Approximately 40% of patients with this variant of papillary carcinoma are found to have FAP, whereas the rest have no evidence of the inherited disease (505,508). Although no microscopic tumor features can distinguish between familial and sporadic disease, tumor multifocality is more common in the setting of the familial disease (505,508). Since many patients with the cribriform-morular variant have FAP, and thyroid cancer can precede clinically detectable colonic abnormalities in ~40% of patients (508), this diagnosis should raise the possibility of the familial disease and prompt consideration for colonic examination and genetic counseling.

Follicular carcinoma may develop as a manifestation of the PTEN hamartoma tumor syndrome, which is caused by a germline mutation in the *PTEN* gene (509–511). The histopathologic appearance of thyroid glands in these patients is very characteristic and should allow pathologists to suspect this syndrome (510,511). The glands typically have numerous sharply delineated, frequently encapsulated thyroid nodules that microscopically are well-delineated and cellular and have variable growth patterns (510–513). Individuals affected by this syndrome also have a high risk for benign and malignant tumors of the breast and endometrium, colon hamartomas, and others, and in light of the characteristic appearance of the thyroid gland in these patients, genetic counseling should be recommended.

Well-differentiated papillary and follicular cancers should be histologically distinguished from poorly differentiated carcinoma. Poorly differentiated carcinoma is an aggressive thyroid tumor characterized by a partial loss of the features of thyroid differentiation that occupies morphologically and behaviorally an intermediate position between well-differentiated papillary and follicular carcinomas and fully

Downloaded by Memorial Sloan Kettering from www.liebertpub.com at 08/14/19. For personal use only.

dedifferentiated anaplastic carcinoma. Another term used in the past for this tumor was ''insular carcinoma.'' Diagnostic criteria for poorly differentiated carcinoma are based on the consensus Turin proposal and include the following three features: (i) solid/trabecular/insular microscopic growth pattern, (ii) lack of well-developed nuclear features of papillary carcinoma, and (iii) convoluted nuclei (evidence for partial loss of differentiation in papillary cancer), tumor necrosis, or three or more mitoses per 10 high-power fields (514). Poorly differentiated carcinomas have significantly worse outcome as compared to well-differentiated PTC and FTC, with a 10-year survival of ~50% (514–516). Patient age over 45 years, larger tumor size, presence of necrosis, and high mitotic activity are additional factors that may influence a more unfavorable outcome in patients with poorly differentiated thyroid cancer (514,517). It is not clear if the proportion of poorly differentiated carcinoma areas within the cancer nodule directly correlates with prognosis. Several studies have reported similarly decreased survival in patients with poorly differentiated carcinoma constituting more than 50% of the tumor and in those in whom it was observed as a minor component (518,519). Tumors with insular, solid, or trabecular architecture, but lacking other diagnostic features of poorly differentiated carcinoma, do not demonstrate such an aggressive behavior and therefore should not be considered as poorly differentiated. On the other hand, some studies suggest that the presence of a high mitotic rate (≥5 mitoses/10 high-power fields or Ki-67 labeling index ≥4%) or tumor necrosis predicts a less favorable outcome irrespective of the presence of the solid/trabecular/insular growth pattern (520,521).

[B16] What is the role of postoperative staging systems and risk stratification in the management of DTC?

[B17] Postoperative staging

■ **RECOMMENDATION 47**

AJCC/UICC staging is recommended for all patients with DTC, based on its utility in predicting disease mortality, and its requirement for cancer registries.

(Strong recommendation, Moderate-quality evidence)

Postoperative staging for thyroid cancer, as for other cancer types, is used (i) to provide prognostic information, which is of value when considering disease surveillance and therapeutic strategies, and (ii) to enable risk-stratified description of patients for communication among health care professionals, tracking by cancer registries, and research purposes.

Accurate initial staging requires a detailed understanding of all pertinent risk stratification data, whether they were obtained as part of preoperative testing, during the operation(s), or as part of postoperative follow-up. It is also important to emphasize that in many cases the written pathology report of the surgical specimen does not convey critical risk factors such as preoperative vocal cord paralysis, extent of gross extrathyroidal invasion, completeness of resection, or remaining gross residual disease. Without these critical pieces of information, it is likely that initial risk stratification will be inaccurate and potentially misleading. Details and suggestions for effectively communicating specific risk factors between health care providers are outlined in a recent publication of the Surgical Affairs Committee of the ATA (440).

It is important to emphasize that the identification of a clinico-pathologic or molecular predictor of recurrence or mortality does not necessarily imply that more aggressive therapies (such as more extensive surgery, RAI therapy, aggressive thyroid hormone therapy with TSH suppression, targeted therapies) will have a significant impact on clinical outcomes. Similarly, the absence of a risk factor does not mean that more aggressive therapies are not indicated. Intervention studies are required to determine which at-risk-patients may benefit from additional therapies or a more conservative management approach. Until appropriate treatment intervention studies are completed, the risk stratification information associated with a clinico-pathologic risk factor or with a molecular profiling can be used as a prognostic factor to guide follow-up management decisions such as the type and frequency of imaging and biochemical testing.

[B18] AJCC/UICC TNM staging

Over the years, multiple staging systems have been developed to predict the risk of mortality in patients with DTC (522). Each of the systems uses some combination of age at diagnosis, size of the primary tumor, specific tumor histology, and extrathyroidal spread of the tumor (direct extension of the tumor outside the thyroid gland, loco-regional metastases, and/or distant metastases) to stratify patients into one of several categories with differing risks of death from thyroid cancer. Recently, a nomogram was developed and validated using the SEER data base, which provides a mathematical approach to integrating these important clinical predictive features into a specific mortality risk estimate for an individual patient (523). Using an approach similar to the MACIS system from the Mayo Clinic (270), a quantitative approach based on histology, age, lymph node metastases, tumor size, and extrathyroidal extension utilizing TNM staging has recently been proposed and validated (524,525)

While none of the staging systems has been shown to be clearly superior to the other systems, several studies have demonstrated that the AJCC/UICC TNM system (Table 10) and the MACIS system consistently provide the highest proportion of variance explained (PVE, a statistical measure of how well a staging system can predict the outcome of interest) when applied to a broad range of patient cohorts (277,501,526–530), and they have been validated in retrospective studies as well as prospectively in clinical practice.

Unfortunately, none of the staging systems designed to predict mortality from thyroid cancer can account for more than a small proportion (5%–30%, corresponding to PVE values of 0.05–0.30) of the uncertainty associated with eventual death from thyroid cancer (277,501,526–530). This relative inability to accurately predict the risk of death from thyroid cancer for an individual patient may be related to the failure of current staging systems to adequately integrate the risk associated with other potentially important clinicopathologic features such as the specific histology (well-differentiated thyroid cancer versus poorly differentiated thyroid cancer), molecular profile, size and location of distant metastases (pulmonary metastases versus bone metastases versus brain metastases), functional status of the metastases (RAI avid versus ^{18}FDG-PET avid), and effectiveness of initial therapy (completeness of resection, effectiveness of

Downloaded by Memorial Sloan Kettering from www.liebertpub.com at 08/14/19. For personal use only.

Downloaded by Memorial Sloan Kettering from www.liebertpub.com at 08/14/19. For personal use only.

Table 10. AJCC 7th Edition/TNM Classification System for Differentiated Thyroid Carcinoma

	Definition
T0	No evidence of primary tumor
T1a	Tumor ≤1 cm, without extrathyroidal extension
T1b	Tumor >1 cm but ≤2 cm in greatest dimension, without extrathyroidal extension
T2	Tumor >2 cm but ≤4 cm in greatest dimension, without extrathyroidal extension.
T3	Tumor >4 cm in greatest dimension limited to the thyroid ***or*** Any size tumor with minimal extrathyroidal extension (e.g., extension into sternothyroid muscle or perithyroidal soft tissues).
T4a	Tumor of any size extending beyond the thyroid capsule to invade subcutaneous soft tissues, larynx, trachea, esophagus, or recurrent laryngeal nerve.
T4b	Tumor of any size invading prevertebral fascia or encasing carotid artery or mediastinal vessels
N0	No metastatic nodes
N1a	Metastases to level VI (pretracheal, paratracheal, and prelaryngeal/Delphian lymph nodes).
N1b	Metastases to unilateral, bilateral, or contralateral cervical (levels I, II III, IV, or V) or retropharyngeal or superior mediastinal lymph nodes (level VII)
M0	No distant metastases
M1	Distant metastases

Patient age <45 years old at diagnosis			
I	Any T	Any N	M0
II	Any T	Any N	M1

Patient age ≥45 years old at diagnosis			
I	T1a	N0	M0
	T1b	N0	M0
II	T2	N0	M0
III	T1a	N1a	M0
	T1b	N1a	M0
	T2	N1a	M0
	T3	N0	M0
	T3	N1a	M0
IVa	T1a	N1b	M0
	T1b	N1b	M0
	T2	N1b	M0
	T3	N1b	M0
	T4a	N0	M0
	T4a	N1a	M0
	T4a	N1b	M0
IVb	T4b	Any N	M0
IVc	Any T	Any N	M1

Used with the permission of the American Joint Committee on Cancer (AJCC), Chicago, Illinois. The original source for this material is the AJCC Cancer Staging Manual, Seventh Edition (1077) published by Springer Science and Business Media LLC (http://www.springer.com).

RAI, external beam radiation therapy or other systemic therapies). Furthermore, recent studies have questioned the use of the age of 45 years as a cutoff to upstage patients using the AJCC/UICC TNM system (340,531–533).

Even though the various staging systems designed to predict mortality from thyroid cancer were developed and validated using cohorts that were either exclusively or predominantly PTC patients, several small studies have demonstrated that MACIS and AJCC/UICC TNM staging systems were also predictive in patients with FTC (501,534,535).

Currently, none of the mortality risk systems incorporate molecular testing results. This may need to be re-evaluated as studies emerge using molecular testing including *BRAF*^{V600E}, *TERT*, and *TP53* or combinations of markers. For example, in one study that analyzed more than 400 DTCs, the presence of a *TERT* mutation was found to be an independent predictor of mortality (hazard ratio [HR] 10.35 [95% CI 2.01–53.24]) for all differentiated cancers and for papillary carcinomas (154). These potential prognostic markers are promising, but require further study.

[B19] What initial stratification system should be used to estimate the risk of persistent/recurrent disease?

■ RECOMMENDATION 48

(A) The 2009 ATA Initial Risk Stratification System is recommended for DTC patients treated with thyroidectomy, based on its utility in predicting risk of disease recurrence and/or persistence.

(Strong recommendation, Moderate-quality evidence)

(B) Additional prognostic variables (such as the extent of lymph node involvement, mutational status, and/or the degree of vascular invasion in FTC), not included in the 2009 ATA Initial Risk Stratification system may be used to further refine risk stratification for DTC as described in the following text (and in Fig. 4) in the Modified Initial Risk Stratification system. However, the incremental benefit of adding these specific prognostic variables to the 2009 Initial Risk Stratification system has not been established.

(Weak recommendation, Low-quality evidence)

(C) While not routinely recommended for initial postoperative risk stratification in DTC, the mutational status of *BRAF*, and potentially other mutations such as *TERT*, have the potential to refine risk estimates when interpreted in the context of other clinico-pathologic risk factors.

(Weak recommendation, Moderate-quality evidence)

Because the AJCC/TNM risk of mortality staging system does not adequately predict the risk of recurrence in DTC (536–539), the 2009 version of the ATA thyroid cancer guidelines proposed a three-tiered clinico-pathologic risk stratification system that classified patients as having low, intermediate, or high risk of recurrence (25). Low-risk patients were defined as having intrathyroidal DTC with no evidence of extrathyroidal extension, vascular invasion, or metastases. Intermediate-risk patients demonstrated either microscopic extrathyroidal extension, cervical lymph node metastases, RAI-avid disease in the neck outside the thyroid

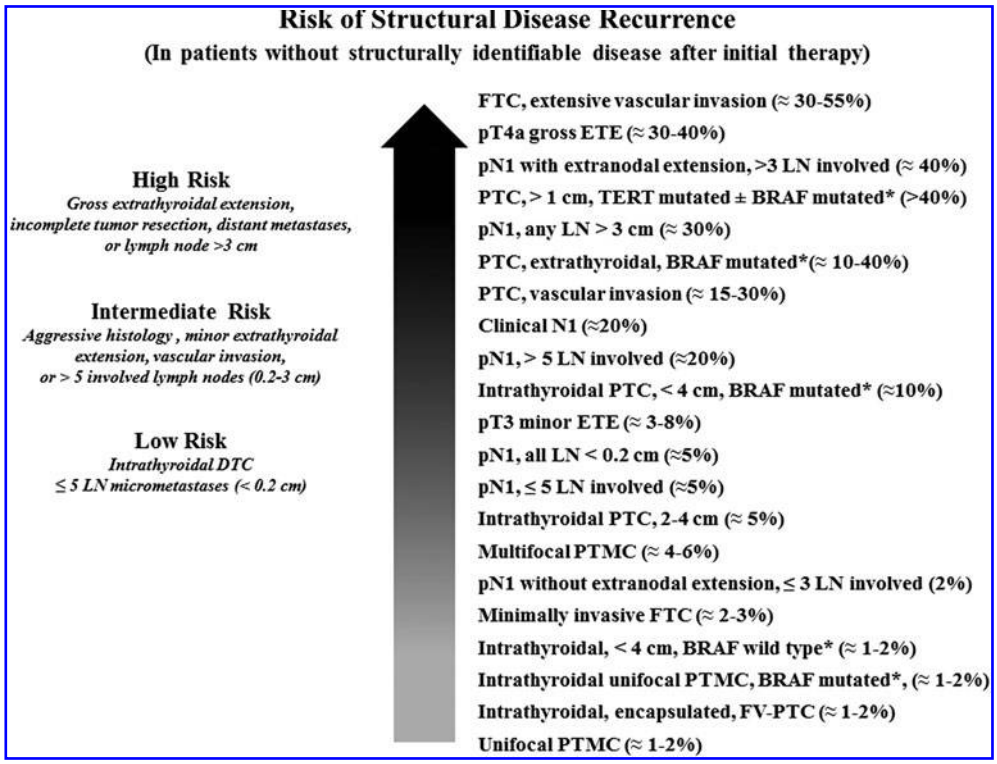

FIG. 4. Risk of structural disease recurrence in patients without structurally identifiable disease after initial therapy. The risk of structural disease recurrence associated with selected clinico-pathological features are shown as a continuum of risk with percentages (ranges, approximate values) presented to reflect our best estimates based on the published literature reviewed in the text. In the left hand column, the three-tiered risk system proposed as the Modified Initial Risk Stratification System is also presented to demonstrate how the continuum of risk estimates informed our modifications of the 2009 ATA Initial Risk System (see Recommendation 48). *While analysis of *BRAF* and/or *TERT* status is not routinely recommended for initial risk stratification, we have included these findings to assist clinicians in proper risk stratification in cases where this information is available. FTC, follicular thyroid cancer; FV, follicular variant; LN, lymph node; PTMC, papillary thyroid microcarcinoma; PTC, papillary thyroid cancer.

Downloaded by Memorial Sloan Kettering from www.liebertpub.com at 08/14/19. For personal use only.

bed, vascular invasion, or aggressive tumor histology. High-risk patients had gross extrathyroidal extension, incomplete tumor resection, distant metastases, or inappropriate postoperative serum Tg values (Table 11).

The 2009 ATA risk stratification system was somewhat different than staging systems proposed by a European Consensus conference (540) and the Latin American Thyroid Society (LATS) (541) which classify patients as either being at very low risk (unifocal, intrathyroidal T1aN0M0), low risk (T1b N0M0, T2N0M0, or multifocal T1N0M0,), or high risk (any T3 or T4, any N1, or any M1). The European and LATS very low risk and low risk categories would be classified as ATA low risk, while the ETA high risk category would be subdivided between ATA intermediate risk (minor extrathyroidal extension, N1 disease) and ATA high risk (gross extrathyroidal extension, M1, incomplete tumor resection).

Subsequent studies have retrospectively validated the 2009 ATA risk of recurrence staging system through analysis of independent datasets originating from three respective continents (Table 12). These studies have reported the estimates of patients who subsequently had no evidence of disease (NED) in each ATA Risk Category after total thyroidectomy and RAI remnant ablation: (a) low risk, 78%–91% NED, (b) intermediate risk, 52%–64% NED, and (c) high risk, 31%–32% NED (538,539,542,543). In these datasets, NED was defined as a stimulated Tg <1 ng/mL with no other radiological or clinical evidence of disease. Prospectively collected validation data for the ATA initial risk stratification system are needed.

Three additional studies, in which the ATA risk classification system was retrospectively evaluated, have also suggested that the ATA risk of recurrence model may be applied in low- and intermediate-risk patients in the absence of RAI remnant ablation (328,544,545). Over a median follow-up period that ranged from 5 to 10 years, structural disease recurrence was identified in less than 1%–2% of ATA low-risk patients and 8% of ATA intermediate-risk patients who underwent thyroid surgery without RAI ablation as the initial therapy (328,544,545).

The type of persistent disease also varies according to ATA initial risk stratification, with 70%–80% of the persistent disease in ATA low-risk patients manifested by abnormal serum Tg levels (suppressed or stimulated Tg >1 ng/mL) without structurally identifiable disease, while only 29%–51% of the ATA intermediate-risk patients and 19%–21% of ATA high-risk patients are classified as having persistent disease only on the basis of biochemical abnormalities (538,539,543). With increasing ATA risk level, the RR of having structural persistent/recurrent disease increases. Thus, the ATA low-risk patients appear to have the highest RR of

Table 11. ATA 2009 Risk Stratification System with Proposed Modifications

ATA low risk	Papillary thyroid cancer (with all of the following): • No local or distant metastases; • All macroscopic tumor has been resected • No tumor invasion of loco-regional tissues or structures • The tumor does not have aggressive histology (e.g., tall cell, hobnail variant, columnar cell carcinoma) • If ^{131}I is given, there are no RAI-avid metastatic foci outside the thyroid bed on the first posttreatment whole-body RAI scan • No vascular invasion • Clinical N0 or ≤5 pathologic N1 micrometastases (<0.2 cm in largest dimension)[a] Intrathyroidal, encapsulated follicular variant of papillary thyroid cancer[a] Intrathyroidal, well differentiated follicular thyroid cancer with capsular invasion and no or minimal (<4 foci) vascular invasion[a] Intrathyroidal, papillary microcarcinoma, unifocal or multifocal, including *BRAF*^{V600E} mutated (if known)[a]
ATA intermediate risk	Microscopic invasion of tumor into the perithyroidal soft tissues RAI-avid metastatic foci in the neck on the first posttreatment whole-body RAI scan Aggressive histology (e.g., tall cell, hobnail variant, columnar cell carcinoma) Papillary thyroid cancer with vascular invasion Clinical N1 or >5 pathologic N1 with all involved lymph nodes <3 cm in largest dimension[a] Multifocal papillary microcarcinoma with ETE and *BRAF*^{V600E} mutated (if known)[a]
ATA high risk	Macroscopic invasion of tumor into the perithyroidal soft tissues (gross ETE) Incomplete tumor resection Distant metastases Postoperative serum thyroglobulin suggestive of distant metastases Pathologic N1 with any metastatic lymph node ≥3 cm in largest dimension[a] Follicular thyroid cancer with extensive vascular invasion (> 4 foci of vascular invasion)[a]

[a]Proposed modifications, not present in the original 2009 initial risk stratification system. See sections [B19]–[B23] and Recommendation 48B.

isolated thyroglobulinemia, which may be of less clinical significance than structural disease persistence or recurrence.

Similar to what was seen with the staging systems designed to predict risk of mortality from thyroid cancer (see section [B18] above), the PVE by the ATA risk of recurrence system was suboptimal, ranging from 19% to 34% (538,542). More recently, a novel mathematical clinico-pathologic staging system from the University of Yonsei yielded similar results with a PVE of 11.9% in predicting disease recurrence (546).

[B20] Potential impact of specific clinico-pathologic features on the risk estimates in PTC

As originally conceived, the ATA initial risk stratification system was a three-tiered system in which clinico-pathologic features available at the time of initial treatment were used to classify DTC patients as having either low, intermediate, or high risk of either recurrence or persistent disease. However, as with any categorical staging system, the risk of recurrence within the individual risk categories (low, intermediate, and

Table 12. American Thyroid Association Risk Stratification System: Clinical Outcomes Following Total Thyroidectomy and Radioiodine Remnant Ablation or Adjuvant Therapy

ATA risk	*Study*	*NED, %*	*Biochemical incomplete, %*[b]	*Structural incomplete, %*[c]
Low	Tuttle *et al.* (538)	86	11	3
	Castagna *et al.* (542)	91	ND[a]	ND[a]
	Vaisman *et al.* (539)	88	10	2
	Pitoia *et al.* (543)	78	15	7
Intermediate[a]	Tuttle *et al.* (538)	57	22	21
	Vaisman *et al.* (539)	63	16	21
	Pitoia *et al.* (543)	52	14	34
High	Tuttle *et al.* (538)	14	14	72
	Vaisman *et al.* (539)	16	12	72
	Pitoia *et al.* (543)	31	13	56

[a]Because the ATA intermediate- and high-risk groups were merged into a single ''high-risk'' group in the series by Castagna *et al.* (542), risk of persistent/recurrent disease for these subgroups is not presented.

[b]Proportion of patients with a biochemical incomplete response. *Definition:* suppressed Tg >1 ng/mL, TSH-stimulated Tg >10 ng/mL, or rising anti-Tg antibody levels in the absence of structural disease.

[c]Proportion of patients with persistent/recurrent disease that is structural. *Definition:* structural disease that is either biopsy-proven or highly suspicious for disease with or without abnormal serum Tg.

ND, not determined.

Downloaded by Memorial Sloan Kettering from www.liebertpub.com at 08/14/19. For personal use only.

high) can vary depending on the specific clinical features of individual patients (Fig. 4). In addition, the three-tiered system did not specifically address the risk of recurrence associated with specific DTC histologies, multifocality, genotype, extent of vascular invasion, or extent of metastatic lymph node involvement.

For example, while intrathyroidal PTCs of all sizes are included in the ATA low-risk category, the risk of structural disease recurrence can vary from 1%–2% in unifocal papillary microcarcinomas, to 4%–6% in multifocal papillary microcarcinomas (141,147), to 5%–6% in 2–4 cm intrathyroidal PTC (547), and 8%–10% in intrathyroidal PTC >4 cm (547). Similarly, while all DTC patients with locoregional lymph node metastases were classified as having intermediate risk in the 2009 ATA risk stratification system, the risk of structural disease recurrence can vary from 4% in patients with fewer than five metastatic lymph nodes, to 5% if all involved lymph nodes are <0.2 cm, to 19% if more than five lymph nodes are involved, to 21% if more than 10 lymph nodes are involved, to 22% if macroscopic lymph node metastases are clinically evident (clinical N1 disease), and 27%–32% if any metastatic lymph node is >3 cm (335,548). These risk estimates apply to both N1a and N1b disease because there are insufficient data to determine risk based on location within the neck independent of size, number of involved nodes, and extranodal extension. It is very likely that these risk estimates could vary depending on the types and extent of nodal dissections done in individual patients. As defined by the ATA surgical affairs committee task force on thyroid cancer nodal surgery, ≤5 pN1 micrometastases (<0.2 cm in largest dimension) are classified as lower risk N1 disease (<5% risk of recurrence) (335). Clinical N1 disease, more than five metastatic lymph nodes, or any metastatic lymph node >3 cm in largest dimension are classified as higher risk N1 disease (>20% risk of recurrence) (335). Identification of extranodal extension of the tumor through the metastatic lymph node capsule has also been associated with an increased risk of recurrent/persistent disease (338,450). It is difficult to estimate the risk associated with extension of the tumor through the capsule of involved lymph nodes because this histologic finding is tightly linked with both the number of involved lymph nodes (338,450) and invasion of the tumor through the thyroid capsule (450,549).

It is also important to differentiate the clinical significance of minor extrathyroidal extension (ATA intermediate risk) from gross extrathyroidal invasion of surrounding structures (ATA high risk). The risk of recurrence associated with minor extrathyroidal extension (pT3 disease manifest by minimal extrathyroidal extension) ranges from 3% to 9% (550–554), while the risk of recurrence in patients with gross extrathyroidal extension (pT4a disease involving the subcutaneous soft tissues, larynx, trachea, esophagus, or RLN) ranges from 23% to 40% (537,550,552–555).

The encapsulated follicular variant of papillary thyroid carcinoma also appears to be associated with a low 10-year risk of recurrence (486,490,556). Only two recurrences were reported in the 152 patients (1.3% risk of recurrence) described in these three reports. No recurrences were described in the 42 patients that had encapsulated FVPTC without capsular or lymphovascular invasion in the series by Liu *et al.* (486). However, the study by Baloch *et al.* (556) included a single patient with encapsulated FVPTC that developed bone metastasis despite not having lymphovascular invasion or lymph node metastases identified at the time of diagnosis. Therefore, intrathyroidal FVPTC is best classified as a low-risk tumor that is unlikely to recur or metastasize.

Well-differentiated FTCs demonstrating only capsular invasion (without vascular invasion) usually have an excellent prognosis with recurrence rates of 0%–7% and can be classified as low-risk tumors (494–496). Encapsulated, minimally invasive FTC with only minor vascular invasion (small number of foci confined to intracapsular vessels) also appears to have a low recurrence rate of approximately 0%–5% (456,500). Furthermore, some studies (456,494,497–500), but not all (496,501), suggest a greater extent of vascular invasion (more than four foci of vascular invasion, or extracapsular vascular invasion) is associated with poorer outcomes even in encapsulated FTCs. However, FTC is considered ATA high risk if extensive vascular invasion is present because the risk of the development of newly identified distant metastases is as high as 30%–55% (455,494,497,500).

In PTC, most (451–453,558–561), but not all (562) studies demonstrate that vascular invasion is associated with worse clinical outcomes. Recurrence rates were significantly higher if vascular invasion was present in the studies by Gardner *et al.* (16%–20% with vascular invasion, 3%–6% without), Nishida *et al.* (28% with vascular invasion, 15% without), and Falvo *et al.* (30% with vascular invasion, 5% without), but not in the studies by Furlan *et al.* (562) or Akslen *et al.* (559). Vascular invasion in PTC was also associated with higher rates of distant metastases (453,561) and disease-specific mortality (559,560).

[B21] Potential impact of BRAF^{V600E} *and other mutations on risk estimates in PTC*

In a pooled univariate analysis of 1849 PTC patients, the presence of a *BRAF*^{V600E} mutation was associated with increased disease-specific mortality, although this was not significantly associated with mortality in a multivariate analysis (370). However, a significant interaction between *BRAF*^{V600E} mutation and several conventional clinicopathological risk factors was seen, such that the risk of mortality was higher in patients with *BRAF* mutation compared to those with wild-type *BRAF* in the setting of lymph node metastases (11.1% vs. 2.6%, $p < 0.001$), distant metastases (51.5% vs. 18.2%, $p < 0.001$), AJCC stage IV disease (31.4% vs. 13%, p0.004), and age ≥45 years at diagnosis (8% vs. 1.9%, $p < 0.001$). In a systematic review and meta-analysis of 14 publications that included 2470 PTC patients from nine different countries, the *BRAF*^{V600E} mutation was associated with a significantly higher risk of recurrence than *BRAF* wild-type tumors (24.9% vs. 12.6%, $p < 0.00001$ [95% CI 1.61–2.32]) (563). In the studies included in this meta-analysis, the risk of recurrence in *BRAF*^{V600E}-positive tumors ranged from 11% to 40% (median 26.5%), while the risk of recurrence in *BRAF* wild-type tumors ranged from 2% to 36% (median 9.5%). Because the *BRAF*^{V600E} mutation is tightly linked with the presence of aggressive histologic phenotypes, lymph node metastases, and extrathyroidal extension, it is difficult to determine the proportion of risk that is attributable to the *BRAF* mutation versus that attributable to the other clinico-pathologic features. Some studies (564,565), but not all (566–568), have demonstrated that the *BRAF*^{V600E} mutation is an independent predictor of risk of

Downloaded by Memorial Sloan Kettering from www.liebertpub.com at 08/14/19. For personal use only.

Downloaded by Memorial Sloan Kettering from www.liebertpub.com at 08/14/19. For personal use only.

recurrence in multivariate analysis. Furthermore, a recent publication demonstrated a small, but statistically significant improvement in risk stratification if *BRAF* status was used in conjunction with the 2009 ATA initial risk stratification system (569). In a meta-analysis of 2167 patients, the presence of a $BRAF^{V600E}$ mutation had a sensitivity of 65% in identifying those tumors that subsequently recurred, but had a PPV of only 25% in predicting the risk of recurrence (563). Unlike previous studies that were often small and primarily single-institution reports, a large multicenter pooled-data evaluation of 2099 patients (1615 women, 484 men, median age 45 years) demonstrated that the $BRAF^{V600E}$ mutation was significantly associated with the risk of recurrence in both classical PTC (20.7% vs. 12.4%, HR 1.46 [95% CI 1.08–1.99] after adjustment for multiple clinico-pathological features), and FVPTC (21.3% vs. 7.0%, HR 3.20 [95% CI 1.46–7.02] after adjustment for multiple clinico-pathological features). Based on these data, it appears that the *BRAF* status in isolation is not sufficient to substantially contribute to risk stratification in most patients. However, an incremental improvement in risk stratification can be achieved if the *BRAF* mutational status is considered in the context of other standard clinico-pathological risk factors. Since the clinical implications of this incremental improvement in risk stratification are not clear, we are not routinely recommending *BRAF* mutational evaluation for initial postoperative risk stratification in DTC.

The potential role of *BRAF* status in isolation as an aid to risk stratification in patients clinico-pathologically classified as having ATA low risk is currently being evaluated. In a cohort of low-risk patients with intrathyroidal PTC (<4 cm, N0, M0; 33% with *BRAF* mutation), the overall risk of having structural disease recurrence over 5 years of follow up was 3% (565). However, $BRAF^{V600E}$-mutated tumors had a recurrence rate of 8% (8 of 106) compared with only 1% (2 of 213) in *BRAF* wild-type tumors ($p = 0.003$, Fisher's exact). Furthermore, in multivariate analysis, the only clinico-pathological significant predictor of persistent disease after 5 years of follow-up was the presence of a $BRAF^{V600E}$ mutation. If these findings are verified in additional studies, it is possible that *BRAF* testing could be used to help further risk stratify patients with intrathyroidal PTC as having very low risk of recurrence (*BRAF* wild-type) or intermediate risk of recurrence ($BRAF^{V600E}$ mutation).

The impact of *BRAF* status on the risk of recurrence in the very low-risk patients (intrathyroidal unifocal papillary microcarcinomas <1 cm) appears to be small. Even though *BRAF* mutation is present in 30%–67% of papillary microcarcinomas (152,153,156,566,570–576), the overall clinical recurrence rate is quite low, ranging from 1% to 6% (274,566). In a series of 99 papillary microcarcinoma patients with an overall recurrence rate of 7%, no recurrences were detected in the patients with a $BRAF^{V600E}$ mutation and intrathyroidal, unifocal tumors. Conversely, $BRAF^{V600E}$-mutated multifocal PTMC with extrathyroidal extension demonstrated a 20% recurrence rate (150). Therefore, in the absence of data demonstrating that the $BRAF^{V600E}$ mutation is associated with increased structural recurrence in very low-risk tumors, we have classified intrathyroidal papillary microcarcinomas (T1a, N0, M0) harboring $BRAF^{V600E}$ mutations with no other worrisome features (such as extrathyroidal extension, aggressive histology, vascular invasion, or lymph node metastases) as ATA low-risk tumors. The few patients (about 10% of PTMC patients) that demonstrate multifocal PTMC with extrathyroidal invasion and a $BRAF^{V600E}$ mutation would be considered as having ATA intermediate risk for recurrence. Based on these data, there appears to be little role for *BRAF* mutational testing as an aid to risk stratification in PTMC tumors that do not demonstrate other worrisome clinico-pathologic features.

More recent data suggest that aggressive behavior of a given thyroid carcinoma, including high probability of tumor recurrence, is likely when it harbors more than one known oncogenic mutation, and specifically a *BRAF* mutation co-occurring with a *TERT* promoter, *PIK3CA*, *TP53*, or *AKT1* mutation (155–157,577). Such a combination of several mutations is seen in a much smaller fraction of PTC as compared with a 40%–45% incidence of *BRAF* mutations and is expected to serve as a more specific marker of unfavorable outcomes of PTC.

Two other molecular markers that appear to confer an increased risk of tumor recurrence and tumor-related mortality are *TP53* and *TERT* mutations. *TP53* mutations have been known to occur mostly in poorly differentiated and anaplastic thyroid cancers. However, more recent broad mutational analyses identified *TP53* mutations in 2 of 57 (3.5%) well-differentiated PTC and 4 of 36 (11%) of well-differentiated FTC (578). Both PTCs in this series that were positive for *TP53* mutations also showed mutations in *BRAF* (or *BRAF* and *PIK3CA*) and developed lung metastases. All four *TP53*-positive FTC (with no other coexisting mutations) were oncocytic, and three out of four of those were widely invasive FTC.

Finally, recent studies identified *TERT* promoter mutations as a likely predictor of more unfavorable outcomes for patients with thyroid cancer. *TERT* mutations were found in 7%–22% of PTC and 14%–17% of FTC, but with a significantly higher prevalence in dedifferentiated thyroid cancers (154,579–581). In some (154,579), but not all (580) reports, *TERT* mutations were found more often in PTC carrying a *BRAF* mutation. In the largest reported series (332 PTC and 70 FTC followed on average for 8 years), a *TERT* mutation was an independent predictor of disease-free survival (odds ratio [OR] 4.68 [95% CI 1.54–14.27]) and mortality (HR 10.35 [95% CI 2.01–53.24]) for well-differentiated thyroid cancer (154). Furthermore, the combination of a *TERT* mutation and a *BRAF* mutation within the same tumor was associated with a high risk of structural disease recurrence (155). These results, although pending confirmation in other studies, suggest that these molecular markers, alone or in combination, may be helpful for risk stratification of thyroid cancer and provide significantly more accurate risk assessment than *BRAF* mutational status taken in isolation.

[B22] Potential impact of postoperative serum Tg on risk estimates

Several studies have demonstrated the clinical utility of a serum Tg measurement (either TSH stimulated or non-stimulated) obtained a few weeks after total thyroidectomy (postoperative Tg) and before RAI remnant ablation as a tool to aid in initial risk stratification and adjuvant therapy decision-making (See Recommendations 50B and 50C). Please see section [C6] for discussion of Tg measurements.

[B23] Proposed modifications to the 2009 ATA initial risk stratification system

While the 2009 risk stratification system has proven to be a valuable tool for initial risk stratification in PTC, modifications are required to better incorporate our new understanding regarding the risks associated with the extent of lymph node involvement, mutational status, and specific FTC histologies (Table 11). While the modified 2009 risk stratification system continues to classify intrathyroidal PTC without vascular invasion as low risk, the category was expanded to include patients with small-volume lymph node metastases (clinical N0 or ≤5 pathologic N1 micrometastases, <0.2 cm in largest dimension), intrathyroidal encapsulated follicular variant of PTC, intrathyroidal well-differentiated follicular cancer with capsular or minor vascular invasion (<4 vessels involved), and intrathyroidal papillary microcarcinomas that are either *BRAF* wild-type or *BRAF* mutated. Similarly, the modified 2009 intermediate-risk category continues to include patients with microscopic invasion of the tumor into perithyroidal soft tissues, vascular invasion, uptake outside the thyroid bed at the time of remnant ablation, and aggressive histologies, but it has been modified to include only a subset of patients with lymph node metastases (clinical N1 or >5 pathologic N1 with all involved lymph nodes <3 cm in largest dimension and multifocal papillary microcarcinoma with extrathyroidal extension and *BRAF* mutated (if known). Finally, the high-risk category continues to include patients with macroscopic extrathyroidal extension, incomplete tumor resection, distant metastases, and postoperative serum Tg suggestive of distant metastases, but it has been expanded to include patients with large-volume lymph node involvement (any metastatic lymph node ≥3 cm in largest dimension), and FTC with extensive vascular invasion (>4 foci of vascular invasion or extracapsular vascular invasion). While these modifications are based on our current literature review of the impact of the individual risk factors, future studies will be required to validate this proposed modification to determine if the additional modifying factors provide significant incremental improvement in risk stratification.

[B24] Risk of recurrence as a continuum of risk

While the ATA initial risk stratification system provides a meaningful and valuable tool for predicting risk of recurrence when used as a three-tiered categorical staging system, additional insights can be gained if one appreciates that the risk of structural disease recurrence is a continuum of risk that ranges from <1% in very low-risk patients to >50% in high-risk patients (see Fig. 4). Therefore, individualized management recommendations should be based not only on the categorical risk of recurrence estimate, but also on a more individualized estimate of risk in which the ATA low- and intermediate-risk categories are further characterized on the basis of respective clinical or pathologic features, such as the size of the primary tumor, number and size of locoregional lymph node metastases (as well as extranodal extension), specific histologic variant, vascular invasion, extent of extrathyroidal extension, or other potentially important factors.

While the risk estimates presented in this section may be useful in guiding initial treatment selections (extent of initial surgery, need for RAI ablation), it is important to recognize that these risk estimates likely reflect not only the tumor biology, but also the impact of initial therapy, which varies from thyroid lobectomy to total thyroidectomy with varying extents of lymph node dissection, either with or without RAI ablation, across the various studies. Additional studies are needed to better define the risk of recurrence in most of these clinical scenarios in patients randomized to receive one of several initial treatment options (lobectomy versus total thyroidectomy, extent of lymph node dissection, with or without RAI ablation).

[B25] How should initial risk estimates be modified over time?

■ **RECOMMENDATION 49**

Initial recurrence risk estimates should be continually modified during follow-up, because the risk of recurrence and disease-specific mortality can change over time as a function of the clinical course of the disease and the response to therapy.

(Strong recommendation, Low-quality evidence)

While initial staging systems provide important insights into an individual patient's risk of recurrence and disease-specific mortality, they provide static, single-point estimates of risk based only on data available at the time of initial therapy. None of the currently available initial staging systems are capable of using new data obtained during the course of follow-up to modify the initial risk estimate. For example, an ATA low-risk patient that demonstrates a rising serum Tg associated with cervical lymphadenopathy highly suspicious for recurrent disease at some point during follow-up would still be classified as ATA low risk despite the presence of clinical data demonstrating a high risk of recurrence. Conversely, an ATA high-risk patient that remains NED over 30 years of appropriate follow-up would still be classified as ATA high risk despite having a risk of recurrence that is significantly lower than would have been predicted at the time of initial therapy.

Therefore, while the initial staging systems can be informative in guiding therapeutic and early diagnostic follow-up strategy decisions, a risk stratification system that incorporates individual response to therapy into a real-time, dynamic risk stratification scheme is needed to provide an individualized approach to ongoing management (582,583). One approach that has been proposed is to use the risk estimates from the initial staging systems to guide initial management recommendations and then to incorporate a response-to-therapy assessment during follow-up to modify these initial risk estimates in an ongoing, dynamic process (584).

Multiple studies have now shown that many patients initially classified as intermediate or high risk of recurrence using initial staging systems can be reclassified as having a subsequent low risk of recurrence based on having an excellent response to initial therapy (538,539,542,586–601). Furthermore, the PVE values associated with staging systems that incorporated response-to-therapy variables into revised risk estimates were significantly higher (62%–84%) than those seen with initial staging systems (<30%) (538,542). These data indicate that long-term outcomes can be more reliably predicted using systems that adjust to new data over time.

Downloaded by Memorial Sloan Kettering from www.liebertpub.com at 08/14/19. For personal use only.

[B26] Proposed terminology to classify response to therapy and clinical implications

All clinical, biochemical, imaging (structural and functional), and cytopathologic findings obtained during follow-up should be used to redefine the clinical status of the patient and to assess their individual response to therapy. Ideally, the global consideration of the composite findings of such an assessment would allow for the disease status to be classified into one of several discrete *response to therapy* risk strata as proposed by Tuttle *et al.* (538,582). Potential challenges in applying this specific system in routine clinical practice include lack of validation in specific subgroups of patients (such as those who had less than total thyroidectomy or those not treated with RAI), the lack of published prospective data utilizing this system in clinical care, and some inconsistency with other authors in classifying the significance of varying levels of detectable Tg levels or imaging findings.

The response to therapy restaging system was also not designed or specifically tested by developers to guide specific therapeutic decisions on primary therapy (such as use of adjuvant treatment) because it has been designed for use after primary therapy is completed. Prospective studies of the value of this system for guiding extent of primary treatment, including adjuvant treatment decisions, are needed. However, given that there is emerging evidence that such a reclassification system has potential to be of great importance in ongoing clinical care of DTC patients after primary treatment, the details are described herein.

It is acknowledged that appropriate clinical application of such a system is highly dependent on the availability of high-quality biochemical testing and structural, and functional imaging with appropriate interpretation (e.g., standardized radiologic reporting). Therefore, applicability may be limited in settings where these procedures are not available or feasible.

The concept and initial validation of the four response-to-therapy categories presented here were described by Tuttle *et al.* (538) and modified in Vaisman *et al.* (328). As originally conceived, these clinical outcomes described the best response to initial therapy during the first 2 years of follow-up (538,582), but they are now being used to describe the clinical status at any point during follow-up.

- **Excellent response:** no clinical, biochemical, or structural evidence of disease
- **Biochemical incomplete response:** abnormal Tg or rising anti-Tg antibody levels in the absence of localizable disease. Please see section [C6] for discussion of Tg measurements.
- **Structural incomplete response:** persistent or newly identified loco-regional or distant metastases
- **Indeterminate response:** nonspecific biochemical or structural findings that cannot be confidently classified as either benign or malignant. This includes patients with stable or declining anti-Tg antibody levels without definitive structural evidence of disease.

The majority of published studies examining response to therapy in DTC have been performed in populations of patients whose primary treatment consisted of total thyroidectomy and RAI ablation. While the following sections will provide the details of multiple studies examining response to therapy, a simplified overview of the clinical implications of the response-to-therapy reclassification system in patients treated with total thyroidectomy and RAI ablation, based on the research from Tuttle *et al.* (538,539) and supported by other studies, is described in Table 13. Specific suggestions with regard to the application of response-to-therapy assessments in patients treated with total thyroidectomy without RAI ablation or with thyroid lobectomy have recently been published by Momesso *et al.* (602).

[B27] Excellent response: no clinical, biochemical, or structural evidence of disease after initial therapy (remission, NED)

These patients have no clinical, biochemical, or structural evidence of disease identified on risk-appropriate follow-up studies (Table 13). If a total thyroidectomy and RAI ablation were done, an excellent response was usually defined as a TSH-stimulated Tg of <1 ng/mL in the absence of structural or functional evidence of disease (and in the absence of anti-Tg antibodies) (538,539,542,586–601). An excellent response to initial therapy is achieved in 86%–91% of ATA low-risk patients, 57%–63% of ATA intermediate-risk patients, and 14%–16% of ATA high-risk patients (538,539,542).

In 20 retrospective studies, the risk of recurrence over 5–10 years of follow-up ranged from 1% to 4% (median 1.8%) in patients who had an excellent response to therapy by 6–18 months after total thyroidectomy and RAI remnant ablation (538,539,542,586–601,603).

The potential impact of this reclassification is the most dramatic in the two-thirds of ATA intermediate-risk patients who achieve an excellent response and therefore have their risk of having recurrent/persistent disease decreased from 36%–43% (predicted by initial ATA risk stratification) to 1%–2% (predicted by response-to-therapy reclassification) (538,539). Because of the very low risk of structural disease recurrence in ATA low risk patients (1%–3%), reclassification based on an excellent response to therapy has less practical implications than in the intermediate- and high-risk patients.

While many of the studies reviewed primarily low-risk DTC patients (586,588,595–598,601), the same low risk of recurrence following achievement of excellent response to therapy was seen in other studies that had substantial numbers of intermediate-risk patients (538,539,542,587,591,592,604). Furthermore, most studies also demonstrate that the few high-risk patients that achieve an excellent response to therapy also have subsequent recurrence rates in the 1%–2% range (542,593,594,600). The one exception is the 14% risk of recurrence seen in the few ATA high-risk patients that achieved remission in a series from Memorial Sloan-Kettering Cancer Center (538), which is likely due to the known referral bias of unusual and very high-risk cases. Nonetheless, high-risk patients that achieve an excellent response to therapy may require somewhat more intense follow-up than ATA low- and intermediate-risk patients demonstrating an excellent response to therapy. It is important to note that patients at intermediate to high risk of recurrence may require additional structural or functional imaging to rule out disease that may not be detected by US and Tg measurements prior to being classified as having an excellent response (602). The details for choice of follow-up tests are found in another section of these guidelines [C4–C13], (Figs. 5–8).

Downloaded by Memorial Sloan Kettering from www.liebertpub.com at 08/14/19. For personal use only.

Table 13. Clinical Implications of Response to Therapy Reclassification in Patients with Differentiated Thyroid Cancer Treated with Total Thyroidectomy and Radioiodine Remnant Ablation

Category	*Definitions*[a]	*Clinical outcomes*	*Management implications*
Excellent response	Negative imaging ***and either*** Suppressed Tg <0.2 ng/mL[b] ***or*** TSH-stimulated Tg <1 ng/mL[b]	1%–4% recurrence[c] <1% disease specific death[c]	An excellent response to therapy should lead to an early decrease in the intensity and frequency of follow up and the degree of TSH suppression
Biochemical incomplete response	Negative imaging ***and*** Suppressed Tg ≥1 ng/mL[b] ***or*** Stimulated Tg ≥10 ng/mL[b] ***or*** Rising anti-Tg antibody levels	At least 30% spontaneously evolve to NED[d] 20% achieve NED after additional therapy[a] 20% develop structural disease[a] <1% disease specific death[a]	If associated with stable or declining serum Tg values, a biochemical incomplete response should lead to continued observation with ongoing TSH suppression in most patients. Rising Tg or anti-Tg antibody values should prompt additional investigations and potentially additional therapies.
Structural incomplete response	Structural or functional evidence of disease With any Tg level With or without anti-Tg antibodies	50%–85% continue to have persistent disease despite additional therapy[e] Disease specific death rates as high as 11% with loco-regional metastases and 50% with structural distant metastases[a]	A structural incomplete response may lead to additional treatments or ongoing observation depending on multiple clinico-pathologic factors including the size, location, rate of growth, RAI avidity, ^{18}FDG avidity, and specific pathology of the structural lesions.
Indeterminate response	Nonspecific findings on imaging studies Faint uptake in thyroid bed on RAI scanning Nonstimulated Tg detectable, but <1 ng/mL Stimulated Tg detectable, but <10 ng/mL ***or*** Anti-Tg antibodies stable or declining in the absence of structural or functional disease	15%–20% will have structural disease identified during follow-up[a] In the remainder, the nonspecific changes are either stable, or resolve[a] <1% disease specific death[a]	An indeterminate response should lead to continued observation with appropriate serial imaging of the nonspecific lesions and serum Tg monitoring. Nonspecific findings that become suspicious over time can be further evaluated with additional imaging or biopsy.

NED denotes a patient as having no evidence of disease at final follow-up.
[a]References (538,539).
[b]In the absence of anti-Tg antibodies.
[c]References (538,539,542,586–593,595–601,1078).
[d]References (598,599,617–621).
[e]References (328,607,626,627,898).

While most studies have assessed response to therapy using TSH-stimulated Tg values obtained 6–18 months after initial therapy (538,539,542,586,588–590,593–595,597–600), at least 15 other studies have evaluated the response to surgical therapy using a stimulated Tg obtained at the time of RAI remnant ablation (605). Patients demonstrating an excellent response to therapy at this very early time point have a very low risk of disease recurrence (605).

Four additional studies used nonstimulated sensitive Tg assays to define an excellent response to therapy at various time points after initial therapy with total thyroidectomy and RAI remnant ablation (587,595,601,606). A recurrence rate of 1.5% was seen in a cohort of 589 DTC patients who had a nonstimulated Tg <0.27 ng/mL at 3 months after initial therapy (595). Malandrino *et al.* (587) reported recurrence rates of 0% in low-risk patients, 1% in intermediate-risk patients, and 2.7% in high-risk patients who demonstrated nonstimulated Tg values <0.15 ng/mL at 9–18 months after initial therapy. Smallridge *et al.* (606) described a 4.3% recurrence rate in 163 low- to intermediate-risk DTC patients with nonstimulated Tg <0.1 ng/mL, measured a median of 1.8 years after initial surgery. Finally, Giovanella *et al.* (601) reported a 1.6% recurrence rate over 5–6 years of follow-up in 185 low-risk patients who had a nonstimulated Tg of <0.2 ng/mL and normal postoperative neck US 6 months after remnant ablation.

Further studies are needed to refine the precise Tg value cutoff used to define what should be an excellent response to therapy in patients treated with total thyroidectomy with or without RAI remnant ablation. In addition to determining whether TSH-stimulated Tg values are clinically helpful in

Downloaded by Memorial Sloan Kettering from www.liebertpub.com at 08/14/19. For personal use only.

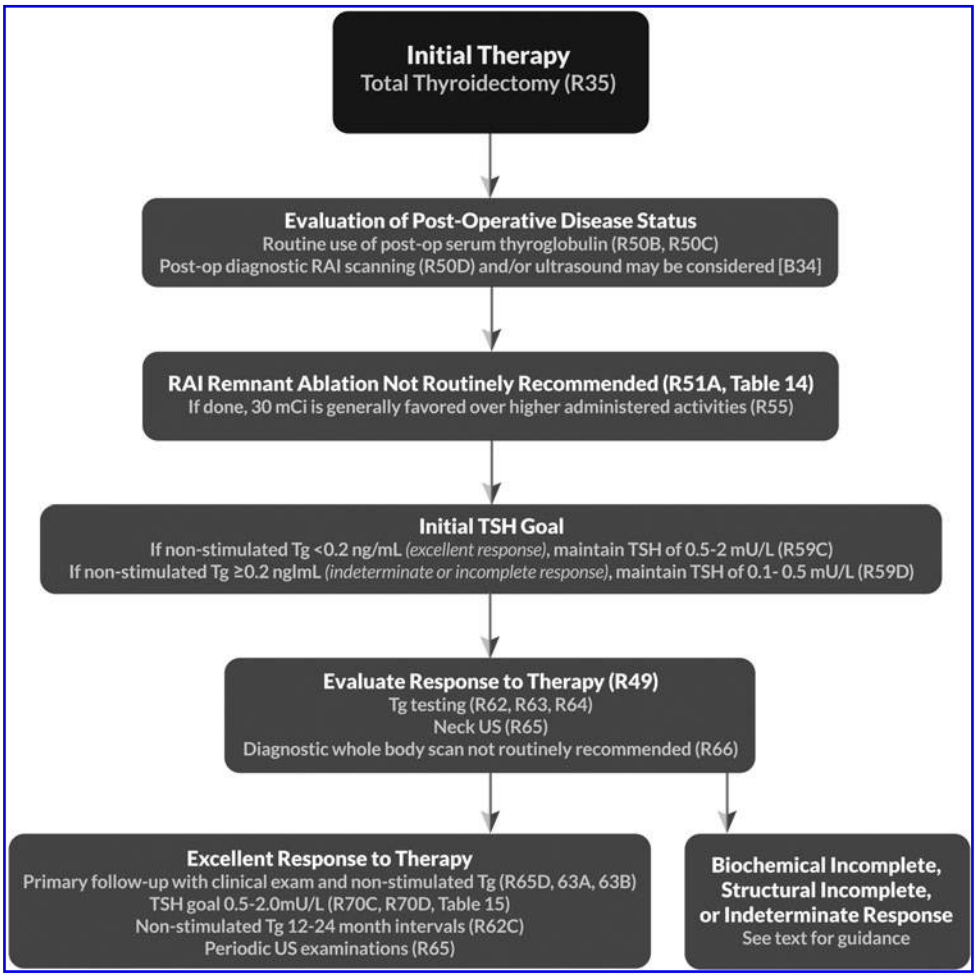

FIG. 5. Clinical decision-making and management recommendations in *ATA low-risk* DTC patients that have undergone total thyroidectomy. R, recommendation in text.

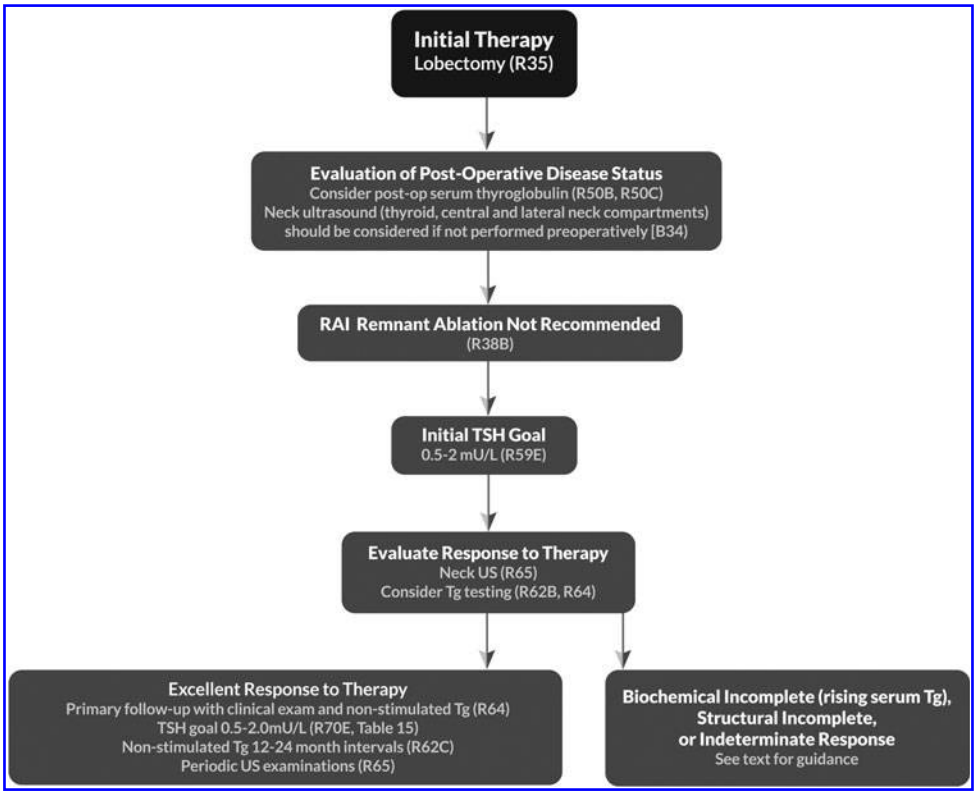

FIG. 6. Clinical decision-making and management recommendations in *ATA low risk* DTC patients that have undergone less than total thyroidectomy (lobectomy or lobectomy with isthmusectomy). R, recommendation in text.

Downloaded by Memorial Sloan Kettering from www.liebertpub.com at 08/14/19. For personal use only.

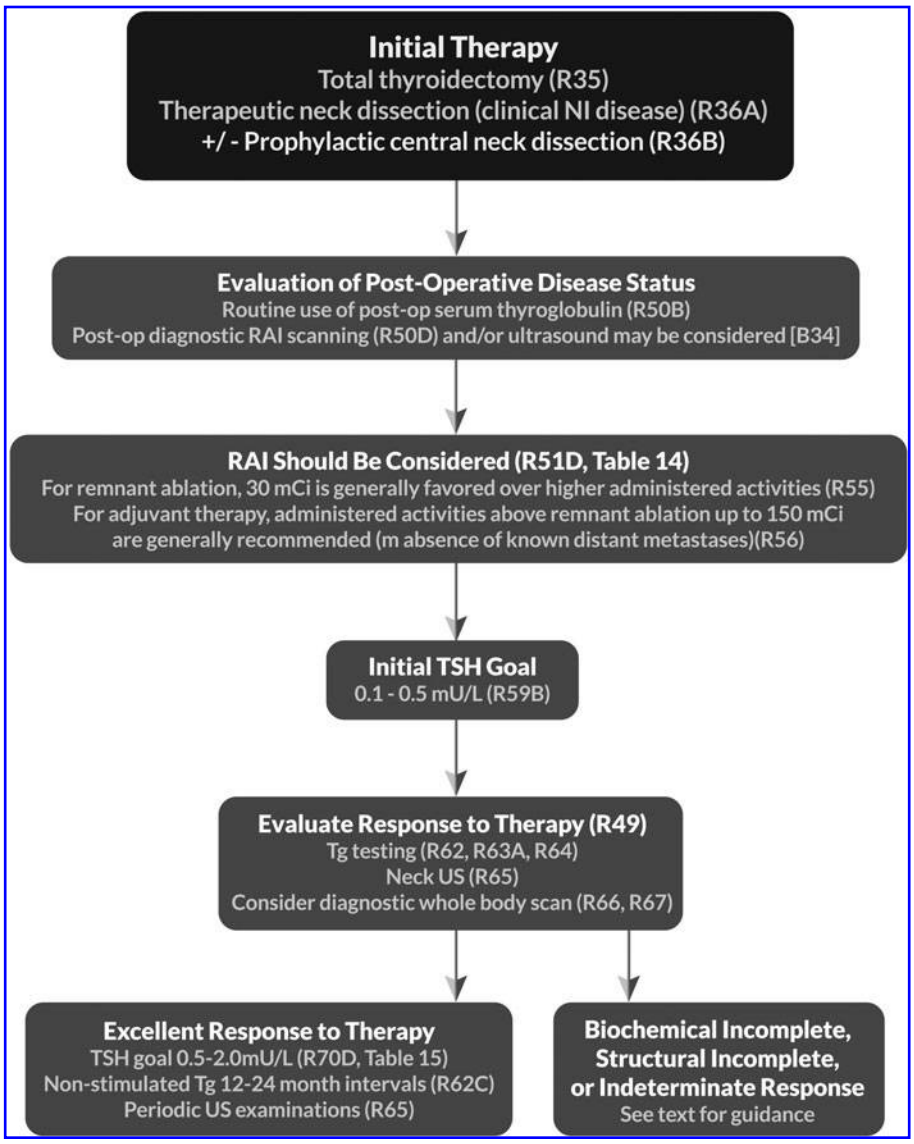

FIG. 7. Clinical decision-making and management recommendations in *ATA intermediate risk* DTC patients that have undergone total thyroidectomy. R, recommendation in text.

Downloaded by Memorial Sloan Kettering from www.liebertpub.com at 08/14/19. For personal use only.

patients at very low risk for recurrence, Tg cut points need to be defined for patients whose primary treatment consisted of thyroid lobectomy or total thyroidectomy without RAI ablation.

In summary, once a patient achieves an excellent response to therapy, the initial risk of recurrence estimate should be modified and the patient reclassified as having a subsequent very low risk of recurrence. This reclassification into a very low risk of recurrence status can occur as early as several weeks (or several months) after initial therapy and is applicable to all DTC patients initially stratified as ATA low or intermediate risk of recurrence and to the few ATA high-risk patients that achieve an excellent response to therapy. Appropriate reclassification into the excellent response category with its very low risk of recurrence should lead to re-evaluation of intensity of diagnostic surveillance procedures and treatment, as discussed in other sections of these clinical practice guidelines [C4–C13] (Figs. 5–8).

[B28] Biochemical incomplete response: abnormal Tg values in the absence of localizable disease

These patients have persistently abnormal suppressed and/or stimulated Tg values or rising anti-Tg antibodies without structural evidence of disease that can be detected using risk-appropriate structural and functional imaging (Table 13). Please see section [C6] for discussion of Tg measurements. Previous studies have used nonstimulated Tg values of >1 ng/mL or TSH-stimulated Tg values of >10 ng/mL to define a biochemical incomplete response to therapy in patients treated with total thyroidectomy and RAI ablation (538,539,542). These studies used Tg assays with variable functional sensitivities, so this definition may change over time, especially for the nonstimulated Tg values.

A biochemical incomplete response is not an uncommon outcome and is seen in 11%–19% of ATA low-risk patients, 21%–22% of ATA intermediate-risk patients, and 16%–18% of ATA high-risk patients (538,539).

Clinical outcomes in these patients are usually very good, with as many as 56%–68% being classified as having NED at final follow-up, while 19%–27% continue to have persistently abnormal Tg values without structural correlate, and only 8%–17% developing structurally identifiable disease over 5–10 years follow-up (538,539,607). No deaths have been reported in patients with a biochemical incomplete response to therapy followed for up to 10 years (539,607).

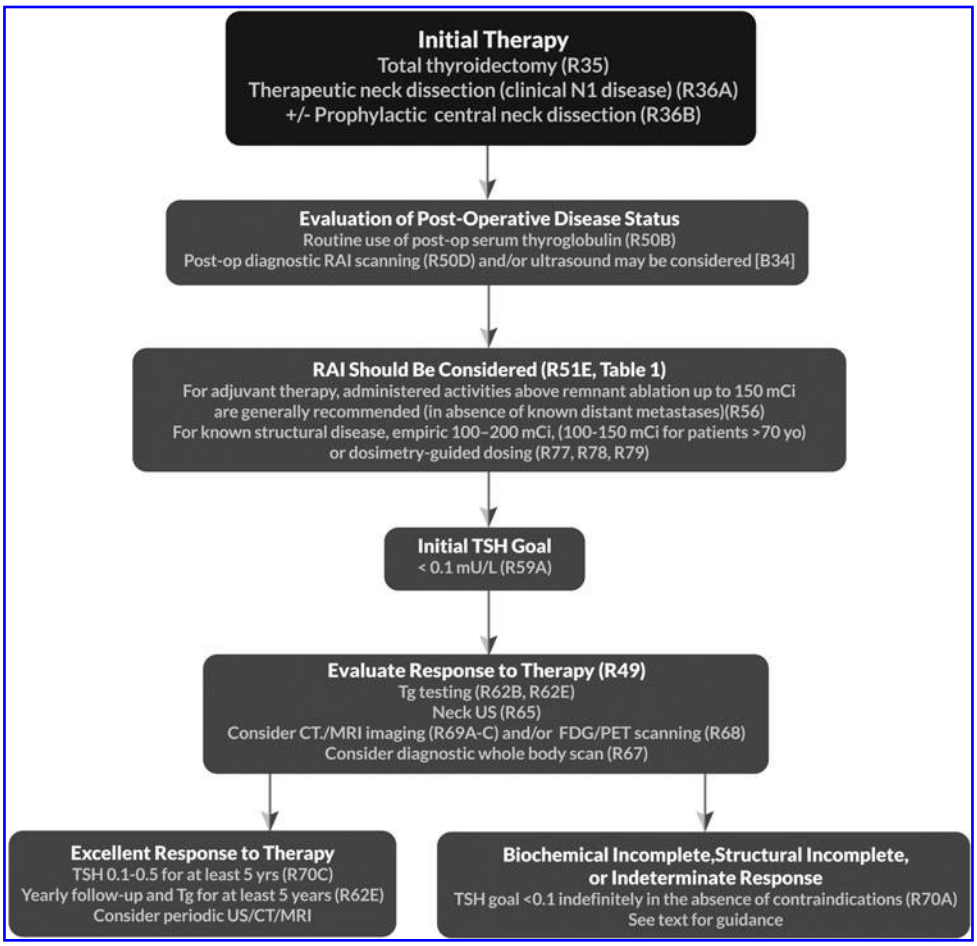

FIG. 8. Clinical decision-making and management recommendations in *ATA high risk* DTC patients that have undergone total thyroidectomy and have no gross residual disease remaining in the neck. R, recommendation in text.

Downloaded by Memorial Sloan Kettering from www.liebertpub.com at 08/14/19. For personal use only.

Anti-Tg antibody levels measured over time in the same assay can provide clinically useful information (608). Rising anti-Tg antibody titers (or new appearance of anti-Tg antibodies) are associated with an increased risk of disease recurrence (609–614). Conversely, patients rendered free of disease with initial therapy will usually demonstrate a decline in anti-Tg antibody titers over several years (611,615,616).

Vaisman *et al.* (607) further demonstrated that the transition to NED status occurred without any additional RAI or surgical therapy (beyond LT_4 suppressive therapy) in 34% of patients classified as having a biochemical incomplete response to initial therapy. These observations are consistent with several previous studies that have demonstrated that abnormal serum Tg values can gradually decline over time without additional RAI or surgical therapy, in the absence of structurally identifiable disease (598,599,617,617–621).

A small percentage of patients with a biochemical incomplete response to therapy will demonstrate progressive increases in the nonstimulated Tg values over time. In patients treated with total thyroidectomy and RAI remnant ablation, clinically significant increases in unstimulated serum Tg values over time as described by Tg doubling times (<1 year, 1–3 years, or >3 years) (622) or rate of rise in unstimulated Tg of ≥0.3 ng/mL/year over time (623), identify patients at increased risk of developing structurally identifiable loco-regional or distant metastases.

Just as with the excellent response to therapy category, additional studies are needed to more precisely define what Tg levels define an incomplete biochemical response to therapy. The specific cut point that defines an ''abnormal Tg'' is dependent on the corresponding TSH value, the amount of residual normal thyroid tissue after thyroidectomy, whether or not RAI ablation was performed, and the duration of time since ablation, because Tg values often decline for months to years after ablation. To define a biochemical incomplete response, previous studies have used nonstimulated Tg values of >5 ng/mL at 6 months (624), nonstimulated Tg values >1 ng/mL more than 12 months after ablation (538,539,542), or TSH-stimulated Tg values >10 ng/mL more than 1 year after ablation (538,539). The precise Tg value for defining a biochemical incomplete response to therapy in patients treated with lobectomy or total thyroidectomy without ablation has not been adequately defined. In addition, some studies also classified patients with persistent or rising anti-Tg antibodies in the absence of structurally identifiable disease as having a biochemical incomplete response to therapy (538,539,625).

In summary, a biochemical incomplete response is seen in approximately 15%–20% of DTC patients. Fortunately, many of these patients are eventually reclassified as having NED at final follow-up, often without any additional RAI or surgical treatments.

[B29] Structural incomplete response: persistent or newly identified loco-regional or distant metastases

These patients have structural or functional (RAI scan, ^{18}FDG-PET) evidence of loco-regional or distant metastases

(538,539,607). This category includes both patients with biopsy-proven disease and also patients in whom structural or functional disease is identified, which is highly likely to be metastatic disease based on the clinical scenario (Table 13). A structural incomplete response to initial therapy is seen in 2%–6% of ATA low-risk patients, 19%–28% of ATA intermediate-risk patients, and 67%–75% of ATA high-risk patients (538,539).

Despite additional treatments, the majority of patients classified as having a structural incomplete response will have persistent structural and/or biochemical evidence of persistent disease at final follow-up (539,607). Depending on the definition used to describe patients as free from disease, higher rates of remission (29%–51%) have been described following surgical intervention for patients with persistent/recurrent loco-regional disease (626–628). While no deaths were reported over a follow-up period that extended to 15 years in patients with biochemical incomplete response to therapy, death from disease was seen in 11% of patients with a loco-regional incomplete response and in 57% of patients with structurally identifiable distant metastases (539,607).

In summary, a structural incomplete response to initial therapy identifies a cohort of DTC patients that may not be cured with additional therapies and consequently demonstrate the highest risk of disease-specific mortality of any of the response-to-therapy categories. Persistent/recurrent loco-regional structural disease may have a higher likelihood of responding to additional treatments and has significantly lower disease-specific mortality rates than persistent/recurrent distant metastases.

[B30] Indeterminate response: biochemical or structural findings that cannot be classified as either benign or malignant (acceptable response)

Patients with an indeterminate response have biochemical, structural, or functional findings that cannot be confidently classified as either excellent response or persistent disease (328,538,539,606,629) (Table 13). Rather than forcing these patients into either the excellent or incomplete response-to-therapy categories, some investigators have recommended a separate category for these patients so that they can be continued to be carefully observed, with selected patients identified for further evaluation with testing designed to establish the presence or absence of disease (538,539).

For example, this category includes patients with subcentimeter avascular thyroid bed nodules or atypical cervical lymph nodes that have not been biopsied, faint uptake in the thyroid bed with undetectable stimulated Tg on follow-up imaging, or nonspecific abnormalities on functional or cross-sectional imaging. Also included in this category are patients with nonstimulated Tg values that are detectable but <1 ng/mL, TSH-stimulated Tg values between 1 and 10 ng/mL, and stable or declining Tg antibodies in the same assay over time in the absence of structural disease (538,539).

This issue was exemplified in a recent study evaluating the prognostic value of a highly sensitive Tg assay in which the response to therapy could not be definitively established in 16 patients that had small indeterminate pulmonary micronodules without other evidence for persistent disease (606). A similar situation arises when trying to determine the response to therapy in the 34% of patients that demonstrated nonspecific subcentimeter thyroid bed nodules after total thyroidectomy (629). Similarly, it is often difficult to be certain whether or not very low-level detectable Tg values represent persistent disease or simply remnant normal thyroid cells remaining after initial therapy.

An indeterminate response to initial therapy is seen in 12%–29% of ATA low-risk patients, 8%–23% of ATA intermediate-risk patients, and 0%–4% of ATA high-risk patients (538,539). The clinical outcomes in patients with an indeterminate response to therapy are intermediate between patients with an excellent response and those with incomplete responses. Two series have demonstrated that only 13%–20% of patients with an indeterminate response to therapy are reclassified as persistent/recurrent disease over approximately 10 years of follow-up. In the remaining 80%–90% of patients, the nonspecific findings either remain stable or resolve with observation alone.

In summary, the majority of patients with an indeterminate response to therapy remain disease-free during prolonged follow-up. However, up to 20% of these patients will eventually have biochemical, functional, or structural evidence of disease progression and may require additional therapies.

[B31] Using risk stratification to guide disease surveillance and therapeutic management decisions

Risk stratification is the cornerstone of individualized thyroid cancer management. Initial risk estimates are useful to guide the wide variety of clinical management decisions that need to be made around the time of initial diagnosis and treatment. As described in this document, initial management decisions are largely made by balancing the estimates of the risk of recurrence and the risk of disease-specific mortality with the potential benefits and risks of proposed therapies. However, in clinical practice many other risk estimates can also significantly influence surveillance and therapeutic decision-making, including the risk of failing initial therapy, the risk of having non–RAI-avid disease, the risk of disease recurring without making appreciable amounts of serum Tg, the risk of adjuvant RAI therapy, the risk of additional thyroid surgery, the risk of additional lymph node surgery, the risk of external beam radiation therapy, and the risk of systemic therapy. Individual management recommendations require that the risks and benefits of potential surveillance and therapeutic management decisions be carefully evaluated in the context of the specific clinicopathologic features of each patient.

Nonetheless, initial risk estimates can be used to guide recommendations with regard to the extent of thyroid surgery, the need for and extent of cervical lymph node dissection, the need for and the dose of administered activities of RAI, the need for and degree of TSH suppression, the need for and details of external beam radiation therapy, the need for and types of systemic therapy, the need for and types of studies required for initial staging, and the intensity and type of follow-up studies required for evaluating response to therapy in the early years following initial therapy. This approach tailors the aggressiveness of intervention and follow-up to the specific risks associated with the tumor in an individual patient.

In summary, this risk-adapted management approach utilizes initial risk estimates to guide early surveillance and therapeutic management decisions. These initial management plans are then modified over time as additional data accumulate and allow for restratification based on individual response to therapy. This system tailors the extent and

Downloaded by Memorial Sloan Kettering from www.liebertpub.com at 08/14/19. For personal use only.

intensity of therapy and follow-up studies to real-time risk estimates that evolve over time for individual patients.

[B32] Should postoperative disease status be considered in decision-making for RAI therapy for patients with DTC?

■ **RECOMMENDATION 50**

(A) Postoperative disease status (i.e., the presence or absence of persistent disease) should be considered in deciding whether additional treatment (e.g., RAI, surgery, or other treatment) may be needed.

(Strong recommendation, Low-quality evidence)

(B) Postoperative serum Tg (on thyroid hormone therapy or after TSH stimulation) can help in assessing the persistence of disease or thyroid remnant and predicting potential future disease recurrence. The Tg should reach its nadir by 3–4 weeks postoperatively in most patients.

(Strong recommendation, Moderate-quality evidence)

(C) The optimal cutoff value for postoperative serum Tg or state in which it is measured (on thyroid hormone therapy or after TSH stimulation) to guide decision-making regarding RAI administration is not known.

(No recommendation, Insufficient evidence)

(D) Postoperative diagnostic RAI WBSs may be useful when the extent of the thyroid remnant or residual disease cannot be accurately ascertained from the surgical report or neck ultrasonography, and when the results may alter the decision to treat or the activity of RAI that is to be administered. Identification and localization of uptake foci may be enhanced by concomitant single photon emission computed tomography–computed tomography (SPECT/CT). When performed, pretherapy diagnostic scans should utilize ^{123}I (1.5–3 mCi) or a low activity of ^{131}I (1–3 mCi), with the therapeutic activity optimally administered within 72 hours of the diagnostic activity.

(Weak recommendation, Low-quality evidence)

Postoperative disease status is a relevant consideration in postoperative treatment decision-making after initial consideration of clinic-pathologic stage. Evaluation of postoperative disease status may be performed by a number of means including serum Tg, neck ultrasonography, and iodine radioisotope scanning. There are currently no RCTs comparing any particular postoperative diagnostic strategy with the intention of modulating decision-making on RAI remnant ablation or RAI treatment for DTC.

[B33] Utility of postoperative serum Tg in clinical decision-making

Serum Tg measurements (with anti-Tg antibodies), with or without neck US, are frequently performed as part of the early postoperative evaluation. Please see section [C6] for discussion of Tg measurements. The predictive value of the postoperative Tg value will be significantly influenced by a wide variety of factors including the amount of residual thyroid cancer and/or normal thyroid tissue, the TSH level at the time of Tg measurement, the functional sensitivity of the Tg assay, the Tg cutoff used for analysis, the individual risk of having RAI-avid loco-regional or distant metastasis, the time elapsed since total thyroidectomy, and/or the sensitivity of the post-therapy scanning technique (SPECT/CT vs. planar imaging).

Multiple studies have confirmed an increase risk of recurrence following total thyroidectomy and RAI remnant ablation in patients that had a postoperative TSH-stimulated Tg >1–2 ng/mL at the time of ablation (596,605,630–637). In multivariate analysis, the postoperative Tg is often found to be an independent predictor of persistent or recurrent disease (596,630,631,636,637). Furthermore, the risk of having recurrent or persistent disease increases as the postoperative Tg rises (634,636). Using receiver operator curve analyses, thyroid hormone withdrawal postoperative Tg values between 20 and 30 ng/mL achieve the optimal balance of sensitivity and specificity for predicting recurrent or persistent disease (638–640). Furthermore, high postoperative stimulated Tg values (>10–30 ng/mL) are also associated with poorer survival (636,639,641). Conversely, postoperative stimulated Tg values less than 1–2 ng/mL are strong predictors of remission (634,636). Even in ATA low- and intermediate-risk patients that did not receive RAI remnant ablation, a nonstimulated postoperative Tg <1 ng/mL was associated with excellent clinical outcomes and recurrence rates <1% (642). The median follow-up in this study was 62 months (2–116 months). Therefore, a postoperative serum Tg can provide valuable information with regard to the likelihood of achieving remission or having persistent or recurrent disease in response to an initial therapy.

A postoperative Tg <10 ng/mL may not distinguish between nodal disease and thyroid remnant, when evaluated using concurrent RAI scans with SPECT/CT (643). In one of the prospective studies mentioned previously, a postoperative Tg threshold of >5 ng/mL was suggested as an indication for RAI treatment (633). However, in a recent retrospective review of consecutive low-risk patients treated with total thyroidectomy without RAI, an unstimulated Tg of ≥2 ng/mL with a concomitant median TSH level of 0.48 mIU/L was reported to detect all patients with disease recurrence (76 patients followed for a median of 2.5 years) (644). Thus, there is some uncertainty as to what degree of postoperative stimulated or unstimulated thyroglobulinemia (with or without neck US interpretation) may be appropriate to prompt RAI treatment. Moreover, detection of unexplained inappropriate thyroglobulinemia may prompt consideration of further investigation for its cause (e.g., imaging studies).

The postoperative Tg can also be used to predict the likelihood of identifying RAI-avid metastatic thyroid cancer outside the thyroid bed on the posttherapy scan at the time of remnant ablation. No uptake outside the thyroid bed was identified in 63 low-risk patients with a nonstimulated postoperative Tg of <0.4 ng/mL (630) or in 132 low-risk patients with a thyroid hormone withdrawal Tg of <1 ng/mL (645). However, RAI-avid metastatic foci outside the thyroid bed were detected in 12% of intermediate-risk patients with a suppressed Tg of <0.6 ng/mL (646), 5.6% of intermediate/high risk patients with a suppressed Tg of <1 .0 ng/mL (647), and 6.3% of intermediate/high-risk patients with a thyroid hormone withdrawal stimulated Tg of <2 ng/mL (648). The likelihood of finding RAI-avid metastatic disease on the post-therapy scan is substantially lower (2.8%) if the postoperative

Downloaded by Memorial Sloan Kettering from www.liebertpub.com at 08/14/19. For personal use only.

Downloaded by Memorial Sloan Kettering from www.liebertpub.com at 08/14/19. For personal use only.

Tg is undetectable in three different Tg assays than if it is undetectable only in a single assay (30%) (649). Conversely, the likelihood of identifying either loco-regional or distant metastases on the posttherapy scan increases as either the suppressed or stimulated Tg values rise above 5–10 ng/mL (631,646,647,650). Therefore, neither a stimulated or suppressed postoperative Tg of <1 ng/mL can completely eliminate the possibility that a posttherapy RAI scan will identify metastatic foci outside the thyroid bed. However, postoperative Tg values greater than 5–10 ng/mL increase the likelihood of identifying RAI-avid metastatic disease on the posttherapy scan.

The postoperative serum Tg value can also be used to predict the likelihood of successful remnant ablation. Postoperative thyroid hormone withdrawal stimulated Tg values >5–6 ng/mL were associated with higher rates of failed ablation after administered activities of both 30 mCi (651) and 100 mCi (652). A TSH-stimulated Tg >6 ng/mL was associated with a 5-fold greater risk of failing ablation after an activity of 30 mCi administered after preparation with thyroid hormone withdrawal (651).

It does appear that a postoperative Tg value (either TSH-stimulated or nonstimulated) is an important prognostic factor that can be used to guide clinical management. Given a disappearance half-life of 1–3 days (653–658), the postoperative Tg should reach its nadir by 3–4 weeks postoperatively in nearly all patients. In low-risk patients, a suppressed or stimulated Tg <1 ng/mL is very reassuring and further confirms classification of the patients as being at low risk. In intermediate-risk patients, postoperative Tg values <1 ng/mL are reassuring, but do not completely rule out the presence of small-volume RAI-avid metastatic disease. However, even without RAI ablation, many intermediate risk patients have excellent clinical outcomes. Therefore, it is not clear that additional therapy is required in these intermediate-risk patients with postoperative Tg values <1 ng/mL even though small-volume RAI-avid disease may still be present after thyroidectomy.

On the other hand, postoperative Tg values (stimulated or nonstimulated) greater than 10–30 ng/mL increase the likelihood of having persistent or recurrent disease, failing initial RAI ablation, having distant metastases, and dying of thyroid cancer. Therefore, postoperative Tg values >10 ng/mL will likely lead to additional evaluations and possibly even additional therapies.

With regard to decision-making on the need for RAI remnant ablation, it appears that the postoperative serum Tg value will be more helpful in identifying patients that may benefit from RAI ablation rather than in identifying patients that do not require ablation. For example, a postoperative Tg value >5–10 ng/mL may lead to selection of RAI ablation in an ATA low-risk patient or ATA intermediate-risk patient that otherwise would not have required RAI ablation (selective use) in order to improve initial staging and facilitate follow-up. Conversely, in high-risk patients, a postoperative Tg value <1 ng/mL does not rule out RAI-avid disease and therefore is unlikely to alter the decision to proceed with RAI ablation.

[B34] Potential role of postoperative US in conjunction with postoperative serum Tg in clinical decision-making

In a prospective study of 218 DTC patients, Lee *et al.* (659) reported that a stimulated Tg <2 ng/mL after thyroid hormone withdrawal (with goal TSH of >30 mIU/L), at the time of administration of 100–200 mCi of ^{131}I (for remnant ablation or treatment), was associated with the following NPVs for biochemical or structural recurrence at 6–12 months: 98.4% for ATA low-risk patients, 94.1% for ATA intermediate-risk patients, and 50% in the ATA high-risk group. They further reported that the NPVs increased to 97.2%, and 100% for ATA intermediate- and high-risk patients, respectively, when the stimulated Tg values were combined with negative neck US findings at baseline (with no change in low-risk patients). Similar significant decreases in the risk of recurrence were seen when ATA intermediate- and high-risk patients had a normal postoperative neck US (660).

[B35] Role of postoperative radioisotope diagnostic scanning in clinical decision-making

Iodine radioisotope diagnostic testing may include ^{131}I or ^{123}I diagnostic imaging with or without SPECT-CT, and/or RAI uptake measurements. Postoperative RAI planar imaging (^{123}I or ^{131}I, with or without SPECT-CT) has been reported to yield information that could alter clinical management (such as altering disease status assessment) in 25%–53% of patients, as reported in single-center, retrospective studies (643,661,662). However, in a multivariate analysis of retrospective data, Hu *et al.* (663) reported that the use of 5 mCi of ^{131}I between 4 and 11 days prior to remnant ablation was independently associated with an increased risk of remnant ablation failure. In contrast, in a smaller retrospective study, the administration of 3–5 mCi of ^{131}I for scanning 2–5 days prior to ablation in 37 patients was not associated with any significant reduction in remnant ablation success, compared to no pretherapy scanning in 63 patients (^{131}I therapeutic activity of 100–200 mCi used in both groups) (664). A possible relationship between ^{131}I diagnostic scan activity on remnant ablation success was suggested in another retrospective study, in which success was lower following the use of 3 mCi as compared to 1 mCi of ^{131}I, 9 days before therapeutic administration of 100 mCi (665). In two small RCTs, there was no significant impact of ^{131}I scanning compared to ^{123}I scanning on the rate of successful remnant ablation (666,667). The timing of whole-body diagnostic scans following administration of radioisotopes in reviewed studies ranged from about 24 to 72 hours for ^{131}I (643,662, 663,665–667) and was 24 hours for ^{123}I (661,662,666). The tailoring of RAI therapeutic activity according to RAI neck uptake (measured 24 hours after administration of 1 mCi of ^{131}I) was associated with a lower rate of remnant ablation success than fixed dosing, in another single-center retrospective observational study (668). Furthermore, in a multivariate analysis of retrospective data (adjusted for relevant risk factors), Verburg *et al.* (669) reported that the use of 1 mCi of ^{131}I for calculation of RAI neck uptake 2 days before remnant ablation was independently associated with an increased risk of remnant ablation failure, although Yap and Murby showed that 1.1 mCi ^{131}I diagnostic scans did not adversely affect the success of ablation or recurrence rate at 3 years (670).

There continues to be discussion on the utility of postoperative iodine radioisotope diagnostic scanning (with or without SPECT/CT) in guiding RAI therapeutic decision-making. Valuable information on disease status, remnant uptake, and the presence of residual RAI-avid disease may be obtained by such testing, which could alter management and potentially

benefit outcome. Questions regarding the potentially negative impact of such scans with ^{131}I on RAI therapeutic efficacy for successful remnant ablation (''stunning'') may be mitigated or avoided by the use of either low-activity ^{131}I (1–3 mCi) or alternative isotopes such as ^{123}I.

[B36] What is the role of RAI (including remnant ablation, adjuvant therapy, or therapy for persistent disease) after thyroidectomy in the primary management of DTC?

■ **RECOMMENDATION 51 (details in Table 14)**

(A) RAI remnant ablation is not routinely recommended after thyroidectomy for ATA low-risk DTC patients. Consideration of specific features of the individual patient that could modulate recurrence risk, disease follow-up implications, and patient preferences are relevant to RAI decision-making.

(Weak recommendation, Low-quality evidence)

(B) RAI remnant ablation is not routinely recommended after lobectomy or total thyroidectomy for patients with unifocal papillary microcarcinoma, in the absence of other adverse features.

(Strong recommendation, Moderate-quality evidence)

(C) RAI remnant ablation is not routinely recommended after thyroidectomy for patients with multifocal papillary microcarcinoma in absence of other adverse features. Consideration of specific features of the individual patient that could modulate recurrence risk, disease follow-up implications, and patient preferences are relevant to RAI decision-making.

(Weak recommendation, Low-quality evidence)

(D) RAI adjuvant therapy should be considered after total thyroidectomy in ATA intermediate-risk level DTC patients.

(Weak recommendation, Low-quality evidence)

(E) RAI adjuvant therapy is routinely recommended after total thyroidectomy for ATA high risk DTC patients

(Strong recommendation, Moderate-quality evidence)

Depending on the postoperative risk stratification of the individual patient, the primary goal of postoperative administration of RAI after total thyroidectomy may include (i) RAI remnant ablation (to facilitate detection of recurrent disease and initial staging by tests such as Tg measurements or whole-body RAI scans), (ii) RAI adjuvant therapy (intended to improve disease-free survival by theoretically destroying suspected, but unproven residual disease, especially in patients at increased risk of disease recurrence), or (iii) RAI therapy (intended to improve disease-specific and disease-free survival by treating persistent disease in higher risk patients). Additional considerations in RAI decision-making may include patient comorbidities (and the potential impact of therapeutic doses of RAI or preparation for the procedure), feasible or preferred disease surveillance procedures, patient preferences (the latter being particularly important when clear data on therapeutic efficacy are lacking), or others. It is important to note that in patients with low-risk DTC, disease surveillance may be accomplished without RAI ablation using neck US and Tg with Tg antibody measurements while on thyroid hormone therapy.

We categorized the results of our review according to the ATA Risk of Recurrence Risk stratification (outlined in a preceding section of these guidelines). However, given that the ATA risk classification is relatively new and the majority of studies examining therapeutic efficacy of postsurgical RAI remnant ablation or therapy (adjuvant or for persistent disease) have been performed with attention to traditional mortality risk stratification systems such as the AJCC/TNM system, MACIS, National Thyroid Cancer Treatment Cooperative Study Group (NTCTCSG), or others, it was necessary to extrapolate the results of many studies according to estimated ATA risk level. We have also categorized some of the results of our evidence review according to the AJCC/TNM risk of mortality stratification system because this system has been in use longer in our field (Table 14). Evaluation of postoperative disease status and recommendations for RAI remnant ablation and adjuvant therapy can be found in algorithms in Figs. 5–8.

ATA low risk. Studies examining the impact of RAI remnant ablation/adjuvant therapy on long-term thyroid cancer outcomes in ATA low-risk patients are subject to limitations due to their observational nature (and potential for bias), as well as limited statistical power to detect relatively uncommon events (such as disease-related mortality). By definition, the risk of disease-specific mortality is low, the risk of persistent/recurrent disease is low (around 3%), and there is no evidence that delayed discovery and treatment of persistent disease may decrease the chance of cure in these patients. In a retrospective multicenter registry study, 1298 DTC patients categorized as being in the ATA low-risk level, were followed for a median of 10.3 years, and there was no significant effect of RAI adjuvant therapy on overall or disease-free survival, using respective multivariate and stratified propensity analysis techniques (544). Prospective data from the NTCTCSG suggest that overall disease-specific and disease-free survival are not improved by RAI treatment in NTCTCSG stage I and II patients (i.e., patients aged <45 years with no distant metastases or patients aged ≥45 years with a primary tumor <4 cm in diameter, no extrathyroidal extension, and no nodal metastases), also using multivariate analyses and propensity analyses (671,672). In two systematic reviews examining results of multivariate adjusted analyses, with a focus on low-risk DTC using classic clinicpathologic staging systems such as TNM/AJCC, the majority of studies did not show a significant effect of RAI adjuvant therapy in reducing thyroid cancer–related death, and conflicting findings of studies relating to outcomes of disease recurrence (673,674). A more recent systematic review of the literature supported the findings of the earlier systematic reviews (675). It is important to note that in the studies summarized in this section on ATA low-risk disease (or equivalent), patients with multifocal PTC were generally included (if no other adverse features meeting criteria for upstaging were noted). To date, there is little evidence to suggest that RAI may improve disease-specific mortality in low-risk DTC patients, and there is some conflicting evidence

Downloaded by Memorial Sloan Kettering from www.liebertpub.com at 08/14/19. For personal use only.

Table 14. Characteristics According to the American Thyroid Association Risk Stratification System and AJCC/TNM Staging System That May Impact Postoperative Radioiodine Decision-Making

ATA risk Staging (TNM)	*Description*	*Body of evidence suggests RAI improves disease-specific survival?*	*Body of evidence suggests RAI improves disease-free survival?*	*Postsurgical RAI indicated?*
ATA low risk T1a N0,Nx M0,Mx	Tumor size ≤1 cm (uni-or multi-focal)	No	No	No
ATA low risk T1b,T2 N0, Nx M0,Mx	Tumor size >1–4 cm	No	Conflicting observational data	Not routine[b]—May be considered for patients with aggressive histology or vascular invasion (ATA intermediate risk).
ATA low to intermediate risk T3 N0,Nx M0,Mx	Tumor size >4 cm	Conflicting data	Conflicting observational data	Consider[b]—Need to consider presence of other adverse features. Advancing age may favor RAI use in some cases, but specific age and tumor size cutoffs subject to some uncertainty.[a]
ATA low to intermediate risk T3 N0,Nx M0,Mx	Microscopic ETE, any tumor size	No	Conflicting observational data	Consider[b]—Generally favored based on risk of recurrent disease. Smaller tumors with microscopic ETE may not require RAI.
ATA low to intermediate risk T1-3 N1a M0,Mx	Central compartment neck lymph node metastases	No, except possibly in subgroup of patients ≥45 years of age (NTCTCSG Stage III)	Conflicting observational data	Consider[b]—Generally favored, due to somewhat higher risk of persistent or recurrent disease, especially with increasing number of large (>2–3 cm) or clinically evident lymph nodes or presence of extranodal extension. Advancing age may also favor RAI use.[a] However, there is insufficient data to mandate RAI use in patients with few (<5) microscopic nodal metastases in central compartment in absence of other adverse features.
ATA low to intermediate risk T1-3 N1b M0,Mx	Lateral neck or mediastinal lymph node metastases	No, except possibly in subgroup of patients ≥45 years of age	Conflicting observational data	Consider[b]—Generally favored, due to higher risk of persistent or recurrent disease, especially with increasing number of macroscopic or clinically evident lymph nodes or presence of extranodal extension. Advancing age may also favor RAI use.[a]
ATA high risk T4 Any N Any M	Any size, gross ETE	Yes, observational data	Yes, observational data	Yes
ATA high risk M1 Any T Any N	Distant metastases	Yes, observational data	Yes, observational data	Yes

[a]Recent data from the NTCTCSG (National Thyroid Cancer Treatment Cooperative Study Group) have suggested that a more appropriate prognostic age cutoff for their and other classification systems could be 55 years, rather than 45 years, particularly for women.

[b]In addition to standard clinicopathologic features, local factors such as the quality of preoperative and postoperative US evaluations, availability and quality of Tg measurements, experience of the operating surgeon, and clinical concerns of the local disease management team may also be considerations in postoperative RAI decision-making.

Downloaded by Memorial Sloan Kettering from www.liebertpub.com at 08/14/19. For personal use only.

Downloaded by Memorial Sloan Kettering from www.liebertpub.com at 08/14/19. For personal use only.

on effect on recurrence, with newer data using the ATA risk system suggesting the lack of a significant effect. Furthermore, the majority of the best available observational evidence suggests that RAI adjuvant therapy is unlikely to improve disease-specific or disease-free survival in papillary microcarcinoma (<1 cm, uni- or multifocal), in the absence of other higher risk features (146,676–680). In a recent retrospective analysis of 704 papillary microcarcinoma patients whose initial risk level was ATA low or intermediate who were followed for a median of 64 months, there was no significant reduction in recurrence rates in patients treated with RAI compared to those not treated with RAI using a propensity score analysis (677). With respect to microcarcinomas of follicular cancer and Hürthle cell cancer, a recent SEER registry secondary data analysis suggested no disease-specific survival benefit in patients treated with RAI in a multivariate analysis adjusted for age, histology, disease extent, type of surgery, and external beam radiation therapy (the total number of patients in this study was 564) (681). A limitation of interpreting these data on follicular and Hürthle cell microcarcinomas is that some of the patients in the study had some adverse features and were not all considered low risk; however, the authors adjusted for relevant variables in their multivariate analysis (681). The role of RAI adjuvant therapy in ATA low-risk DTC should be clarified in the future, following completion of RCTs, such as the Iodine or Not (IoN) trial for low- and intermediate-risk patients (682) and ESTIMABL2 for low-risk patients.

ATA intermediate risk. Multivariate adjusted analyses from SEER suggest that postsurgical RAI treatment is associated with improved overall survival for aggressive PTC histologies such as tall cell, diffuse sclerosing, and insular variants (683,684). Furthermore, multivariate adjusted analyses from SEER suggest that RAI treatment is associated with improved overall survival in node-positive adult patients with PTC or pT3 node-negative PTC, in which the primary tumor is >4 cm or there is evidence of microscopic extrathyroidal extension (685). It is important to note, however, that in this SEER study the overall survival rate was very high in node-positive or pT3-node negative PTC patients aged <45 years, such that 99% and 98% of such individuals were alive after a median follow-up period of 6.8 years, with or without RAI treatment, respectively. The clinical significance of this approximately 1% absolute risk difference could be questioned. In contrast, in the same study, for individuals aged ≥65 years, assuming the same median study follow-up period of 6.8 years, 73% of T3-node negative or node-positive PTC patients treated with RAI and 69% of those not treated with RAI were alive (685); in this older subgroup, the absolute risk difference would be estimated to be about 4%.

There is some supportive evidence from multivariate and propensity analyses that there may be a benefit of adjuvant RAI treatment in improving overall and disease-specific survival as well as disease-free survival in patients with nodal metastases aged ≥45 years, as such patients would be included in the NTCTCSG stage III category (671). Furthermore, in a single-center retrospective study from Hong Kong examining data from a subgroup of 421 patients with node-positive PTC, lymph node failure-free survival was improved with postsurgical RAI treatment, with the greatest treatment benefits observed in patients with N1b disease, as well as with lymph nodes >1 cm in diameter (686). RAI therapeutic efficacy in patients <45 years of age with nodal metastases are unclear because such patients are categorized as stage I by the NTCTCSG system and no significant benefit of RAI treatment was observed for the stage I group in that study, with no specific subgroup analysis reported according to node positivity (671). A single-center retrospective study from the Mayo Clinic examining 20-year cause-specific mortality and recurrence rate, suggested no significant benefit in PTC patients with a MACIS score of <6 who had positive lymph nodes, using respective univariate analyses (278). Given that age is incorporated in the MACIS score, it is possible that age was a contributing factor in the results of that analysis. In a subgroup of 352 patients with microscopic extrathyroidal extension from a single-center retrospective study, postsurgical RAI treatment was associated with a reduction in rate of local relapse (686). However, in the NTCTCSG study, microscopic extraglandular invasion would be classified as NTCTCSG stage I for patients <45 years of age and II for those ≥45 years of age, and those stages were associated with lack of clear benefit of RAI. In a recent systematic review, Lamartina *et al.* (675) reported conflicting results on the impact of RAI treatment on disease recurrence, specifically indicating that 11 nonrandomized studies suggested a benefit, whereas 13 studies did not show a significant benefit. For patients with ATA intermediate-risk DTC, limited risk-group specific data examining RAI efficacy is available, but existing data suggest that the greatest potential benefit may be observed with adverse thyroid cancer histologies, increasing volume of nodal disease, lymph node disease outside the central neck, and advancing patient age. Benefits regarding survival or recurrence can be expected primarily in patients with higher risk of recurrent or persistent disease that is iodine avid. More studies are needed, including RCTs, to characterize RAI treatment efficacy in ATA intermediate-risk patients. The adjuvant therapeutic efficacy of RAI treatment in improving long-term thyroid cancer outcomes in the situation of isolated microscopic central neck nodal disease in the absence of other adverse features is unknown, so the relatively good overall prognosis of this group (as outlined in the preceding section of these guidelines) as well as the uncertain RAI therapeutic efficacy for this subgroup, are important considerations in RAI decision-making. Clearly more research is needed to understand the therapeutic efficacy in various subgroups of patients in the ATA intermediate-risk category.

ATA high risk. A prospective multicenter study reported a significant improvement in overall and disease-specific mortality, as well as disease-free survival in NTCTCSG stage III and IV patients, after statistical adjustment using multivariate and propensity stratified analyses (671). Furthermore, prospectively collected data from the SEER cancer registry suggest that postsurgical RAI therapy is associated with improved overall survival in patients with PTC with distant metastases (when distant metastases were combined with age >45 years, tumor size >2 cm, and positive lymph nodes at primary diagnosis) (687). Data from SEER also suggest that overall survival in patients with FTC with distant metastases more than doubled in patients receiving postsurgical RAI treatment (687). Thus, routine postsurgical RAI treatment is recommended in patients with ATA high-risk DTC.

[B37] What is the role of molecular marker status in therapeutic RAI decision-making?

■ **RECOMMENDATION 52**

The role of molecular testing in guiding postoperative RAI use has yet to be established; therefore, no molecular testing to guide postoperative RAI use can be recommended at this time.

(No recommendation, Insufficient evidence)

Preclinical studies show that the presence of the $BRAF^{V600E}$ mutation significantly reduces sodium-iodide symporter expression and RAI uptake (688). There are currently insufficient clinical data, however, to know whether the presence or absence of the $BRAF^{V600E}$ mutation or other genetic alterations in PTC may impact the success of adjuvant therapy or remnant ablation in PTC, or if adjustments in administered activity are warranted for any planned treatments. In a recent subgroup analysis of 134 PTC patients with T1aN0M0 disease, the rate of macroscopic structural disease recurrence was 0% in the no RAI group (24% of whom were *BRAF* positive), 2.6% in 39 *BRAF*-positive patients who received RAI, and 1.7% in *BRAF*-negative patients who received RAI (mean follow-up of 5.3 years for the entire study) (565). Of the 97 T1aN0M0 patients who received postoperative RAI, the rate of biochemical persistence of disease (defined by a stimulated Tg of >1 ng/mL), was 13% in the 39 *BRAF*-positive patients and 1.7% in the *BRAF*-negative patients; the standard activity for remnant ablation in this study was 30 mCi in most cases (565). The relatively small number of patients who did not receive postoperative RAI and the relatively small number of structural disease recurrences in the T1aN0M0 subgroup of PTC patients and lack of randomization in this study may preclude meaningful analysis of RAI therapeutic efficacy. The ESTIMABL2 study will analyze the relevance of *BRAF* status on outcome (registration number NCT01837745). There are no studies examining therapeutic efficacy of RAI in ATA high-risk patients, but the presence or absence of a $BRAF^{V600E}$ mutation in that situation would be unlikely to alter RAI decision-making at present. Thus, the role of molecular testing in guiding postoperative RAI use has yet to be established, and more research in this area is clearly needed. Moreover, in general, RCTs examining RAI therapeutic efficacy are needed, and ideally these should be appropriately stratified for ATA recurrence risk level and other important prognostic variables.

[B38] How long does thyroid hormone need to be withdrawn in preparation for RAI remnant ablation/ treatment or diagnostic scanning?

■ **RECOMMENDATION 53**

(A) If thyroid hormone withdrawal is planned prior to RAI therapy or diagnostic testing, LT_4 should be withdrawn for 3–4 weeks. Liothyronine (LT_3) may be substituted for LT_4 in the initial weeks if LT_4 is withdrawn for 4 or more weeks, and in such circumstances, LT_3 should be withdrawn for at least 2 weeks. Serum TSH should be measured prior to radioisotope administration to evaluate the degree of TSH elevation.

(Strong recommendation, Moderate-quality evidence)

(B) A goal TSH of >30 mIU/L has been generally adopted in preparation for RAI therapy or diagnostic testing, but there is uncertainty relating to the optimum TSH level associated with improvement in long-term outcomes.

(Weak recommendation, Low-quality evidence)

Thyrotropin stimulation before RAI remnant ablation/ therapy or scanning has been a long-established standard of care because early observational research suggested that a TSH >30 mIU/L was required for incompletely resected thyroid tumors to significantly concentrate ^{131}I (689). There have been two RCTs comparing various thyroid hormone withdrawal protocols prior to therapeutic or diagnostic iodine radioisotope administration (690,691). Lee *et al.* (691) reported on an open-label, single-center study, in which 291 patients with well-differentiated thyroid cancer (TNM stage T1–T3, N0/N1a,M0) were randomized to either (a) withdrawal LT_4 for 4 weeks ($n = 89$), (b) withdrawal of LT_4 for 4 weeks with substitution of LT_3 for the first 2 weeks ($n = 133$), or (c) recombinant human TSH (rhTSH; with withdrawal of LT_4 for a few days from the time of the first rhTSH injection to radioisotope administration) ($n = 69$) (691). In this trial, all patients received 30 mCi of ^{131}I for remnant ablation and were prescribed a 2-week low-iodine diet (LID) pre-ablation. Although the randomization method was unclear, the baseline characteristics (including pre-ablation urinary iodine measurements) were well balanced among groups. Furthermore, the pre-ablation TSH was >30 in all patients in all groups in this trial, with no significant difference in mean pre-ablation TSH levels. Moreover, the primary outcome, which was the rate of successful remnant ablation at 12 months, was not significantly different among groups (range 91.0%–91.7% among groups). Upon administration of questionnaires in a double-blind fashion, there was no significant difference in quality of life during preparation for RAI ablation, between the LT_4 withdrawal group and the LT_4 withdrawal with LT_3 substitution group; however, quality of life in both withdrawal groups prior to remnant ablation was significantly worse than after rhTSH preparation (691). Long-term outcome data from this trial were not reported. In a single-center trial, Leboeuf *et al.* (690) randomized 20 individuals with well-differentiated thyroid cancer awaiting RAI remnant ablation or diagnostic scanning to LT_4 withdrawal and either (a) substitution of LT_3 (50 μg/d, divided as two capsules) for 21 days, followed by 2 weeks off LT_3, or (b) identical-appearing placebo for LT_3 (two pills per day) for 21 days. In both groups, either the LT_3 or placebo was withdrawn for another 2 weeks, and weekly measurements were performed for serum TSH, free thyroxine, and free triiodothyronine (690). The primary outcome was the hypothyroidism symptom score (Billewicz scale), which was ascertained in a double-blind fashion at time of LT_4 withdrawal and every 2 weeks until the end of the study. The randomization method was a computer-generated number sequence; the LT_3 group was significantly older than the placebo group (mean age 64 compared to 46), suggesting imbalance in the randomization (690). Disease stage of participants was not reported. Approximately 15% of participants withdrew from this trial (two in the placebo group and one in the LT_3 group). Leboeuf *et al.* (690) reported no significant differences between the two thyroid hormone

Downloaded by Memorial Sloan Kettering from www.liebertpub.com at 08/14/19. For personal use only.

withdrawal protocol groups for hypothyroid symptom scores at any time point in the trial in a protocol-based analysis. At the time of ablation or whole-body scanning, the mean TSH was not significantly different between groups. In summary, available evidence from recent RCTs suggests that either direct LT_4 withdrawal or LT_4 withdrawal with substitution of LT_3 in initial weeks is associated with similar short-term quality of life and hypothyroidism symptom scores; moreover, the remnant ablation success rate appears comparable.

There is some conflicting observational evidence on whether any specific pre-RAI administration TSH level is associated with success of remnant ablation (692–696). For example, in a secondary analysis of a RAI remnant ablation activity RCT, Fallahi *et al.* (692) reported that a pre-RAI TSH of >25 following (LT_4 and LT_3) thyroid hormone withdrawal was significantly associated with increased likelihood of successful remnant ablation (odds ratio 2.36, [95% CI 1.28–4.35], $p = 0.006$), after adjustment for RAI activity, baseline serum Tg, on-LT_4 TSH level, sex, age, histology, baseline RAI uptake, and extent of surgery). In two retrospective studies, each including several hundred DTC patients who underwent thyroid hormone withdrawal, no significant association was observed between pre-RAI TSH and rate of successful remnant ablation, in respective multivariate analyses adjusted for relevant variables such as disease extent, ^{131}I activity, and sex (695,696). However, results of these two studies may not necessarily be extrapolated to TSH levels below 30 mU/L, given that patients with such TSH thresholds were not generally considered eligible for RAI ablation in these studies. Pre–RAI ablation TSH was not a significant predictor of becoming disease free without further treatment in a secondary subgroup analysis of 50 patients who underwent thyroid hormone withdrawal, but the small number of patients in this subgroup may have limited the statistical power for a multivariate analysis (694). In summary, there is some uncertainty on the optimal level pre–RAI treatment TSH following thyroid hormone withdrawal in considering long-term outcome effects.

[B39] Can rhTSH (Thyrogen) be used as an alternative to thyroxine withdrawal for remnant ablation or adjuvant therapy in patients who have undergone near-total or total thyroidectomy?

■ RECOMMENDATION 54

(A) In patients with ATA low-risk and ATA intermediate-risk DTC without extensive lymph node involvement (i.e., T1–T3, N0/Nx/N1a, M0), in whom RAI remnant ablation or adjuvant therapy is planned, preparation with rhTSH stimulation is an acceptable alternative to thyroid hormone withdrawal for achieving remnant ablation, based on evidence of superior short-term quality of life, noninferiority of remnant ablation efficacy, and multiple consistent observations suggesting no significant difference in long-term outcomes.

(Strong recommendation, Moderate-quality evidence)

(B) In patients with ATA intermediate-risk DTC who have extensive lymph node disease (multiple clinically involved LN) in the absence of distant metastases, preparation with rhTSH stimulation may be considered as an alternative to thyroid hormone withdrawal prior to adjuvant RAI treatment.

(Weak recommendation, Low-quality evidence)

(C) In patients with ATA high-risk DTC with attendant higher risks of disease-related mortality and morbidity, more controlled data from long-term outcome studies are needed before rhTSH preparation for RAI adjuvant treatment can be recommended.

(No recommendation, Insufficient evidence)

(D) In patients with DTC of any risk level with significant comorbidity that may preclude thyroid hormone withdrawal prior to iodine RAI administration, rhTSH preparation should be considered. Significant comorbidity may include (a) a significant medical or psychiatric condition that could be acutely exacerbated with hypothyroidism, leading to a serious adverse event, or (b) inability to mount an adequate endogenous TSH response with thyroid hormone withdrawal.

(Strong recommendation, Low-quality evidence)

Recombinant human thyrotropin (trade name Thyrogen) is currently approved by many international authorities including the United States Food and Drug Administration (FDA) and Health Canada for use in preparation for RAI remnant ablation in patients who have undergone a near-total or total thyroidectomy for well-differentiated thyroid cancer and who do not have evidence of distant metastases (FDA, www.accessdata.fda.gov; Health Canada, http://webprod.hc-sc.gc.ca). Data from a compassionate use observational study suggest that rhTSH raises serum TSH measurements in patients who are unable to mount an endogenous TSH rise and appears to reduce the risk of hypothyroid-related complications in patients with significant medical or psychiatric comorbidity (697). Some of the complications that were reported to be avoided by use of rhTSH included worsening of psychiatric illness, respiratory compromise, central nervous system (CNS) compromise, aggravation of congestive heart failure, and aggravation of coronary artery disease (697).

Multiple RCTs have focused on short-term remnant ablation outcomes in low and intermediate risk DTC with lower risk features, using rhTSH compared to thyroid hormone withdrawal. In six RCTs of patients with well-differentiated thyroid cancer without distant metastases undergoing RAI remnant ablation (T1–T3, N1 or N0, all M0), the rate of successful remnant ablation, was not significantly different after rhTSH preparation compared to thyroid hormone withdrawal, using ^{131}I dose activities ranging from 30 to 100 mCi (691,698–702). Patients with resected cervical lymph node metastases were included in five of these trials (691,699–702), and these may be assumed to be confined to the central neck, given the extent of primary surgery described in these studies. In one trial, a further inclusion restriction was fewer than five positive nodes at the time of the primary surgery (702). Some potential limitations of the existing RCTs in this area include lack of blinding of patients and treating physicians (because it was not feasible). In five of the RCTs that examined health-related quality of life around the time of remnant ablation, this outcome was significantly worse in patients who underwent thyroid hormone withdrawal compared to rhTSH preparation, and this was attributed to hypothyroid symptoms (691,699–702). However, in three of these RCTs, which examined longer term

Downloaded by Memorial Sloan Kettering from www.liebertpub.com at 08/14/19. For personal use only.

quality of life, there was no significant difference in measurements between patients who had received rhTSH compared to those who had thyroid hormone withdrawal preparation, 3 or more months after RAI remnant ablation (699,701,702). A smaller RCT including a total of 25 individuals who had incidentally discovered PTC in the course of thyroidectomy for multinodular goiter, showed that mean Tg measurements were similar at various time points out to about 20 months in 13 individuals who were prepared for remnant ablation using rhTSH within a week after thyroidectomy, compared to those prepared by LT_4 withdrawal for 4–6 weeks postoperatively (703). A meta-analysis pooling data from 1535 patients in all seven trials described herein, suggested that the rates of remnant ablation success were not significantly different using rhTSH compared to thyroid hormone withdrawal (risk ratio 0.97 [95% CI 0.94–1.01]) (704). Furthermore, a pooled analysis suggested that quality-of-life measures were superior on the day of remnant ablation in the rhTSH group, with no significant difference between groups 3 months later (704). Another meta-analysis including six of the previously mentioned RCTs, also suggested that the success of remnant ablation was not significantly different between patients prepared with rhTSH or thyroid hormone withdrawal, and this result was robust using a variety of definitions of remnant ablation success (705). In summary, the use of rhTSH for preparation for remnant ablation is associated with superior short-term quality of life and similar rates of successful remnant ablation compared to traditional thyroid hormone withdrawal.

There are some limited long-term outcome data following rhTSH preparation for RAI treatment compared to thyroid hormone withdrawal. In one aforementioned RCT in ATA low- and intermediate-risk patients (700), follow-up data were reported at a median of 3.7 years later for 51 of the original 63 patients, and rates of reoperation for cervical neck recurrence were essentially identical between groups (4% of patients), with no deaths (706). In the same study, repeat treatment with ^{131}I for detectable Tg or imaging evidence of disease was performed in 4 of the 28 patients in the rhTSH group and 5 of the 23 patients in the hypothyroid group in this study (706). The low number of thyroid cancer–related deaths and recurrences in this small trial limit the ability to make meaningful statistical comparisons of long-term outcomes. In another RCT including 44 mixed risk–level DTC patients, who were subjected to either rhTSH preparation ($n=24$) for RAI treatment within a week after surgery or 4–6 weeks of LT_4 withdrawal ($n=20$), after a mean follow-up period of about 52 months, only one individual in the rhTSH group was histologically proven to have recurrent disease (lymph nodes and bone) (707). However, this study was likely underpowered to detect meaningful differences in this outcome, and the final data analysis would be limited by lack of data available at the final follow-up (i.e., in progress) for 18% of the trial participants (707). In one prospective (694) and two retrospective (708,709) observational studies including largely ATA low- and intermediate-risk DTC patients, no significant difference was observed in the long-term presence of clinically significant disease, regardless of whether rhTSH or thyroid hormone withdrawal was used in preparing for therapeutic RAI for DTC patients). In a subgroup analysis of 183 DTC patients with level N1b nodal disease from one of the aforementioned retrospective studies, the rate of NED at last follow-up was not significantly different in patients prepared with thyroid hormone withdrawal (26.8%) compared to those prepared with rhTSH (33.7%) (708). In a smaller retrospective, multicenter study, Pitoia *et al.* (710) reported that in 45 consecutive Tg antibody-negative patients with T3-T4 /N1-Nx/M0 disease, the absence of persistence or recurrence of disease after a mean follow-up of about 3 years was 72% in patients pretreated with rhTSH and 59% in those pretreated with thyroid hormone withdrawal ($p=0.03$). In a multicenter retrospective analysis of patients with T4 disease with or without nodal or distant metastases (T4, N0/N1, M0/M1), the rate of stimulated Tg <2 ng/mL Tg among antibody-negative patients was 67.7% (42 of 62) in patients prepared for RAI treatment with rhTSH, compared to 57.8% (37 of 64) in those prepared with thyroid hormone withdrawal (6-month follow-up) (711). In a retrospective analysis of 175 patients with RAI-avid metastatic disease to lungs and/or bone, the authors observed no significant difference in overall survival after a mean follow-up period of 5.5 years, among patients prepared prior to RAI treatment with rhTSH alone for all RAI treatments, thyroid hormone withdrawal for all RAI treatments, or thyroid hormone withdrawal for initial treatments followed by rhTSH for subsequent treatment(s) (712). In this study, whole-body and blood dosimetry studies were performed in all patients; therefore, the results may not be extrapolated to RAI fixed dosing. Some important differences among groups in this study that could have impacted the findings included differences in cumulative RAI activities received and longer follow-up in groups who had thyroid hormone withdrawal (712). Although the authors performed a multivariable analysis examining for predictors of overall survival, and method of TSH stimulation was not significant, this model did not adjust for these variables. In a two-center retrospective analysis comparing responses to treatment using RECIST 1.1 criteria in 56 patients with distant metastatic disease pretreated with either rhTSH or thyroid hormone withdrawal prior to RAI, there were no differences in outcomes between groups after a mean follow-up period of about 6 years (713). Also in this study, there were important baseline differences among groups, such as rates of use of dosimetry and mean cumulative RAI activity. Rates of xerostomia, leukopenia, or thrombocytopenia were not significantly different between treatment groups in this study. The overall mortality rate was 20% in the rhTSH group (3 of 15) and 7.3% in the thyroid hormone withdrawal group (3 of 41) ($p=0.188$) (713), although the study was likely not sufficiently large to examine differences in this important outcome. The findings of the latter study cannot be readily extrapolated to fixed-dosing RAI treatment regimens because 80% of the individuals in the rhTSH group and 46% in the thyroid hormone withdrawal group had dosimetry-based RAI treatment. RCTs comparing rhTSH to thyroid hormone withdrawal preparation pre–RAI treatment, are clearly needed to guide clinical care in higher risk DTC patients.

[B40] What activity of ^{131}I should be used for remnant ablation or adjuvant therapy?

■ RECOMMENDATION 55

(A) If RAI remnant ablation is performed after total thyroidectomy for ATA low-risk thyroid cancer or intermediate-risk disease with lower risk features (i.e., low-

Downloaded by Memorial Sloan Kettering from www.liebertpub.com at 08/14/19. For personal use only.

volume central neck nodal metastases with no other known gross residual disease or any other adverse features), a low administered activity of approximately of 30 mCi is generally favored over higher administered activities.

(Strong recommendation, High-quality evidence)

(B) Higher administered activities may need to be considered for patients receiving less than a total or near-total thyroidectomy in which a larger remnant is suspected or in which adjuvant therapy is intended.

(Weak recommendation, Low-quality evidence)

■ **RECOMMENDATION 56**

When RAI is intended for initial adjuvant therapy to treat suspected microscopic residual disease, administered activities above those used for remnant ablation up to 150 mCi are generally recommended (in absence of known distant metastases). It is uncertain whether routine use of higher administered activities (>150 mCi) in this setting will reduce structural disease recurrence for T3 and N1 disease.

(Weak recommendation, Low-quality evidence)

Successful remnant ablation can be defined by an undetectable stimulated serum Tg, in the absence of interfering Tg antibodies, with or without confirmatory nuclear or other imaging studies. An alternative definition in cases in which Tg antibodies are present is the absence of visible RAI uptake on a subsequent diagnostic RAI scan. In this section, we only included published original RCTs or systematic reviews/meta-analyses of such studies examining the impact of various ^{131}I dose activities on the rate of successful remnant ablation or thyroid cancer outcomes (including thyroid cancer–related deaths or recurrences) in adult patients with well-differentiated thyroid carcinoma who had been treated with total or near-total thyroidectomy and who were not known to have any gross residual disease following surgery. Our search yielded six RCTs (692,699,701,714–716), the majority of which had had no blinding of patients and health care providers (699,701,714–717).

In the trial by Fallahi *et al.* (692), the randomization program was prepared and executed by a technologist in the laboratory where the ^{131}I activities were prepared for dispensing in coded vials, without revealing the administered activity to participants and health care providers. The pathologic stage of disease of patients included was TNM stage pT1 to pT3 in four trials (699,714,715,717), whereas only pT1 or pT2 patients were eligible in one trial (701), and primary tumor size or tumor size staging was not reported in two trials (692,716). Some patients with known small-volume lymph node disease were included in five of the trials (699,701,714,715,717), but patients with known lymph node disease were excluded from one trial (692), and lymph node staging was not reported in another trial (716). Although the specific levels and size of lymph node metastases at baseline were not clearly reported, data reported on surgical extent suggested that these were consistent with relatively nonbulky central neck nodal metastases resected in the course of thyroidectomy with or without central neck dissection (699,701, 714,715,717).

The ^{131}I activities compared were as follows: 30 mCi compared to 100 mCi in four trials (692,699,701,714), 50 mCi compared to 100 mCi in two trials (715,716), or 30 mCi compared to 60 mCi or 100 mCi in one study comprising pooled long-term outcome data from two staged smaller trials from the same group (717).

The rate of successful remnant ablation was reported to be not inferior using an administered activity of 30 mCi as compared to 100 mCi in three trials after preparation with thyroid hormone withdrawal (699,701,714) and in two trials after preparation with rhTSH (699,701), including data from the two large factorial design trials in both comparisons (699,701). Pilli *et al.* (715) reported that an administered activity of 50 mCi was not inferior to 100 mCi in achieving successful remnant ablation, following preparation with rhTSH. In contrast, Zaman *et al.* (716) suggested that 100 mCi may be superior to 50 mCi following thyroid hormone withdrawal, but the small size (40 patients) and lack of reporting of statistical comparisons are important limitations of this study. The third largest trial (341 patients randomized) by Fallahi *et al.* (692) reported that an administered activity of 100 mCi was superior to 30 mCi in achieving successful remnant ablation after thyroid hormone withdrawal. The rate of initial successful remnant ablation (as defined by the primary authors) was highly variable among trials, and the following rates were reported following initial administration of 100 mCi of ^{131}I: 64% in the trial from Fallahi *et al.* (692), 56% in the trial from Maenpaa *et al.* (714), 89% in the trial from Mallick *et al.* (699), 67% in the trial from Pilli *et al.* (715), 94% in the trial from Schlumberger *et al.* (701), and 60% in the trial from Zaman *et al.* (716). The reasons explaining variability in the rates of successful RAI remnant ablation among trials are not completely understood but could potentially be due to differences in study populations, completeness of surgery (including size of the remaining remnant), or sensitivity of techniques used to evaluate outcomes (such as Tg assays or diagnostic imaging studies).

Short-term side effects in the weeks following remnant ablation have been reported to be more frequent in patients treated with 100 mCi as compared to 30 mCi activities by Mallick *et al.* (699), and a similar trend was reported by Maenpaa *et al.* (714). Repeat treatment with additional ^{131}I has been reported to be more frequent in patients treated with 30 mCi as compared to higher activities in three trials (692,699,717), but not in one trial (714). Long-term outcome data from randomized trials in this area are limited by relatively low event rates, potentially underpowering statistical analyses. Kukulska *et al.* (717) followed 390 patients that had been randomized to either 30, 60, or 100 mCi administered activities for remnant ablation, and reported the following event rates after a median period of 10 years following treatment: local relapse in 2% following an initial 30 mCi activity compared to 3% for initial administered activities of 60 or 100 mCi (reported to be not significantly different), and distant metastatic recurrence in 0% of the patients in all of the treatment groups. Maenpaa *et al.* (714) followed 160 patients who were randomized to either 30 or 100 mCi for a median of 51 months, and they reported the following outcomes: reoperation for resection of thyroid cancer in lymph nodes in 7% and 8% of patients who were treated with activities of 30 and 100 mCi, respectively; distant metastatic recurrence in 0% and 4% of patients treated with activities of 30 and 100 mCi, respectively; and no thyroid cancer–related deaths in any of the treatment groups.

Downloaded by Memorial Sloan Kettering from www.liebertpub.com at 08/14/19. For personal use only.

Downloaded by Memorial Sloan Kettering from www.liebertpub.com at 08/14/19. For personal use only.

Overall, the rate of successful remnant ablation in patients who have undergone total or near-total thyroidectomy appears to be not inferior in patients treated with 30 mCi compared to 100 mCi in the majority of studies comparing these activities and particularly in studies achieving the highest successful ablation rates. Rates of short-term adverse effects may be higher after administration of 100 mCi ^{131}I compared to 30 mCi, in a small number of trials examining these outcomes. Limited long-term RCT data on the impact of various activities for remnant ablation or adjuvant therapy are available, but thyroid cancer–related recurrences or deaths do not appear to be higher with the use of lower initial activities for remnant ablation, compared to higher administered activities. Four recent systematic reviews and meta-analyses reported results that are supportive of these conclusions (718–721), although some of the predefined study inclusion criteria in these reviews were generally not as strict as defined in our review (particularly for variables such as the extent of primary surgery or the stringency of Tg threshold in the definition of success of remnant ablation); it is also important to note that in some of these meta-analyses, statistically significant heterogeneity (variability) of treatment effect was noted for the pooled analyses on successful remnant ablation (718,720,721). A recent retrospective database analysis by Verburg *et al.* (722) with longer follow-up than most earlier studies adds a note of caution for the use of lower administered activities in older low-risk patients. They followed 698 patients with low-risk DTC (pT1 or pT2 and no involved LN) for at least 5 years. There were no long-term (10–15 year) overall survival or disease-specific survival differences in younger patients (<45 years old) who received lower administered activities of ^{131}I (≤54 mCi) compared with those receiving higher administered activities. The older patients (≥45 years old), however, who received lower administered activities of ^{131}I (≤54 mCi) did have a lower disease-specific survival compared with those receiving higher administered activities. Disease was defined as abnormal structural or functional imaging or a detectable serum Tg after TSH stimulation. The absolute disease-specific survival remained high even in the patients receiving lower administered activities of ^{131}I, and there were no differences in overall survival in these older patients.

In 2009, the ATA guidelines task force recommended a fixed administered activity of between 100 and 200 mCi for adjuvant RAI treatment if residual microscopic disease is suspected) or if an aggressive histologic variant of DTC was present (25). Since that time, at least five retrospective, single institution studies have compared clinical outcomes following various adjuvant RAI fixed activities in ATA intermediate-risk and ATA higher risk patients, without distant metastases (723–726). In comparing rates of disease persistence or recurrence in 225 ATA intermediate-risk DTC patients treated with 30 to 50 mCi compared to ≥100 mCi of adjuvant RAI, Castagna *et al.* (723) reported no significant difference in rates of successful remnant ablation or in long-term disease persistence/recurrence between groups. However, there were some statistically significant differences between the treatment groups that may have influenced these results, including higher numbers of men and individuals with lateral neck nodal disease and a longer follow-up period (which may increase the rate of detection) in the higher administered activity group of this study (723). In another study including 176 DTC patients with a primary tumor size ≤2 cm in diameter and microscopic extrathyroidal extension, no significant differences were found in a comparison of rates of successful remnant ablation and long-term recurrences in patients treated with 30 mCi ^{131}I compared with 149 mCi (724). In this study, no recurrences were noted in either group after a median follow-up of 7.2 years. Although the mean primary tumor size was higher in the group treated with higher activities compared with the lower activity group in this study ($p < 0.001$), the difference in mean tumor diameter was only 2 mm, so it may be of questionable clinical significance (724). Kruijff *et al.* (725) reported the results of multiple secondary subgroup analyses on data from 341 patients with T3 PTC, in which a postsurgical ^{131}I administered activity of ≤75 mCi was compared to >75 mCi. In this study, the respective rates of disease recurrence, mortality, and stimulated Tg >2 ng/mL were not significantly different in the lower administered activity group (i.e., 7%, 3%, 72%), compared to the higher activity group (12%, 1.7%, 64%) (respective *p*-values of 0.55, 0.43, 0.40). Furthermore, in this study, a multivariate analysis using data from 1171 mixed-risk DTC patients without distant metastases suggested that there was no significant difference in risk of disease recurrence with the use of >75 mCi of ^{131}I postoperatively compared to ≤75 mCi (higher administered activity hazard ratio 1.57 ([95% CI 0.61–3.98], $p = 0.341$), after adjustment for age, sex, primary tumor size, presence of vascular invasion, multifocality, and lymph node positivity, with a mean follow-up period of 60 months) (725). In another study comparing rates of disease structural recurrence/persistence in 181 patients with positive N1b lymph nodes, Sabra *et al.* (726) reported no statistically significant difference between the following approximate fixed administered activity categories: 75–139 mCi with a median of 102 mCi (31%), 140–169 mCi with a median of 150 mCi (32%), and 170–468 mCi with a median of 202 mCi (23%) ($p = 0.17$). Consistent with this finding, no significant correlation between RAI activity and best clinical response was observed in this study. In respective secondary subgroup analyses, a dose response was apparent in individuals ≥45 years of age, but not younger individuals, and the authors cautioned about the use of fixed RAI activities exceeding 150 mCi because of concerns about potential toxicity in the context of renal impairment (726). In the three studies utilizing either thyroid hormone withdrawal or rhTSH for RAI treatment preparation (723,725,726), insufficient data were reported to make any meaningful interpretation on any relationship between administered activity in the context of preparation method. In one study, RAI adjuvant treatment was performed postoperatively, presumably without initiation of thyroid hormone because rhTSH was not reported to be used (724). None of the aforementioned studies (723–726) reported on RAI toxicity or quality of life outcomes; furthermore, T4 disease was not included in these studies. Overall, there is little evidence to suggest that increasing administered activities of adjuvant RAI is necessarily associated with improvement of clinical outcomes for patients with ATA intermediate- and high-risk disease without evidence of persistent disease. There is an important unmet need for RCTs examining thyroid cancer–related outcomes, quality of life, and toxicities in patients with ATA intermediate or higher level thyroid cancer, in the absence of gross residual disease or distant metastases.

[B41] Is a low-iodine diet necessary before remnant ablation?

■ **RECOMMENDATION 57**

A low iodine diet (LID) for approximately 1–2 weeks should be considered for patients undergoing RAI remnant ablation or treatment.

(Weak recommendation, Low-quality evidence)

It is important for health care providers to inquire about a history of possible high-dose iodine exposure (e.g., IV contrast, amiodarone, or others) in considering timing of scheduling RAI therapy or imaging. There are no studies examining whether the use of a LID in preparation for RAI remnant ablation or treatment impacts long-term disease-related recurrence or mortality rates. In a recent systematic review of observational studies in this area, the most commonly studied LIDs allowed for ≤50 μg/d of iodine for 1–2 weeks and that the use of LIDs appeared to be associated with reduction in urinary iodine excretion as well as increase in ^{131}I uptake, compared to no LID (727). There is conflicting evidence on the impact of a LID on the outcome of remnant ablation success (727), with the best available evidence largely restricted to retrospective analyses, using historical controls (728,729). In a study including a total of 120 patients, the use of a 4-day LID (with seafood restriction for 1 week) was associated with a higher rate of remnant ablation success (defined by absent neck activity and stimulated Tg <2 ng/mL) compared to no LID (728). In a study including a total of 94 patients, comparing a more stringent LID to a less stringent diet of restricted salt/vitamins/seafood, each for 10 to 14 days, there was no significant difference in rate of successful remnant ablation, using a visually negative ^{131}I scan to define that outcome (729). The optimal stringency and duration of LID (if any) prior to therapeutic RAI is not known. In a RCT including 46 patients, the increase in ^{131}I uptake and reduction in urinary iodine excretion was not significantly different between patients who followed a LID for 2 weeks compared to 3 weeks prior to RAI scanning (730), suggesting that there may be little reason to extend the LID past 2 weeks. However, a lack of association between urinary iodine excretion and rate of successful thyroid ablation has been reported in patients not specifically prescribed a LID (731); the absence of a specific LID comparison group in this study may limit the generalizability of the findings to situations in which a specific LID is prescribed. Such findings may suggest, however, that the routine measurement of urinary iodine excretion, outside of possibly a research setting or suspected iodine contamination, may not be necessary. Although LIDs may be cumbersome or unpalatable, serious side effects are relatively infrequent (727), with case reports of potentially life-threatening hyponatremia occurring largely in elderly patients who were subject to thyroid hormone withdrawal, often in the presence of metastatic disease, sometimes concurrently treated with thiazide diuretics, and with a LID duration of longer than a week in the majority of cases (732). It is important to avoid restriction of noniodized salt during the LID, since this may be associated with hyponatremia, especially in patients undergoing thyroid hormone withdrawal. Some examples of LID descriptions for patients, may be found at the following websites: ATA (www.thyroid.org/faq-low-iodine-diet/), ThyCa: Thyroid Cancer Survivors' Association, Inc. (http://thyca.org/rai.htm#diet), Light of Life Foundation (www.checkyourneck.com/About-Thyroid-Cancer/Low-Iodine-Cookbook), and Thyroid Cancer Canada (www.thyroidcancercanada.org/userfiles/files/LID_English_Aug_2013_final.pdf).

[B42] Should a posttherapy scan be performed following remnant ablation or adjuvant therapy?

■ **RECOMMENDATION 58**

A posttherapy WBS (with or without SPECT/CT) is recommended after RAI remnant ablation or treatment, to inform disease staging and document the RAI avidity of any structural disease.

(Strong recommendation, Low-quality evidence)

The literature on the utility of posttherapy RAI scans is largely based on single-center retrospective studies (643,733–736), many of which included a relatively large proportion of ATA intermediate- and high-risk DTC patients (643,733,734). In a comparison of the results of pretherapy ^{131}I scans to posttherapy scans, the rate of newly discovered lesions on posttherapy scans was reported to be between 6% and 13%. In a study examining post–remnant ablation scans in 60 DTC patients, the disease stage was altered in 8.3% of individuals (735). In older literature, it had been reported that posttherapy scanning demonstrated new findings in 31% of 39 cases studied, but the detection of thyroid foci was included in that outcome, whereas almost a third of the patients (12 of 39) had a sizeable portion of their thyroid remaining following primary surgery (736). In the recent posttherapy scan literature, the ^{131}I activities ranged from 30 to 300 mCi (733–735), and the timing of scans was between 2 and 12 days following therapeutic RAI (643,733–735,737,738), with some studies prescribing a preparatory LID (643,735,738) and others not prescribing such a diet (733,734). In one study, posttherapy scan images were compared on the third and seventh day following ablative or therapeutic RAI administration for mixed-risk DTC (following thyroid hormone withdrawal) (738). The authors of this study reported that the concordance of lesions detected on both scans was 80.5% (108 of 135 patients), with 7.5% of early scans providing more information than late scans, and 12% of late scans providing more information than early scans (738). A limitation in interpreting the posttherapy scan literature is that all of the lesions identified on posttherapy scans were not always confirmed to represent structural disease (i.e., using cross-sectional imaging, histopathology, or long-term outcome data), and readers of posttherapy scans were generally not specifically blinded to the results of other investigations, such as pretherapy RAI scans.

The potential utility of the combination of RAI posttherapy scanning in conjunction with SPECT/CT has been examined in multiple prospective (737,739,740) and retrospective studies (741–743). The majority of these studies (737,739–742) have independently confirmed the presence of disease by means such as alternative imaging studies, histopathology, or clinical follow-up. In a single-center

Downloaded by Memorial Sloan Kettering from www.liebertpub.com at 08/14/19. For personal use only.

study of 170 patients with mixed risk level well-differentiated thyroid cancer, the combination RAI posttherapy scanning and neck/thorax SPECT/CT, was estimated to have a sensitivity of 78% [95% CI 60%–90%], with a specificity of 100% (negative or indeterminate scans were grouped as negative), for the outcome of persistent/recurrent disease (median study follow-up period of 29 months) (737). Furthermore, in a multivariate analysis reported in this study, posttherapy RAI scanning with SPECT/CT significantly independently predicted an increased risk of future disease persistence/recurrence (HR 65.2 [95% CI 26.0–163.4) (737). In a single-center study of 81 DTC patients who underwent ^{131}I posttherapy scanning in conjunction with SPECT-spiral CT of the neck, 1.6% of the 61 patients with negative cervical scintigraphy–SPECT/CT had evidence of abnormal cervical scintigraphy 5 months later, whereas 3 of the 20 patients (15%) with positive or indeterminate cervical posttherapy scintigraphy–SPECT/CT, had abnormal cervical scintigraphy 5 months later (741). The incremental value of SPECT/CT in impacting therapeutic planning appears to be greatest in studies in which its use was reserved for situations of posttherapy scan diagnostic uncertainty (impacted therapy in 24.4% [8 of 33] of cases, all of which went on to surgery) (739), or when disease was advanced and WBS was inconclusive (impacted management in 35% [8 of 23] of such patients in another study) (740). The routine addition of neck/chest SPECT/CT to all posttherapy scans was estimated to alter postsurgical ATA recurrence risk estimate in 6.4% (7 of 109) of patients (743), impact therapeutic planning in about 2% of cases (742), and reduce the need for additional cross-sectional imaging in 20% of cases (29 of 148). In one study examining the use of routine cervical/thoracic SPECT/CT in conjunction with posttherapy scanning, the SPECT/CT portion identified non–iodine avid lesions in 22% of patients (32 of 148), although the underlying pathologic diagnosis or long-term clinical significance of these lesions was not clearly reported (i.e., ''tiny'' lung nodules in 19 patients, mediastinal lymph nodes <5 mm in 10 patients, and osteolytic bone metastases in three patients) (743). In situations in which SPECT/CT may not be feasible to perform in conjunction with a posttherapy RAI scan, clinical judgment needs to prevail on the utility of alternative cross-sectional imaging studies, considering factors such as clinical-pathologic stage, the completeness of surgery, inappropriate thyroglobulinemia, and, if performed, the posttherapy RAI scan result.

[B43] Early management of DTC after initial therapy

[B44] What is the appropriate degree of initial TSH suppression?

■ RECOMMENDATION 59

(A) For high-risk thyroid cancer patients, initial TSH suppression to below 0.1 mU/L is recommended.

(Strong recommendation, Moderate-quality evidence)

(B) For intermediate-risk thyroid cancer patients, initial TSH suppression to 0.1– 0.5 mU/L is recommended.

(Weak recommendation, Low-quality evidence)

(C) For low-risk patients who have undergone remnant ablation and have undetectable serum Tg levels, TSH may be maintained at the lower end of the reference range (0.5–2 mU/L) while continuing surveillance for recurrence. Similar recommendations hold for low-risk patients who have not undergone remnant ablation and have undetectable serum Tg levels.

(Weak recommendation, Low-quality evidence)

(D) For low-risk patients who have undergone remnant ablation and have low-level serum Tg levels, TSH may be maintained at or slightly below the lower limit of normal (0.1–0.5 mU/L) while surveillance for recurrence is continued. Similar recommendations hold for low-risk patients who have not undergone remnant ablation, although serum Tg levels may be measurably higher and continued surveillance for recurrence applies.

(Weak recommendation, Low-quality evidence)

(E) For low-risk patients who have undergone lobectomy, TSH may be maintained in the mid to lower reference range (0.5–2 mU/L) while surveillance for recurrence is continued. Thyroid hormone therapy may not be needed if patients can maintain their serum TSH in this target range.

(Weak recommendation, Low-quality evidence)

DTC expresses the TSH receptor on the cell membrane and responds to TSH stimulation by increasing the expression of several thyroid specific proteins (Tg, sodium-iodide symporter) and by increasing the rates of cell growth (744). Suppression of TSH, using supraphysiologic doses of LT_4, is used commonly to treat patients with thyroid cancer in an effort to decrease the risk of recurrence (275,671,745–747). A meta-analysis supported the efficacy of TSH suppression therapy in preventing major adverse clinical events (RR = 0.73 [CI = 0.60–0.88], $p < 0.05$) (745). A large RCT from Japan (748) showed that disease-free survival was equivalent in patients with normal TSH (0.4–5 mU/L) compared with those on LT_4 suppression therapy (TSH <0.01 mU/L). Extent of residual disease is uncertain in these patients in that most did not undergo total thyroidectomy or RAI ablation and Tg levels were not monitored or reported, making direct comparisons to a North American approach difficult.

Retrospective and prospective studies have demonstrated that TSH suppression to below 0.1 mU/L may improve outcomes in high-risk thyroid cancer patients (275,749), though no such evidence of benefit has been documented in low-risk patients. Higher degrees of suppression to <0.03 mU/L may offer no additional benefit (746). A prospective, nonrandomized cohort study (671) of 2936 patients found that overall survival improved significantly when the TSH was suppressed to undetectable levels in patients with NTCTCSG stage III or IV disease and suppressed to the subnormal to undetectable range in patients with NTCTCSG stage II disease; however, in the latter group there was no incremental benefit from suppressing TSH to undetectable levels. Patients in the NTCTCSG stage II classification are somewhat different from AJCC/UICC stage II patients. Suppression of TSH was not beneficial in patients with NTCTCSG stage I disease. In another study, there was a positive association between serum TSH levels and the risk for recurrent

Downloaded by Memorial Sloan Kettering from www.liebertpub.com at 08/14/19. For personal use only.

disease and cancer-related mortality (750). Adverse effects of TSH suppression may include the known consequences of subclinical thyrotoxicosis, including exacerbation of angina in patients with ischemic heart disease, increased risk for atrial fibrillation in older patients (751), and increased risk of osteoporosis in postmenopausal women (748,752–754). Therefore, optimal TSH goals for individual patients must balance the potential benefit of TSH suppression with the possible harm from subclinical thyrotoxicosis especially in patients with medical conditions that can be exacerbated with aggressive TSH suppression.

There is little evidence to guide TSH targets or the use of thyroid hormone in ATA low-risk patients who have undergone lobectomy. Most of the studies evaluating lobectomy for these patients do not discuss TSH targets or the use of thyroid hormone therapy or note that these data were unavailable in the databases studied (318,323–327). Vaisman *et al.* (328) noted that ''levothyroxine was often not given after lobectomy if the patient maintained thyroid function tests within the reference range,'' while Matsuzu *et al.* (322) noted that ''TSH suppression therapy was performed in most of the cases postoperatively, but the patients' TSH levels were not analyzed in this study.'' A recent study by Ebina *et al.* (755) retrospectively analyzed low-risk patients who had undergone lobectomy and had not received thyroid hormone therapy. After a mean follow-up of 8.3 years, only 13% of the 674 patients undergoing lobectomy became overtly hypothyroid. The 10-year cause-specific and disease-specific survivals were not different between the patients who underwent thyroidectomy versus a lesser operation, although it was common for the patients undergoing lobectomy to also receive an ipsilateral central neck dissection. More research is needed in this area to help guide management of those patients undergoing lobectomy for low-risk DTC.

[B45] Is there a role for adjunctive external beam radiation therapy or chemotherapy?

[B46] External beam radiation therapy

■ **RECOMMENDATION 60**

There is no role for routine adjuvant EBRT to the neck in patients with DTC after initial complete surgical removal of the tumor.

(Strong recommendation, Low-quality evidence)

The application of adjuvant neck/thyroid bed/loco-regional radiation therapy in DTC patients remains controversial. In particular, the use of radiation therapy within the context of initial/primary surgery/thyroidectomy has no meaningful literature support. There are reports of responses among patients with locally advanced disease (756,757) and improved relapse-free and cause-specific survival in patients over age 60 with extrathyroidal extension but no gross residual disease (758), and selective use can be considered in these patients. It remains unknown whether external beam radiation therapy might reduce the risk for recurrence in the neck following adequate primary surgery and/or RAI treatment in patients with aggressive histologic subtypes (759). However, in the context of certain individual patients undergoing multiple and frequent serial neck re-operations for palliation of loco-regionally recurrent disease, adjuvant EBRT may be considered. In such contexts, the risks of anticipated additional serial re-operations versus the risks of EBRT must be carefully weighed to arrive at optimal decisions for individual patients. The approach to patients with gross incomplete surgical resection of disease is addressed in another section (Recommendation 72).

[B47] Systemic adjuvant therapy

■ **RECOMMENDATION 61**

There is no role for routine systemic adjuvant therapy in patients with DTC (beyond RAI and/or TSH suppressive therapy using LT_4).

(Strong recommendation, Low-quality evidence)

There are no clinical trial data to indicate that any adjuvant therapy beyond RAI and/or TSH suppressive therapy using LT_4 has a net beneficial role in DTC patients. Furthermore, as the prognosis of DTC patients in complete remission and without any indication of active systemic disease is very good—and as toxicities, and even the risk of death, from use of kinase inhibitor therapies are appreciable—toxicities/risks have strong potential to exceed expected therapeutic benefit in the adjuvant context in most patients with DTC.

Whether populations of DTC patients might be identifiable who have sufficiently great future risks from recurrent disease to justify the corresponding risks attendant to the application of adjuvant systemic therapy (beyond RAI and/or TSH suppressive therapy using LT_4) remains uncertain. Doxorubicin may act as a radiation sensitizer in some tumors of thyroid origin (760) and could be considered for patients with locally advanced disease undergoing external beam radiation therapy. It is unproven whether patients with rising Tg in the setting of no identifiable progression of anatomical disease have sufficiently high future risks from disease to justify the application of adjuvant systemic therapy beyond RAI and/or TSH suppressive therapy using LT_4.

[C1] DTC: LONG-TERM MANAGEMENT AND ADVANCED CANCER MANAGEMENT GUIDELINES

[C2] What are the appropriate features of long-term management?

Accurate surveillance for possible recurrence in patients thought to be free of disease is a major goal of long-term follow-up. Tests with high specificity allow identification of patients unlikely to experience disease recurrence, so that less aggressive management strategies can be used that may be more cost effective and safe. Similarly, patients with a higher risk of recurrence are monitored more aggressively because it is believed that early detection of recurrent disease offers the best opportunity for effective treatment. A large study (761) found that the residual life span in disease-free patients treated with total or near-total thyroidectomy, ^{131}I for remnant ablation, and in some cases high-dose ^{131}I for residual disease was similar to that in the general Dutch population. In contrast, the life expectancy for patients with persistent disease was reduced to 60% of that in the general population but varied widely depending upon tumor features. Age was not a factor in disease-specific mortality in a comparison of patients with age-matched individuals in the Dutch population. Treatment thus appears safe and does not shorten life expectancy. Although an increased incidence of second tumors in thyroid

Downloaded by Memorial Sloan Kettering from www.liebertpub.com at 08/14/19. For personal use only.

cancer patients has been recognized after the administration of high cumulative activities of ^{131}I (762,763), this elevated risk was not found to be associated with the use of ^{131}I in another study (764). RAI therapy in low-risk patients did not affect median overall survival in one study (765), but did increase second primary malignancies in another study (766). This risk of second primary malignancies after RAI therapy is discussed in more detail in section C33. Patients with persistent or recurrent disease are offered treatment to cure or to delay future morbidity or mortality. In the absence of such options, therapies to palliate by substantially reducing tumor burden or preventing tumor growth are utilized, with special attention paid to tumors threatening critical structures.

A second goal of long-term follow-up is to monitor thyroxine suppression or replacement therapy to avoid under-replacement or overly aggressive therapy (767).

[C3] What are the criteria for absence of persistent tumor (excellent response)?

In patients who have undergone total or near-total thyroidectomy and RAI treatment (remnant ablation, adjuvant therapy or therapy), disease-free status comprises all of the following (summarized in Table 13):

1. No clinical evidence of tumor
2. No imaging evidence of tumor by RAI imaging (no uptake outside the thyroid bed on the initial posttreatment WBS if performed, or if uptake outside the thyroid bed had been present, no imaging evidence of tumor on a recent diagnostic or posttherapy WBS) and/or neck US
3. Low serum Tg levels during TSH suppression (Tg <0.2 ng/mL) or after stimulation (Tg <1 ng/mL) in the absence of interfering antibodies

[C4] What are the appropriate methods for following patients after initial therapy?

[C5] What is the role of serum Tg measurement in the follow-up of DTC?

■ RECOMMENDATION 62

(A) Serum Tg should be measured by an assay that is calibrated against the CRM457 standard. Thyroglobulin antibodies should be quantitatively assessed with every measurement of serum Tg. Ideally, serum Tg and anti-Tg antibodies should be assessed longitudinally in the same laboratory and using the same assay for a given patient.

(Strong recommendation, High-quality evidence)

(B) During initial follow-up, serum Tg on thyroxine therapy should be measured every 6–12 months. More frequent Tg measurements may be appropriate for ATA high-risk patients.

(Strong recommendation, Moderate-quality evidence)

(C) In ATA low- and intermediate-risk patients that achieve an excellent response to therapy, the utility of subsequent Tg testing is not established. The time interval between serum Tg measurements can be lengthened to at least 12–24 months.

(Weak recommendation, Low-quality evidence)

(D) Serum TSH should be measured at least every 12 months in all patients on thyroid hormone therapy.

(Strong recommendation, Low-quality evidence)

(E) ATA high-risk patients (regardless of response to therapy) and all patients with biochemical incomplete, structural incomplete, or indeterminate response should continue to have Tg measured at least every 6–12 months for several years.

(Weak recommendation, Low-quality evidence)

■ RECOMMENDATION 63

(A) In ATA low-risk and intermediate-risk patients who have had remnant ablation or adjuvant therapy and negative cervical US, serum Tg should be measured at 6–18 months on thyroxine therapy with a sensitive Tg assay (<0.2 ng/mL) or after TSH stimulation to verify absence of disease (excellent response).

(Strong recommendation, Moderate-quality evidence)

(B) Repeat TSH-stimulated Tg testing is not recommended for low- and intermediate-risk patients with an excellent response to therapy.

(Weak recommendation, Low-quality evidence)

(C) Subsequent TSH-stimulated Tg testing may be considered in patients with an indeterminate, biochemical incomplete, or structural incomplete response following either additional therapies or a spontaneous decline in Tg values on thyroid hormone therapy over time in order to reassess response to therapy.

(Weak recommendation, Low-quality evidence)

Subsequent stimulated testing is rarely needed for those with NED, because there are rarely benefits seen in this patient population from repeated TSH-stimulated Tg testing (590,594,597,768). The use of sensitive methods for serum Tg may obviate the need for rhTSH stimulation in low-risk patients with a Tg on LT_4 treatment below 0.1–0.2 ng/mL (393,587,595,601,606,769).

[C6] Serum Tg measurement and clinical utility

Measurement of serum Tg levels is an important modality to monitor patients for residual or recurrent disease. Most laboratories currently use immunometric assays to measure serum Tg, and it is important that these assays are calibrated against the CRM-457 international standard. Despite improvements in standardization of Tg assays, there is still a two-fold difference between some assays (316,770), leading to the recommendation that measurements in individual patients be performed with the same assay over time. Immunometric assays are prone to interference from anti-Tg autoantibodies, which commonly cause falsely low serum Tg measurements. Moreover, variability in Tg autoantibody assays may result in falsely negative antibody levels associated with a misleadingly undetectable serum Tg due to the antibodies that are present but not detected (771). Assays for anti-Tg autoantibodies suffer from a similar variance and lack of concordance as do Tg assays (608,772), and both Tg and Tg autoantibody assays may be affected by heterophilic antibodies (773,774). The presence of Tg autoantibodies should be suspected when the surgical pathology indicates the presence of background Hashimoto thyroiditis (775). While there

Downloaded by Memorial Sloan Kettering from www.liebertpub.com at 08/14/19. For personal use only.

Downloaded by Memorial Sloan Kettering from www.liebertpub.com at 08/14/19. For personal use only.

is no method that reliably eliminates Tg antibody interference, radioimmunoassays for Tg may be less prone to antibody interference, which can occasionally result in falsely elevated Tg levels (776–778). However, radioimmunoassays for Tg are not as widely available, may be less sensitive than immunometric assays in detecting small amounts of residual tumor, and their role in the clinical care of patients is uncertain. In the absence of antibody interference, serum Tg has a high degree of sensitivity and specificity to detect thyroid cancer, especially after total thyroidectomy and remnant ablation. In patients with low risk for recurrence, serum Tg measurement at the time of remnant ablation/adjuvant therapy may be useful for prediction of subsequent disease-free status (605).

Most data come from studies using methods with a functional sensitivity of 1 ng/mL. Functional sensitivity of many contemporary assays is ≤0.1 ng/mL, which may lead to greater reliance of Tg on thyroid hormone therapy instead of performing Tg determination following TSH stimulation. Because TSH stimulation generally increases basal serum Tg by 5- to 10-fold, significant serum Tg levels (>1–2 ng/mL) found after TSH stimulation when using an assay with a functional sensitivity of 0.5–1 ng/mL may already be predicted in patients on LT4 treatment without TSH stimulation by a highly sensitive Tg assay when Tg levels are above 0.2 ng/mL.

The highest degrees of sensitivity for serum Tg are noted following thyroid hormone withdrawal or stimulation using rhTSH (779). Serum Tg measurements obtained during thyroid hormone suppression of TSH and less commonly following TSH stimulation may fail to identify patients with relatively small amounts of residual tumor (583,649, 780,781). These minimal amounts of residual disease are often located in the neck, and performing neck US in these patients offers the best opportunity to recognize or exclude neoplastic disease even when serum Tg is undetectable (297,782,783). Conversely, even TSH-stimulated Tg measurement may fail to identify patients with clinically significant tumor because of anti-Tg antibodies or less commonly because of defective or absent production and secretion of immunoreactive Tg by tumor cells (649,780). Tg levels should be interpreted in light of the pretest probability of clinically significant residual tumor. An aggressive or poorly differentiated tumor may be present despite low basal or stimulated Tg; in contrast, a minimally elevated stimulated Tg may occur in patients at low risk for clinically significant morbidity (784). Nevertheless, a single rhTSH-stimulated serum Tg <0.5–1.0 ng/mL in the absence of anti-Tg antibody has an approximately 98%–99.5% likelihood of identifying patients completely free of tumor on follow-up (590,591,593,597,768). Repeating rhTSH-stimulated Tg measurements may not be necessary in most cases when surveillance includes an undetectable basal serum Tg and negative ultrasonography (604,617). However, 0.5%–3% of patients may manifest clinical or biochemical recurrence in spite of an initial rhTSH-stimulated Tg of <0.5 ng/mL (592).

Initial follow-up for low-risk patients (about 85% of postoperative patients) who have undergone total or near-total thyroidectomy and ^{131}I remnant ablation should be based mainly on TSH-suppressed Tg and cervical US, followed by TSH-stimulated serum Tg measurements if the TSH-suppressed Tg testing is undetectable (583,785). However, a Tg assay with a functional sensitivity of 0.1–0.2 ng/mL may reduce the need to perform TSH-stimulated Tg measurements during the initial and long-term follow-up of some patients. In one study using such an assay, a T_4-suppressed serum Tg <0.1 ng/mL was only rarely (2%) associated with an rhTSH-stimulated Tg >2 ng/mL; however, 42% of the patients had baseline rhTSH-stimulated Tg elevation >0.1 ng/mL, but only one patient was found to have residual tumor (606). In another study using the same assay (787), a TSH-suppressed serum Tg level was >0.1 ng/mL in 14% of patients, but the false-positive rate was 35% using an rhTSH-stimulated Tg cutoff of >2 ng/mL, raising the possibility of unnecessary testing and treatment. In low-risk patients not undergoing ablation, an ultrasensitive Tg was <1 ng/mL in 91% and <2 ng/mL in 96% of patients at 9 months after thyroidectomy (644). In a second-generation assay, a cutoff of 0.15 ng/mL was shown to have a NPV of 98.6% and 91% specificity for residual disease or potential recurrence (587). The only prospective study also documented increased sensitivity of detection of disease at the expense of reduced specificity (770), and receiver operating curves have shown that a Tg level on thyroid hormone therapy around 0.2–0.3 ng/mL portends the best sensitivity and specificity for detecting persistent disease. With the use of these sensitive Tg assays, it was concluded that an annual serum Tg on LT_4 treatment with periodic neck US is adequate for detection of recurrence without need for rhTSH stimulation testing in those patients with a serum Tg <0.2–0.3 ng/mL on thyroid hormone therapy (606). In patients at low to intermediate risk of recurrence, the utility of an undetectable postoperative nonstimulated Tg level is uncertain and may depend upon the functional sensitivity of the Tg assay, with some studies (632,646) observing RAI-avid metastatic foci (usually in neck lymph nodes) in 8.5%–12% of such patients, while another study (630) noted negative scans in 63 of 63 patients when the baseline Tg was <0.2 ng/mL. The different results likely relate to both the degree of intermediate versus higher risk patients in the respective cohorts, the amount of residual thyroid tissue, the elapsed time since surgery, the cutoff for functional sensitivity of the Tg assays, as well as the sensitivity of the post-RAI imaging techniques.

Approximately 20% of patients who are clinically free of disease with serum Tg levels <1 ng/mL during thyroid hormone suppression of TSH (785) will have a serum Tg level >2 ng/mL after rhTSH or thyroid hormone withdrawal at 12 months after initial therapy with surgery and RAI. In this patient population, one-third will have identification of persistent or recurrent disease and of increasing Tg levels, and the other two-thirds will remain free of clinical disease and will have stable or decreasing stimulated serum Tg levels over time (618,624). However, there may be a low likelihood of a rise in serum Tg to >2 ng/mL when the basal serum Tg is <0.1 ng/mL if a second-generation Tg immunochemiluminometric assay (ICMA) with a functional sensitivity of 0.05 ng/mL is employed (788). There is good evidence that a Tg cutoff level above 2 ng/mL following rhTSH stimulation is highly sensitive in identifying patients with persistent tumor (785,789–794). However, the results of serum Tg measurements made on the same serum specimen differ among assay methods (316). Therefore, the Tg cutoff may differ significantly among medical centers and laboratories. Further, the clinical significance of minimally

detectable Tg levels is unclear, especially if only detected following TSH stimulation. However, receiver operating curves have shown that a Tg level on thyroid hormone around 0.2–0.3 ng/mL portends the best sensitivity and specificity for detecting persistent disease. In these patients, the trend in serum Tg over time will typically identify patients with clinically significant residual disease. A rising unstimulated or stimulated serum Tg indicates disease that is likely to become clinically apparent (618,795). Thyroglobulin doubling time may have utility as a predictor of recurrence, analogous to the use of calcitonin doubling time for MTC (622,796).

[C7] Anti-Tg antibodies

The presence of anti-Tg antibodies, which occur in approximately 25% of thyroid cancer patients (797) and 10% of the general population (798), will falsely lower serum Tg determinations in immunometric assays (799). The use of recovery assays in this setting to detect significant interference is controversial (799,800). Serum anti-Tg antibody should be measured in conjunction with serum Tg assay by an immunometric method. Although assay standardization against the International Reference Preparation 65/93 has been recommended (608), wide-ranging variability in assay results and analytical sensitivity of the assay remains (801,802). Use of recovery methods for anti-Tg antibody may suffer variable interferences (608). Anti-Tg antibody may rise transiently postoperatively as an apparent immune reaction to the surgery itself and may also rise after ablation therapy (611). Anti-Tg antibodies should be measured in a different assay if the routine anti-Tg antibody assay is negative in a patient with surgically proven Hashimoto thyroiditis (775). It may be useful to measure anti-Tg antibodies shortly after thyroidectomy and prior to ablation because high levels may herald the likelihood of recurrence in patients without Hashimoto thyroiditis (801). Similarly, recurrent or progressive disease is suggested in those patients initially positive for anti-Tg antibodies who then become negative but subsequently have rising levels of anti-Tg antibodies. Falling levels of anti-Tg antibodies may indicate successful therapy (614,801). Thus, serial serum anti-Tg antibody quantification using the same methodology may serve as an imprecise surrogate marker of residual normal thyroid tissue, Hashimoto thyroiditis, or tumor (608,609,615). Following total thyroidectomy and RAI remnant ablation, anti-Tg antibodies usually disappear over a median of about 3 years in patients without evidence of persistent disease (611,615,616). Several studies demonstrate an increased risk of recurrence/persistent disease associated either with a new appearance of anti-Tg antibodies or rising titers (609–614). From a clinical perspective, anti-Tg antibody levels that are declining over time are considered a good prognostic sign, while rising antibody levels, in the absence of an acute injury to the thyroid (release of antigen by surgery or RAI treatment), significantly increases the risk that the patient will subsequently be diagnosed with persistent or recurrent thyroid cancer.

The recent development of liquid chromatography-tandem mass spectrometry assay of Tg holds promise for accurate Tg measurement in the presence of Tg autoantibodies (803–805), but further studies will be required to validate the assays in terms of functional sensitivity, correlations with immunoassay results, and patient outcomes, reflecting either excellent response or persistent disease (806).

[C8] What is the role of serum Tg measurement in patients who have not undergone RAI remnant ablation?

■ **RECOMMENDATION 64**

Periodic serum Tg measurements on thyroid hormone therapy should be considered during follow-up of patients with DTC who have undergone less than total thyroidectomy and in patients who have had a total thyroidectomy but not RAI ablation. While specific cutoff levels of Tg that optimally distinguish normal residual thyroid tissue from persistent thyroid cancer are unknown, rising Tg values over time are suspicious for growing thyroid tissue or cancer.

(Strong recommendation, Low-quality evidence)

In low- and intermediate-risk patients who underwent a total thyroidectomy without remnant ablation or adjuvant therapy, the same strategy of follow-up is used, based on serum Tg determination on LT_4 treatment and on neck US at 9–12 months. In most of these patients, neck US does not reveal any suspicious findings and the serum Tg is <1 ng/mL on LT_4 treatment, is low (<2 ng/mL) and will remain at a low level, or will decrease without any additional therapy over time (545). There is no need for rhTSH stimulation because Tg will increase to a value above 1 ng/mL in 50% of the cases, even in individuals without residual cancer, with the magnitude of increase being related to the size of normal thyroid remnants (783). These patients are followed on an annual basis with serum TSH and Tg determination.

In the few patients with a serum Tg that remains elevated over time, especially for those with a rising Tg, remnant ablation or adjuvant therapy with ^{131}I may be considered with a posttherapy WBS if neck US is negative. There is no evidence in these low-risk patients that a delayed treatment over the postoperative treatment may adversely affect the outcome.

A cohort of 80 consecutive patients with very low-risk PTMC who had undergone near-total thyroidectomy without postoperative RAI treatment were studied over 5 years (783). The rhTSH-stimulated serum Tg levels were ≤1 ng/mL in 45 patients (56%) and >1 ng/mL in 35 (44%) patients in whom rhTSH-stimulated Tg levels were as high as 25 ng/mL. The diagnostic WBS revealed uptake in the thyroid bed but showed no pathological uptake in any patient, and thyroid bed uptake correlated with the rhTSH-stimulated serum Tg levels ($p < 0.0001$). Neck ultrasonography identified lymph node metastases in both Tg-positive and Tg-negative patients. The authors concluded that for follow-up of this group of patients: (i) diagnostic WBS was ineffective at detecting metastases; (ii) neck ultrasonography as the main surveillance tool was highly sensitive in detecting lymph node metastases; and (iii) detectable rhTSH-stimulated serum Tg levels mainly depended upon the size of thyroid remnants, which suggests that serum Tg determination should be performed primarily on thyroid hormone therapy when using a sensitive Tg assay (functional sensitivity ≤0.2 ng/mL). In a series of 290 low-risk patients who had not undergone remnant ablation (545), serum Tg levels on LT_4 became undetectable (<1 ng/mL) within 5–7 years in 95% of the cohort and was <0.1 ng/mL in 80% of a subset of these patients, using a sensitive assay to confirm the utility of Tg measurements on thyroid hormone treatment

Downloaded by Memorial Sloan Kettering from www.liebertpub.com at 08/14/19. For personal use only.

for routine follow-up. The frequency of follow-up is uncertain in patients who have not received RAI ablation and have sufficient residual thyroid tissue to produce measurable levels of serum Tg, the magnitude of which will depend upon the mass of residual tissue and the degree of TSH suppression. It appears reasonable to consider periodic measurements of Tg as surveillance for a trend in rising values.

[C9] What is the role of US and other imaging techniques (RAI SPECT/CT, CT, MRI, PET-CT) during follow-up?

[C10] Cervical ultrasonography

■ **RECOMMENDATION 65**

(A) Following surgery, cervical US to evaluate the thyroid bed and central and lateral cervical nodal compartments should be performed at 6–12 months and then periodically, depending on the patient's risk for recurrent disease and Tg status.

(Strong recommendation, Moderate-quality evidence)

(B) If a positive result would change management, ultrasonographically suspicious lymph nodes ≥8–10 mm (see Recommendation 71) in the smallest diameter should be biopsied for cytology with Tg measurement in the needle washout fluid.

(Strong recommendation, Low-quality evidence)

(C) Suspicious lymph nodes less than 8–10 mm in smallest diameter may be followed without biopsy with consideration for FNA or intervention if there is growth or if the node threatens vital structures.

(Weak recommendation, Low-quality evidence)

(D) Low-risk patients who have had remnant ablation, negative cervical US, and a low serum Tg on thyroid hormone therapy in a sensitive assay (<0.2 ng/mL) or after TSH stimulation (Tg <1 ng/mL) can be followed primarily with clinical examination and Tg measurements on thyroid hormone replacement.

(Weak recommendation, Low-quality evidence)

Cervical ultrasonography is performed with a high-frequency probe (≥10 MHz) and is highly sensitive in the detection of cervical metastases in patients with DTC (290,783,807). These studies primarily evaluate patients with PTC, and the utility of neck US for monitoring patients with low-risk FTC is not well-established. Neck US should interrogate all lymph node compartments and the thyroid bed. Frequently, US does not distinguish thyroid bed recurrences from benign nodules (629,808). When an abnormality is found during the year after surgery in patients without any other suspicious findings, including low serum Tg on thyroid hormone therapy, follow-up may be performed with neck US.

A correlation performed between US findings and pathology at surgery (292) has shown for lymph nodes >7 mm in the smallest diameter that a cystic appearance or hyperechoic punctuations in a context of thyroid cancer should be considered as malignant; lymph nodes with a hyperechoic hilum are reassuring; the type of vascularization (central: reassuring; peripheral: concerning) has a high sensitivity/specificity; a round shape, a hypoechoic appearance or the loss of the hyperechoic hilum by themselves does not justify a FNA biopsy (FNAB).

Interpretation of neck US should take into account all other clinical and biological data. In fact, the risk of recurrence is closely related to the initial lymph node status: most lymph node recurrences occur in already involved compartments; the risk increases with a higher number of N1 and a higher number of N1 with extracapsular extension (338) and with macroscopic rather than microscopic lymph node metastases (335,809).

In low- and intermediate-risk patients, the risk of lymph node recurrence is low (<2%) in patients with undetectable serum Tg and is much higher in those with detectable/elevated serum Tg. In fact, 1 g of neoplastic thyroid tissue will increase the serum Tg by ~1 ng/mL during LT_4 treatment and by approximately 2–10 ng/mL following TSH stimulation (788,800). Neck US can detect N1 as small as 2–3 mm in diameter (in patients in whom serum Tg may be low or undetectable), but benefits of their early discovery (<8–10 mm) is not demonstrated.

FNAB for cytology and Tg measurement in the aspirate fluid is performed for suspicious lymph nodes ≥8–10 mm in their smallest diameter. US guidance may improve the results of FNAB, in particular for small lymph nodes and those located deep in the neck. However, FNAB cytology misses thyroid cancer in a significant proportion (up to 20%) of patients. The combination of cytology and serum Tg determination in the aspirate fluid increases sensitivity (303,810,811). In cases of lymph node metastases, the Tg concentration in the aspirate fluid is often elevated (>10 ng/mL), and concentrations above this level are highly suspicious (296,298,301). A Tg concentration in the aspirate fluid between 1 and 10 ng/mL is moderately suspicious for malignancy, and comparison of the Tg measurement in the aspirate fluid and the serum should be considered in these patients. Also, up to half of the FNAB performed for suspicious US findings are benign, demonstrating that selection of patients for FNAB needs to be improved (296,298,812). Nonsuspicious and small nodes (<8–10 mm in the smallest diameter) can be monitored with neck US.

[C11] Diagnostic whole-body RAI scans

■ **RECOMMENDATION 66**

After the first posttreatment WBS performed following RAI remnant ablation or adjuvant therapy, low-risk and intermediate-risk patients (lower risk features) with an undetectable Tg on thyroid hormone with negative anti-Tg antibodies and a negative US (excellent response to therapy) do not require routine diagnostic WBS during follow-up.

(Strong recommendation, Moderate-quality evidence)

■ **RECOMMENDATION 67**

(A) Diagnostic WBS, either following thyroid hormone withdrawal or rhTSH, 6–12 months after adjuvant RAI therapy can be useful in the follow-up of patients with high or intermediate risk (higher risk features) of persistent disease (see risk stratification system, section [B19]) and should be done with ^{123}I or low activity ^{131}I.

(Strong recommendation, Low-quality evidence)

B) SPECT/CT RAI imaging is preferred over planar imaging in patients with uptake on planar imaging to better

Downloaded by Memorial Sloan Kettering from www.liebertpub.com at 08/14/19. For personal use only.

anatomically localize the RAI uptake and distinguish between likely tumors and nonspecific uptake

(Weak recommendation, Moderate-quality evidence)

Following RAI ablation or adjuvant therapy, when the posttherapy scan does not reveal uptake outside the thyroid bed, subsequent diagnostic WBSs have low sensitivity and are usually not necessary in low-risk patients who are clinically free of residual tumor and have an undetectable serum Tg level on thyroid hormone and negative cervical US (583,785,813,814).

A diagnostic WBS may be indicated in three primary clinical settings: (i) patients with abnormal uptake outside the thyroid bed on posttherapy WBS, (ii) patients with poorly informative postablation WBS because of large thyroid remnants with high uptake of ^{131}I (>2% of the administered activity at the time of WBS) that may hamper the visualization of lower uptake in neck lymph nodes, and (iii) patients with Tg antibodies, at risk of false-negative Tg measurement, even when neck US does not show any suspicious findings. Iodine 123 is preferred over ^{131}I in these rare indications for diagnostic WBS, because it delivers lower radiation doses to the body and provides better quality images.

Iodine 131 or ^{123}I whole-body scintigraphy includes planar images or images using a dual-head SPECT gamma camera of the whole body and spot images of the neck, mediastinum, and on any abnormal focus of RAI uptake. It may be performed after the administration of either a diagnostic (usually 2–5 mCi) or a therapeutic activity (30–150 mCi) of RAI. Because of the lack of anatomical landmarks on planar images, it is often difficult to differentiate uptake in normal thyroid remnants from lymph node metastases (especially when thyroid remnants are large), uptake in lung metastases from rib lesions, or accumulation of RAI in intestine or bladder from a pelvic bone lesion. Hybrid cameras combine a dual-head SPECT gamma camera with a CT scanner in one gantry. This allows direct superimposition of functional and anatomical imaging. The radiation dose delivered to the patient by the low-dose CT scan is 2–5 mSv, a dose that is much lower than the dose delivered by the administration of 100 mCi of ^{131}I (around 50 mSv).

Whole-body SPECT/CT performed after the administration of a diagnostic or a therapeutic activity (30 mCi or more) of RAI is associated with (i) an increased number of patients with a diagnosis of metastatic lymph node and (ii) a decreased frequency of equivocal findings (739,743,815–818). Furthermore, the CT portion of the SPECT/CT provides additional information on non–iodine-avid lesions; SPECT-CT changed tumor risk classifications in 25% of the patients according to the International Union Against Cancer classification and in 6% of the patients according to the ATA risk of recurrence classification; the SPECT-CT changed treatment management in 24 to 35% of patients, by decreasing the rate of equivocal findings. Finally, SPECT-CT avoids the need for further cross-sectional imaging studies such as contrast CT or MRI. Neoplastic lesions with low uptake of RAI or without any uptake may be a cause of false negative SPECT-CT.

Iodine 124 emits positrons, allowing PET/CT imaging in DTC patients. It is used as a dosimetric and also as a diagnostic tool to localize disease. In fact, for each neoplastic focus ^{124}I PET/CT permits an accurate measurement of its volume as well as the uptake and half-life of ^{124}I in it, therefore allowing a reliable individual dosimetric assessment for each neoplastic focus.

The sensitivity of ^{124}I-PET for the detection of residual thyroid tissue and/or metastatic DTC was reported to be higher than that of a diagnostic ^{131}I planar WBS (99% vs. 66%) (819–821). Iodine 124 PET/CT has not yet been compared with ^{131}I SPECT/CT in a large series of patients with DTC. Furthermore, ^{124}I is not yet widely available for clinical use and is primarily a research tool at this time.

[C12] ^{18}FDG-PET scanning

■ RECOMMENDATION 68

(A) ^{18}FDG-PET scanning should be considered in high-risk DTC patients with elevated serum Tg (generally >10 ng/mL) with negative RAI imaging

(Strong recommendation, Moderate-quality evidence)

(B) ^{18}FDG-PET scanning may also be considered as (i) a part of initial staging in poorly differentiated thyroid cancers and invasive Hürthle cell carcinomas, especially those with other evidence of disease on imaging or because of elevated serum Tg levels, (ii) a prognostic tool in patients with metastatic disease to identify lesions and patients at highest risk for rapid disease progression and disease-specific mortality, and (iii) an evaluation of post-treatment response following systemic or local therapy of metastatic or locally invasive disease.

(Weak recommendation, Low-quality evidence)

^{18}FDG-PET/CT is primarily considered in high-risk DTC patients with elevated serum Tg (generally >10 ng/mL) with negative RAI imaging. In a meta-analysis of 25 studies that included 789 patients, the sensitivity of ^{18}FDG-PET/CT was 83% (ranging from 50% to 100%) and the specificity was 84% (ranging from 42% to 100%) in non–^{131}I-avid DTC (822). Factors influencing ^{18}FDG-PET/CT sensitivity included tumor dedifferentiation, larger tumor burden, and to a lesser extent, TSH stimulation.

^{18}FDG-PET is more sensitive in patients with an aggressive histological subtype, including poorly differentiated, tall cell, and Hürthle cell thyroid cancer. ^{18}FDG uptake on PET in metastatic DTC patients is a major negative predictive factor for response to RAI treatment and an independent prognostic factor for survival (823,824). It can also identify lesions with high ^{18}FDG uptake (standardized uptake value) that may be more aggressive and should be targeted for therapy or close monitoring. It is complementary to ^{131}I WBS, even in the presence of detectable ^{131}I uptake in metastases, because ^{18}FDG uptake may be present in neoplastic foci with no ^{131}I uptake.

In patients with a TSH-stimulated Tg ≤10 ng/mL, the sensitivity of ^{18}FDG is low, ranging from <10% to 30%. It is therefore recommended to consider ^{18}FDG-PET only in DTC patients with a stimulated Tg level ≥10 ng/mL. Of course, this level needs to be adapted and lowered in case of aggressive pathological variant of thyroid cancer that may produce low amounts of serum Tg. Furthermore, in patients with undetectable Tg levels but with persistent Tg antibodies the level of serum Tg cannot be reliably assessed and ^{18}FDG-PET may localize disease in some of these patients.

The sensitivity of ^{18}FDG-PET scanning may be slightly increased with TSH stimulation. A multicentric prospective study on 63 patients showed an increase in the number of lesions

Downloaded by Memorial Sloan Kettering from www.liebertpub.com at 08/14/19. For personal use only.

detected on the ^{18}FDG-PET/CT performed after rhTSH stimulation compared to the ^{18}FDG-PET/CT performed on thyroid hormone treatment and without TSH stimulation (825). However, the sensitivity for detecting patients with at least one tumor site was not improved by the rhTSH stimulation. In this study, the lesions found only by rhTSH-PET contributed adequately to an altered therapeutic plan in four patients (6%), and the clinical benefit of identifying these additional small foci remains to be proven. Its clinical benefit might be higher in patients with normal neck and chest CT scan and normal neck ultrasonography. A meta-analysis on seven studies including the previous study and comprising 168 patients confirmed these results and showed that ^{18}FDG-PET/CT performed following TSH stimulation altered clinical management in only 9% of patients. Furthermore, false positives can be seen with ^{18}FDG-PET imaging with or without TSH stimulation (825).

Results of ^{18}FDG-PET/CT might alter the indications for ^{131}I treatment or the decision for surgical removal of small tumor foci with ^{18}FDG uptake. The frequency of false-positive lesions varies among series from 0% to 39%, and this high number justifies a FNAB with cytology and Tg measurement in the aspirate fluid in cases in which surgery is planned, based on ^{18}FDG-PET results. The higher sensitivity of neck ultrasonography for the detection of small metastatic lymph nodes should be noted, with ^{18}FDG-PET being more sensitive for some locations such as the retropharyngeal or the retro-clavicular regions (825).

To date, there is no evidence that TSH stimulation improves the prognostic value of ^{18}FDG-PET imaging.

[C13] CT and MRI

■ RECOMMENDATION 69

(A) Cross-sectional imaging of the neck and upper chest (CT, MRI) with IV contrast should be considered (i) in the setting of bulky and widely distributed recurrent nodal disease where US may not completely delineate disease, (ii) in the assessment of possible invasive recurrent disease where potential aerodigestive tract invasion requires complete assessment, or (iii) when neck US is felt to be inadequately visualizing possible neck nodal disease (high Tg, negative neck US).

(Strong recommendation, Moderate-quality evidence)

(B) CT imaging of the chest without IV contrast (imaging pulmonary parenchyma) or with IV contrast (to include the mediastinum) should be considered in high risk DTC patients with elevated serum Tg (generally >10 ng/mL) or rising Tg antibodies with or without negative RAI imaging.

(Strong recommendation, Moderate-quality evidence)

(C) Imaging of other organs including MRI brain, MR skeletal survey, and/or CT or MRI of the abdomen should be considered in high-risk DTC patients with elevated serum Tg (generally >10 ng/mL) and negative neck and chest imaging who have symptoms referable to those organs or who are being prepared for TSH-stimulated RAI therapy (withdrawal or rhTSH) and may be at risk for complications of tumor swelling.

(Strong recommendation, Low-quality evidence)

In patients with elevated or rising Tg or anti-Tg antibodies and NED on neck US or RAI imaging (if performed), CT imaging of the neck and chest should be considered. The frequency of positive anatomic imaging increases with higher serum Tg levels above 10 ng/mL. CT is the most frequently recommended first-line technique to search for lymph node metastases in patients with squamous cell carcinoma of the head and neck, and an injection of contrast medium is mandatory for the analysis of the neck and mediastinum (826). Radioiodine can be administered 4–8 weeks following the injection of contrast medium, because at that time a majority of the iodine contamination has disappeared in most patients (315). If there is a concern, a random urine iodine (and creatinine) prior to initiation of a LID and RAI testing or treatment can be measured to make sure the urine iodine is not high. Diagnostic CT scan may complement neck US for the detection of macrometastases in the central compartment, in the mediastinum, and behind the trachea (307–309), and it is the most sensitive tool for the detection of micrometastases in the lungs. Before revision surgery is contemplated, presumptive recurrent neck targets must be defined by high-resolution radiographic anatomic studies such as US or spiral axial CT scan to complement ^{18}FDG-PET/CT or RAI imaging and must be carefully defined to allow for adequate preoperative mapping and definitive surgical localization. In addition to nodal assessment axial scanning, including CT scan with contrast has utility in the evaluation of locally recurrent invasive disease and relationships with vessels. Such patients may present with hoarseness, vocal cord paralysis on laryngeal exam, progressive dysphagia or mass fixation to surrounding structures, respiratory symptoms including stridor or hemoptysis, and lesions with rapid progression/enlargement. Such lesions are incompletely evaluated with US alone, and axial CT scanning with contrast medium is indicated.

The use of MRI has also been advocated for imaging the neck and the mediastinum. It is performed with and without injection of gadolinium chelate as a contrast medium and does not require any injection of iodine contrast medium. The performance of MRI for imaging the neck and mediastinum has not been directly compared with CT on large numbers of thyroid cancer patients (827–829). Compared to CT scan, it may better delineate any involvement of the aerodigestive tract (830,831). It is often used as second-line imaging technique in patients with demonstrated or suspicious lesions on CT scan in order to better delineate these lesions. In the lower part of the neck, movements of the aerodigestive axis during the procedure that may last several minutes will decrease the quality of images (414). Endoscopy of the trachea and or esophagus, with or without ultrasonography, looking for evidence of intraluminal extension can also be helpful in cases of suspected aerodigestive tract invasion. MRI is less sensitive than CT scan for the detection of lung micronodules.

Finally, whether these imaging techniques (CT and MRI) should be performed for diagnostic purposes or whether an ^{18}FDG-PET/CT scan should be performed as the first-line imaging procedure for diagnosis is still a matter of debate. In the past, CT scan with injection of contrast medium was more sensitive for the detection of lymph node metastases (832), but with modern PET/CT equipment, the CT scan of the PET/CT is as reliable as a CT scan used for radiology, and many lesions can be found on ^{18}FDG-PET/CT scanning, even if no

Downloaded by Memorial Sloan Kettering from www.liebertpub.com at 08/14/19. For personal use only.

injection of contrast medium has been performed (833,834). Delineation between lymph node metastases or local recurrence and vessels or the aerodigestive axis is often not well visualized on ^{18}FDG-PET/CT in the absence of contrast injection, and if necessary other imaging techniques (CT and MRI with contrast medium) may be performed especially for a preoperative work-up. As a result, most patients with extensive disease should be considered for ^{18}FDG-PET/CT and CT imaging with contrast, and some patients will also be considered for MRI.

This imaging strategy is applied in patients with elevated serum Tg (>5–10 ng/mL) and no other evidence of disease (neck and chest imaging), starting with a ^{18}FDG-PET/CT (822,833). In the past an empiric treatment was used in such patients, but recent studies have shown that ^{18}FDG-PET/CT imaging is more sensitive and should be performed as the first-line approach, with empiric RAI treatment being considered only for those patients with no detectable ^{18}FDG uptake (833).

[C14] Using ongoing risk stratification (response to therapy) to guide disease long-term surveillance and therapeutic management decisions

Ongoing risk stratification allows the clinician to continue to provide individualized management recommendations as the risk estimates evolve over time. While the specific details of how surveillance and therapeutic strategies should be modified over time as a function of response to therapy reclassification within each ATA risk category remains to be defined, we do endorse the following concepts (more details in Table 13).

Excellent response: An excellent response to therapy should lead to a decrease in the intensity and frequency of follow-up and the degree of TSH suppression (this change in management will be most apparent in ATA intermediate- and high-risk patients).

Biochemical incomplete response: If associated with stable or declining serum Tg values, a biochemical incomplete response should lead to continued observation with ongoing TSH suppression in most patients. Rising Tg or anti-Tg antibody values should prompt additional imaging and potentially additional therapies.

Structural incomplete response: A structural incomplete response may lead to additional treatments or ongoing observation depending on multiple clinico-pathologic factors including the size, location, rate of growth, RAI avidity, ^{18}FDG avidity, and specific pathology of the structural lesions.

Indeterminate response: An indeterminate response should lead to continued observation with appropriate serial imaging of the nonspecific lesions and serum Tg monitoring. Nonspecific findings that become suspicious over time or rising Tg or anti-Tg antibody levels can be further evaluated with additional imaging or biopsy.

[C15] What is the role of TSH suppression during thyroid hormone therapy in the long-term follow-up of DTC?

■ RECOMMENDATION 70

(A) In patients with a structural incomplete response to therapy, the serum TSH should be maintained below 0.1 mU/L indefinitely in the absence of specific contraindications.

(Strong recommendation, Moderate-quality evidence)

(B) In patients with a biochemical incomplete response to therapy, the serum TSH should be maintained between 0.1 and 0.5 mU/L, taking into account the initial ATA risk classification, Tg level, Tg trend over time, and risk of TSH suppression.

(Weak recommendation, Low-quality evidence)

(C) In patients who presented with high-risk disease but have an excellent (clinically and biochemically free of disease) or indeterminate response to therapy, consideration should be given to maintaining thyroid hormone therapy to achieve serum TSH levels of 0.1–0.5 mU/L for up to 5 years after which the degree of TSH suppression can by reduced with continued surveillance for recurrence.

(Weak recommendation, Low-quality evidence)

(D) In patients with an excellent (clinically and biochemically free of disease) or indeterminate response to therapy, especially those at low risk for recurrence, the serum TSH may be kept within the low reference range (0.5–2 mU/L).

(Strong recommendation, Moderate-quality evidence)

(E) In patients who have not undergone remnant ablation or adjuvant therapy who demonstrate an excellent or indeterminate response to therapy with a normal neck US, and low or undetectable suppressed serum Tg, and Tg or anti-Tg antibodies that are not rising, the serum TSH can be allowed to rise to the low reference range (0.5–2 mU/L).

(Weak recommendation, Low-quality evidence)

A meta-analysis has suggested an association between thyroid hormone suppression therapy and reduction of major adverse clinical events (745). The appropriate degree of TSH suppression by thyroid hormone therapy is still unknown, especially in high-risk patients rendered free of disease. A constantly suppressed TSH (0.05 mU/L) was found in one study to be associated with a longer relapse-free survival than when serum TSH levels were always 1 mU/L or greater, and the degree of TSH suppression was an independent predictor of recurrence in multivariate analysis (749). Conversely, another large study found that disease stage, patient age, and ^{131}I therapy independently predicted disease progression, but the degree of TSH suppression did not (275). A third study showed that during LT_4 therapy the mean Tg levels were significantly higher when TSH levels were normal than when TSH levels were suppressed (<0.5 mU/L) but only in patients with local or distant recurrence (835). A fourth study of 2936 patients found that overall survival improved significantly when the TSH was suppressed to <0.1 mU/L in patients with NTCTCSG stage III or IV disease and to a range of 0.1 mU/L to about 0.5 mU/L in patients with NTCTCSG stage II disease; however, there was no incremental benefit from suppressing TSH to undetectable levels in stage II patients, and suppression of TSH was of no benefit in patients with stage I disease (671), and higher degrees of suppression to TSH of <0.03 mU/L provided no additional benefit (746). Another study found that a serum TSH

Downloaded by Memorial Sloan Kettering from www.liebertpub.com at 08/14/19. For personal use only.

threshold of 2 mU/L differentiated best between patients free of disease and those with relapse or cancer-related mortality, which remained significant when age and tumor stage were included in a multivariate analysis (750). A prospective study showed that disease-free survival for low-risk patients without TSH suppression was not inferior to patients with TSH suppression (836). No prospective studies have been performed examining the risk of recurrence and death from thyroid cancer associated with varying serum TSH levels, based on the criteria outlined above in [C14] for the absence of tumor at 6–12 months post surgery and RAI ablation.

A recent observational study demonstrated increased risk of all-cause and cardiovascular mortality in DTC patients compared to a control population (837). The authors also showed that survival in the DTC patients was lower when the serum TSH was <0.02 mU/L, which is particularly relevant in patients with an excellent response to therapy in whom overtreatment should be avoided. An approach to balancing the risks of thyroxine suppression against the risks of tumor recurrence or progression has been presented in a recent review (747). This review helped to define patients at low, intermediate, and high risk of complications from TSH suppression therapy. Table 15 provides recommendations for TSH ranges based on response to thyroid cancer therapy weighed against risks of LT_4 therapy, which is adapted from the review by Biondi and Cooper (747). In patients at high risk of adverse effects on heart and bone by TSH suppression therapy, the benefits of TSH suppression should be weighed against the potential risks. In peri- and postmenopausal women at risk for bone loss, adjunctive therapy with calcium supplements, vitamin D, and other bone-enhancing agents (bisphosphonates, denosumab, etc.) should be considered. β-Adrenergic blocking drugs may be considered in older patients to obviate increases in left ventricular mass and tachycardia (838,839).

There are inadequate data to make a strong recommendation regarding the intensity and duration of TSH suppression in the biochemical incomplete response to therapy category. This category encompasses a variety of patients with low serum Tg levels (median nonstimulated Tg 3.6 ng/mL) having been initially classified as ATA low risk (16%–24%), ATA intermediate risk (47%–64%), or ATA high risk (18%–21%) (539,607). Furthermore, the risk of development of structurally identifiable disease within this cohort is not uniform but rather is related to the ongoing behavior of residual disease as reflected by both the magnitude of the Tg elevation and to the rate of rise of the serum Tg or anti-Tg antibodies. Based on weak data and expert opinion, we recommend a goal TSH of 0.1–0.5 mIU/L for the majority of patients with a biochemical

Table 15. Thyrotropin Targets for Long-Term Thyroid Hormone Therapy

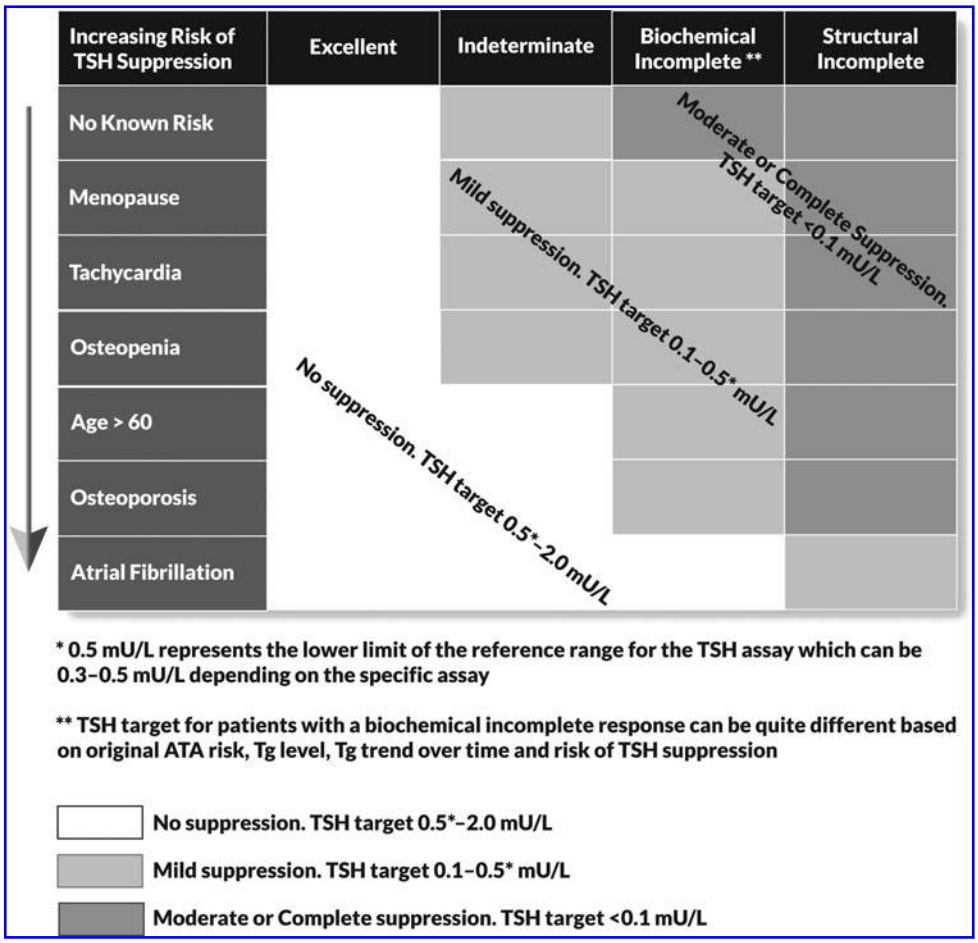

Downloaded by Memorial Sloan Kettering from www.liebertpub.com at 08/14/19. For personal use only.

incomplete response, recognizing that less intense TSH suppression (0.5–2.0 mIU/L) may be appropriate for ATA low-risk patients with stable nonstimulated Tg values near the threshold for excellent response (e.g., nonstimulated Tg values in the 1–2 ng/mL range), while more intense TSH suppression (<0.1 mIU/L) may be desired in the setting of more elevated or rapidly rising Tg values.

[C16] What is the most appropriate management of DTC patients with metastatic disease?

Metastases may be discovered at the time of initial disease staging or may be identified during longitudinal follow-up. If metastases are found following initial therapy, some patients may subsequently experience a reduction in tumor burden with additional treatments that may offer a survival or palliative benefit (840–844). The preferred hierarchy of treatment for metastatic disease (in order) is surgical excision of locoregional disease in potentially curable patients, ^{131}I therapy for RAI-responsive disease, external beam radiation therapy or other directed treatment modalities such as thermal ablation, TSH-suppressive thyroid hormone therapy for patients with stable or slowly progressive asymptomatic disease, and systemic therapy with kinase inhibitors (preferably by use of FDA-approved drugs or participation in clinical trials), especially for patients with significantly progressive macroscopic refractory disease. Clinical trials or kinase inhibitor therapy may be tried before external beam radiation therapy in special circumstances, in part because of the morbidity of external beam radiation and its relative lack of efficacy. However, localized treatments with thermal (radiofrequency or cryo-) ablation (845), ethanol ablation (846), or chemo-embolization (847) may be beneficial in patients with a single or a few metastases and in those with metastases at high risk of local complications; the treatments should be performed in such patients before the initiation of any systemic treatment. These modalities may control treated metastases, may avoid local complications, and may delay initiation of systemic treatment. Additionally, surgical therapy in selected incurable patients is important to prevent complications in targeted areas, such as the CNS and central neck compartment. Conversely, conservative intervention with TSH-suppressive thyroid hormone therapy may be appropriate for selected patients with stable asymptomatic local metastatic disease and most patients with stable asymptomatic non-CNS distant metastatic disease.

[C17] What is the optimal directed approach to patients with suspected structural neck recurrence?

■ **RECOMMENDATION 71**

Therapeutic compartmental central and/or lateral neck dissection in a previously operated compartment, sparing uninvolved vital structures, should be performed for patients with biopsy-proven persistent or recurrent disease for central neck nodes ≥8 mm and lateral neck nodes ≥10 mm in the smallest dimension that can be localized on anatomic imaging.

(Strong recommendation, Moderate-quality evidence)

Persistent or recurrent nodal disease may result in local invasion and is the source of considerable patient and physician anxiety (848). However, several observational studies suggest that low-volume recurrent nodal disease can be indolent and can be managed through active surveillance, although not all lesions in these series are documented as malignant (629,849). Bulky or invasive recurrent disease is best treated surgically (319,850–853).

The judgment to offer surgery for recurrent nodal disease in the neck is made with equipoise in two opposing decision elements: (i) the risks of revision surgery (which are typically higher than primary surgery due to scarring from previous surgery (854) balanced with (ii) the fact that surgical resection generally represents the optimal treatment of macroscopic gross nodal disease over other treatment options. An important element in this decision-making process is the availability of surgical expertise specifically in the performance of revision thyroid cancer nodal surgery, which is a discrete surgical skill set. The decision to treat cervical nodal recurrence surgically should be made with an appreciation of distant disease presence and progression but may be undertaken even in the setting of known distant metastasis for palliation of symptoms and prevention of aerodigestive tract obstruction. The decision for treatment and surgery specifically is best derived through collaborative team approach involving surgery, endocrinology, and importantly the patient and family (855). Therefore, cytologic confirmation of disease can be deferred if the findings of the FNA will not lead to additional evaluation or treatment. While we generally recommend cytologic confirmation of abnormal radiographic findings prior to surgical resection, we recognize that this may not be necessary (or possible) in every case (e.g., radiographic findings with a very high likelihood of malignancy, or the specific location of the lymph node makes it difficult/impossible to biopsy).

[C18] Nodal size threshold

Surgery is considered with the recognition of clinically apparent, macroscopic nodal disease through radiographic analysis including US (Table 7) and/or axial (CT) scanning rather than through isolated Tg elevation (309,335,856). Given the risks of revision nodal surgery, a clearly defined preoperative radiographic target is mandatory. The risks of surgery relate in part to the exact location of the target node(s) and whether the compartment in question has been previously dissected such as recurrent central neck nodes after primary thyroidectomy. This target must be defined by high-resolution radiographic anatomic studies such as US or spiral CT scan with contrast, as a complement to ^{18}FDG-PET/CT or RAI-SPECT/CT when performed, to allow for adequate preoperative mapping and definitive surgical localization (309,856). Ultrasound-guided FNA for cytology with Tg measurement in the aspiration sample can be performed in the setting of radiographically suspicious nodal recurrence keeping in mind that Tg rinsing may be positive with thyroid bed persistent benign thyroid remnant tissue if the patient has not been treated with RAI. Charcoal tattooing under US guidance may help the surgeon to localize the lymph node to be removed during surgery (344).

Malignant central neck nodes ≥8 mm and lateral neck nodes ≥10 mm in the smallest dimension that have undergone FNAB and can be localized on anatomic imaging (US with or without axial CT) can be considered surgical targets

Downloaded by Memorial Sloan Kettering from www.liebertpub.com at 08/14/19. For personal use only.

(309,857–859). Short-axis nodal diameter measurement is optimally employed in surgical decision-making for nodal malignancy. Smaller lesions are probably best managed with active surveillance (observation) with serial cross-sectional imaging, reserving FNA and subsequent intervention for documented structural disease progression. However, multiple factors in addition to size should be taken into account when considering surgical options, including proximity of given malignant nodes to adjacent vital structures and the functional status of the vocal cords. Patient comorbidities, motivation, and emotional concerns should also be taken into account along with primary tumor factors (high-grade histology, Tg doubling time, RAI avidity, ^{18}FDG-PET avidity, and presence of molecular markers associated with aggressive behavior). Through thorough patient and multidisciplinary collaborative discussions, metastatic nodes >8–10 mm can be carefully observed in properly selected patients with serial clinical and radiographic follow-up, with surgery being offered if they progress during follow-up and conservative follow-up being maintained if they are stable over time.

[C19] Extent of nodal surgery

Because of the increased risk of recurrence with focal ''berry-picking'' techniques, compartmental surgery is recommended (860,861). Planned compartmental dissection should be adjusted and be more limited depending on the surgeon's judgment of procedural safety as it relates to scarring/distortion of anatomy (from prior surgery and/or past radiation therapy) and the perception of impending complications. Typical revision lateral neck dissection involves levels II, III, and IV, while revision central neck dissection includes at least one paratracheal region with prelaryngeal and pretracheal subcompartments. Bilateral central neck dissection is offered only when dictated by disease distribution because of the risks of bilateral nerve injury and permanent hypoparathyroidism.

Basal Tg decreases by 60%–90% after compartmental dissection for recurrent nodal disease in modern series, but only 30%–50% of patients have unmeasurable basal Tg after such surgery, and it is difficult to predict who will respond to surgery with Tg reduction (627,628,634,858,862–876). However, most series suggest surgery results in a high clearance rate of structural disease in over 80% of patients (859,875).

[C20] Ethanol injection

Percutaneous ethanol injection for patients with metastatic lymph nodes is gaining interest as a nonsurgical directed therapy for patients with recurrent DTC. Most of the studies limited PEI to patients who had undergone previous neck dissections and RAI treatment, those who had FNA-proven DTC in the lymph node, and those with no known distant metastases.

One of the first studies examining the effectiveness of local metastatic lymph node control by PEI treated 14 patients with 29 lymph nodes (846). Twelve of the 14 patients had good loco-regional control in this study with short-term follow-up (mean 18 months). The largest study to date treated 63 patients with 109 metastatic lymph nodes between the years 2004 and 2009 (878). Ninety-two lymph nodes (84%) were successfully ablated in this retrospective study with a mean follow-up of 38 months, and most required one to three treatment sessions. Minor complications included brief discomfort at the PEI site, and there were no major complications.

A recent study retrospectively reviewed 25 patients who had 37 lymph nodes ablated between the years 1994 and 2012, with a relatively long follow-up of a mean of 65 months (879). All lymph nodes were successfully ablated in one to five treatment sessions by lack of flow on US. Most of the lymph nodes decreased in size and 46% completely disappeared. Serum Tg levels were reduced in most patients and brought into an acceptable range (<2.4 ng/mL) in 82% of patients with negative anti-Tg antibodies. There were no serious or long-term complications. Another recent study also demonstrated safety and efficacy of PEI in 21 patients with 41 metastatic lymph nodes (880). These investigators treated patients with only one session, and 24% of patients had a recurrence at the site of the injection.

Limitations of many of the studies included small numbers of patients, relatively short-term follow-up, and many patients with small lymph nodes (<5–8 mm).

A general consensus from studies and reviews is that PEI should be considered in patients who are poor surgical candidates. Many patients will likely need more than one treatment session and lymph nodes >2 cm may be difficult to treat with PEI. Focal PEI treatment does represent a nonsurgical form of berry picking. Formal neck compartmental dissection is still the first-line therapy in DTC patients with clinically apparent or progressive lymph node metastases. When deciding for the optimal strategy of care for a patient's lymph node metastases, previous treatment modalities should also be taken into consideration.

[C21] Radiofrequency or laser ablation

The use of radiofrequency ablation (RFA) with local anesthesia in the treatment of recurrent thyroid cancer has been associated with a mean volume reduction that ranges between approximately 55% and 95% (881,882) and complete disappearance of the metastatic foci in 40%–60% of the cases (845,882,883). As with alcohol ablation, multiple treatment sessions are often required. Complications include discomfort, pain, skin burn, and changes in the voice (884). Similar to alcohol ablation techniques, it appears that RFA may be most useful in high-risk surgical patients or in patients refusing additional surgery, rather than as a standard alternative to surgical resection of metastatic disease (883–885). More recently, preliminary findings using US-guided laser ablation for treatment of cervical lymph node metastases have been reported (886).

[C22] Other therapeutic options

Empiric RAI therapy for structurally identifiable disease that is not RAI avid by diagnostic scanning is very unlikely to have a significant tumoricidal effect and is therefore not generally recommended (887). Stereotactic radiotherapy (SBRT) can be successfully used to treat isolated metastatic disease foci, but it has no role in most patients with resectable lymph node metastases. EBRT using modern techniques such as intensity modulated radiotherapy and sterotactic radiation, is considered for loco-regional recurrence that is not surgically resectable or with extranodal extension or involvement of soft tissues, particularly in patients with no evidence of

Downloaded by Memorial Sloan Kettering from www.liebertpub.com at 08/14/19. For personal use only.

distant disease. Efficacy has been suggested only in retrospective studies on limited numbers of patients (888,889). Likewise, systemic therapies (such as cytotoxic chemotherapy or kinase inhibitors) for loco-regional disease are considered only after all surgical and radiation therapy options have been exhausted.

[C23] What is the surgical management of aerodigestive invasion?

■ **RECOMMENDATION 72**

When technically feasible, surgery for aerodigestive invasive disease is recommended in combination with RAI and/or EBRT.

(Strong Recommendation, Moderate-quality evidence)

For tumors that invade the upper aerodigestive tract, surgery combined with additional therapy such as ^{131}I and/or external beam radiation therapy is generally advised (890,891). Patient outcome is related to complete resection of all gross disease with the preservation of function, with techniques ranging from shaving a tumor off the trachea or esophagus for superficial invasion, to more aggressive techniques when the trachea is more deeply invaded (e.g., direct intraluminal invasion), including tracheal resection and anastomosis or laryngopharyngoesophagectomy (892–894). Surgical decision-making can be complex and must balance oncologic surgical completeness with preservation of upper aerodigestive track head and neck function. In some circumstances such surgery represents a possible attempt for cure, and in other circumstances it offers significant regional neck palliation in patients with distant metastasis with impending asphyxiation or significant hemoptysis (414,891).

[C24] How should RAI therapy be considered for loco-regional or distant metastatic disease?

For regional nodal metastases discovered on diagnostic WBS, RAI may be employed in patients with low-volume disease or in combination with surgery, although surgery is typically preferred in the presence of bulky disease or disease amenable to surgery. Radioiodine is also used adjunctively following surgery for regional nodal disease or aerodigestive invasion if residual RAI-avid disease is present or suspected. Significant variation exists nationally in the United States in regard to RAI use, irrespective of the degree of disease or risk of recurrence (895,896). However, there are no randomized, controlled clinical trials demonstrating better patient outcomes after RAI therapy. One retrospective analysis indicated that a delay in RAI therapy of 6 months or more was associated with disease progression and reduced survival (897). In one study of 45 patients with persistent serum Tg elevation after reoperation for loco-regional recurrence, adjuvant RAI therapy demonstrated no benefit (898).

[C25] Administered activity of ^{131}I for loco-regional or metastatic disease

■ **RECOMMENDATION 73**

(A) Although there are theoretical advantages to dosimetric approaches to the treatment of loco-regional or metastatic disease, no recommendation can be made about the superiority of one method of RAI administration over another (empiric high activity versus blood and/or body dosimetry versus lesional dosimetry).

(No recommendation, Insufficient evidence)

(B) Empirically administered amounts of ^{131}I exceeding 150 mCi that often potentially exceed the maximum tolerable tissue dose should be avoided in patients over age 70 years.

(Strong recommendation, Moderate-quality evidence)

Despite the apparent effectiveness of ^{131}I therapy in many patients, the optimal therapeutic activity remains uncertain and controversial (895,899). There are three approaches to ^{131}I therapy: empiric fixed amounts, therapy determined by the upper limit of blood and body dosimetry (900–907), and quantitative tumor or lesional dosimetry (908,909). Dosimetric methods are often reserved for patients with distant metastases or unusual situations such as renal insufficiency (910,911), children (912,913), the elderly, and those with extensive pulmonary metastases (914). Comparison of outcomes among these methods from published series is difficult (895,897,900). No prospective randomized trial to address the optimal therapeutic approach has been published. One retrospective study concluded that patients with loco-regional disease were more likely to respond after dosimetric therapy than after empiric treatment (915). Another study demonstrated improved efficacy of administration of dosimetric maximal activity after failure of empiric dosage (916). Arguments in favor of higher activities cite a positive relationship between the total ^{131}I uptake per tumor mass and outcome (908), while others have not confirmed this relationship (917). In the future, the use of ^{123}I or ^{131}I with modern SPECT/CT or ^{124}I PET-based dosimetry may facilitate whole-body and lesional dosimetry (918–920). In certain settings (e.g., in the patients with radiation-induced thyroid cancer seen after the Chernobyl accident), RAI treatment may be associated with good outcomes even in high-risk patients with metastatic disease (921).

The efficacy of RAI therapy is related to the mean radiation dose delivered to neoplastic foci and also to the radiosensitivity of tumor tissue (922). The radiosensitivity is higher in patients who are younger, with small metastases from well-differentiated papillary or follicular carcinoma and with uptake of RAI but no or low ^{18}FDG uptake.

The maximum tolerated radiation absorbed dose (MTRD), commonly defined as 200 rads (cGy) to the blood, is potentially exceeded in a significant number of patients undergoing empiric treatment with various amounts of ^{131}I. In one study (923) 1%–22% of patients treated with ^{131}I according to dosimetry calculations would have theoretically exceeded the MTRD had they been empirically treated with 100–300 mCi of ^{131}I. Another study (924) found that an empirically administered ^{131}I activity of 200 mCi would exceed the MTRD in 8%–15% of patients younger than age 70 and 22%–38% of patients aged 70 years and older. Administering 250 mCi empirically would have exceeded the MTRD in 22% of patients younger than 70 and 50% of patients 70 and older. These estimates imply the need for caution in administering empiric activities higher than 100–150 mCi in certain populations such as elderly patients and patients with renal insufficiency.

Downloaded by Memorial Sloan Kettering from www.liebertpub.com at 08/14/19. For personal use only.

[C26] Use of rhTSH (Thyrogen) to prepare patients for ^{131}I therapy for loco-regional or metastatic disease

■ **RECOMMENDATION 74**

There are currently insufficient outcome data to recommend rhTSH-mediated therapy for all patients with distant metastatic disease being treated with ^{131}I.

(No Recommendation, Insufficient evidence)

■ **RECOMMENDATION 75**

Recombinant human TSH–mediated therapy may be indicated in selected patients with underlying comorbidities making iatrogenic hypothyroidism potentially risky, in patients with pituitary disease whose serum TSH cannot be raised, or in patients in whom a delay in therapy might be deleterious. Such patients should be given the same or higher activity that would have been given had they been prepared with hypothyroidism or a dosimetrically determined activity.

(Strong Recommendation, Low-quality evidence)

No randomized trial comparing thyroid hormone withdrawal therapy to rhTSH-mediated therapy for treatment of distant metastatic disease has been reported, but there is a growing body of nonrandomized studies exploring the use of rhTSH to prepare patients for therapy of metastatic disease (713,925–934). One small comparative study showed that the radiation dose to metastatic foci is lower with rhTSH than that following withdrawal (935). Many of these case reports and series report disease stabilization or improvement in some patients following rhTSH-mediated ^{131}I therapy, but whether the efficacy of this preparation is comparable to thyroid hormone withdrawal is unknown. Extreme or prolonged elevations of TSH from either thyroid hormone withdrawal or rhTSH may acutely stimulate tumor growth and mass of metastases (930,936–938). With metastatic deposits in the brain or in close relation to the spinal cord or the superior vena cava, such swelling may severely compromise neurologic function or produce a superior vena cava syndrome, respectively. When distant metastases are evident, MRI of the brain and spine is recommended to detect the presence of critical metastases prior to treatment (see sections [C28] and [C39]). When metastases are detected, institution of temporary high-dose corticosteroid therapy is recommended for trying to limit the risk of acute tumor swelling and compromised function. Dexamethasone has been employed in doses of 2–4 mg every 8 hours starting 6–12 hours prior to rhTSH and RAI dosing or after 10–12 days of thyroid hormone withdrawal, with the steroids continued in a tapering dosage schedule for 1 week post therapy, for 48–72 hours after rhTSH administration, or for 72 hours after re-institution of thyroxine therapy when thyroid hormone withdrawal was employed (927). In patients with these critical metastases, consideration should be given to preparation with either a reduced dose of rhTSH or to attenuating the degree and duration of endogenous TSH elevation after thyroid hormone withdrawal while monitoring serum TSH levels. This can be achieved by the temporary addition of LT_3 therapy to thyroxine replacement. Satisfactory RAI treatment with either empiric or dosimetric activities should be feasible after achieving TSH levels of 30–50 mU/L. When thyroid hormone withdrawal has been employed, LT_4 therapy should recommence once the dose of RAI is administered in order to reduce the duration of TSH elevation.

[C27] Use of lithium in ^{131}I therapy

■ **RECOMMENDATION 76**

Since there are no outcome data that demonstrate a better outcome of patients treated with lithium as an adjunct to ^{131}I therapy, the data are insufficient to recommend lithium therapy.

(No recommendation, Insufficient evidence)

Lithium inhibits iodine release from the thyroid without impairing iodine uptake, thus enhancing ^{131}I retention in normal thyroid and tumor cells (939). One study (940) found that lithium increased the estimated ^{131}I radiation dose in metastatic tumors on average by more than 2-fold, but primarily in those tumors that rapidly cleared iodine. On the other hand, a different study was unable to document any clinical advantage of lithium therapy on outcome in patients with metastatic disease, despite an increase in RAI uptake in tumor deposits (941). Lithium use may be associated with adverse events and needs to be precisely managed.

[C28] How should distant metastatic disease to various organs be treated?

The overall approach to treatment of distant metastatic thyroid cancer is based upon the following observations and oncologic principles:

1. Morbidity and mortality are increased in patients with distant metastases, but individual prognosis depends upon factors including histology of the primary tumor, distribution and number of sites of metastasis (e.g., brain, bone, lung), tumor burden, age at diagnosis of metastases, and ^{18}FDG and RAI avidity (842,933,942–948).
2. Improved survival is associated with responsiveness to directed therapy (surgery, EBRT, thermal ablation, etc.) and/or RAI (842,933,942–948).
3. In the absence of demonstrated survival benefit, certain interventions can provide significant palliation or reduce morbidity (847,949–951).
4. Treatment of a specific metastatic area must be considered in light of the patient's performance status and other sites of disease; for example, 5%–20% of patients with distant metastases die from progressive cervical disease (948,952).
5. Longitudinal re-evaluation of patient status and continuing reassessment of potential benefit and risk of intervention are required.
6. In the setting of overall poor anticipated outcome of patients with radiographically evident or symptomatic metastases that do not respond to RAI, the complexity of multidisciplinary treatment considerations and the availability of prospective clinical trials should encourage the clinician to refer such patients to tertiary centers with particular expertise.
7. Mutation profiling of metastatic tumor (to detect abnormalities in genes such as *BRAF*, *TERT*, *RAS*, or *PAX8/*

Downloaded by Memorial Sloan Kettering from www.liebertpub.com at 08/14/19. For personal use only.

PPARγ) has not yet definitively proven to be of value for estimating patient prognosis or for predicting response to treatments such as anti-angiogenic kinase inhibitors, although the presence of certain mutations such as *BRAF*^{V600E} or *PAX8/PPARγ* are required for some clinical trials. Thus, routine mutation profiling cannot be recommended at this time outside of research settings.

There is little if any benefit derived from the treatment of RAI-refractory DTC with RAI (953). Although RAI-refractory tumors often may harbor *BRAF*^{V600E} mutations and RAI-avid tumors are overrepresented with *RAS* mutations, RAI therapy has not been shown to be more effective in patients with *RAS* mutations (954).

[C29] Treatment of pulmonary metastases

■ RECOMMENDATION 77

(A) Pulmonary micrometastases should be treated with RAI therapy and RAI therapy should be repeated every 6–12 months as long as disease continues to concentrate RAI and respond clinically because the highest rates of complete remission are reported in these subgroups.

(Strong recommendation, Moderate-quality evidence)

(B) The selection of RAI activity to administer for pulmonary micrometastases can be empiric (100–200 mCi, or 100–150 mCi for patients ≥70 years old) or estimated by dosimetry to limit whole-body retention to 80 mCi at 48 hours and 200 cGy to the bone marrow.

(Strong recommendation, Moderate-quality evidence)

■ RECOMMENDATION 78

Radioiodine-avid macronodular metastases may be treated with RAI and treatment may be repeated when objective benefit is demonstrated (decrease in the size of the lesions, decreasing Tg), but complete remission is not common and survival remains poor. The selection of RAI activity to administer can be made empirically (100–200 mCi) or by lesional dosimetry or whole-body dosimetry if available in order to limit whole-body retention to 80 mCi at 48 hours and 200 cGy to the bone marrow.

(Weak recommendation, Low-quality evidence)

In the management of the patient with pulmonary metastases, key criteria for therapeutic decisions include (i) size of metastatic lesions (macronodular typically detected by chest radiography, micronodular typically detected by CT, lesions beneath the resolution of CT); (ii) avidity for RAI and, if applicable, response to prior RAI therapy; and (iii) stability (or lack thereof) of metastatic lesions. Pulmonary pneumonitis and fibrosis are rare complications of high-dose RAI treatment. Dosimetric approaches to therapy with a limit of 80 mCi whole-body retention at 48 hours and 200 cGy to the bone marrow should be considered in patients with diffuse ^{131}I pulmonary uptake (955). If pulmonary fibrosis is suspected, then appropriate periodic pulmonary function testing and consultation should be obtained. The presence of pulmonary fibrosis may limit the ability to further treat metastatic disease with RAI (956).

Patients with pulmonary micrometastases (<2 mm, generally not seen on anatomic imaging) that are RAI avid have the highest rates of complete remission after treatment with RAI (942,947,957,958). These patients should be treated with RAI therapy repeatedly every 6–12 months as long as disease continues to concentrate RAI and respond clinically.

A precise definition of ''responding clinically'' is not feasible given the wide variation in disease presentation and response to therapy. A meaningful response to RAI treatment is generally associated with a significant reduction in serum Tg and/or in the size or rate of growth of metastases or structurally apparent disease. In contrast, a reduction in serum Tg and in RAI uptake with no concomitant decrease or with an increase in tumor size suggests refractoriness to RAI therapy. In the presence of widespread metastases, especially when in bone, additional RAI may temporarily stabilize progression, but it is unlikely to result in cure. The risks of bone marrow suppression or pulmonary fibrosis should generate caution when repeated doses of RAI are being considered. Absolute neutrophil count and platelet counts are the usual markers of bone marrow suppression, and pulmonary function testing including diffusing capacity of the lungs for carbon monoxide can be markers of pulmonary toxicity. Other approaches (see sections [C36–C41]) should be considered once maximal cumulative tolerable radiation doses have been administered.

Macronodular pulmonary metastases may also be treated with RAI if demonstrated to be iodine avid. How many doses of RAI to give and how often to give RAI is a decision that must be individualized based on the disease response to treatment, age of the patient, and the presence or absence of other metastatic lesions (942,947). The presence of significant side effects including bone marrow suppression and salivary gland damage may temper enthusiasm for additional RAI therapy (959), and risk of second malignancies after RAI treatment remains controversial (766,960,961). Patients with solitary pulmonary DTC metastases may be considered for surgical resection, although the potential benefit weighed against the risk of surgery is unclear.

The likelihood of significant long-term benefit of ^{131}I treatment in patients with elevated Tg and negative diagnostic RAI scans is very low. (962,963). While some reduction in serum Tg may be observed after such empiric therapy, one analysis concluded that there was no good evidence either for or against such treatment (964). In one small retrospective series of patients with structural disease but negative diagnostic ^{131}I WBSs, additional RAI therapy was associated with stability of disease in 44%, but progression of structural disease occurred in 56% of the patients (887).

[C30] RAI treatment of bone metastases

■ RECOMMENDATION 79

(A) RAI therapy of iodine-avid bone metastases has been associated with improved survival and should be employed, although RAI is rarely curative.

(Strong recommendation, Moderate-quality evidence)

(B) The RAI activity administered can be given empirically (100–200 mCi) or determined by dosimetry.

(Weak recommendation, Low-quality evidence)

RAI therapy for patients with bone metastases is rarely curative, but some patients with RAI-avid bone metastases may benefit from this therapy (842,947). A dosimetrically

Downloaded by Memorial Sloan Kettering from www.liebertpub.com at 08/14/19. For personal use only.

determined administered dose of RAI may be beneficial for patients with bone metastases (908), although this is not proven in controlled studies. Patients undergoing RAI therapy for bone metastases should also be considered for directed therapy of bone metastases that are visible on anatomical imaging (section [C38]). This may include surgery, external beam radiation therapy, and other focal treatment modalities. These patients should also be considered for systemic therapy with bone-directed agents (section [C47]).

[C31] When should empiric RAI therapy be considered for Tg-positive, RAI diagnostic scan–negative patients?

■ **RECOMMENDATION 80**

In the absence of structurally evident disease, patients with stimulated serum Tg <10 ng/mL with thyroid hormone withdrawal or <5 ng/mL with rhTSH (indeterminate response) can be followed without empiric RAI therapy on continued thyroid hormone therapy alone, reserving additional therapies for those with rising serum Tg levels over time or other evidence of structural disease progression.

(Weak recommendation, Low-quality evidence)

■ **RECOMMENDATION 81**

Empiric (100–200 mCi) or dosimetrically determined RAI therapy may be considered in patients with more significantly elevated serum Tg levels (see Recommendation 80), rapidly rising serum Tg levels, or rising ant-Tg antibody levels, in whom imaging (anatomic neck/chest imaging and/or ^{18}FDG-PET/CT) has failed to reveal a tumor source that is amenable to directed therapy. The risk of high cumulative administered activities of RAI must be balanced against uncertain long-term benefits. If empiric RAI therapy is given and the posttherapy scan is negative, the patient should be considered to have RAI-refractory disease and no further RAI therapy should be administered.

(Weak recommendation, Low-quality evidence)

■ **RECOMMENDATION 82**

If persistent nonresectable disease is localized after an empiric dose of RAI, and there is objective evidence of significant tumor reduction, then consideration can be made for RAI therapy to be repeated until the tumor has been eradicated or the tumor no longer responds to treatment. The risk of repeated therapeutic doses of RAI must be balanced against uncertain long-term benefits.

(Weak recommendation, Low-quality evidence)

Factors to consider when selecting patients for empiric RAI therapy include the level of serum Tg elevation and the results of ^{18}FDG-PET scanning, if performed. Since tumors that are ^{18}FDG-PET positive generally do not concentrate RAI (965), RAI therapy is much less likely to be efficacious (965,966) and it is unlikely to alter the poorer outcome in such patients (823). Because of this, it is reasonable to perform ^{18}FDG-PET/CT scanning prior to consideration of empiric RAI therapy (967).

The cutoff value of serum Tg above which a patient should be treated with an empiric dose of RAI is not clear. Most studies have reported primarily on patients with Tg levels after T_4 withdrawal of 10 ng/mL or higher; it has been suggested that a corresponding level after rhTSH stimulation would be 5 ng/mL (321,782,962,968,969). Patients with a suppressed (624) or stimulated (970) serum Tg of 5 ng/mL or higher are unlikely to demonstrate a decline without therapy, and they have higher rates of subsequent structural recurrence than those with lower serum Tg levels (970). In addition, a rising serum Tg indicates disease that is likely to become clinically apparent, particularly if it is rapidly rising (622,971,972).

If serum Tg levels suggest residual or recurrent disease, but diagnostic RAI WBS imaging is negative and structural imaging does not reveal disease that is amenable to directed therapy (surgical, thermal ablation, EBRT, alcohol ablation, see section [C17 and C38]), then empiric therapy with RAI (100–200 mCi) or dosimetrically determined RAI activities can be considered for two purposes: (i) to aid in disease localization, and/or (ii) as therapy for nonsurgical disease. This approach may identify the location of persistent disease in approximately 50% of patients (968,973,974), although the reported range of success is wide. From a therapeutic perspective, over half of patients experience a fall in serum Tg after empiric RAI therapy in patients with negative diagnostic WBS (963,969,975,976); however, there is no evidence for improved survival with empiric therapy in this setting (782,962,968). Further, there is evidence that Tg levels may decline without specific therapy in a significant proportion of patients with Tg levels <10 ng/mL (539,618–620,624,782,970–972,975,977–979). The most compelling evidence for benefit from empiric RAI therapy is for pulmonary metastases, which are not amenable to surgical management or EBRT (782,844,980).

[C32] What is the management of complications of RAI therapy?

■ **RECOMMENDATION 83**

The evidence is insufficient to recommend for or against the routine use of measures to prevent salivary gland damage after RAI therapy.

(No recommendation, Low-quality evidence)

■ **RECOMMENDATION 84**

Patients with xerostomia are at increased risk of dental caries and should discuss preventive strategies with their dental/oral health professional.

(Weak recommendation, Low-quality evidence)

■ **RECOMMENDATION 85**

Surgical correction should be considered for nasolacrimal outflow obstruction, which often presents as excessive tearing (epiphora) but also predisposes to infection.

(Strong recommendation, Low-quality evidence)

While RAI appears to be a reasonably safe therapy, it is associated with a cumulative dose-related low risk of early- and late-onset complications such as salivary gland damage, dental caries (981), nasolacrimal duct obstruction (982), and secondary malignancies (762,763,961,983,984), and it may likely contribute to long-term dysphagia (985). Therefore, it is important to ensure that the benefits of RAI therapy, especially repeated courses, outweigh the potential risks. There is probably no dose

Downloaded by Memorial Sloan Kettering from www.liebertpub.com at 08/14/19. For personal use only.

of RAI that is completely safe, nor is there any maximum cumulative dose that could not be used in selected situations. However, with higher individual and cumulative doses there are increased risks of side effects as discussed previously.

For acute transient loss of taste or change in taste and sialadentitis, recommended measures to prevent damage to the salivary glands have included hydration, sour candies, amifostine, and cholinergic agents (986), but evidence is insufficient to recommend for or against these modalities. One study suggested sour candy may actually increase salivary gland damage when given within 1 hour of RAI therapy, as compared to its use until 24 hours post therapy (987). Another study showed that the use of lemon slices within 20 min of ^{124}I administration resulted in increased radiation absorbed dose to the salivary glands (988). A different study suggested that early use and multiple administered doses of lemon juice transiently decreased radiation exposure to the parotid glands (989), so the exact role and details of use of sialagogues to prevent salivary gland damage remains uncertain. Patients with painful sialadenitis may receive pain relief from local application of ice. For chronic salivary gland complications, such as dry mouth and dental caries, cholinergic agents may increase salivary flow (986). Interventional sialendoscopy has been shown in a number of small studies to be an effective treatment in patients with RAI-induced sialadenitis that is unresponsive to medical therapy (990–992).

[C33] How should patients who have received RAI therapy be monitored for risk of secondary malignancies?

■ **RECOMMENDATION 86**

Although patients should be counseled on the risks of second primary malignancy with RAI treatment for DTC, the absolute increase in risk of developing a second primary malignancy attributable to RAI treatment is considered small and does not warrant specific screening to any extent greater than age-appropriate general population health screening.

(Weak recommendation, Low-quality evidence)

Most long-term follow-up studies variably report a very low risk of secondary malignancies (bone and soft tissue malignancies, including breast, colorectal, kidney, and salivary cancers, and leukemia) in long-term survivors (762,763). A meta-analysis of two large multicenter studies showed that the RR of second malignancies was significantly increased at 1.19 ([95% CI 1.04–1.36], $p < 0.010$), relative to thyroid cancer survivors not treated with RAI, although the absolute increase in second primary malignancy risk attributable to RAI is considered to be small (961). The risk of leukemia was also significantly increased in thyroid cancer survivors treated with RAI, with a RR of 2.5 ([95% CI 1.13–5.53], $p < 0.024$) (961). Studies on T1N0 PTC from the SEER registry suggested that the excess risk of leukemia after RAI treatment was greater in young individuals compared with older individuals. The excess risk of leukemia was significantly greater in patients aged <45 years (standardized incidence rate of 5.32 [95% CI 2.75–9.30] for those aged <45 years versus 2.26 [95% CI 1.43–3.39] in older individuals) (766). The risk of secondary malignancies is dose related (763), with an excess absolute risk of 14.4 solid cancers and of 0.8 leukemias per gigabecquerel (1 GBq = 27 mCi) of ^{131}I at 10,000 person-years of follow-up. Cumulative ^{131}I activities above 500–600 mCi are associated with a significant increase in risk. In theory, the risk of second primary malignancies increases with higher administered activities. There is no direct evidence of increased risk of secondary malignancies after a single administration of 30–100 mCi in comparison to the observed risk of second primary cancer in thyroid cancer patients who have not been treated with ^{131}I. The risk is clearly increased in patients who have been treated with a large cumulative activity that is higher than 600 mCi (763), which suggests a dose–effect relationship. This is an argument for using the minimal activity necessary to treat each patient. There appears to be an increased risk of breast cancer in women with thyroid cancer (762,983,993). It is unclear whether this is due to screening bias, RAI therapy, or other factors. An elevated risk of breast cancer with ^{131}I was not observed in another study (764). The use of laxatives may decrease radiation exposure of the bowel, particularly in patients treated after prolonged withdrawal of thyroid hormone, and vigorous oral hydration will reduce exposure of the bladder and gonads (22).

[C34] What other testing should patients receiving RAI therapy undergo?

■ **RECOMMENDATION 87**

Patients receiving therapeutic doses of RAI should have baseline complete blood count and assessment of renal function.

(Weak recommendation, Low-quality evidence)

Published data indicate that when administered activities are selected to remain below 200 cGy to the bone marrow, minimal transient effects are noted in white blood cell and platelet counts (955). However, persistent mild decrements in white blood cell count and/or platelets are seen in some patients who have received multiple RAI therapies. Further, radiation to the bone marrow is impacted by several factors, including renal function. The kidneys are a major means of iodine excretion from the body, and physiologic radioisotope study research in nonthyroidectomized individuals has shown that renal impairment significantly reduces RAI excretion (994).

[C35] How should patients be counseled about RAI therapy and pregnancy, breastfeeding, and gonadal function?

■ **RECOMMENDATION 88**

Women of childbearing age receiving RAI therapy should have a negative screening evaluation for pregnancy prior to RAI administration and avoid pregnancy for 6–12 months after receiving RAI.

(Strong recommendation, Low-quality evidence)

■ **RECOMMENDATION 89**

Radioactive iodine should not be given to nursing women. Depending on the clinical situation, RAI therapy could be deferred until lactating women have stopped breastfeeding or pumping for at least 3 months. A diagnostic ^{123}I or low-dose ^{131}I scan should be considered in recently lactating women to detect breast uptake that may warrant deferral of therapy.

Downloaded by Memorial Sloan Kettering from www.liebertpub.com at 08/14/19. For personal use only.

(Strong recommendation, Moderate-quality evidence)

■ **RECOMMENDATION 90**

Men receiving cumulative RAI activities ≥400 mCi should be counseled on potential risks of infertility.

(Weak recommendation, Low-quality evidence)

Women about to receive RAI therapy should first undergo pregnancy testing. Gonadal tissue is exposed to radiation from RAI in the blood, urine, and feces. Temporary amenorrhea/oligomenorrhea lasting 4–10 months occurs in 20%–27% of menstruating women after ^{131}I therapy for thyroid cancer. Although the numbers of patients studied are small, long-term rates of infertility, miscarriage, and fetal malformation do not appear to be elevated in women after RAI therapy (995–997). One recent large retrospective cohort study showed that use of RAI was associated with delayed childbearing and decreased birthrate in later years, although it is unclear if this is due to reproductive choice or reproductive health (998). Another large retrospective study suggested that pregnancy should be postponed for 1 year after therapy because of an increase in miscarriage rate (999), although this was not confirmed in a subsequent study (1000). Ovarian damage from RAI therapy may result in menopause occurring approximately 1 year earlier than in the general population, but this result was not associated with cumulative dose administered or the age at which the therapy was given (1001). Radioiodine is also significantly concentrated in lactating breast tissue (1002). Therefore, RAI should not be given to women who are breastfeeding (1003). A diagnostic ^{123}I or low-dose ^{131}I scan can be employed in recently lactating women to detect breast uptake that may warrant deferral of therapy (662). Dopaminergic agents might be useful in decreasing breast exposure in recently lactating women, although caution should be exercised given the risk of serious, albeit rare, side effects associated with their routine use to suppress postpartum lactation (1003,1004).

In men, RAI therapy may be associated with a temporary reduction in sperm counts and elevated serum follicle-stimulating hormone levels (1005,1006). Higher cumulative activities (500–800 mCi) in men are associated with an increased risk of persistent elevation of serum follicle-stimulating hormone levels, but fertility and risks of miscarriage or congenital abnormalities in subsequent pregnancies are not changed with moderate RAI activities (~200 mCi) (1007,1008). Permanent male infertility is unlikely with a single ablative activity of RAI, but theoretically there could be cumulative damage with multiple treatments. It has been suggested that sperm banking be considered in men who may receive cumulative RAI activities ≥400 mCi (1006). Gonadal radiation exposure is reduced with good hydration, frequent micturition to empty the bladder, and avoidance of constipation (1009). Some specialists recommend that men wait 3 months (or one full sperm cycle) to avoid the potential for transient chromosomal abnormalities.

[C36] How is RAI-refractory DTC classified?

■ **RECOMMENDATION 91**

Radioiodine-refractory structurally evident DTC is ***classified*** in patients with appropriate TSH stimulation and iodine preparation in four basic ways: (i) the malignant/metastatic tissue does not ever concentrate RAI (no uptake outside the thyroid bed at the first therapeutic WBS), (ii) the tumor tissue loses the ability to concentrate RAI after previous evidence of RAI-avid disease (in the absence of stable iodine contamination), (iii) RAI is concentrated in some lesions but not in others; and (iv) metastatic disease progresses despite significant concentration of RAI.

When a patient with DTC is classified as refractory to RAI, there is no indication for further RAI treatment.

(Weak recommendation, Low-quality evidence)

The prognosis of patients with DTC is usually favorable, even when metastatic RAI-avid disease is present. For this reason, ^{131}I is considered the gold standard in the treatment of metastatic disease. However, many DTC patients with advanced disease do not respond or become refractory to ^{131}I, with some of these patients dying within 3–5 years, but there are also long-term survivors with very slowly progressive disease.

Iodine 131 refractory DTC includes four categories of patients (1010). In the first category, the malignant/metastatic tissue does not concentrate ^{131}I outside the thyroid bed at the first therapeutic WBS. There is no evidence in these patients that further treatment with RAI may be of any benefit. Furthermore, patients with measurable disease with an absence of ^{131}I uptake on subsequent diagnostic WBS may also be considered refractory because even when uptake is seen on posttherapy scan, it will likely have limited benefit. In the second category, the tumor tissue loses the ability to concentrate ^{131}I (in the absence of stable iodine contamination) after previous evidence of uptake. This often occurs in patients with large and multiple metastases and is due to the eradication by ^{131}I treatment of differentiated cells able to concentrate RAI but not of poorly differentiated cells that do not concentrate ^{131}I and that generally will progress. In the third category, ^{131}I uptake is retained in some lesions but not in others; this pattern is frequent in patients with multiple large metastases as shown by ^{124}I studies on PET scan (918) and by comparing results of ^{18}FDG-PET scan with ^{131}I WBS. In these patients, progression is likely to occur in metastases without uptake (in particular when ^{18}FDG uptake is present), and RAI treatment will not be beneficial on the overall outcome of the disease. Some patients may have predominantly RAI-avid disease with only a few lesions that do not concentrate RAI. While these patients technically meet the definition of RAI-refractory disease, they may benefit from a combination of RAI therapy for the majority of the lesions and directed therapy (section [C38]; Recommendation 93) for those few lesions that do not concentrate RAI. In the fourth category, metastatic disease progresses despite significant uptake of ^{131}I (new lesions, progressive growth of lesions, continual rise in serum Tg within months of RAI therapy). The definition of any of these possibilities depends on imaging modalities, including a posttherapy ^{131}I WBS combined with other imaging modalities, such as CT scan, MRI, or ^{18}FDG PET/CT. The criteria for RAI-refractory disease remain somewhat controversial. Future studies will hopefully help to refine this definition.

Predictive factors for tumor response to RAI treatment are indeed the presence of ^{131}I uptake by tumor, and among those patients with RAI uptake, younger age, well-differentiated histotype, small metastases, and low ^{18}FDG uptake. Indeed these

Downloaded by Memorial Sloan Kettering from www.liebertpub.com at 08/14/19. For personal use only.

parameters are closely interrelated (823,824,844) and may permit predicting the outcome of RAI treatment at the time of the discovery of the metastases. About two-thirds of patients with metastases demonstrate ^{131}I uptake in their metastases, and only half of them will be cured with repeated courses of ^{131}I treatment.

Less clear is the case of patients with visible RAI uptake in all the known lesions, who are not cured despite several treatment courses but whose disease remains stable and does not progress according to RECIST criteria. It is controversial whether these patients should be considered ^{131}I refractory and whether RAI treatment should be abandoned in favor of other treatment modalities. The probability to obtain a cure with further treatments is low and side effects may increase, including the risk of secondary cancers and leukemias (762,763,844,961). Several parameters should then be taken into consideration for the decision to continue treatment with RAI, including response to previous treatment courses, high or significant ^{131}I uptake after previous treatment courses, low ^{18}FDG uptake in tumor foci, and limited side effects from the RAI therapy.

[C37] Which patients with metastatic thyroid cancer can be followed without additional therapy?

■ RECOMMENDATION 92

(A) Patients with ^{131}I-refractory metastatic DTC that is asymptomatic, stable, or minimally progressive who are not likely to develop rapidly progressive, clinically significant complications and do not have indications for directed therapy can be monitored on TSH-suppressive thyroid hormone therapy with serial radiographic imaging every 3–12 months.

(Weak recommendation, Low-quality evidence)

(B) *BRAF* or other mutational testing is not routinely recommended for prognostic purposes in patients with RAI-refractory, progressive, locally advanced, or metastatic DTC.

(Weak recommendation, Moderate-quality evidence)

Patients with ^{131}I-refractory metastatic DTC often have an indolent clinical course, with no apparent symptoms or adverse impact from their disease burden for many years. In the absence of tolerable therapies with significant likelihood of inducing durable complete remission or improving overall survival, treatment should be limited to interventions that prevent morbidity or palliate symptoms. Thus, once ^{131}I refractory metastatic disease is identified, attention should be directed toward (i) determining the extent of metastatic disease by staging imaging studies such as CT, ^{18}FDG PET/CT, or MRI as described in sections [C9–C13]; (ii) assessing degree of current or potential symptoms from the disease; (iii) understanding the comorbidities that might influence the choice of therapies for the metastatic disease; and (iv) determining the rate of progression of radiographically evident lesions. Serial assessment of the size and development of metastatic lesions can be enhanced by applying criteria similar to RECIST, as commonly used to assess tumor response in clinical trials (1011). Representative soft tissue metastatic lesions, typically >1 cm, are identified as ''targets'' on cross-sectional imaging, with the longest diameter of each lesion measured. Disease extent can be considered to be stable or minimally progressive if the sum of the longest diameters of the target lesions increases <20% in the absence of new metastatic foci on sequential imaging over 12–15 months of follow-up. No study has identified an appropriate frequency for repeat imaging, but it is reasonable to repeat the staging imaging studies within 3–12 months based on the disease burden and locations of lesions (953,1012). More frequent assessment could be considered once metastatic disease is identified and/or in response to intercurrent patient symptoms, and less frequent imaging performed once a pattern of stability is identified. The development of progressive disease, either by RECIST assessment identifying at least 20% increase in sum of longest diameters of target lesions, the appearance of significant new metastatic lesions, or development of disease-related symptoms should warrant consideration of appropriate systemic therapies (section [C41]) beyond TSH-suppressive thyroid hormone and/or directed therapies (sections [C15] and [C38]). Although serum Tg levels should be measured as biomarkers of the disease extent, patients should not be identified as having progressive disease and requiring more aggressive therapy solely on the basis of rising levels of Tg; accelerating increases in Tg levels should, however, lead to consideration of more frequent and comprehensive imaging in efforts to identify previously occult structural correlates.

In each of two recent international, randomized phase III trials of kinase inhibitors for therapy of progressive, RAI-refractory, metastatic DTC, patients whose tumors contained the $BRAF^{V600E}$ mutation who were randomized to the placebo treatment arms experienced similar progression-free survival compared with those whose tumors did not harbor a *BRAF* mutation (1013,1014). Thus, *BRAF* mutation status does not appear to be of prognostic value once patients reach this degree of advanced disease that would have qualified them for these clinical trials, that is, RAI-refractory, locally advanced, or metastatic DTC that has progressed by RECIST within 13 or 14 months.

[C38] What is the role for directed therapy in advanced thyroid cancer?

■ RECOMMENDATION 93

(A) Both stereotactic radiation and thermal ablation (RFA and cryoablation) show a high efficacy in treating individual distant metastases with relatively few side effects and may be considered as valid alternatives to surgery.

(Weak recommendation, Moderate-quality evidence)

(B) Stereotactic radiation or thermal ablation should be considered prior to initiation of systemic treatment when the individual distant metastases are symptomatic or at high risk of local complications.

(Strong recommendation, Moderate-quality evidence)

Several local treatment modalities other than surgery may be used to treat brain, lung, liver, and bone lesions from thyroid carcinoma. These local treatment modalities should be considered prior to initiation of systemic treatment when the individual distant metastases are symptomatic or at high risk of local complications. They may also be helpful in case

Downloaded by Memorial Sloan Kettering from www.liebertpub.com at 08/14/19. For personal use only.

of progression in a single lesion in patients with otherwise controlled disease during systemic treatment. In these patients, benefits can be achieved in preventing local complications, in improving symptoms such as pain, in delaying the initiation of systemic treatments, and even in improving survival. These techniques can be a less aggressive alternative to surgery and may be indicated in cases of lung metastases associated with insufficient respiratory reserve, poor patient clinical status, or after multiple previous surgical resections, local recurrence at the site of previous surgery, or refusal of additional surgery.

In selected patients, the techniques may be an alternative to surgery as first-line treatment, and they may induce local tumor control with a similar efficacy to surgical resection. Of interest, long-term benefits in terms of disease control have been reported in patients with a single or few metastases and in whom the disease is slowly progressive.

Interventional radiology (thermal ablation and cement injections), SBRT, or intensity modulated radiotherapy are the most frequently used techniques. The main principle of these techniques is to selectively treat the lesion, be minimally invasive, and be well tolerated with relatively few side effects. The indications and the feasibility of each technique depend on the location and the size of the lesion to be treated. Experience with metastases from thyroid cancer is scarce, and most available data have been obtained in patients with metastases from nonthyroid cancers.

SBRT allows for delivering high radiation doses in few fractions to the target tumoral lesion with a high degree of precision, minimizing the radiation of normal surrounding tissue. It has been used in several trials to treat brain, liver, lung, and bone metastases.

For patients with few (one to three) brain metastases, SBRT is as effective as surgery and can be repeated in case of appearance of new brain lesions. It is usually well tolerated, and brain necrosis that occurred in less than 10% of cases is usually limited and had no clinical consequences. The patient outcome depends mostly on the progression rate of extracerebral lesions (1015).

Data on lung and liver metastases are available only in retrospective studies on low numbers of patients and with a median follow-up of less than 1 year in most cases and in one prospective study (1016). This study included patients with many different primary tumors, including 10% of the patients having thyroid cancer. They showed a local control rate ranging from 63% to 98% in lung lesions and from 57% to 100% in liver lesions, with a cumulative dose delivered ranging from 20 to 75 Gy in 5–15 fractions. The local tumor control seems to be long lasting with complete response ranging from 70% to 90% at 2–3 years. Furthermore, rare (<3%) grade 3–4 toxicities (pneumonitis, pleural effusion, intestinal complications) were reported (1017). These toxicities are much less common that those associated with percutaneous treatment modalities. The local control rate seems to be dose-related, but the optimal protocol for SBRT is still not established.

Concerning bone lesions, radiotherapy plays an important role because it can complement surgery in case of incomplete resection or be used alone for pain relief or palliation. In many cases, usual radiotherapy can be given. However, the major limitation of radiotherapy in spine lesions is the cumulative dose to the spinal cord. SBRT compared to standard radiotherapy demonstrated a higher efficacy on tumor control and for limiting radiation to the spinal cord, especially in patients who need to be re-irradiated. A local tumor control rate of bone lesions for SBRT ranging from 88% to 100% was reported especially for lesions that were previously surgically resected, with a pain relief rate of 30%–83%. SBRT protocols differed among studies, with a maximum of 30 Gy administrated in one to five fractions but a single dose of 12.5–15 Gy seems to achieve similar results (1018). Spinal myelopathy or vertebral fractures are the most important side effects, especially in case of large-volume lesions.

Percutaneous thermal ablation is aimed at destroying tumor foci by increasing (RFA) or decreasing (cryoablation) temperatures sufficiently to induce irreversible cellular damages.

RFA is performed for liver, lung, and bone tumor foci. Clinical trials showed high efficacy of RFA for liver lesions, especially from colorectal cancer with long-term local disease control ranging from 40% to 80%, depending on lesion size, and a prolonged overall survival in treated patients (1019,1020).

In a total of 100 lung lesions including primary lung tumors and metastases, RFA was both efficient and well tolerated, with a complete tumor control rate of 93% at 18 months (1021). A multicenter prospective trial on 183 lung metastases from cancer other than colorectal showed a complete response rate of 88% at 1 year and an overall survival of 92% and 64% at 1 year and at 2 years, respectively (1022). Recurrence occurs more frequently in lesions >3 cm and can be detected early after ablation (within 3 months) by ^{18}FDG PET/CT (824,1016). Cases of delayed recurrence have also been reported, and long-term follow-up is needed. RFA may be considered for lung lesions <3 cm of diameter, without soft tissue or mediastinum invasion and without contact with large vessels. Furthermore, repeated treatments can be performed on the same lesion and multiple lesions can be treated in the same patient.

RFA or cryoablation of bone lesions showed promising results with rapid (1–7 days) and long-lasting pain control (1023,1024). Cryoablation is a safe technique to treat or to stabilize bone lesions, is frequently associated with cementoplasty to consolidate the bone and avoid subsequent complications, and can treat larger lesions than RFA.

Local disease control was achieved in the few reported cases of lung and bone metastases from thyroid cancer treated by thermal ablation (883,1016,1025). The association of cryoablation and cementoplasty seems promising in purely lytic bone metastases from thyroid cancer. Furthermore, in three patients with liver metastases from thyroid cancer (two MTC and one FTC) RFA was feasible and reduced local symptoms (1026). Multidisciplinary treatment for metastases from thyroid cancer especially for bone metastases—including, for example, thermal ablation (RFA or cryoablation) and/or cementoplasty associated with systemic treatment (RAI, bone-directed agents, or chemotherapy)—can improve the patient's quality of life by reducing pain and prolonging time to skeletal events, delaying initiation of systemic treatment, and even improving patient survival (1027).

The toxicity of thermal ablation is generally low, but pneumothorax or pleural effusion was observed in up to 50% of RFA procedures for lung lesions, but it rarely required further treatments. Local pain or transient neurological deficit or vertebral fracture can occur in case of ablation of bone

Downloaded by Memorial Sloan Kettering from www.liebertpub.com at 08/14/19. For personal use only.

lesions (5%–6%), and intestinal perforation, abdominal pain, or intraperitoneal bleeding was observed following ablation of liver lesions (1021,1028).

Published experience using thermal ablation and stereotactic radiation in thyroid cancer patients is limited, and recommendations are currently based on more robust evidence in other solid tumors. Randomized prospective studies comparing the efficacy and tolerability of these different techniques are lacking, and their choice in clinical practice is based on local experience, lesion location as well as patient status and preference.

[C39] Treatment of brain metastases

■ **RECOMMENDATION 94**

While surgical resection and stereotactic EBRT are the mainstays of therapy for CNS metastases, RAI can be considered if CNS metastases concentrate RAI. If RAI is being considered, stereotactic EBRT and concomitant glucocorticoid therapy are recommended prior to RAI therapy to minimize the effects of a potential TSH-induced increase in tumor size and RAI-induced inflammatory response.

(Weak recommendation, Low-quality evidence)

Brain metastases typically occur in older patients with more advanced disease and are associated with a poor prognosis (933). Surgical resection and stereotactic EBRT are the mainstays of therapy (933,1029,1030). There are few data showing efficacy of RAI. Stereotactic radiation therapy is preferred to whole-brain radiation because life expectancy in patients with brain metastases may be prolonged, and stereotactic radiation induces less short- and long-term toxicity compared with whole-brain radiation (fatigue, headache, cognitive decline, and behavioral changes), and it may be effective even in patients with multiple brain lesions.

[C40] Who should be considered for clinical trials?

■ **RECOMMENDATION 95**

Patients should be considered for referral to participate in prospective therapeutic clinical trials based upon specific eligibility requirements for given studies and the likelihood that the patient may or may not benefit from study participation. Clinicians considering referral of patients for trials should review available treatment options and eligibility criteria, preferably through discussions with trial center personnel and review of trial materials at the website www.clinicaltrials.org.

(Strong recommendation, Moderate-quality evidence)

A therapeutic clinical trial is a systematic investigation of the effectiveness and safety of a potential new or modified treatment or combination of treatments, potentially including medications, surgery, radiation therapy, and/or other novel or revised approaches. A broad variety of such trials may exist at any given time, which can generally be identified through online databases such as www.clinicaltrials.org, best supplemented with direct contact with the institutions conducting trials of particular interest so as to ensure trial availability and patient eligibility. There is limited evidence that enrollment into clinical trials is associated with lower overall cancer-specific mortality for patients with common cancers, even within contexts in which approved and ''standard of care'' therapies already exist (1031). The reasons for this association are unclear, but there is no evidence to suggest that trial participation is deleterious to patient outcomes, and it may be beneficial. Participation in a clinical trial should be considered in any situation wherein there exists no effective or proven standard of care, or when a standard of care is being compared with a promising new or investigational therapy. Adjuvant therapy trials may be appropriate for patients at high risk for disease recurrence following primary treatment who wish to pursue aggressive therapy. For patients with RAI-refractory carcinoma that is locally advanced or metastatic, clinical trials may be appropriate in the setting of disease that is considered progressive by RECIST criteria, especially if progression occurred after use of an approved kinase inhibitor such as lenvatinib or sorafenib, and/or if approved therapies are otherwise unaffordable to a specific patient. Patients demonstrated to have specific therapeutically targetable tumor alterations, such as *BRAF* mutations or *PAX8/PPARγ* or *ALK* rearrangements, can also be considered for trials testing therapies specifically targeting these alterations. However, given the indolent nature of metastatic disease in most patients, therapeutic clinical trial participation should not be considered for patients with stable, asymptomatic metastatic disease unless agents with significant likelihood of complete remission, prolongation of survival, or biologic impact such as redifferentiation that could sensitize to definitive therapy are available (see section [C37]).

[C41] What is the role of systemic therapy (kinase inhibitors, other selective therapies, conventional chemotherapy, bisphosphonates, denosumab) in treating metastatic DTC?

Systemic therapeutics of several types *in selected clinical contexts* appear to provide clinical benefit in treating metastatic DTC (1032). Benefit has been demonstrated in the form of improved progression-free survival (delay in time to disease progression or death) in three randomized, double-blinded, placebo-controlled clinical trials: vandetanib (1033), sorafenib (1013), and lenvatinib (1034). Benefit has also been demonstrated in the form of induced durable tumor regression (1035–1037).

However, randomized clinical trial data are not yet available to address many additional critical questions, including effects of systemic therapies of various types on survival and quality of life, or to address critical issues of optimal patient selection/inclusion/exclusion criteria for therapy and duration of treatment.

To date, no clinical trial has demonstrated an overall survival advantage or improved quality of life from use of any therapy in RAI-refractory DTC (1013,1034). Consequently, therapeutic decisions are presently based upon the convergence of expert opinion and patient preference/philosophy, thus emphasizing the critical need to address the above questions definitively through clinical trials. It is therefore important to involve highly skilled clinicians familiar with RAI-refractory disease and these systemic therapies in decision-making until definitive guidelines can be developed based upon more rigorous data. As a guide, evidence-based recommendations with expert consensus have been recently published (953).

It should also be highlighted that, broadly construed, systemic therapy encompasses not only more recently emerging

Downloaded by Memorial Sloan Kettering from www.liebertpub.com at 08/14/19. For personal use only.

Downloaded by Memorial Sloan Kettering from www.liebertpub.com at 08/14/19. For personal use only.

''targeted'' approaches, but also historical ''mainstay'' therapies including TSH suppression and RAI. Although more ''novel'' approaches have attracted attention recently, it is important to optimally apply fundamental approaches. In this regard, therapeutic RAI should also be used to optimal effect prior to the initiation of more recent/novel therapies. To accomplish this requires attention to detail, including ensuring adequate TSH stimulation, patient adherence to low-iodine pre-RAI therapy dietary restrictions, and avoidance of proximal preceding iodine contamination from IV contrast agents, with verification by urinary iodine concentration measurements in selected cases. In this context, occasional patients previously declared ''RAI-refractory'' can instead be found to have RAI-responsive disease when such details are attended to if previously neglected.

Also important is the consideration of alternatives to the use of systemic therapy, such as the application of surgery or other localized approaches (including radiation therapy or thermal ablation approaches). In patients in whom the threats imposed by cancer are more localized, directed approaches may have greater potential to control localized disease and symptoms compared to systemic therapies, especially given the absence of data to indicate survival benefit or improved quality of life from the application of systemic therapies in advanced RAI-refractory DTC.

It is also critically important to ensure that the disease prompting therapy represents metastatic thyroid cancer. In particular, because pulmonary nodules attributable to benign causes are common, the presence of pulmonary nodules does not in and of itself justify the application of systemic therapy. Thus, in cases of diagnostic uncertainty in which the result would have definitive therapeutic implications, biopsy is required, especially when Tg levels are low/unhelpful (such as in the presence of anti-Tg antibodies). Conversely, stable, asymptomatic pulmonary nodules of a few millimeters in size likely do not justify invasive assessment or systemic therapy.

The introduction of systemic therapy requires that both the clinician and the patient agree that clinical benefits are expected to exceed risks for that individual patient. The problem in this determination, however, is that it is often very difficult to precisely define such risks and benefits because they vary greatly depending upon patient context and they are often poorly articulated in the literature. It is also critical to weigh not just risks of death and injury, but also risks of systemic therapies on quality of life, especially as viewed by a particular patient considering treatment. Hence, the decision is not based solely on benefits and risks of therapy, but also on patient value judgments. Issues of risks and benefits are reviewed in this context in conjunction with each therapeutic modality below. Finally, it is important that the involved care team (physicians, physician assistants, nurse practitioners, nurses) be experienced in the use and management of toxicities associated with these therapies.

[C42] Kinase inhibitors

■ RECOMMENDATION 96

(A) Kinase inhibitor therapy should be considered in RAI-refractory DTC patients with metastatic, rapidly progressive, symptomatic, and/or imminently threatening disease not otherwise amenable to local control using other approaches. Kinase inhibitors that are FDA approved for differentiated thyroid carcinoma or other available kinase inhibitors (preferably within the context of therapeutic clinical trials) can be considered since the impact of these agents on overall survival and quality of life remains to be defined.

(Weak recommendation, Moderate-quality evidence)

(B) Patients who are candidates for kinase inhibitor therapy should be thoroughly counseled on the potential risks and benefits of this therapy as well as alternative therapeutic approaches including best supportive care. Appropriate informed consent should be obtained and documented in the medical record prior to initiation of any therapy, regardless of whether the patient is being treated in the context of a clinical trial.

(Strong recommendation, Low-quality evidence)

Cytotoxic chemotherapy has historically produced disappointing results in patients with DTC (1038). Kinase inhibitors, many of which share the common target of the VEGF receptor (VEGFR) (e.g., sorafenib, pazopanib, sunitinib, lenvatinib, axitinib, cabozantinib, and vandetanib), have recently emerged as highly promising therapies for metastatic RAI-refractory DTC (1032). Kinase inhibitors, however, are associated with numerous adverse effects including diarrhea, fatigue, induced hypertension (requiring initiation of antihypertensive therapy in about half of all previously normotensive individuals), hepatotoxicity, skin changes, nausea, increased LT_4 dosage requirement, changes in taste, and weight loss. These potential side effects have high probability of negatively impacting quality of life and/or necessitating dosage reductions in many patients and treatment discontinuation in up to 20% of patients. Furthermore, these agents are also associated with more serious and potentially fatal risks including of thrombosis, bleeding, heart failure, hepatotoxicity, gastrointestinal tract fistula formation, and intestinal perforation (1039). Overall, the risk of therapy-related death in cancer patients treated with oral kinase inhibitors is about 1.5%–2% (RR = 2.23, $p < 0.023$, compared with randomized placebo treated control cancer patients) based upon meta-analysis of results from 10 recently published randomized trials conducted in several cancers (1039). In the setting of thyroid cancer, lenvatinib (now approved in the United States for use in RAI-refractory DTC) was associated with severe toxicities in 75% of patients and therapy-attributed mortality in 2.3% of patients (1034). While risk of drug-related death is relatively low, the knowledge of potentially fatal therapeutic outcomes should prompt considerable restraint in the use of kinase inhibitors, especially in patients who are asymptomatic and/or with stable or slowly progressive disease and in patients who can otherwise be effectively treated using directed therapies.

Three randomized placebo-controlled clinical trials (phase 2, vandetanib; phase 3, sorafenib and lenvatinib) had been published by the time of the writing of these guidelines, each demonstrating delayed time to disease progression among kinase inhibitor–treated patients relative to those treated with a placebo (1013,1033,1034). On this basis, sorafenib and lenvatinib were approved for use in the United States and the European Union for patients with advanced RAI-refractory

DTC. Sorafenib or vandetanib treatment were each associated with progression-free survival prolonged by 5 months, with <15% objective response rates, but with no improvement on overall survival demonstrated to date. Assessments comparing sorafenib to placebo outcomes demonstrated overall lower quality of life among sorafenib-treated patients relative to those treated with placebo, despite improved progression-free survival. Lenvatinib therapy was associated with longer prolonged median progression-free survival by 14.7 months compared with placebo, with a RECIST response rate of 65%, with some complete responses also reported. Despite these very encouraging results and regulatory approval, however, no statistically significant impact of lenvatinib (or any other kinase inhibitor) therapy on overall survival has yet been observed (1034). However, survival data in this context, where all three randomized and placebo-controlled DTC trials allowed crossover of placebo-treated patients to kinase inhibitor, must be interpreted with great caution. The crossover trial designs effectively ''contaminated'' overall survival data, with many placebo-treated patients later crossing over to receive open-label kinase inhibitor. Hence, the absence of a proven effect of kinase inhibitors on overall survival in these trials can best be interpreted as indicating that, among study populations, a delay in initiation of kinase inhibitor therapy until observation of RECIST disease progression among initially placebo-treated patients did not adversely affect overall survival.

Additional VEGFR-directed kinase inhibitors including axitinib, pazopanib, cabozantinib, and sunitinib also have activity in metastatic DTC based upon phase 2 therapeutic trials (1035–1037). No multi-arm comparison ''superiority'' phase 3 trial data in DTC are available to inform decision-making with regard to selection among available and mostly similarly targeted kinase inhibitors. Recent regulatory approval in DTC and more abundant outcome data in response to lenvatinib and sorafenib therapy in DTC (1013,1034, 1040–1043) prompt prominent consideration of either lenvatinib or sorafenib as a first-line therapy.

Despite encouraging trial results, the extent to which any kinase inhibitor may prolong overall survival and in which contexts remains undefined. In some situations, however, the decision to initiate kinase inhibitor therapy is straightforward. For example, patients with oxygen dependence attributable to DTC lung metastases are not only adversely affected by their cancers, but also imminently threatened. Such patients have potential to gain symptomatic benefit even in the absence of definite extension of life. At the other extreme, many patients with metastatic DTC are asymptomatic from their cancers and are not expected to be threatened by their cancers in the foreseeable future. These patients should remain on TSH-suppressive treatment as their primary therapeutic intervention rather than be exposed to kinase inhibitor therapy. For patients with disease between these two extremes, it is critical that risks and benefits of therapy, anticipated side effects, goals, patient context, and the therapeutic philosophy of each particular patient be thoroughly vetted so as to best individualize therapy. This decision is ideally made within the context of specialized centers with comprehensive knowledge of the natural history of the disease and of the effects of available therapies.

As a general ''expert consensus'' guideline, structurally progressive, symptomatic, and/or imminently threatening DTC (wherein disease progression is expected to require intervention and/or to produce morbidity or mortality in <6 months) that is RAI refractory and not amenable to satisfactory control using directed approaches (e.g., surgery, radiation therapy, thermal ablation) should prompt consideration of kinase inhibitor therapy. Specific characteristics impacting decision-making for starting such therapy are outlined in Table 16.

Patients who are candidates for kinase inhibitor therapy should be thoroughly counseled with regard not only to

Table 16. Factors to Review When Considering Kinase Inhibitor Therapy[a]

Factors favoring kinase inhibitor therapy	*Factors discouraging kinase inhibitor therapy*
Imminently threatening disease progression expected to require intervention and/or to produce morbidity or mortality in <6 months (e.g., pulmonary lesions or lymphadenopathy likely to rapidly invade airways, produce dyspnea, or cause bronchial obstruction).	Comorbidity including • Active or recent intestinal disease (e.g., diverticulitis, inflammatory bowel disease, recent bowel resection) • Liver disease • Recent bleeding (e.g., ulcer/GI bleed) or coagulopathy • Recent cardiovascular event(s) (e.g., CVA, MI) • Recent tracheal radiation therapy (this is associated with increased risks of aerodigestive fistula with kinase inhibitor therapy) • Cachexia/low weight/poor nutrition • Poorly controlled hypertension • Prolonged QTc interval/history of significant arrhythmia (includes ventricular and bradyarrhythmias) • Untreated brain metastases (controversial) • Recent suicidal ideation (suicide has been reported in depressed patients receiving TKIs)
Symptomatic disease (e.g., exertional dyspnea, painful unresectable adenopathy), not adequately addressable using directed therapy.	Life expectancy based upon other comorbidities estimated to be too brief to justify systemic therapy
Diffuse disease progression as opposed to focal progression (e.g., in multiple lung metastases, as opposed to a few growing lesions)	

[a]Bone metastases are often poorly responsive to kinase inhibitor therapy (see Bone-Directed Agents in section [C47]).
GI, gastrointestinal; CVA, cerebrovascular accident; MI, myocardial infarction; TKI, tyrosine kinase inhibitor.

Downloaded by Memorial Sloan Kettering from www.liebertpub.com at 08/14/19. For personal use only.

potential benefits, but also about potential side effects and risks of therapy and alternative therapeutic approaches including best supportive care, as should be the case with any medical therapeutic decision-making (1044). Such extensive and comprehensive discussions are particularly important to undertake in the context of kinase inhibitor therapy because of the high probability of side effects of these agents and because of their presently uncertain effects on patient overall survival and quality of life (1045).

Another critical and complex question often faced in treating patients with kinase inhibitor therapy centers on when treatment should be discontinued once initiated. In general, therapy should be continued so long as net benefit exceeds net detriment. In case of slow RECIST disease progression after significant tumor response, treatment may be maintained so long as overall disease control is maintained providing that toxicities are manageable. Progression rate should be taken into account, and when global progression is rapid, therapy should be discontinued. However, there are times when focal/oligometastatic disease progression amenable to directed therapies is noted. In such instances, superimposed loco-regional therapies in the setting of maintained systemic therapy can sometimes be in the best interest of a particular patient. For instance, in the setting of regressed lung metastases and yet progression at a solitary bone site, maintained systemic therapy with superimposed directed radiation therapy may be reasonable.

[C43] Patients for whom first-line kinase inhibitor therapy fails

■ **RECOMMENDATION 97**

Patients who have disease progression while on initial kinase inhibitor therapy without prohibitive adverse effects should be considered for second-line kinase inhibitor therapy. Ideally, such therapy should be undertaken within the context of therapeutic clinical trials.

(Weak recommendation, Low-quality evidence)

DTC patients who progress through first-line line kinase inhibitor therapy commonly respond to a second similarly targeted agent, and thus they should be considered candidates for second-line kinase inhibitor therapy (1014,1046). Hence, the selection of an agent for initial therapy may be less critical in some senses because many patient will go on to receive several kinase inhibitors over their disease courses. In the near future, other treatment modalities, such as RAI resensitization therapy, immunotherapy, or drugs directed to other targets, may also offer additional therapeutic options.

[C44] Management of toxicities from kinase inhibitor therapy

■ **RECOMMENDATION 98**

Proactive monitoring and timely intervention in response to emergent toxicities are critical components of management in patients receiving kinase inhibitor therapy.

(Strong recommendation, Low-quality evidence)

Patients treated with kinase inhibitors are subject to many potential toxicities that can negatively impact quality of life or even be fatal; as a consequence, great care must be taken not only in selecting appropriate patients for therapy, but also in monitoring patients once they are receiving kinase inhibitor therapy (1044). Some toxicities (e.g., fatigue, diarrhea, gastrointestinal symptoms, cutaneous effects) will be symptomatic and can be more easily addressed upon close communication with patients. However, there are also more serious potential toxicities that might not be expected to immediately lead to patient symptoms (e.g., hepatotoxicity, prolonged QTc) that require proactive screening (Table 17).

Hypertension and hepatotoxicity are especially important to serially monitor and rapidly address. Cardiotoxicity is also important to be aware of and to monitor according to patient risk factors, agent used, and induced symptoms/signs. In particular, sunitinib induces a decreased cardiac ejection fraction in about 20% of treated patients (1047). Furthermore, kinase inhibitors can induce QTc prolongation that should prompt careful consideration of coadministered drugs and periodic electrocardiography. Also important is that kinase inhibitor half-life is long; consequently, severe toxicities should prompt complete cessation of kinase inhibitor therapy for an adequate amount of time to allow drug levels to decline before resumption at a lower dosage.

Serum TSH level frequently increases during kinase inhibitor therapy; this should lead to frequent TSH assessment in conjunction with therapy initiation and upon therapy cessation, with responsive modifications thyroid hormone therapy where indicated.

[C45] Other novel agents

■ **RECOMMENDATION 99**

Agents without established efficacy in DTC should be used primarily within the context of therapeutic clinical trials.

(Strong recommendation, Low-quality evidence)

A variety of novel agents have been and/or are being tested as candidate therapeutics in progressive metastatic RAI-refractory DTC (1032,1048). At the time of the writing of these guidelines, however, only kinase inhibitors have shown sufficient promise to consider use other than within the context of therapeutic clinical trials. Agents of particular interest for further testing include BRAF kinase inhibitors because PTC frequently harbors the constitutively activating $BRAF^{V600E}$ mutation and the inhibitors have already shown efficacy and been approved for use in *BRAF* mutant melanoma (1049–1051). Inhibitors of MEK kinase and other signaling pathways are also of considerable investigational interest. In addition, promising initial results in response to use of kinase inhibition to ''resensitize'' RAI-refractory tumors to RAI have been reported (1052). Data developed to date, however, do not yet favor the use of these novel approaches over use of VEGFR-directed kinase inhibitors unless within the context of therapeutic clinical trials or alternatively when used as ''salvage'' therapies after disease progression has occurred despite prior VEGFR-directed kinase inhibitor therapy.

[C46] Cytotoxic chemotherapy

■ **RECOMMENDATION 100**

Cytotoxic chemotherapy can be considered in RAI-refractory DTC patients with metastatic, rapidly progressive,

Downloaded by Memorial Sloan Kettering from www.liebertpub.com at 08/14/19. For personal use only.

Table 17. Potential Toxicities and Recommended Screening or Monitoring Approaches in Patients Started on Kinase Inhibitor Therapy

Toxicity	*Recommended screening/monitoring*
Hypertension	Frequent blood pressure monitoring, most critical during the first 8 weeks of therapy; if hypertension is induced, therapy should be individualized to patient response • Note: effective and expeditious management of hypertension is critical - and may reduce potential for cardiotoxicity. If antihypertensive therapy is needed, calcium channel blockers (e.g., amlodipine) may be most effective.
Cutaneous/mucocutaneous toxicities	Careful patient reporting of rash/mouth sores, patient awareness and education related to increased potential for photosentization/sunburn.
Hepatotoxicity	Serial assessment of alanine serum transferase (AST), alkaline phosphatase and bilirubin - most critical during the first 8 weeks of therapy • Note: dose reduction of kinase inhibitor therapy is commonly required due to hepatic toxicity
Cardiotoxicity	ECG pretherapy and frequently during therapy • Hold (or do not initiate) kinase inhibitor therapy if QTc >480 ms Echocardiogram: elective, but recommended in any patient with cardiac history and especially important in patient with hypertension, symptoms consistent with congestive heart failure or coronary artery disease and in patients receiving sunitinib
Hypothyroidism	TSH should be assessed frequently, with levothyroxine dosage altered in response to rising TSH if observed
Nephrotoxicity	Serial serum creatinine, urine analysis with protein determination,
Hematological toxicities	Serial CBC/diff
Pancreatitis	Serial amylase
Teratogenicity	Pretherapy pregnancy testing and effective contraception in women and men of childbearing potential

CBC, complete blood count; ECG, electrocardiography.

Downloaded by Memorial Sloan Kettering from www.liebertpub.com at 08/14/19. For personal use only.

symptomatic, and/or imminently threatening disease not otherwise amenable to control through other approaches, including kinase inhibitors. Too few data exist to recommend specific cytotoxic regimens, and use within the context of a therapeutic clinical trial is preferred.

(Weak recommendation, Low-quality evidence)

Although doxorubicin was approved for use in thyroid cancer by the US FDA in 1974 and has some utility in anaplastic thyroid cancer, cytotoxic chemotherapy has historically produced disappointing results when used to treat RAI-refractory DTC (1038). Cytotoxic chemotherapy, however, may have selective benefit in patients unresponsive to kinase inhibitors and perhaps also in some patients with poorly differentiated thyroid cancer (1053). Data are limited and primarily anecdotal.

[C47] Bone-directed agents

■ **RECOMMENDATION 101**

Bisphosphonate or denosumab therapy should be considered in patients with diffuse and/or symptomatic bone metastases from RAI-refractory DTC, either alone or concomitantly with other systemic therapies. Adequate renal function (bisphosphonates) and calcium level (bisphosphonates and denosumab) should be documented prior to each dose, and dental evaluation should take place before initial use.

(Strong recommendation, Moderate-quality evidence)

Metastatic bone disease represents a particularly challenging clinical problem in patients with RAI-refractory DTC, especially given the high rate of multiple skeletal-related events in patients following detection of an initial bone lesion (1054). Patients with a small number of threatening and/or symptomatic bone lesions are generally best treated with focal approaches such as radiation therapy and/or surgery and/or thermoablation. Many patients, however, suffer from diffuse progression of bone metastases that are not amenable to effective control using focal therapies alone. In such patients, focal therapy to symptomatic lesions or lesions at high risk of complications may be beneficial and should be performed before initiation of systemic treatment.

Unfortunately, kinase inhibitors appear to be less effective in controlling bone metastatic disease in comparison to disease at other soft tissue sites such as lungs and lymph nodes. Progression of bone metastases while on kinase inhibitor therapy commonly occurs despite maintained benefit with respect to disease at other metastatic sites. Hence, kinase inhibitor therapy cannot be relied upon to control diffuse bone metastases in many patients with RAI-refractory DTC.

In other solid tumors, bone-directed therapeutics including bisphosphonates (especially zoledronic acid) and the RANK ligand–directed agent denosumab have been shown to delay time to occurrence of subsequent skeletal-related adverse events (fracture, pain, neurologic complications) and to improve symptoms, and these agents may provide benefits for patients

with diffuse bone metastases (1055,1056). The determination of benefits across several tumor types suggests that they may be broadly generalizable, prompting FDA approval for their general use in patients with solid tumor bone metastases. Two small studies have suggested benefit from bisphosphonates specifically within the context of DTC bone metastases (951,1057).

Risks of bisphosphonates and RANK ligand–directed agents include hypocalcemia, which can be severe, prompting the recommended concomitant use of supplemental calcium and vitamin D therapy. Moreover, these agents also moderately increase the risk of nonhealing oral lesions and jaw osteonecrosis; thus, candidates for this therapy should undergo dental/oral surgical evaluation prior to their initiation so as to minimize these risks (1055).

Recent studies have overall shown equivalence or superiority of denosumab to zoledronic acid in delaying bone-related adverse events in several solid tumors, with similar risk of jaw osteonecrosis, greater incidence of hypocalcemia, and less nephrotoxicity (1058). However, no thyroid-specific data related to the efficacy of denosumab have yet been published. If the patient's renal function is impaired, there is sometimes justification for beginning with RANK ligand–directed/denosumab therapy because this agent seems to produce fewer adverse renal effects, albeit the oral/jaw effects are similar to bisphosphonates in magnitude.

Expert consensus is that bone-directed therapy should be strongly considered in patients with multiple progressing and/or symptomatic bone metastases, likely best beginning with bisphosphonate/zoledronic acid (assuming calcium and renal function permit). Candidates for such therapy should be cleared by their dentist/oral surgeon prior to therapy initiation; in addition, calcium and vitamin D therapy should be ongoing in conjunction with any intended bone-directed therapeutic. In general, there is consensus that the administration of zoledronic acid therapy every 3 months (rather than every month) is a reasonable initial approach in terms of dosing interval, but randomized trial data are unavailable to definitively clarify this issue. Expert consensus is that bone-directed therapy should be used in the setting of diffuse bone metastases *even if kinase inhibitor therapy is intended or ongoing.*

[D1] DIRECTIONS FOR FUTURE RESEARCH

[D2] Optimizing molecular markers for diagnosis, prognosis, and therapeutic targets

Significant progress has been made over the last several years in understanding the genetic mechanisms of thyroid cancer and creating molecular tests for cancer diagnosis in thyroid nodules. This process is currently going through an accelerated phase, which is expected to continue into the future. The Cancer Genome Atlas (TCGA) and work from multiple research laboratories led to the identification of mutations and other driver genetic alterations in more than 90% of thyroid cancers, making it one of the best characterized human cancers from a genetic standpoint (1059). The TCGA focused only on PTC. Moreover, next-generation sequencing technologies may allow detection of most of these alterations in a limited cell sample obtained by FNA. Progress in identifying mutational, other genetic (gene expression, miRNA), and epigenetic markers of thyroid cancer is expected to result in a significantly improved accuracy of cancer detection in thyroid nodules as compared to the currently available clinical tests. If such progress continues, it is expected that future molecular tests will be able to predict the risk of cancer in thyroid nodules with high accuracy, dramatically reducing the uncertainty of indeterminate FNA cytology. Furthermore, as the cost of next-generation sequencing of human DNA continues to decrease and the analytical tools become more efficient, it should be expected that the cost of molecular testing will decrease, enabling cost-efficient utilization of testing.

Molecular markers are expected to have a significant impact on cancer prognostication. While the *BRAF* status can be considered as a relatively sensitive prognostic marker for papillary cancer, it cannot be used in isolation for tumor prognostication. However, recent results obtained by broad tumor genotyping show that several specific molecular signatures (such as presence of several driver mutations, *TP53* mutation, *TERT* mutation in isolation or in combination with *BRAF*) are found in a small fraction of well-differentiated papillary and follicular cancers and appear to be associated with more aggressive tumor behavior. It is expected that these molecular signatures will be confirmed and perhaps further improved in additional studies and will offer a more specific detection of well-differentiated thyroid cancers that have high risks of tumor recurrence and cancer-related mortality. Furthermore, research may identify how such data may inform therapeutic decision-making (e.g., surgical extent [if any], treatment with multi-kinase and specific kinase inhibitors or their combination). Discoveries of new gene mutations/rearrangements involved in the pathogenesis of thyroid cancer, such as those of *ALK* and *NTRK3*, are expected to offer new effective therapeutic targets. Finally, new therapeutic approaches to target genes commonly mutated in thyroid cancer, such as the *RAS* genes, are in development and expected to enter clinical trials in the future. Prospective long-term outcome studies, ideally in the form of RCTs, will be needed to define the optimal surgical and postsurgical management of patients based on these molecular signatures. Such research may enable personalized, evidence-based care of patients with thyroid cancer across the disease trajectory.

[D3] Active surveillance of DTC primary tumors

Our Japanese colleagues have provided compelling data that an active surveillance management approach to papillary microcarcinoma is a safe and effective alternative to immediate surgical resection in properly selected patients (143,149).

Unfortunately, no clinical features or molecular abnormality in isolation can reliably differentiate the relatively small number of PTMC patients destined to develop clinically significant progression from the larger population of people that harbor indolent PTMCs that will not cause significant disease. Therefore, additional studies are needed to identify specific risk factors that would favor surgical resection over active surveillance.

Furthermore, additional studies are needed to define important management issues that arise during an active surveillance follow-up approach. These issues include the frequency of US evaluations required during follow-up, optimal TSH goals, the potential role of serum Tg in follow-up, and specific indications for surgical intervention (e.g., what measurements should be used to define a clinically significant

Downloaded by Memorial Sloan Kettering from www.liebertpub.com at 08/14/19. For personal use only.

increase in the size of the primary tumor, what constitutes clinically significant lymph node metastases).

Finally, studies that examine decision-making and acceptability of an active surveillance approach to thyroid cancer in patients, family members, and clinicians are required to better understand how to implement this novel management approach outside of Japan. These studies should ideally be performed in the context of an Institutional Review Board–approved clinical trial.

[D4] Improved risk stratification

While the AJCC/UICC TNM staging provides valuable information with regard to disease-specific mortality, studies are needed to determine if inclusion of additional prognostic variables into the AJCC staging system could improve its predictive ability. Potential variables for consideration include the specific histology (well-differentiated thyroid cancer versus poorly differentiated thyroid cancer), molecular profile, size and location of distant metastases (pulmonary metastases versus bone metastases versus brain metastases), functional status of the metastases (RAI avid versus ^{18}FDG-PET avid), and effectiveness of initial therapy (completeness of resection; effectiveness of RAI, external beam radiation, or other systemic therapies).

Furthermore, additional studies will be required to determine if there is any significant incremental benefit of adding these specific prognostic variables to the 2009 Initial Risk Stratification system.

Since the response to therapy dynamic (ongoing) risk stratification systems were primarily optimized and validated on DTC patients that had total thyroidectomy and RAI remnant ablation or adjuvant therapy, additional studies are needed to refine the definitions of excellent, biochemical incomplete, structural incomplete, and indeterminate responses in patients treated with total thyroidectomy without RAI ablation and in patients treated with less than total thyroidectomy (602). Furthermore, additional studies are needed to define what types of cross-sectional/functional imaging are required to rule out structural disease in order to classify a patient as having a biochemical incomplete response to therapy (based on initial risk, serum Tg, signs/symptoms, or other imaging results).

Another area of significant research interest centers on identifying specific clinical situations in which the molecular findings provide clinically meaningful information that goes beyond what is predicted by standard clinico-pathological staging. Molecular findings that provide these types of prognostic information or guide optimal initial/ongoing treatment decisions have the potential to significantly alter clinical management.

[D5] Improving our understanding of the risks and benefits of DTC treatments and optimal implementation/utilization

In achieving a better understanding of the risks and benefits of DTC treatments (such as extent of primary surgery or secondary surgery for recurrence, RAI ablation/treatment, and thyroid hormone suppressive therapy), more prospective long-term outcome research is needed, and in particular, RCTs. In the case of relatively uncommon adverse effects of treatments, prospective surveillance research is also needed. Vaisman and colleagues (633) are conducting a prospective, nonrandomized study to determine which patients with low- to intermediate-risk DTC should receive RAI remnant ablation based on the postoperative stimulated serum Tg level. Longer-term follow-up and randomized multicenter studies are needed to determine how this commonly used biomarker can be applied to decision-making in a majority of patients with low- to intermediate-risk DTC. Prospective collection of data on quality of life and related outcomes (when relevant) is also needed in DTC trials. Using an evidence-based approach to knowledge synthesis (systematic reviews, meta-analyses, and clinical practice guidelines) of data can also enable evidence-informed clinical practice. Barriers to dissemination and implementation of clinical practice guideline recommendations need to be overcome. Evidence-based guidelines may need to be formally adapted to various practice settings to enable their implementation. Important gaps in patient-directed knowledge translation have been recently identified by thyroid cancer patients and survivors (1060,1061). The development of plain language educational materials, including decision aids or other decision support tools would be helpful for use as adjuncts in physician counseling of patients about diagnostic and treatment options. Decision aids and other decision support have been associated with improvement in patients' medical knowledge and reducing decisional conflict, in general oncology (1062,1063), with a recent RCT demonstrating benefits of a decision aid in thyroid cancer survivors considering RAI remnant ablation (1064).

[D6] Issues with measurement of Tg and anti-Tg antibodies

Current methodologies for both Tg and anti-Tg antibodies remain problematic in many ways that hopefully will be overcome in the future. For Tg assays, these include interference with Tg measurement by the presence of anti-Tg and heterophile antibodies and the use of a host of different methods with varying results in terms of sensitivity or detection limits. Assay calibration or standardization may be successful only if the same certified reference standard is employed, which currently is CRM-457. While more ''ultrasensitive'' Tg assays have been developed, we need to determine the true clinical significance or utility of measurable levels below 0.2 ng/mL (either on suppression or after TSH stimulation) as indicating evidence of residual disease or outcome. Recently developed mass spectrometry–based assays have offered some promise, but are yet to be validated (806). Competitive immunoassays have not provided an alternative in view of their unpredictability (771). In regard to anti-Tg antibodies, we need to better characterize the various epitopes of interfering antibodies to better understand their effect in different sera in order to interpret the associated spectrum of results obtained for measurable Tg. We will need to do better than approximating Tg levels by the ratio of ICMA Tg to Tg measured by competitive immunoassay (1065). Authoritative bodies such as the National Academy of Clinical Biochemistry should consider mandating specific methodology rather than recommending general guidance. It remains to be seen whether the future standard might entail adoption of a modified ICMA, radioimmunoassay, or mass spectrometry methodology.

[D7] Management of metastatic cervical adenopathy detected on US

With the advent of improved technology, increased utilization, and specialized operator experience, US imaging can identify small-volume metastatic cervical lymph nodes. From the surgical pathology literature analyzing specimens

Downloaded by Memorial Sloan Kettering from www.liebertpub.com at 08/14/19. For personal use only.

Downloaded by Memorial Sloan Kettering from www.liebertpub.com at 08/14/19. For personal use only.

from prophylactic lateral and central neck dissections with normal preoperative cervical lymph node sonography, up to 90% of patients with papillary cancers <1 cm have metastatic level VI lymph nodes and up to 40% have metastatic lateral neck lymph nodes (359,1066,1067). Yet, in the absence of these dissections, this is not the observed clinical loco-regional recurrence rate for these patients. It should not be surprising then, that during extended surveillance, US will be able to detect small-volume metastatic disease that may represent a stable reservoir of residual cancer. On the other hand, grossly involved metastatic lymph nodes were at one time minimally invaded by metastatic thyroid cancer. The challenge is to differentiate between low-volume metastatic disease that progresses with potential clinical consequences, and that which remains stable. To date, only one study has addressed this question, and no sonographic, pathologic, demographic, or molecular feature predicted outcome (849). In addition, it is unclear if growth itself is a harbinger of decreased survival. Therefore, observational studies using standardized US scanning protocols are first required to define the magnitude of this scenario and define predictors of disease progression. Subsequently, randomized controlled interventional trials could be designed to address change in outcome, such as development of additional loco-regional disease, appearance of distant metastases, or disease-specific survival.

[D8] Novel therapies for systemic RAI-refractory disease

Over the years, a wide variety of agents have been used in preclinical (valproic acid, trichostatin, depsipeptide, 5-azacytidine, arsenic tri-oxide) and clinical (retinoids, thiazolidinediones) models to ''redifferentiate'' thyroid cancer cells in order to restore RAI avidity. While these agents showed limited clinical effectiveness, the observation that oncogenic activation of the MAP kinase pathway was associated with down-regulation of the genes involved in iodine metabolism suggested an alternative, targeted approach to redifferentiation therapy. Recently, two proof-of-principle pilot clinical trials have confirmed that targeted blockade of the MAP kinase pathway can result in clinically relevant restoration of RAI avidity in a substantial percentage of RAI-refractory thyroid cancer patients (1052,1068). In the first trial, 1 month of the MEK inhibitor selumetinib increased RAI uptake in 12 of 20 iodine-refractory thyroid cancer patients, with structural tumor shrinkage seen in five of the eight patients that achieved lesional dosimetry high enough to warrant RAI therapy (1052). In the second trial, 1 month of the BRAF inhibitor dabrabenib restored RAI avidity on diagnostic WBS in 6 of 10 RAI-refractory patients, resulting in structural responses in two patients and a decrease in serum Tg in four patients (1068). While the primary focus of current redifferentiation trials has been in the setting of RAI-refractory distant metastases, future studies are needed to define the role of redifferentiation therapy in the high-risk adjuvant therapy setting and in the RAI-responsive metastatic disease setting in an effort to enhance the tumoricidal effect of RAI before the tumors become RAI refractory.

Efforts to develop additional and further improved systemic therapeutic approaches to RAI-refractory metastatic DTC presently involve a wide a variety of approaches. First, the question arises as to whether kinase inhibitors with already demonstrated clinical activity in DTC can be made more effective as single agents. For example, based upon data indicating strong correlation between achieved pazopanib levels and extent of clinical response in DTC, indicating absence of response to pazopanib therapy in the lowest quintile of pazopanib drug levels, one clinical trial is presently examining the feasibility and potential benefits of individualization of pazopanib therapy with the goal of achieving target drug levels in the highest achievable fraction of patients, in hopes of improving the fraction of patients benefiting (NCT01552356). Another study is examining the differential impacts of continuous versus intermittent pazopanib dosing in thyroid cancer (NCT01813136).

Generally predicated upon identification of synergistic interactions in preclinical models, several studies are examining the question of whether therapy combining several agents may improve outcomes in thyroid cancer. Although the majority of combinatorial studies assess effects of multiple coadministered small molecule therapeutics, several are using kinase inhibitors in combination with RAI in efforts to enhance RAI avidity and clinical efficacy in the context of RAI-refractory disease (e.g., NCT00970359). Still other trials are focusing on novel nontraditional therapies, including engineered candidate virotherapeutics (e.g., NCT01229865).

Alternatively, another active area of investigation involves efforts to therapeutically target specific alterations (mutations, translocation) found in thyroid cancers to individualize therapy and thereby potentially improve outcomes in the process; one such recent example is the use of the $BRAF^{V600E}$ inhibitor vemurafenib in $BRAF^{V600E}$ PTC (NCT01286753), with many additional mutation-specific therapeutic trials under development or underway.

Finally, immunotherapy including checkpoint inhibitors (e.g., PD-1/PD-L1) has shown promise in other cancers (1069–1071) and is being investigated in advanced RAI-refractory thyroid cancer.

[D9] Survivorship care

The American Cancer Society estimates that there will be 62,450 new cases of thyroid cancer diagnosed in 2015, but only 1950 deaths from thyroid cancer (www.cancer.org/cancer/thyroidcancer/detailedguide/thyroid-cancer-key-statistics). According to SEER database statistics, there are more than 600,000 people living with thyroid cancer in the United States alone (seer.cancer.gov/statfacts/html/thyro.html). Despite these large numbers of patients living with thyroid cancer, there is only a modest amount of peer-reviewed literature studying thyroid cancer survivors.

The majority of the literature involving thyroid cancer survivors relates directly to the short- and long-term effects of thyroid cancer therapies: surgery, RAI, and lifetime thyroid hormone therapy. There is very little information regarding the impact of the diagnosis itself or the effect of living with persistent disease such as Tg-positive, scan-negative thyroid cancer. A thoughtful and comprehensive analysis of thyroid cancer survivors will likely require both qualitative studies with in-depth interviews of survivors that will represent as many demographics of thyroid cancer patients as possible. Additionally, or as a next step, the development and/or utilization of a validated survey type instrument needs to be developed. This instrument would be designed to assess the quality of life of thyroid cancer survivors in a more quantitative manner, allowing for rigorous statistical analyses, and will help identifying areas to target that may improve the lives of thyroid cancer survivors (1072).

Further research also needs to be performed in addressing patient and survivor care needs throughout the active treatment and survivorship trajectory, including issues such as identification and management of treatment-related side effects (1060,1061), psychosocial distress (1060,1061), persistent fatigue (1073,1074), financial impact (12), and cancer-related worry (1075).

ACKNOWLEDGMENTS

The task force wishes to thank Ms. Bobbi Smith, Executive Director, ATA, and Ms. Sharleene Cano, Assistant to the Taskforce, for their constant help and support, as well as Ms. Vicki Wright (Division of Endocrinology, University of Colorado School of Medicine) for her assistance in manuscript preparation. We thank Dr. Joshua Klopper (Division of Endocrinology, University of Colorado School of Medicine) on behalf of the CAC Quality Of Life Task Force for the contribution of the Survivorship Care section [D9]. We also thank Dr. Irwin Klein (North Shore University Hospital, Manhasset, New York) for his input on TSH targets for long-term thyroid hormone therapy (Table 15). We would like to thank the ATA members who responded to our survey in preparation for this iteration of the guidelines as well as manuscript review prior to journal submission, and the leadership of ThyCa: Thyroid Cancer Survivors' Association, Inc. and Thyroid Cancer Canada who provided written feedback on our survey. A.M.S. holds a Cancer Care Ontario Health Services Research Chair, which enabled protected time for research and contribution to these guidelines. These guidelines were funded by the ATA without support from any commercial sources. The patient organization, ThyCa: Thyroid Cancer Survivors' Association, Inc., contributed an unrestricted educational grant toward the development of the thyroid nodules and differentiated thyroid cancer guidelines.

The following groups reviewed and endorsed the final document: American Association of Clinical Endocrinologists; American Association of Endocrine Surgeons; American Head and Neck Society; Asia Oceania Thyroid Association (AOTA); British Society of Nuclear Medicine; Canadian Association of Otolaryngology Head and Neck Surgery; The Endocrine Society; Endocrine Society of Australia; European Thyroid Association; International Association of Endocrine Surgeons; International Federation of Head and Neck Oncologic Societie; Japanese Thyroid Association; Latin American Thyroid Society; Society of Surgical Oncology; Ukrainian Association of Endocrine Surgeons.

DISCLAIMER

It is our goal in formulating these guidelines, and the ATA's goal in providing support for the development of these guidelines, that they assist in the clinical care of patients and share what we believe is current, rational, and optimal medical practice. In some circumstances, it may be apparent that the level of care recommended may be best provided in limited centers with specific expertise. Finally, it is not the intent of these guidelines to replace individual decision-making, the wishes of the patient or family, or clinical judgment.

AUTHOR DISCLOSURE STATEMENT

These guidelines were funded by the ATA without support from any commercial sources.

K.C.B., G.M.D., F.P., G.A.R., A.M.S., and K.S. have no significant financial or competing interests to disclose.

B.R.H. has received grant/research support from Veracyte and Genzyme, as well as a one-time speaker honorarium from Genzyme. E.K.A. has received research support from Asuragen, Veracyte, and Novo Nordisk. He has been a consultant for NPS Pharmaceuticals, Genzyme, and Veracyte as well as on the Scientific Advisory Board for Asuragen. S.J.M. has received grant/research support from Veracyte and Asuragen. She has been on the scientific advisory committee for Asuragen and has been a CME speaker for Genzyme. Y.N. has been a consultant for Quest Diagnostics. His institution, UPMC, has a service agreement with CBLPath to provide molecular testing for various tumors. M.S. has received grant/research support from Genzyme, Bayer, AstraZeneca, Exelixis, and Eisai. He has been a consultant for Genzyme, Bayer, AstraZeneca, Exelixis, and Eisai. S.I.S. has received grant/research support from Genzyme and the National Cancer Institute. He is a consultant for Veracyte, Exelixis, Bayer, AstraZeneca, Eisai, Genzyme, Novo Nordisk, and Eli Lilly. He has received honoraria from Onyx, and he has fiduciary responsibility as Chairman of International Thyroid Oncology Group. J.A.S. has received one-time speaker honorarium from Exelixis and is a member/ATA representative on the Data Monitoring Committee for the Medullary Thyroid Cancer Registry called for by the FDA and funded by NovoNordisk, Astra Zeneca, GlaxoSmithKline, and Eli Lilly. D.L.S. has received grant/research support from Astra-Zeneca. R.M.T. is a consultant for Genzyme, Novo Nordisk, AstraZeneca, Bayer/Onyx, and Veracyte. L.W. has been a consultant for Asuragen, Interpace Diagnostics, Eisei, and IBSA. He has received speaker honoraria from Genzyme.

E.K.A. and R.M.T. received consulting payments through stock options from Veracyte. This has been reviewed and discussed with the Ethics Committee and reviewed by the ATA Board. E.K.A. and R.M.T. were recused from review and approval of the molecular markers sections. They divested these stock options prior to submission of this document for journal review.

REFERENCES

1. Vander JB, Gaston EA, Dawber TR 1968 The significance of nontoxic thyroid nodules. Final report of a 15-year study of the incidence of thyroid malignancy. Ann Intern Med **69:**537–540.
2. Tunbridge WM, Evered DC, Hall R, Appleton D, Brewis M, Clark F, Evans JG, Young E, Bird T, Smith PA 1977 The spectrum of thyroid disease in a community: the Whickham survey. Clin Endocrinol (Oxf) **7:**481–493.
3. Tan GH, Gharib H 1997 Thyroid incidentalomas: management approaches to nonpalpable nodules discovered incidentally on thyroid imaging. Ann Intern Med **126:** 226–231.
4. Guth S, Theune U, Aberle J, Galach A, Bamberger CM 2009 Very high prevalence of thyroid nodules detected by high frequency (13 MHz) ultrasound examination. Eur J Clin Invest **39:**699–706.
5. Hegedus L 2004 Clinical practice. The thyroid nodule. N Engl J Med **351:**1764–1771.
6. Mandel SJ 2004 A 64-year-old woman with a thyroid nodule. JAMA **292:**2632–2642.
7. Sherman SI 2003 Thyroid carcinoma. Lancet **361:**501–511.

Downloaded by Memorial Sloan Kettering from www.liebertpub.com at 08/14/19. For personal use only.

8. Siegel R, Ma J, Zou Z, Jemal A 2014 Cancer statistics, 2014. CA Cancer J Clin **64:**9–29.
9. Davies L, Welch HG 2014 Current thyroid cancer trends in the United States. JAMA Otolaryngol Head Neck Surg **140:**317–322.
10. Leenhardt L, Bernier MO, Boin-Pineau MH, Conte DB, Maréchaud R, Niccoli-Sire P, Nocaudie M, Orgiazzi J, Schlumberger M, Wémeau JL, Cherie-Challine L, De Vathaire F 2004 Advances in diagnostic practices affect thyroid cancer incidence in France. Eur J Endocrinol **150:**133–139.
11. Brito JP, Al Nofal A, Montori V, Hay ID, Morris JC III 2015 The impact of subclinical disease and mechanism of detection on the rise in thyroid cancer incidence: a population-based study in Olmsted County, Minnesota during 1935 through 2012. Thyroid **25:**999–1007.
12. Aschebrook-Kilfoy B, Schechter RB, Shih YC, Kaplan EL, Chiu BC, Angelos P, Grogan RH 2013 The clinical and economic burden of a sustained increase in thyroid cancer incidence. Cancer Epidemiol Biomarkers Prev **22:**1252–1259.
13. Singer PA, Cooper DS, Daniels GH, Ladenson PW, Greenspan FS, Levy EG, Braverman LE, Clark OH, McDougall IR, Ain KV, Dorfman SG 1996 Treatment guidelines for patients with thyroid nodules and well-differentiated thyroid cancer. American Thyroid Association. Arch Intern Med **156:**2165–2172.
14. Francis GL, Waguespack SG, Bauer AJ, Angelos P, Benvenga S, Cerutti JM, Dinauer CA, Hamilton J, Hay ID, Luster M, Parisi MT, Rachmiel M, Thompson GB, Yamashita S 2015 Management guidelines for children with thyroid nodules and differentiated thyroid cancer. Thyroid **25:**716–759.
15. Lewis MH, Gohagan JK, Merenstein DJ 2007 The locality rule and the physician's dilemma: local medical practices vs the national standard of care. JAMA **297:**2633–2637.
16. Harrison MB, Graham ID, van den Hoek J, Dogherty EJ, Carley ME, Angus V 2013 Guideline adaptation and implementation planning: a prospective observational study. Implement Sci **8:**49–63.
17. Carlson RW, Larsen JK, McClure J, Fitzgerald CL, Venook AP, Benson AB III, Anderson BO 2014 International adaptations of NCCN Clinical Practice Guidelines in Oncology. J Natl Compr Canc Netw **12:**643–648.
18. Gharib H, Papini E, Paschke R, Duick DS, Valcavi R, Hegedus L, Vitti P 2010 American Association of Clinical Endocrinologists, Associazione Medici Endocrinologi, and European Thyroid Association Medical guidelines for clinical practice for the diagnosis and management of thyroid nodules: executive summary of recommendations. Endocr Pract **16:**468–475.
19. Perros P, Boelaert K, Colley S, Evans C, Evans RM, Gerrard BG, Gilbert J, Harrison B, Johnson SJ, Giles TE, Moss L, Lewington V, Newbold K, Taylor J, Thakker RV, Watkinson J, Williams GR 2014 Guidelines for the management of thyroid cancer. Clin Endocrinol (Oxf) **81 Suppl 1:**1–122.
20. Leenhardt L, Erdogan MF, Hegedus L, Mandel SJ, Paschke R, Rago T, Russ G 2013 2013 European Thyroid Association guidelines for cervical ultrasound scan and ultrasound-guided techniques in the postoperative management of patients with thyroid cancer. Eur Thyroid J **2:**147–159.
21. Silberstein EB, Alavi A, Balon HR, Clarke SE, Divgi C, Gelfand MJ, Goldsmith SJ, Jadvar H, Marcus CS, Martin WH, Parker JA, Royal HD, Sarkar SD, Stabin M, Waxman AD 2012 The SNMMI practice guideline for therapy of thyroid disease with 131I 3.0. J Nucl Med **53:**1633–1651.
22. Luster M, Clarke SE, Dietlein M, Lassmann M, Lind P, Oyen WJ, Tennvall J, Bombardieri E 2008 Guidelines for radioiodine therapy of differentiated thyroid cancer. Eur J Nucl Med Mol Imaging **35:**1941–1959.
23. Takami H, Ito Y, Okamoto T, Onoda N, Noguchi H, Yoshida A 2014 Revisiting the guidelines issued by the Japanese Society of Thyroid Surgeons and Japan Association of Endocrine Surgeons: a gradual move towards consensus between Japanese and Western practice in the management of thyroid carcinoma. World J Surg **38:**2002–2010.
24. Cooper DS, Doherty GM, Haugen BR, Kloos RT, Lee SL, Mandel SJ, Mazzaferri EL, McIver B, Sherman SI, Tuttle RM 2006 Management guidelines for patients with thyroid nodules and differentiated thyroid cancer. Thyroid **16:**109–142.
25. Cooper DS, Doherty GM, Haugen BR, Kloos RT, Lee SL, Mandel SJ, Mazzaferri EL, McIver B, Pacini F, Schlumberger M, Sherman SI, Steward DL, Tuttle RM 2009 Revised American Thyroid Association management guidelines for patients with thyroid nodules and differentiated thyroid cancer. Thyroid **19:**1167–1214.
26. Qaseem A, Snow V, Owens DK, Shekelle P 2010 The development of clinical practice guidelines and guidance statements of the American College of Physicians: summary of methods. Ann Intern Med **153:**194–199.
27. Schunemann HJ, Oxman AD, Brozek J, Glasziou P, Jaeschke R, Vist GE, Williams JW Jr, Kunz R, Craig J, Montori VM, Bossuyt P, Guyatt GH 2008 Grading quality of evidence and strength of recommendations for diagnostic tests and strategies. BMJ **336:**1106–1110.
28. Brozek JL, Akl EA, Jaeschke R, Lang DM, Bossuyt P, Glasziou P, Helfand M, Ueffing E, Alonso-Coello P, Meerpohl J, Phillips B, Horvath AR, Bousquet J, Guyatt GH, Schunemann HJ 2009 Grading quality of evidence and strength of recommendations in clinical practice guidelines: part 2 of 3. The GRADE approach to grading quality of evidence about diagnostic tests and strategies. Allergy **64:**1109–1116.
29. Bossuyt PM, Reitsma JB, Bruns DE, Gatsonis CA, Glasziou PP, Irwig LM, Lijmer JG, Moher D, Rennie D, de Vet HC 2003 Towards complete and accurate reporting of studies of diagnostic accuracy: the STARD Initiative. Ann Intern Med **138:**40–44.
30. Leung AN, Bull TM, Jaeschke R, Lockwood CJ, Boiselle PM, Hurwitz LM, James AH, McCullough LB, Menda Y, Paidas MJ, Royal HD, Tapson VF, Winer-Muram HT, Chervenak FA, Cody DD, McNitt-Gray MF, Stave CD, Tuttle BD 2011 An official American Thoracic Society/Society of Thoracic Radiology clinical practice guideline: evaluation of suspected pulmonary embolism in pregnancy. Am J Respir Crit Care Med **184:**1200–1208.
31. Whiting PF, Rutjes AW, Westwood ME, Mallett S, Deeks JJ, Reitsma JB, Leeflang MM, Sterne JA, Bossuyt PM 2011 QUADAS-2: a revised tool for the quality assessment of diagnostic accuracy studies. Ann Intern Med **155:**529–536.

Downloaded by Memorial Sloan Kettering from www.liebertpub.com at 08/14/19. For personal use only.

32. Marqusee E, Benson CB, Frates MC, Doubilet PM, Larsen PR, Cibas ES, Mandel SJ 2000 Usefulness of ultrasonography in the management of nodular thyroid disease. Ann Intern Med **133:**696–700.
33. Hagag P, Strauss S, Weiss M 1998 Role of ultrasound-guided fine-needle aspiration biopsy in evaluation of nonpalpable thyroid nodules. Thyroid **8:**989–995.
34. Charkes ND 2006 On the prevalence of familial non-medullary thyroid cancer in multiply affected kindreds. Thyroid **16:**181–186.
35. Capezzone M, Marchisotta S, Cantara S, Busonero G, Brilli L, Pazaitou-Panayiotou K, Carli AF, Caruso G, Toti P, Capitani S, Pammolli A, Pacini F 2008 Familial non-medullary thyroid carcinoma displays the features of clinical anticipation suggestive of a distinct biological entity. Endocr Relat Cancer **15:**1075–1081.
36. Moses W, Weng J, Kebebew E 2011 Prevalence, clinicopathologic features, and somatic genetic mutation profile in familial versus sporadic nonmedullary thyroid cancer. Thyroid **21:**367–371.
37. Ito Y, Kakudo K, Hirokawa M, Fukushima M, Yabuta T, Tomoda C, Inoue H, Kihara M, Higashiyama T, Uruno T, Takamura Y, Miya A, Kobayashi K, Matsuzuka F, Miyauchi A 2009 Biological behavior and prognosis of familial papillary thyroid carcinoma. Surgery **145:**100–105.
38. Park YJ, Ahn HY, Choi HS, Kim KW, Park do J, Cho BY 2012 The long-term outcomes of the second generation of familial nonmedullary thyroid carcinoma are more aggressive than sporadic cases. Thyroid **22:**356–362.
39. Mazeh H, Benavidez J, Poehls JL, Youngwirth L, Chen H, Sippel RS 2012 In patients with thyroid cancer of follicular cell origin, a family history of nonmedullary thyroid cancer in one first-degree relative is associated with more aggressive disease. Thyroid **22:**3–8.
40. Robenshtok E, Tzvetov G, Grozinsky-Glasberg S, Shraga-Slutzky I, Weinstein R, Lazar L, Serov S, Singer J, Hirsch D, Shimon I, Benbassat C 2011 Clinical characteristics and outcome of familial nonmedullary thyroid cancer: a retrospective controlled study. Thyroid **21:**43–48.
41. Richards ML 2010 Familial syndromes associated with thyroid cancer in the era of personalized medicine. Thyroid **20:**707–713.
42. Curtis RE, Rowlings PA, Deeg HJ, Shriner DA, Socie G, Travis LB, Horowitz MM, Witherspoon RP, Hoover RN, Sobocinski KA, Fraumeni JF Jr, Boice JD Jr 1997 Solid cancers after bone marrow transplantation. N Engl J Med **336:**897–904.
43. Pacini F, Vorontsova T, Demidchik EP, Molinaro E, Agate L, Romei C, Shavrova E, Cherstvoy ED, Ivashkevitch Y, Kuchinskaya E, Schlumberger M, Ronga G, Filesi M, Pinchera A 1997 Post-Chernobyl thyroid carcinoma in Belarus children and adolescents: comparison with naturally occurring thyroid carcinoma in Italy and France. J Clin Endocrinol Metab **82:**3563–3569.
44. Gharib H, Papini E 2007 Thyroid nodules: clinical importance, assessment, and treatment. Endocrinol Metab Clin North Am **36:**707–35, vi.
45. Boelaert K, Horacek J, Holder RL, Watkinson JC, Sheppard MC, Franklyn JA 2006 Serum thyrotropin concentration as a novel predictor of malignancy in thyroid nodules investigated by fine-needle aspiration. J Clin Endocrinol Metab **91:**4295–4301.
46. Haymart MR, Repplinger DJ, Leverson GE, Elson DF, Sippel RS, Jaume JC, Chen H 2008 Higher serum thyroid stimulating hormone level in thyroid nodule patients is associated with greater risks of differentiated thyroid cancer and advanced tumor stage. J Clin Endocrinol Metab **93:**809–814.
47. Repplinger D, Bargren A, Zhang YW, Adler JT, Haymart M, Chen H 2008 Is Hashimoto's thyroiditis a risk factor for papillary thyroid cancer? J Surg Res **150:**49–52.
48. Suh I, Vriens MR, Guerrero MA, Griffin A, Shen WT, Duh QY, Clark OH, Kebebew E 2010 Serum thyroglobulin is a poor diagnostic biomarker of malignancy in follicular and Hürthle-cell neoplasms of the thyroid. Am J Surg **200:**41–46.
49. Lee EK, Chung KW, Min HS, Kim TS, Kim TH, Ryu JS, Jung YS, Kim SK, Lee YJ 2012 Preoperative serum thyroglobulin as a useful predictive marker to differentiate follicular thyroid cancer from benign nodules in indeterminate nodules. J Korean Med Sci **27:**1014–1018.
50. Elisei R, Bottici V, Luchetti F, Di Coscio G, Romei C, Grasso L, Miccoli P, Iacconi P, Basolo F, Pinchera A, Pacini F 2004 Impact of routine measurement of serum calcitonin on the diagnosis and outcome of medullary thyroid cancer: experience in 10,864 patients with nodular thyroid disorders. J Clin Endocrinol Metab **89:**163–168.
51. Hahm JR, Lee MS, Min YK, Lee MK, Kim KW, Nam SJ, Yang JH, Chung JH 2001 Routine measurement of serum calcitonin is useful for early detection of medullary thyroid carcinoma in patients with nodular thyroid diseases. Thyroid **11:**73–80.
52. Niccoli P, Wion-Barbot N, Caron P, Henry JF, de Micco C, Saint Andre JP, Bigorgne JC, Modigliani E, Conte-Devolx B 1997 Interest of routine measurement of serum calcitonin: study in a large series of thyroidectomized patients. The French Medullary Study Group. J Clin Endocrinol Metab **82:**338–341.
53. Costante G, Meringolo D, Durante C, Bianchi D, Nocera M, Tumino S, Crocetti U, Attard M, Maranghi M, Torlontano M, Filetti S 2007 Predictive value of serum calcitonin levels for preoperative diagnosis of medullary thyroid carcinoma in a cohort of 5817 consecutive patients with thyroid nodules. J Clin Endocrinol Metab **92:**450–455.
54. Chambon G, Alovisetti C, Idoux-Louche C, Reynaud C, Rodier M, Guedj AM, Chapuis H, Lallemant JG, Lallemant B 2011 The use of preoperative routine measurement of basal serum thyrocalcitonin in candidates for thyroidectomy due to nodular thyroid disorders: results from 2733 consecutive patients. J Clin Endocrinol Metab **96:**75–81.
55. Colombo C, Verga U, Mian C, Ferrero S, Perrino M, Vicentini L, Dazzi D, Opocher G, Pelizzo MR, Beck-Peccoz P, Fugazzola L 2012 Comparison of calcium and pentagastrin tests for the diagnosis and follow-up of medullary thyroid cancer. J Clin Endocrinol Metab **97:** 905–913.
56. Karga H, Giagourta I, Papaioannou G, Doumouchtsis K, Polymeris A, Thanou S, Papamichael K, Zerva C 2011 Changes in risk factors and Tumor Node Metastasis stage of sporadic medullary thyroid carcinoma over 41 years, before and after the routine measurements of serum calcitonin. Metabolism **60:**604–608.
57. Cheung K, Roman SA, Wang TS, Walker HD, Sosa JA 2008 Calcitonin measurement in the evaluation of thyroid nodules in the United States: a cost-effectiveness and decision analysis. J Clin Endocrinol Metab **93:** 2173–2180.

Downloaded by Memorial Sloan Kettering from www.liebertpub.com at 08/14/19. For personal use only.

58. Gagel RF, Hoff AO, Cote GE 2005 Medullary thyroid carcinoma. In: Braverman L, Utiger R (eds) Werner and Ingbar's The Thyroid. Lippincott Williams and Wilkins, Philadelphia, PA, pp 967–988.
59. Diazzi C, Madeo B, Taliani E, Zirilli L, Romano S, Granata AR, De Santis MC, Simoni M, Cioni K, Carani C, Rochira V 2013 The diagnostic value of calcitonin measurement in wash-out fluid from fine-needle aspiration of thyroid nodules in the diagnosis of medullary thyroid cancer. Endocr Pract **19:**769–779.
60. Soelberg KK, Bonnema SJ, Brix TH, Hegedus L 2012 Risk of malignancy in thyroid incidentalomas detected by 18F-fluorodeoxyglucose positron emission tomography: a systematic review. Thyroid **22:**918–925.
61. Chen W, Parsons M, Torigian DA, Zhuang H, Alavi A 2009 Evaluation of thyroid FDG uptake incidentally identified on FDG-PET/CT imaging. Nucl Med Commun **30:**240–244.
62. Nishimori H, Tabah R, Hickeson M, How J 2011 Incidental thyroid ''PETomas'': clinical significance and novel description of the self-resolving variant of focal FDG-PET thyroid uptake. Can J Surg **54:**83–88.
63. Hall TL, Layfield LJ, Philippe A, Rosenthal DL 1989 Sources of diagnostic error in fine needle aspiration of the thyroid. Cancer **63:**718–725.
64. Alexander EK, Heering JP, Benson CB, Frates MC, Doubilet PM, Cibas ES, Marqusee E 2002 Assessment of nondiagnostic ultrasound-guided fine needle aspirations of thyroid nodules. J Clin Endocrinol Metab **87:** 4924–4927.
65. Smith-Bindman R, Lebda P, Feldstein VA, Sellami D, Goldstein RB, Brasic N, Jin C, Kornak J 2013 Risk of thyroid cancer based on thyroid ultrasound imaging characteristics: results of a population-based study. JAMA Intern Med **173:**1788–1796.
66. Brito JP, Gionfriddo MR, Al NA, Boehmer KR, Leppin AL, Reading C, Callstrom M, Elraiyah TA, Prokop LJ, Stan MN, Murad MH, Morris JC, Montori VM 2014 The accuracy of thyroid nodule ultrasound to predict thyroid cancer: systematic review and meta-analysis. J Clin Endocrinol Metab **99:**1253–1263.
67. Langer JE, Agarwal R, Zhuang H, Huang SS, Mandel SJ 2011 Correlation of findings from iodine 123 scan and ultrasonography in the recommendation for thyroid fine-needle aspiration biopsy. Endocr Pract **17:**699–706.
68. Danese D, Sciacchitano S, Farsetti A, Andreoli M, Pontecorvi A 1998 Diagnostic accuracy of conventional versus sonography-guided fine-needle aspiration biopsy of thyroid nodules. Thyroid **8:**15–21.
69. Carmeci C, Jeffrey RB, McDougall IR, Nowels KW, Weigel RJ 1998 Ultrasound-guided fine-needle aspiration biopsy of thyroid masses. Thyroid **8:**283–289.
70. Kwak JY, Han KH, Yoon JH, Moon HJ, Son EJ, Park SH, Jung HK, Choi JS, Kim BM, Kim EK 2011 Thyroid imaging reporting and data system for US features of nodules: a step in establishing better stratification of cancer risk. Radiology **260:**892–899.
71. Moon WJ, Jung SL, Lee JH, Na DG, Baek JH, Lee YH, Kim J, Kim HS, Byun JS, Lee DH 2008 Benign and malignant thyroid nodules: US differentiation—multicenter retrospective study. Radiology **247:**762–770.
72. Moon HJ, Kwak JY, Kim MJ, Son EJ, Kim EK 2010 Can vascularity at power Doppler US help predict thyroid malignancy? Radiology **255:**260–269.
73. Salmaslioglu A, Erbil Y, Dural C, Issever H, Kapran Y, Ozarmagan S, Tezelman S 2008 Predictive value of sonographic features in preoperative evaluation of malignant thyroid nodules in a multinodular goiter. World J Surg **32:**1948–1954.
74. Papini E, Guglielmi R, Bianchini A, Crescenzi A, Taccogna S, Nardi F, Panunzi C, Rinaldi R, Toscano V, Pacella CM 2002 Risk of malignancy in nonpalpable thyroid nodules: predictive value of ultrasound and color-Doppler features. J Clin Endocrinol Metab **87:**1941–1946.
75. Gul K, Ersoy R, Dirikoc A, Korukluoglu B, Ersoy PE, Aydin R, Ugras SN, Belenli OK, Cakir B 2009 Ultrasonographic evaluation of thyroid nodules: comparison of ultrasonographic, cytological, and histopathological findings. Endocrine **36:**464–472.
76. Cappelli C, Pirola I, Cumetti D, Micheletti L, Tironi A, Gandossi E, Martino E, Cherubini L, Agosti B, Castellano M, Mattanza C, Rosei EA 2005 Is the anteroposterior and transverse diameter ratio of nonpalpable thyroid nodules a sonographic criteria for recommending fine-needle aspiration cytology? Clin Endocrinol (Oxf) **63:**689–693.
77. Frates MC, Benson CB, Doubilet PM, Kunreuther E, Contreras M, Cibas ES, Orcutt J, Moore FD Jr, Larsen PR, Marqusee E, Alexander EK 2006 Prevalence and distribution of carcinoma in patients with solitary and multiple thyroid nodules on sonography. J Clin Endocrinol Metab **91:**3411–3417.
78. Moon HJ, Sung JM, Kim EK, Yoon JH, Youk JH, Kwak JY 2012 Diagnostic performance of gray-scale US and elastography in solid thyroid nodules. Radiology **262:** 1002–1013.
79. Kim DS, Kim JH, Na DG, Park SH, Kim E, Chang KH, Sohn CH, Choi YH 2009 Sonographic features of follicular variant papillary thyroid carcinomas in comparison with conventional papillary thyroid carcinomas. J Ultrasound Med **28:**1685–1692.
80. Park YJ, Kim JA, Son EJ, Youk JH, Kim EK, Kwak JY, Park CS 2014 Thyroid nodules with macrocalcification: sonographic findings predictive of malignancy. Yonsei Med J **55:**339–344.
81. Cappelli C, Castellano M, Pirola I, Cumetti D, Agosti B, Gandossi E, Agabiti Rosei E 2007 The predictive value of ultrasound findings in the management of thyroid nodules. QJM **100:**29–35.
82. Jeh SK, Jung SL, Kim BS, Lee YS 2007 Evaluating the degree of conformity of papillary carcinoma and follicular carcinoma to the reported ultrasonographic findings of malignant thyroid tumor. Korean J Radiol **8:**192–197.
83. Machens A, Holzhausen HJ, Dralle H 2005 The prognostic value of primary tumor size in papillary and follicular thyroid carcinoma. Cancer **103:**2269–2273.
84. Nam-Goong IS, Kim HY, Gong G, Lee HK, Hong SJ, Kim WB, Shong YK 2004 Ultrasonography-guided fine-needle aspiration of thyroid incidentaloma: correlation with pathological findings. Clin Endocrinol (Oxf) **60:** 21–28.
85. Henrichsen TL, Reading CC, Charboneau JW, Donovan DJ, Sebo TJ, Hay ID 2010 Cystic change in thyroid carcinoma: prevalence and estimated volume in 360 carcinomas. J Clin Ultrasound **38:**361–366.
86. Lee MJ, Kim EK, Kwak JY, Kim MJ 2009 Partially cystic thyroid nodules on ultrasound: probability of malignancy and sonographic differentiation. Thyroid **19:** 341–346.

Downloaded by Memorial Sloan Kettering from www.liebertpub.com at 08/14/19. For personal use only.

87. Kim DW, Lee EJ, In HS, Kim SJ 2010 Sonographic differentiation of partially cystic thyroid nodules: a prospective study. AJNR Am J Neuroradiol **31:**1961–1966.
88. Bonavita JA, Mayo J, Babb J, Bennett G, Oweity T, Macari M, Yee J 2009 Pattern recognition of benign nodules at ultrasound of the thyroid: which nodules can be left alone? AJR Am J Roentgenol **193:**207–213.
89. Horvath E, Majlis S, Rossi R, Franco C, Niedmann JP, Castro A, Dominguez M 2009 An ultrasonogram reporting system for thyroid nodules stratifying cancer risk for clinical management. J Clin Endocrinol Metab **94:** 1748–1751.
90. Tae HJ, Lim DJ, Baek KH, Park WC, Lee YS, Choi JE, Lee JM, Kang MI, Cha BY, Son HY, Lee KW, Kang SK 2007 Diagnostic value of ultrasonography to distinguish between benign and malignant lesions in the management of thyroid nodules. Thyroid **17:**461–466.
91. Shimura H, Haraguchi K, Hiejima Y, Fukunari N, Fujimoto Y, Katagiri M, Koyanagi N, Kurita T, Miyakawa M, Miyamoto Y, Suzuki N, Suzuki S, Kanbe M, Kato Y, Murakami T, Tohno E, Tsunoda-Shimizu H, Yamada K, Ueno E, Kobayashi K, Kobayashi T, Yokozawa T, Kitaoka M 2005 Distinct diagnostic criteria for ultrasonographic examination of papillary thyroid carcinoma: a multicenter study. Thyroid **15:**251–258.
92. Russ G, Royer B, Bigorgne C, Rouxel A, Bienvenu-Perrard M, Leenhardt L 2013 Prospective evaluation of thyroid imaging reporting and data system on 4550 nodules with and without elastography. Eur J Endocrinol **168:**649–655.
93. Cheng SP, Lee JJ, Lin JL, Chuang SM, Chien MN, Liu CL 2013 Characterization of thyroid nodules using the proposed thyroid imaging reporting and data system (TI-RADS). Head Neck **35:**541–547.
94. Ito Y, Amino N, Yokozawa T, Ota H, Ohshita M, Murata N, Morita S, Kobayashi K, Miyauchi A 2007 Ultrasonographic evaluation of thyroid nodules in 900 patients: comparison among ultrasonographic, cytological, and histological findings. Thyroid **17:**1269–1276.
95. Ito Y, Miyauchi A, Kihara M, Higashiyama T, Kobayashi K, Miya A 2014 Patient age is significantly related to the progression of papillary microcarcinoma of the thyroid under observation. Thyroid **24:**27–34.
96. Hamming JF, Goslings BM, van Steenis GJ, van Ravenswaay CH, Hermans J, van de Velde CJ 1990 The value of fine-needle aspiration biopsy in patients with nodular thyroid disease divided into groups of suspicion of malignant neoplasms on clinical grounds. Arch Intern Med **150:**113–116.
97. Rago T, Santini F, Scutari M, Pinchera A, Vitti P 2007 Elastography: new developments in ultrasound for predicting malignancy in thyroid nodules. J Clin Endocrinol Metab **92:**2917–2922.
98. Azizi G, Keller J, Lewis M, Puett D, Rivenbark K, Malchoff C 2013 Performance of elastography for the evaluation of thyroid nodules: a prospective study. Thyroid **23:**734–740.
99. Baloch ZW, LiVolsi VA, Asa SL, Rosai J, Merino MJ, Randolph G, Vielh P, DeMay RM, Sidawy MK, Frable WJ 2008 Diagnostic terminology and morphologic criteria for cytologic diagnosis of thyroid lesions: a synopsis of the National Cancer Institute Thyroid Fine-Needle Aspiration State of the Science Conference. Diagn Cytopathol **36:**425–437.
100. Crippa S, Mazzucchelli L, Cibas ES, Ali SZ 2010 The Bethesda System for reporting thyroid fine-needle aspiration specimens. Am J Clin Pathol **134:**343–344.
101. Theoharis CG, Schofield KM, Hammers L, Udelsman R, Chhieng DC 2009 The Bethesda thyroid fine-needle aspiration classification system: year 1 at an academic institution. Thyroid **19:**1215–1223.
102. Luu MH, Fischer AH, Pisharodi L, Owens CL 2011 Improved preoperative definitive diagnosis of papillary thyroid carcinoma in FNAs prepared with both ThinPrep and conventional smears compared with FNAs prepared with ThinPrep alone. Cancer Cytopathol **119:**68–73.
103. Bongiovanni M, Spitale A, Faquin WC, Mazzucchelli L, Baloch ZW 2012 The Bethesda System for Reporting Thyroid Cytopathology: a meta-analysis. Acta Cytol **56:** 333–339.
104. Nayar R, Ivanovic M 2009 The indeterminate thyroid fine-needle aspiration: experience from an academic center using terminology similar to that proposed in the 2007 National Cancer Institute Thyroid Fine Needle Aspiration State of the Science Conference. Cancer **117:** 195–202.
105. Ohori NP, Schoedel KE 2011 Variability in the atypia of undetermined significance/follicular lesion of undetermined significance diagnosis in the Bethesda System for Reporting Thyroid Cytopathology: sources and recommendations. Acta Cytol **55:**492–498.
106. Cibas ES, Baloch ZW, Fellegara G, LiVolsi VA, Raab SS, Rosai J, Diggans J, Friedman L, Kennedy GC, Kloos RT, Lanman RB, Mandel SJ, Sindy N, Steward DL, Zeiger MA, Haugen BR, Alexander EK 2013 A prospective assessment defining the limitations of thyroid nodule pathologic evaluation. Ann Intern Med **159:** 325–332.
107. Nishino M, Wang HH 2014 Should the thyroid AUS/FLUS category be further stratified by malignancy risk? Cancer Cytopathol **122:**481–483.
108. Crothers BA, Henry MR, Firat P 2010 Nondiagnostic/unsatisfactory. In: Ali SZ, Cibas ES (eds) The Bethesda System for Reporting Thyroid Cytopathology. Springer, pp 5–14.
109. Baloch ZW, Tam D, Langer J, Mandel S, LiVolsi VA, Gupta PK 2000 Ultrasound-guided fine-needle aspiration biopsy of the thyroid: role of on-site assessment and multiple cytologic preparations. Diagn Cytopathol **23:** 425–429.
110. Braga M, Cavalcanti TC, Collaco LM, Graf H 2001 Efficacy of ultrasound-guided fine-needle aspiration biopsy in the diagnosis of complex thyroid nodules. J Clin Endocrinol Metab **86:**4089–4091.
111. Redman R, Zalaznick H, Mazzaferri EL, Massoll NA 2006 The impact of assessing specimen adequacy and number of needle passes for fine-needle aspiration biopsy of thyroid nodules. Thyroid **16:**55–60.
112. Orija IB, Pineyro M, Biscotti C, Reddy SS, Hamrahian AH 2007 Value of repeating a nondiagnostic thyroid fine-needle aspiration biopsy. Endocr Pract **13:**735–742.
113. Wu HH, Rose C, Elsheikh TM 2012 The Bethesda system for reporting thyroid cytopathology: an experience of 1,382 cases in a community practice setting with the implication for risk of neoplasm and risk of malignancy. Diagn Cytopathol **40:**399–403.
114. Layfield LJ, Abrams J, Cochand-Priollet B, Evans D, Gharib H, Greenspan F, Henry M, LiVolsi V, Merino M,

Downloaded by Memorial Sloan Kettering from www.liebertpub.com at 08/14/19. For personal use only.

Michael CW, Wang H, Wells SA 2008 Post-thyroid FNA testing and treatment options: a synopsis of the National Cancer Institute Thyroid Fine Needle Aspiration State of the Science Conference. Diagn Cytopathol **36:**442–448.
115. Singh RS, Wang HH 2011 Timing of repeat thyroid fine-needle aspiration in the management of thyroid nodules. Acta Cytol **55:**544–548.
116. Lubitz CC, Nagarkatti SS, Faquin WC, Samir AE, Hassan MC, Barbesino G, Ross DS, Randolph GW, Gaz RD, Stephen AE, Hodin RA, Daniels GH, Parangi S 2012 Diagnostic yield of nondiagnostic thyroid nodules is not altered by timing of repeat biopsy. Thyroid **22:** 590–594.
117. Choi YS, Hong SW, Kwak JY, Moon HJ, Kim EK 2012 Clinical and ultrasonographic findings affecting nondiagnostic results upon the second fine needle aspiration for thyroid nodules. Ann Surg Oncol **19:** 2304–2309.
118. Moon HJ, Kwak JY, Choi YS, Kim EK 2012 How to manage thyroid nodules with two consecutive nondiagnostic results on ultrasonography-guided fine-needle aspiration. World J Surg **36:**586–592.
119. Na DG, Kim JH, Sung JY, Baek JH, Jung KC, Lee H, Yoo H 2012 Core-needle biopsy is more useful than repeat fine-needle aspiration in thyroid nodules read as nondiagnostic or atypia of undetermined significance by the Bethesda system for reporting thyroid cytopathology. Thyroid **22:**468–475.
120. Nam SY, Han BK, Ko EY, Kang SS, Hahn SY, Hwang JY, Nam MY, Kim JW, Chung JH, Oh YL, Shin JH 2010 $BRAF^{V600E}$ mutation analysis of thyroid nodules needle aspirates in relation to their ultrasongraphic classification: a potential guide for selection of samples for molecular analysis. Thyroid **20:**273–279.
121. Yip L, Nikiforova MN, Carty SE, Yim JH, Stang MT, Tublin MJ, LeBeau SO, Hodak SP, Ogilvie JB, Nikiforov YE 2009 Optimizing surgical treatment of papillary thyroid carcinoma associated with BRAF mutation. Surgery **146:**1215–1223.
122. Cantara S, Capezzone M, Marchisotta S, Capuano S, Busonero G, Toti P, Di SA, Caruso G, Carli AF, Brilli L, Montanaro A, Pacini F 2010 Impact of proto-oncogene mutation detection in cytological specimens from thyroid nodules improves the diagnostic accuracy of cytology. J Clin Endocrinol Metab **95:**1365–1369.
123. Renshaw AA, Pinnar N 2007 Comparison of thyroid fine-needle aspiration and core needle biopsy. Am J Clin Pathol **128:**370–374.
124. Yeon JS, Baek JH, Lim HK, Ha EJ, Kim JK, Song DE, Kim TY, Lee JH 2013 Thyroid nodules with initially nondiagnostic cytologic results: the role of core-needle biopsy. Radiology **268:**274–280.
125. Deleted.
126. Hatada T, Okada K, Ishii H, Ichii S, Utsunomiya J 1998 Evaluation of ultrasound-guided fine-needle aspiration biopsy for thyroid nodules. Am J Surg **175:**133–136.
127. Deleted.
128. Cesur M, Corapcioglu D, Bulut S, Gursoy A, Yilmaz AE, Erdogan N, Kamel N 2006 Comparison of palpation-guided fine-needle aspiration biopsy to ultrasound-guided fine-needle aspiration biopsy in the evaluation of thyroid nodules. Thyroid **16:**555–561.
129. Chehade JM, Silverberg AB, Kim J, Case C, Mooradian AD 2001 Role of repeated fine-needle aspiration of thyroid nodules with benign cytologic features. Endocr Pract **7:**237–243.
130. Orlandi A, Puscar A, Capriata E, Fideleff H 2005 Repeated fine-needle aspiration of the thyroid in benign nodular thyroid disease: critical evaluation of long-term follow-up. Thyroid **15:**274–278.
131. Oertel YC, Miyahara-Felipe L, Mendoza MG, Yu K 2007 Value of repeated fine needle aspirations of the thyroid: an analysis of over ten thousand FNAs. Thyroid **17:**1061–1066.
132. Erdogan MF, Kamel N, Aras D, Akdogan A, Baskal N, Erdogan G 1998 Value of re-aspirations in benign nodular thyroid disease. Thyroid **8:**1087–1090.
133. Illouz F, Rodien P, Saint-Andre JP, Triau S, Laboureau-Soares S, Dubois S, Vielle B, Hamy A, Rohmer V 2007 Usefulness of repeated fine-needle cytology in the follow-up of non-operated thyroid nodules. Eur J Endocrinol **156:**303–308.
134. Tee YY, Lowe AJ, Brand CA, Judson RT 2007 Fine-needle aspiration may miss a third of all malignancy in palpable thyroid nodules: a comprehensive literature review. Ann Surg **246:**714–720.
135. Pinchot SN, Al-Wagih H, Schaefer S, Sippel R, Chen H 2009 Accuracy of fine-needle aspiration biopsy for predicting neoplasm or carcinoma in thyroid nodules 4 cm or larger. Arch Surg **144:**649–655.
136. Kuru B, Gulcelik NE, Gulcelik MA, Dincer H 2010 The false-negative rate of fine-needle aspiration cytology for diagnosing thyroid carcinoma in thyroid nodules. Langenbecks Arch Surg **395:**127–132.
137. Wharry LI, McCoy KL, Stang MT, Armstrong MJ, LeBeau SO, Tublin ME, Sholosh B, Silbermann A, Ohori NP, Nikiforov YE, Hodak SP, Carty SE, Yip L 2014 Thyroid nodules (>/=4 cm): can ultrasound and cytology reliably exclude cancer? World J Surg **38:**614–621.
138. Yoon JH, Kwak JY, Moon HJ, Kim MJ, Kim EK 2011 The diagnostic accuracy of ultrasound-guided fine-needle aspiration biopsy and the sonographic differences between benign and malignant thyroid nodules 3 cm or larger. Thyroid **21:**993–1000.
139. Porterfield JR Jr, Grant CS, Dean DS, Thompson GB, Farley DR, Richards ML, Reading CC, Charboneau JW, Vollrath BK, Sebo TJ 2008 Reliability of benign fine needle aspiration cytology of large thyroid nodules. Surgery **144:**963–968.
140. Nou E, Kwong N, Alexander LK, Cibas ES, Marqusee E, Alexander EK 2014 Determination of the optimal time interval for repeat evaluation after a benign thyroid nodule aspiration. J Clin Endocrinol Metab **99:**510–516.
141. Mazzaferri EL 2007 Management of low-risk differentiated thyroid cancer. Endocr Pract **13:**498–512.
142. Hay ID 2007 Management of patients with low-risk papillary thyroid carcinoma. Endocr Pract **13:**521–533.
143. Sugitani I, Toda K, Yamada K, Yamamoto N, Ikenaga M, Fujimoto Y 2010 Three distinctly different kinds of papillary thyroid microcarcinoma should be recognized: our treatment strategies and outcomes. World J Surg **34:** 1222–1231.
144. Yu XM, Wan Y, Sippel RS, Chen H 2011 Should all papillary thyroid microcarcinomas be aggressively treated? An analysis of 18,445 cases. Ann Surg **254:**653–660.
145. Chow SM, Law SC, Chan JK, Au SK, Yau S, Lau WH 2003 Papillary microcarcinoma of the thyroid—prog-

Downloaded by Memorial Sloan Kettering from www.liebertpub.com at 08/14/19. For personal use only.

nostic significance of lymph node metastasis and multifocality. Cancer **98:**31–40.
146. Hay ID, Hutchinson ME, Gonzalez-Losada T, McIver B, Reinalda ME, Grant CS, Thompson GB, Sebo TJ, Goellner JR 2008 Papillary thyroid microcarcinoma: a study of 900 cases observed in a 60-year period. Surgery **144:**980–987.
147. Roti E, degli Uberti EC, Bondanelli M, Braverman LE 2008 Thyroid papillary microcarcinoma: a descriptive and meta-analysis study. Eur J Endocrinol **159:** 659–673.
148. Giordano D, Gradoni P, Oretti G, Molina E, Ferri T 2010 Treatment and prognostic factors of papillary thyroid microcarcinoma. Clin Otolaryngol **35:**118–124.
149. Ito Y, Miyauchi A, Inoue H, Fukushima M, Kihara M, Higashiyama T, Tomoda C, Takamura Y, Kobayashi K, Miya A 2010 An observational trial for papillary thyroid microcarcinoma in Japanese patients. World J Surg **34:** 28–35.
150. Niemeier LA, Kuffner AH, Song C, Carty SE, Hodak SP, Yip L, Ferris RL, Tseng GC, Seethala RR, LeBeau SO, Stang MT, Coyne C, Johnson JT, Stewart AF, Nikiforov YE 2012 A combined molecular-pathologic score improves risk stratification of thyroid papillary microcarcinoma. Cancer **118:**2069–2077.
151. Roh JL, Kim JM, Park CI 2008 Central cervical nodal metastasis from papillary thyroid microcarcinoma: pattern and factors predictive of nodal metastasis. Ann Surg Oncol **15:**2482–2486.
152. Lin KL, Wang OC, Zhang XH, Dai XX, Hu XQ, Qu JM 2010 The BRAF mutation is predictive of aggressive clinicopathological characteristics in papillary thyroid microcarcinoma. Ann Surg Oncol **17:**3294–3300.
153. Zheng X, Wei S, Han Y, Li Y, Yu Y, Yun X, Ren X, Gao M 2013 Papillary microcarcinoma of the thyroid: clinical characteristics and BRAF(V600E) mutational status of 977 cases. Ann Surg Oncol **20:**2266–2273.
154. Melo M, da Rocha AG, Vinagre J, Batista R, Peixoto J, Tavares C, Celestino R, Almeida A, Salgado C, Eloy C, Castro P, Prazeres H, Lima J, Amaro T, Lobo C, Martins MJ, Moura M, Cavaco B, Leite V, Cameselle-Teijeiro JM, Carrilho F, Carvalheiro M, Maximo V, Sobrinho-Simoes M, Soares P 2014 TERT promoter mutations are a major indicator of poor outcome in differentiated thyroid carcinomas. J Clin Endocrinol Metab **99:**E754-E765.
155. Xing M, Liu R, Liu X, Murugan AK, Zhu G, Zeiger MA, Pai S, Bishop J 2014 $BRAF^{V600E}$ and TERT promoter mutations cooperatively identify the most aggressive papillary thyroid cancer with highest recurrence. J Clin Oncol **32:**2718–2726.
156. Nikiforova MN, Kimura ET, Gandhi M, Biddinger PW, Knauf JA, Basolo F, Zhu Z, Giannini R, Salvatore G, Fusco A, Santoro M, Fagin JA, Nikiforov YE 2003 BRAF mutations in thyroid tumors are restricted to papillary carcinomas and anaplastic or poorly differentiated carcinomas arising from papillary carcinomas. J Clin Endocrinol Metab **88:**5399–5404.
157. Ricarte-Filho JC, Ryder M, Chitale DA, Rivera M, Heguy A, Ladanyi M, Janakiraman M, Solit D, Knauf JA, Tuttle RM, Ghossein RA, Fagin JA 2009 Mutational profile of advanced primary and metastatic radioactive iodine-refractory thyroid cancers reveals distinct pathogenetic roles for BRAF, PIK3CA, and AKT1. Cancer Res **69:**4885–4893.
158. Febbo PG, Ladanyi M, Aldape KD, De Marzo AM, Hammond ME, Hayes DF, Iafrate AJ, Kelley RK, Marcucci G, Ogino S, Pao W, Sgroi DC, Birkeland ML 2011 NCCN Task Force report: Evaluating the clinical utility of tumor markers in oncology. J Natl Compr Canc Netw **9(Suppl 5):**S1–S32.
159. Bernet V, Hupart KH, Parangi S, Woeber KA 2014 AACE/ACE disease state commentary: molecular diagnostic testing of thyroid nodules with indeterminate cytopathology. Endocr Pract **20:**360–363.
160. Ferris RL, Baloch Z, Bernet V, Chen A, Fahey TJ III, Ganly I, Hodak SP, Kebebew E, Patel KN, Shaha A, Steward DL, Tufano RP, Wiseman SM, Carty SE; American Thyroid Association Surgical Affairs Committee 2015 American Thyroid Association Statement on Surgical Application of Molecular Profiling for Thyroid Nodules: Current Impact on Perioperative Decision Making. Thyroid **25:**760–768.
161. Xing M, Haugen BR, Schlumberger M 2013 Progress in molecular-based management of differentiated thyroid cancer. Lancet **381:**1058–1069.
162. Nikiforov YE, Ohori NP, Hodak SP, Carty SE, LeBeau SO, Ferris RL, Yip L, Seethala RR, Tublin ME, Stang MT, Coyne C, Johnson JT, Stewart AF, Nikiforova MN 2011 Impact of mutational testing on the diagnosis and management of patients with cytologically indeterminate thyroid nodules: a prospective analysis of 1056 FNA samples. J Clin Endocrinol Metab **96:** 3390–3397.
163. Alexander EK, Kennedy GC, Baloch ZW, Cibas ES, Chudova D, Diggans J, Friedman L, Kloos RT, LiVolsi VA, Mandel SJ, Raab SS, Rosai J, Steward DL, Walsh PS, Wilde JI, Zeiger MA, Lanman RB, Haugen BR 2012 Preoperative diagnosis of benign thyroid nodules with indeterminate cytology. N Engl J Med **367:**705–715.
164. Bartolazzi A, Orlandi F, Saggiorato E, Volante M, Arecco F, Rossetto R, Palestini N, Ghigo E, Papotti M, Bussolati G, Martegani MP, Pantellini F, Carpi A, Giovagnoli MR, Monti S, Toscano V, Sciacchitano S, Pennelli GM, Mian C, Pelizzo MR, Rugge M, Troncone G, Palombini L, Chiappetta G, Botti G, Vecchione A, Bellocco R 2008 Galectin-3-expression analysis in the surgical selection of follicular thyroid nodules with indeterminate fine-needle aspiration cytology: a prospective multicentre study. Lancet Oncol **9:**543–549.
165. Nikiforov YE, Steward DL, Robinson-Smith TM, Haugen BR, Klopper JP, Zhu Z, Fagin JA, Falciglia M, Weber K, Nikiforova MN 2009 Molecular testing for mutations in improving the fine-needle aspiration diagnosis of thyroid nodules. J Clin Endocrinol Metab **94:** 2092–2098.
166. Moses W, Weng J, Sansano I, Peng M, Khanafshar E, Ljung BM, Duh QY, Clark OH, Kebebew E 2010 Molecular testing for somatic mutations improves the accuracy of thyroid fine-needle aspiration biopsy. World J Surg **34:**2589–2594.
167. Beaudenon-Huibregtse S, Alexander EK, Guttler RB, Hershman JM, Babu V, Blevins TC, Moore P, Andruss B, Labourier E 2014 Centralized molecular testing for oncogenic gene mutations complements the local cytopathologic diagnosis of thyroid nodules. Thyroid **24:** 1479–1487.
168. Liu S, Gao A, Zhang B, Zhang Z, Zhao Y, Chen P, Ji M, Hou P, Shi B 2014 Assessment of molecular testing in

Downloaded by Memorial Sloan Kettering from www.liebertpub.com at 08/14/19. For personal use only.

fine-needle aspiration biopsy samples: an experience in a Chinese population. Exp Mol Pathol **97:**292–297.
169. Nikiforov YE, Nikiforova MN 2011 Molecular genetics and diagnosis of thyroid cancer. Nat Rev Endocrinol **7:** 569–580.
170. Nikiforov YE, Carty SE, Chiosea SI, Coyne C, Duvvuri U, Ferris RL, Gooding WE, Hodak SP, LeBeau SO, Ohori NP, Seethala RR, Tublin ME, Yip L, Nikiforova MN 2014 Highly accurate diagnosis of cancer in thyroid nodules with follicular neoplasm/suspicious for a follicular neoplasm cytology by ThyroSeq v2 next-generation sequencing assay. Cancer **120:**3627–3634.
171. Alexander EK, Schorr M, Klopper J, Kim C, Sipos J, Nabhan F, Parker C, Steward DL, Mandel SJ, Haugen BR 2014 Multicenter clinical experience with the Afirma gene expression classifier. J Clin Endocrinol Metab **99:** 119–125.
172. Harrell RM, Bimston DN 2014 Surgical utility of Afirma: effects of high cancer prevalence and oncocytic cell types in patients with indeterminate thyroid cytology. Endocr Pract **20:**364–369.
173. McIver B, Castro MR, Morris JC, Bernet V, Smallridge R, Henry M, Kosok L, Reddi H 2014 An independent study of a gene expression classifier (Afirma) in the evaluation of cytologically indeterminate thyroid nodules. J Clin Endocrinol Metab **99:**4069–4077.
174. Marti JL, Avadhani V, Donatelli LA, Niyogi S, Wang B, Wong RJ, Shaha AR, Ghossein RA, Lin O, Morris LG, Ho AS 2015 Wide inter-institutional variation in performance of a molecular classifier for indeterminate thyroid nodules. Ann Surg Oncol **22:**3996–4001.
175. Franco C, Martinez V, Allamand JP, Medina F, Glasinovic A, Osorio M, Schachter D 2009 Molecular markers in thyroid fine-needle aspiration biopsy: a prospective study. Appl Immunohistochem Mol Morphol **17:**211–215.
176. Fadda G, Rossi ED, Raffaelli M, Pontecorvi A, Sioletic S, Morassi F, Lombardi CP, Zannoni GF, Rindi G 2011 Follicular thyroid neoplasms can be classified as low- and high-risk according to HBME-1 and Galectin-3 expression on liquid-based fine-needle cytology. Eur J Endocrinol **165:**447–453.
177. Lubitz CC, Fahey TJ III 2005 The differentiation of benign and malignant thyroid nodules. Adv Surg **39:** 355–377.
178. Prasad NB, Somervell H, Tufano RP, Dackiw AP, Marohn MR, Califano JA, Wang Y, Westra WH, Clark DP, Umbricht CB, Libutti SK, Zeiger MA 2008 Identification of genes differentially expressed in benign versus malignant thyroid tumors. Clin Cancer Res **14:**3327–3337.
179. Lappinga PJ, Kip NS, Jin L, Lloyd RV, Henry MR, Zhang J, Nassar A 2010 HMGA2 gene expression analysis performed on cytologic smears to distinguish benign from malignant thyroid nodules. Cancer Cytopathol **118:**287–297.
180. Chen YT, Kitabayashi N, Zhou XK, Fahey TJ III, Scognamiglio T 2008 MicroRNA analysis as a potential diagnostic tool for papillary thyroid carcinoma. Mod Pathol **21:**1139–1146.
181. Nikiforova MN, Tseng GC, Steward D, Diorio D, Nikiforov YE 2008 MicroRNA expression profiling of thyroid tumors: biological significance and diagnostic utility. J Clin Endocrinol Metab **93:**1600–1608.
182. Mazeh H, Mizrahi I, Halle D, Ilyayev N, Stojadinovic A, Trink B, Mitrani-Rosenbaum S, Roistacher M, Ariel I, Eid A, Freund HR, Nissan A 2011 Development of a microRNA-based molecular assay for the detection of papillary thyroid carcinoma in aspiration biopsy samples. Thyroid **21:**111–118.
183. Shen R, Liyanarachchi S, Li W, Wakely PE Jr, Saji M, Huang J, Nagy R, Farrell T, Ringel MD, de la Chapelle A, Kloos RT, He H 2012 MicroRNA signature in thyroid fine needle aspiration cytology applied to ''atypia of undetermined significance'' cases. Thyroid **22:**9–16.
184. Keutgen XM, Filicori F, Crowley MJ, Wang Y, Scognamiglio T, Hoda R, Buitrago D, Cooper D, Zeiger MA, Zarnegar R, Elemento O, Fahey TJ III 2012 A panel of four miRNAs accurately differentiates malignant from benign indeterminate thyroid lesions on fine needle aspiration. Clin Cancer Res **18:**2032–2038.
185. Agretti P, Ferrarini E, Rago T, Candelieri A, De Marco G, Dimida A, Niccolai F, Molinaro A, Di Coscio G, Pinchera A, Vitti P, Tonacchera M 2012 MicroRNA expression profile helps to distinguish benign nodules from papillary thyroid carcinomas starting from cells of fine-needle aspiration. Eur J Endocrinol **167:**393–400.
186. Labourier E, Shifrin A, Busseniers AE, Lupo MA, Manganelli ML, Andruss B, Wylie D, Beaudenon-Huibregtse S 2015 Molecular testing for miRNA, mRNA, and DNA on fine-needle aspiration improves the preoperative diagnosis of thyroid nodules with indeterminate cytology. J Clin Endocrinol Metab **100:**2743–2750.
187. Milas M, Shin J, Gupta M, Novosel T, Nasr C, Brainard J, Mitchell J, Berber E, Siperstein A 2010 Circulating thyrotropin receptor mRNA as a novel marker of thyroid cancer: clinical applications learned from 1758 samples. Ann Surg **252:**643–651.
188. McGovern MM, Benach MO, Wallenstein S, Desnick RJ, Keenlyside R 1999 Quality assurance in molecular genetic testing laboratories. JAMA **281:**835–840.
189. McGovern MM, Elles R, Beretta I, Somerville MJ, Hoefler G, Keinanen M, Barton D, Carson N, Dequeker E, Brdicka R, Blazkova A, Ayme S, Schnieders B, Muller CR, Dalen V, Martinez AA, Kristoffersson U, Ozguc M, Mueller H, Boone J, Lubin IM, Sequeiros J, Taruscio D, Williamson B, Mainland L, Yoshikura H, Ronchi E 2007 Report of an international survey of molecular genetic testing laboratories. Community Genet **10:**123–131.
190. Krane JF, Nayar R, Renshaw AA 2010 Atypia of undetermined significance/follicular lesion of undetermined significance. In: Ali SZ, Cibas ES (eds) The Bethesda System for Reporting Thyroid Cytopathology. Springer, pp 37–49.
191. Bongiovanni M, Crippa S, Baloch Z, Piana S, Spitale A, Pagni F, Mazzucchelli L, Di BC, Faquin W 2012 Comparison of 5-tiered and 6-tiered diagnostic systems for the reporting of thyroid cytopathology: a multi-institutional study. Cancer Cytopathol **120:**117–125.
192. Davidov T, Trooskin SZ, Shanker BA, Yip D, Eng O, Crystal J, Hu J, Chernyavsky VS, Deen MF, May M, Artymyshyn RL 2010 Routine second-opinion cytopathology review of thyroid fine needle aspiration biopsies reduces diagnostic thyroidectomy. Surgery **148:** 1294–1299.

Downloaded by Memorial Sloan Kettering from www.liebertpub.com at 08/14/19. For personal use only.

193. Baloch Z, LiVolsi VA, Jain P, Jain R, Aljada I, Mandel S, Langer JE, Gupta PK 2003 Role of repeat fine-needle aspiration biopsy (FNAB) in the management of thyroid nodules. Diagn Cytopathol **29:**203–206.
194. Yassa L, Cibas ES, Benson CB, Frates MC, Doubilet PM, Gawande AA, Moore FD Jr, Kim BW, Nose V, Marqusee E, Larsen PR, Alexander EK 2007 Long-term assessment of a multidisciplinary approach to thyroid nodule diagnostic evaluation. Cancer **111:**508–516.
195. Yang J, Schnadig V, Logrono R, Wasserman PG 2007 Fine-needle aspiration of thyroid nodules: a study of 4703 patients with histologic and clinical correlations. Cancer **111:**306–315.
196. Vanderlaan PA, Marqusee E, Krane JF 2011 Clinical outcome for atypia of undetermined significance in thyroid fine-needle aspirations: should repeated fna be the preferred initial approach? Am J Clin Pathol **135:**770–775.
197. Nasrollah N, Trimboli P, Rossi F, Amendola S, Guidobaldi L, Ventura C, Maglio R, Nigri G, Romanelli F, Valabrega S, Crescenzi A 2014 Patient's comfort with and tolerability of thyroid core needle biopsy. Endocrine **45:**79–83.
198. Kim SK, Hwang TS, Yoo YB, Han HS, Kim DL, Song KH, Lim SD, Kim WS, Paik NS 2011 Surgical results of thyroid nodules according to a management guideline based on the BRAF(V600E) mutation status. J Clin Endocrinol Metab **96:**658–664.
199. Adeniran AJ, Hui P, Chhieng DC, Prasad ML, Schofield K, Theoharis C 2011 BRAF mutation testing of thyroid fine-needle aspiration specimens enhances the predictability of malignancy in thyroid follicular lesions of undetermined significance. Acta Cytol **55:**570–575.
200. Lastra RR, Pramick MR, Crammer CJ, LiVolsi VA, Baloch ZW 2014 Implications of a suspicious afirma test result in thyroid fine-needle aspiration cytology: an institutional experience. Cancer Cytopathol **122:**737–744.
201. Jeong SH, Hong HS, Lee EH, Cha JG, Park JS, Kwak JJ 2013 Outcome of thyroid nodules characterized as atypia of undetermined significance or follicular lesion of undetermined significance and correlation with ultrasound features and BRAF(V600E) mutation analysis. AJR Am J Roentgenol **201:**W854–W860.
202. Yoo WS, Choi HS, Cho SW, Moon JH, Kim KW, Park HJ, Park SY, Choi SI, Choi SH, Lim S, Yi KH, Park do J, Jang HC, Park YJ 2014 The role of ultrasound findings in the management of thyroid nodules with atypia or follicular lesions of undetermined significance. Clin Endocrinol (Oxf) **80:**735–742.
203. Gweon HM, Son EJ, Youk JH, Kim JA 2013 Thyroid nodules with Bethesda system III cytology: can ultrasonography guide the next step? Ann Surg Oncol **20:**3083–3088.
204. Kim DW, Lee EJ, Jung SJ, Ryu JH, Kim YM 2011 Role of sonographic diagnosis in managing Bethesda class III nodules. AJNR Am J Neuroradiol **32:**2136–2141.
205. Rosario PW 2014 Thyroid nodules with atypia or follicular lesions of undetermined significance (Bethesda Category III): importance of ultrasonography and cytological subcategory. Thyroid **24:**1115–1120.
206. Henry MR, DeMay RM, Berezowski K 2010 Follicular neoplasm/suspicious for a follicular neoplasm. In: Ali SZ, Cibas ES (eds) The Bethesda System for Reporting Thyroid Cytopathology. Springer, pp 51–58.
207. Faquin WC, Michael CW, Renshaw AA 2010 Follicular neoplasm, Hürthle cell type/suspicious for a follicular neoplasm, Hürthle cell type. In: Ali SZ, Cibas ES (eds) The Bethesda System for Reporting Thyroid Cytopathology. Springer, pp 59–73.
208. Gupta N, Dasyam AK, Carty SE, Nikiforova MN, Ohori NP, Armstrong M, Yip L, LeBeau SO, McCoy KL, Coyne C, Stang MT, Johnson J, Ferris RL, Seethala R, Nikiforov YE, Hodak SP 2013 RAS mutations in thyroid FNA specimens are highly predictive of predominantly low-risk follicular-pattern cancers. J Clin Endocrinol Metab **98:**E914–E922.
209. Wang HH, Filie AC, Clark DP 2010 Suspicious for malignancy. In: Ali SZ, Cibas ES (eds) The Bethesda System for Reporting Thyroid Cytopathology. Springer, pp 75–89.
210. Moon HJ, Kwak JY, Kim EK, Choi JR, Hong SW, Kim MJ, Son EJ 2009 The role of BRAFV600E mutation and ultrasonography for the surgical management of a thyroid nodule suspicious for papillary thyroid carcinoma on cytology. Ann Surg Oncol **16:**3125–3131.
211. Adeniran AJ, Theoharis C, Hui P, Prasad ML, Hammers L, Carling T, Udelsman R, Chhieng DC 2011 Reflex BRAF testing in thyroid fine-needle aspiration biopsy with equivocal and positive interpretation: a prospective study. Thyroid **21:**717–723.
212. Jara SM, Bhatnagar R, Guan H, Gocke CD, Ali SZ, Tufano RP 2014 Utility of BRAF mutation detection in fine-needle aspiration biopsy samples read as ''suspicious for papillary thyroid carcinoma''. Head Neck doi: 10.1002/hed.23829. [Epub ahead of print].
213. de Geus-Oei LF, Pieters GF, Bonenkamp JJ, Mudde AH, Bleeker-Rovers CP, Corstens FH, Oyen WJ 2006 18F-FDG PET reduces unnecessary hemithyroidectomies for thyroid nodules with inconclusive cytologic results. J Nucl Med **47:**770–775.
214. Kresnik E, Gallowitsch HJ, Mikosch P, Stettner H, Igerc I, Gomez I, Kumnig G, Lind P 2003 Fluorine-18-fluorodeoxyglucose positron emission tomography in the preoperative assessment of thyroid nodules in an endemic goiter area. Surgery **133:**294–299.
215. Kim JM, Ryu JS, Kim TY, Kim WB, Kwon GY, Gong G, Moon DH, Kim SC, Hong SJ, Shong YK 2007 18F-fluorodeoxyglucose positron emission tomography does not predict malignancy in thyroid nodules cytologically diagnosed as follicular neoplasm. J Clin Endocrinol Metab **92:**1630–1634.
216. Sebastianes FM, Cerci JJ, Zanoni PH, Soares J Jr, Chibana LK, Tomimori EK, de Camargo RY, Izaki M, Giorgi MC, Eluf-Neto J, Meneghetti JC, Pereira MA 2007 Role of 18F-fluorodeoxyglucose positron emission tomography in preoperative assessment of cytologically indeterminate thyroid nodules. J Clin Endocrinol Metab **92:**4485–4488.
217. Hales NW, Krempl GA, Medina JE 2008 Is there a role for fluorodeoxyglucose positron emission tomography/computed tomography in cytologically indeterminate thyroid nodules? Am J Otolaryngol **29:**113–118.
218. Traugott AL, Dehdashti F, Trinkaus K, Cohen M, Fialkowski E, Quayle F, Hussain H, Davila R, Ylagan L, Moley JF 2010 Exclusion of malignancy in thyroid nodules with indeterminate fine-needle aspiration cytology after negative 18F-fluorodeoxyglucose positron emission tomography: interim analysis. World J Surg **34:**1247–1253.
219. Smith RB, Robinson RA, Hoffman HT, Graham MM 2008 Preoperative FDG-PET imaging to assess the ma-

Downloaded by Memorial Sloan Kettering from www.liebertpub.com at 08/14/19. For personal use only.

lignant potential of follicular neoplasms of the thyroid. Otolaryngol Head Neck Surg **138:**101–106.
220. Deandreis D, Al Ghuzlan A, Auperin A, Vielh P, Caillou B, Chami L, Lumbroso J, Travagli JP, Hartl D, Baudin E, Schlumberger M, Leboulleux S 2012 Is (18)F-fluorodeoxyglucose-PET/CT useful for the presurgical characterization of thyroid nodules with indeterminate fine needle aspiration cytology? Thyroid **22:**165–172.
221. Vriens D, de Wilt JH, van der Wilt GJ, Netea-Maier RT, Oyen WJ, de Geus-Oei LF 2011 The role of [18F]-2-fluoro-2-deoxy-d-glucose-positron emission tomography in thyroid nodules with indeterminate fine-needle aspiration biopsy: systematic review and meta-analysis of the literature. Cancer **117:**4582–4594.
222. Wang N, Zhai H, Lu Y 2013 Is fluorine-18 fluorodeoxyglucose positron emission tomography useful for the thyroid nodules with indeterminate fine needle aspiration biopsy? A meta-analysis of the literature. J Otolaryngol Head Neck Surg **42:**38–45.
223. Vriens D, Adang EM, Netea-Maier RT, Smit JW, de Wilt JH, Oyen WJ, de Geus-Oei LF 2014 Cost-effectiveness of FDG-PET/CT for cytologically indeterminate thyroid nodules: a decision analytic approach. J Clin Endocrinol Metab **99:**3263–3274.
224. Duren M, Yavuz N, Bukey Y, Ozyegin MA, Gundogdu S, Acbay O, Hatemi H, Uslu I, Onsel C, Aksoy F, Oz F, Unal G, Duren E 2000 Impact of initial surgical treatment on survival of patients with differentiated thyroid cancer: experience of an endocrine surgery center in an iodine-deficient region. World J Surg **24:**1290–1294.
225. Stojadinovic A, Peoples GE, Libutti SK, Henry LR, Eberhardt J, Howard RS, Gur D, Elster EA, Nissan A 2009 Development of a clinical decision model for thyroid nodules. BMC Surg **9:**12.
226. Tuttle RM, Lemar H, Burch HB 1998 Clinical features associated with an increased risk of thyroid malignancy in patients with follicular neoplasia by fine-needle aspiration. Thyroid **8:**377–383.
227. Goldstein RE, Netterville JL, Burkey B, Johnson JE 2002 Implications of follicular neoplasms, atypia, and lesions suspicious for malignancy diagnosed by fine-needle aspiration of thyroid nodules. Ann Surg **235:**656–662.
228. Schlinkert RT, van Heerden JA, Goellner JR, Gharib H, Smith SL, Rosales RF, Weaver AL 1997 Factors that predict malignant thyroid lesions when fine-needle aspiration is ''suspicious for follicular neoplasm''. Mayo Clin Proc **72:**913–916.
229. Mehta RS, Carty SE, Ohori NP, Hodak SP, Coyne C, LeBeau SO, Tublin ME, Stang MT, Johnson JT, McCoy KL, Nikiforova MN, Nikiforov YE, Yip L 2013 Nodule size is an independent predictor of malignancy in mutation-negative nodules with follicular lesion of undetermined significance cytology. Surgery **154:**730–736.
230. McCoy KL, Carty SE, Armstrong MJ, Seethala RR, Ohori NP, Kabaker AS, Stang MT, Hodak SP, Nikiforov YE, Yip L 2012 Intraoperative pathologic examination in the era of molecular testing for differentiated thyroid cancer. J Am Coll Surg **215:**546–554.
231. Kandil E, Krishnan B, Noureldine SI, Yao L, Tufano RP 2013 Hemithyroidectomy: a meta-analysis of postoperative need for hormone replacement and complications. ORL J Otorhinolaryngol Relat Spec **75:**6–17.
232. Sosa JA, Bowman HM, Tielsch JM, Powe NR, Gordon TA, Udelsman R 1998 The importance of surgeon experience for clinical and economic outcomes from thyroidectomy. Ann Surg **228:**320–330.
233. Loyo M, Tufano RP, Gourin CG 2013 National trends in thyroid surgery and the effect of volume on short-term outcomes. Laryngoscope **123:**2056–2063.
234. Verloop H, Louwerens M, Schoones JW, Kievit J, Smit JW, Dekkers OM 2012 Risk of hypothyroidism following hemithyroidectomy: systematic review and meta-analysis of prognostic studies. J Clin Endocrinol Metab **97:**2243–2255.
235. Brito JP, Yarur AJ, Prokop LJ, McIver B, Murad MH, Montori VM 2013 Prevalence of thyroid cancer in multinodular goiter versus single nodule: a systematic review and meta-analysis. Thyroid **23:**449–455.
236. Kwak JY, Koo H, Youk JH, Kim MJ, Moon HJ, Son EJ, Kim EK 2010 Value of US correlation of a thyroid nodule with initially benign cytologic results. Radiology **254:**292–300.
237. Brauer VF, Eder P, Miehle K, Wiesner TD, Hasenclever H, Paschke R 2005 Interobserver variation for ultrasound determination of thyroid nodule volumes. Thyroid **15:** 1169–1175.
238. Alexander EK, Hurwitz S, Heering JP, Benson CB, Frates MC, Doubilet PM, Cibas ES, Larsen PR, Marqusee E 2003 Natural history of benign solid and cystic thyroid nodules. Ann Intern Med **138:**315–318.
239. Papini E, Petrucci L, Guglielmi R, Panunzi C, Rinaldi R, Bacci V, Crescenzi A, Nardi F, Fabbrini R, Pacella CM 1998 Long-term changes in nodular goiter: a 5-year prospective randomized trial of levothyroxine suppressive therapy for benign cold thyroid nodules. J Clin Endocrinol Metab **83:**780–783.
240. Erdogan MF, Gursoy A, Erdogan G 2006 Natural course of benign thyroid nodules in a moderately iodine-deficient area. Clin Endocrinol (Oxf) **65:**767–771.
241. Durante C, Costante G, Lucisano G, Bruno R, Meringolo D, Paciaroni A, Puxeddu E, Torlontano M, Tumino S, Attard M, Lamartina L, Nicolucci A, Filetti S 2015 The natural history of benign thyroid nodules. JAMA **313:** 926–935.
242. Rosario PW, Purisch S 2010 Ultrasonographic characteristics as a criterion for repeat cytology in benign thyroid nodules. Arq Bras Endocrinol Metabol **54:** 52–55.
243. Zelmanovitz F, Genro S, Gross JL 1998 Suppressive therapy with levothyroxine for solitary thyroid nodules: a double-blind controlled clinical study and cumulative meta-analyses. J Clin Endocrinol Metab **83:**3881–3885.
244. Wemeau JL, Caron P, Schvartz C, Schlienger JL, Orgiazzi J, Cousty C, Vlaeminck-Guillem V 2002 Effects of thyroid-stimulating hormone suppression with levothyroxine in reducing the volume of solitary thyroid nodules and improving extranodular nonpalpable changes: a randomized, double-blind, placebo-controlled trial by the French Thyroid Research Group. J Clin Endocrinol Metab **87:**4928–4934.
245. Castro MR, Caraballo PJ, Morris JC 2002 Effectiveness of thyroid hormone suppressive therapy in benign solitary thyroid nodules: a meta-analysis. J Clin Endocrinol Metab **87:**4154–4159.
246. Yousef A, Clark J, Doi SA 2010 Thyroxine suppression therapy for benign, non-functioning solitary thyroid nodules: a quality-effects meta-analysis. Clin Med Res **8:**150–158.

Downloaded by Memorial Sloan Kettering from www.liebertpub.com at 08/14/19. For personal use only.

247. Sdano MT, Falciglia M, Welge JA, Steward DL 2005 Efficacy of thyroid hormone suppression for benign thyroid nodules: meta-analysis of randomized trials. Otolaryngol Head Neck Surg **133:**391–396.
248. Grussendorf M, Reiners C, Paschke R, Wegscheider K 2011 Reduction of thyroid nodule volume by levothyroxine and iodine alone and in combination: a randomized, placebo-controlled trial. J Clin Endocrinol Metab **96:**2786–2795.
249. Puzziello A, Carrano M, Angrisani E, Marotta V, Faggiano A, Zeppa P, Vitale M 2014 Evolution of benign thyroid nodules under levothyroxine non-suppressive therapy. J Endocrinol Invest **37:**1181–1186.
250. Bennedbaek FN, Hegedus L 2003 Treatment of recurrent thyroid cysts with ethanol: a randomized double-blind controlled trial. J Clin Endocrinol Metab **88:**5773–5777.
251. Valcavi R, Frasoldati A 2004 Ultrasound-guided percutaneous ethanol injection therapy in thyroid cystic nodules. Endocr Pract **10:**269–275.
252. Antonelli A, Campatelli A, Di VA, Alberti B, Baldi V, Salvioni G, Fallahi P, Baschieri L 1994 Comparison between ethanol sclerotherapy and emptying with injection of saline in treatment of thyroid cysts. Clin Investig **72:**971–974.
253. Verde G, Papini E, Pacella CM, Gallotti C, Delpiano S, Strada S, Fabbrini R, Bizzarri G, Rinaldi R, Panunzi C 1994 Ultrasound guided percutaneous ethanol injection in the treatment of cystic thyroid nodules. Clin Endocrinol (Oxf) **41:**719–724.
254. Chen AY, Bernet VJ, Carty SE, Davies TF, Ganly I, Inabnet WB III, Shaha AR 2014 American Thyroid Association statement on optimal surgical management of goiter. Thyroid **24:**181–189.
255. Shin JJ, Caragacianu D, Randolph GW 2015 Impact of thyroid nodule size on prevalence and post-test probability of malignancy: a systematic review. Laryngoscope **125:**263–272.
256. Marley EF, Oertel YC 1997 Fine-needle aspiration of thyroid lesions in 57 pregnant and postpartum women. Diagn Cytopathol **16:**122–125.
257. Kung AW, Chau MT, Lao TT, Tam SC, Low LC 2002 The effect of pregnancy on thyroid nodule formation. J Clin Endocrinol Metab **87:**1010–1014.
258. Moosa M, Mazzaferri EL 1997 Outcome of differentiated thyroid cancer diagnosed in pregnant women. J Clin Endocrinol Metab **82:**2862–2866.
259. Rosen IB, Korman M, Walfish PG 1997 Thyroid nodular disease in pregnancy: current diagnosis and management. Clin Obstet Gynecol **40:**81–89.
260. McLeod DS, Watters KF, Carpenter AD, Ladenson PW, Cooper DS, Ding EL 2012 Thyrotropin and thyroid cancer diagnosis: a systematic review and dose-response meta-analysis. J Clin Endocrinol Metab **97:** 2682–2692.
261. Karger S, Schotz S, Stumvoll M, Berger F, Fuhrer D 2010 Impact of pregnancy on prevalence of goitre and nodular thyroid disease in women living in a region of borderline sufficient iodine supply. Horm Metab Res **42:** 137–142.
262. Messuti I, Corvisieri S, Bardesono F, Rapa I, Giorcelli J, Pellerito R, Volante M, Orlandi F 2014 Impact of pregnancy on prognosis of differentiated thyroid cancer: clinical and molecular features. Eur J Endocrinol **170:** 659–666.
263. Vannucchi G, Perrino M, Rossi S, Colombo C, Vicentini L, Dazzi D, Beck-Peccoz P, Fugazzola L 2010 Clinical and molecular features of differentiated thyroid cancer diagnosed during pregnancy. Eur J Endocrinol **162:**145–151.
264. Mestman JH, Goodwin TM, Montoro MM 1995 Thyroid disorders of pregnancy. Endocrinol Metab Clin North Am **24:**41–71.
265. Herzon FS, Morris DM, Segal MN, Rauch G, Parnell T 1994 Coexistent thyroid cancer and pregnancy. Arch Otolaryngol Head Neck Surg **120:**1191–1193.
266. Mazzaferri EL, Jhiang SM 1994 Long-term impact of initial surgical and medical therapy on papillary and follicular thyroid cancer. Am J Med **97:**418–428.
267. Kuy S, Roman SA, Desai R, Sosa JA 2009 Outcomes following thyroid and parathyroid surgery in pregnant women. Arch Surg **144:**399–406.
268. Aschebrook-Kilfoy B, Ward MH, Sabra MM, Devesa SS 2011 Thyroid cancer incidence patterns in the United States by histologic type, 1992–2006. Thyroid **21:**125–134.
269. Hundahl SA, Fleming ID, Fremgen AM, Menck HR 1998 A National Cancer Data Base report on 53,856 cases of thyroid carcinoma treated in the U.S., 1985–1995 [see commetns]. Cancer **83:**2638–2648.
270. Hay ID, Bergstralh EJ, Goellner JR, Ebersold JR, Grant CS 1993 Predicting outcome in papillary thyroid carcinoma: development of a reliable prognostic scoring system in a cohort of 1779 patients surgically treated at one institution during 1940 through 1989. Surgery **114:** 1050–1057.
271. Shah MD, Hall FT, Eski SJ, Witterick IJ, Walfish PG, Freeman JL 2003 Clinical course of thyroid carcinoma after neck dissection. Laryngoscope **113:**2102–2107.
272. Wang TS, Dubner S, Sznyter LA, Heller KS 2004 Incidence of metastatic well-differentiated thyroid cancer in cervical lymph nodes. Arch Otolaryngol Head Neck Surg **130:**110–113.
273. Mazzaferri EL 1999 An overview of the management of papillary and follicular thyroid carcinoma. Thyroid **9:**421–427.
274. Mazzaferri EL 2000 Long-term outcome of patients with differentiated thyroid carcinoma: effect of therapy. Endocr Pract **6:**469–476.
275. Cooper DS, Specker B, Ho M, Sperling M, Ladenson PW, Ross DS, Ain KB, Bigos ST, Brierley JD, Haugen BR, Klein I, Robbins J, Sherman SI, Taylor T, Maxon HR III 1998 Thyrotropin suppression and disease progression in patients with differentiated thyroid cancer: results from the National Thyroid Cancer Treatment Cooperative Registry. Thyroid **8:**737–744.
276. Lin JD, Chao TC, Huang MJ, Weng HF, Tzen KY 1998 Use of radioactive iodine for thyroid remnant ablation in well-differentiated thyroid carcinoma to replace thyroid reoperation. Am J Clin Oncol **21:**77–81.
277. Brierley JD, Panzarella T, Tsang RW, Gospodarowicz MK, O'Sullivan B 1997 A comparison of different staging systems predictability of patient outcome. Thyroid carcinoma as an example. Cancer **79:**2414–2423.
278. Hay ID, Thompson GB, Grant CS, Bergstralh EJ, Dvorak CE, Gorman CA, Maurer MS, McIver B, Mullan BP, Oberg AL, Powell CC, van Heerden JA, Goellner JR 2002 Papillary thyroid carcinoma managed at the Mayo Clinic during six decades (1940–1999): temporal trends in initial therapy and long-term outcome in 2444 consecutively treated patients. World J Surg **26:**879–885.

Downloaded by Memorial Sloan Kettering from www.liebertpub.com at 08/14/19. For personal use only.

279. Gourin CG, Tufano RP, Forastiere AA, Koch WM, Pawlik TM, Bristow RE 2010 Volume-based trends in thyroid surgery. Arch Otolaryngol Head Neck Surg **136:**1191–1198.
280. Stavrakis AI, Ituarte PH, Ko CY, Yeh MW 2007 Surgeon volume as a predictor of outcomes in inpatient and outpatient endocrine surgery. Surgery **142:**887–899.
281. Grebe SK, Hay ID 1996 Thyroid cancer nodal metastases: biologic significance and therapeutic considerations. Surg Oncol Clin N Am **5:**43–63.
282. Scheumann GF, Gimm O, Wegener G, Hundeshagen H, Dralle H 1994 Prognostic significance and surgical management of locoregional lymph node metastases in papillary thyroid cancer. World J Surg **18:**559–567.
283. Ito Y, Uruno T, Nakano K, Takamura Y, Miya A, Kobayashi K, Yokozawa T, Matsuzuka F, Kuma S, Kuma K, Miyauchi A 2003 An observation trial without surgical treatment in patients with papillary microcarcinoma of the thyroid. Thyroid **13:**381–387.
284. Hay ID, Grant CS, van Heerden JA, Goellner JR, Ebersold JR, Bergstralh EJ 1992 Papillary thyroid microcarcinoma: a study of 535 cases observed in a 50-year period. Surgery **112:**1139–1146.
285. Qubain SW, Nakano S, Baba M, Takao S, Aikou T 2002 Distribution of lymph node micrometastasis in pN0 well-differentiated thyroid carcinoma. Surgery **131:**249–256.
286. Arturi F, Russo D, Giuffrida D, Ippolito A, Perrotti N, Vigneri R, Filetti S 1997 Early diagnosis by genetic analysis of differentiated thyroid cancer metastases in small lymph nodes. J Clin Endocrinol Metab **82:**1638–1641.
287. Solorzano CC, Carneiro DM, Ramirez M, Lee TM, Irvin GL, III 2004 Surgeon-performed ultrasound in the management of thyroid malignancy. Am Surg **70:**576–580.
288. Shimamoto K, Satake H, Sawaki A, Ishigaki T, Funahashi H, Imai T 1998 Preoperative staging of thyroid papillary carcinoma with ultrasonography. Eur J Radiol **29:**4–10.
289. Stulak JM, Grant CS, Farley DR, Thompson GB, van Heerden JA, Hay ID, Reading CC, Charboneau JW 2006 Value of preoperative ultrasonography in the surgical management of initial and reoperative papillary thyroid cancer. Arch Surg **141:**489–494.
290. Kouvaraki MA, Shapiro SE, Fornage BD, Edeiken-Monro BS, Sherman SI, Vassilopoulou-Sellin R, Lee JE, Evans DB 2003 Role of preoperative ultrasonography in the surgical management of patients with thyroid cancer. Surgery **134:**946–954.
291. O'Connell K, Yen TW, Quiroz F, Evans DB, Wang TS 2013 The utility of routine preoperative cervical ultrasonography in patients undergoing thyroidectomy for differentiated thyroid cancer. Surgery **154:**697–701.
292. Leboulleux S, Girard E, Rose M, Travagli JP, Sabbah N, Caillou B, Hartl DM, Lassau N, Baudin E, Schlumberger M 2007 Ultrasound criteria of malignancy for cervical lymph nodes in patients followed up for differentiated thyroid cancer. J Clin Endocrinol Metab **92:**3590–3594.
293. Frasoldati A, Valcavi R 2004 Challenges in neck ultrasonography: lymphadenopathy and parathyroid glands. Endocr Pract **10:**261–268.
294. Kuna SK, Bracic I, Tesic V, Kuna K, Herceg GH, Dodig D 2006 Ultrasonographic differentiation of benign from malignant neck lymphadenopathy in thyroid cancer. J Ultrasound Med **25:**1531–1537.
295. Park JH, Lee YS, Kim BW, Chang HS, Park CS 2012 Skip lateral neck node metastases in papillary thyroid carcinoma. World J Surg **36:**743–747.
296. Snozek CL, Chambers EP, Reading CC, Sebo TJ, Sistrunk JW, Singh RJ, Grebe SK 2007 Serum thyroglobulin, high-resolution ultrasound, and lymph node thyroglobulin in diagnosis of differentiated thyroid carcinoma nodal metastases. J Clin Endocrinol Metab **92:**4278–4281.
297. Frasoldati A, Pesenti M, Gallo M, Caroggio A, Salvo D, Valcavi R 2003 Diagnosis of neck recurrences in patients with differentiated thyroid carcinoma. Cancer **97:**90–96.
298. Boi F, Baghino G, Atzeni F, Lai ML, Faa G, Mariotti S 2006 The diagnostic value for differentiated thyroid carcinoma metastases of thyroglobulin (Tg) measurement in washout fluid from fine-needle aspiration biopsy of neck lymph nodes is maintained in the presence of circulating anti-Tg antibodies. J Clin Endocrinol Metab **91:**1364–1369.
299. Jeon MJ, Park JW, Han JM, Yim JH, Song DE, Gong G, Kim TY, Baek JH, Lee JH, Shong YK, Kim WB 2013 Serum antithyroglobulin antibodies interfere with thyroglobulin detection in fine-needle aspirates of metastatic neck nodes in papillary thyroid carcinoma. J Clin Endocrinol Metab **98:**153–160.
300. Chung J, Kim EK, Lim H, Son EJ, Yoon JH, Youk JH, Kim JA, Moon HJ, Kwak JY 2014 Optimal indication of thyroglobulin measurement in fine-needle aspiration for detecting lateral metastatic lymph nodes in patients with papillary thyroid carcinoma. Head Neck **36:**795–801.
301. Grani G, Fumarola A 2014 Thyroglobulin in lymph node fine-needle aspiration wash-out: a systematic review and meta-analysis of diagnostic accuracy. J Clin Endocrinol Metab **99:**1970–1982.
302. Pak K, Suh S, Hong H, Cheon GJ, Hahn SK, Kang KW, Kim EE, Lee DS, Chung JK 2015 Diagnostic values of thyroglobulin measurement in fine-needle aspiration of lymph nodes in patients with thyroid cancer. Endocrine **49:**70–77.
303. Pacini F, Fugazzola L, Lippi F, Ceccarelli C, Centoni R, Miccoli P, Elisei R, Pinchera A 1992 Detection of thyroglobulin in fine needle aspirates of nonthyroidal neck masses: a clue to the diagnosis of metastatic differentiated thyroid cancer. J Clin Endocrinol Metab **74:**1401–1404.
304. Moon JH, Kim YI, Lim JA, Choi HS, Cho SW, Kim KW, Park HJ, Paeng JC, Park YJ, Yi KH, Park do J, Kim SE, Chung JK 2013 Thyroglobulin in washout fluid from lymph node fine-needle aspiration biopsy in papillary thyroid cancer: large-scale validation of the cutoff value to determine malignancy and evaluation of discrepant results. J Clin Endocrinol Metab **98:**1061–1068.
305. Giovanella L, Bongiovanni M, Trimboli P 2013 Diagnostic value of thyroglobulin assay in cervical lymph node fine-needle aspirations for metastatic differentiated thyroid cancer. Curr Opin Oncol **25:**6–13.
306. Stephenson BM, Wheeler MH, Clark OH 1994 The role of total thyroidectomy in the management of differentiated thyroid cancer. Curr Opin Gen Surg **2:**53–59.
307. Ahn JE, Lee JH, Yi JS, Shong YK, Hong SJ, Lee DH, Choi CG, Kim SJ 2008 Diagnostic accuracy of CT and ultrasonography for evaluating metastatic cervical lymph nodes in patients with thyroid cancer. World J Surg **32:**1552–1558.

Downloaded by Memorial Sloan Kettering from www.liebertpub.com at 08/14/19. For personal use only.

308. Choi JS, Kim J, Kwak JY, Kim MJ, Chang HS, Kim EK 2009 Preoperative staging of papillary thyroid carcinoma: comparison of ultrasound imaging and CT. AJR Am J Roentgenol **193:**871–878.
309. Lesnik D, Cunnane ME, Zurakowski D, Acar GO, Ecevit C, Mace A, Kamani D, Randolph GW 2014 Papillary thyroid carcinoma nodal surgery directed by a preoperative radiographic map utilizing CT scan and ultrasound in all primary and reoperative patients. Head Neck **36:**191–202.
310. Jeong HS, Baek CH, Son YI, Choi JY, Kim HJ, Ko YH, Chung JH, Baek HJ 2006 Integrated 18F-FDG PET/CT for the initial evaluation of cervical node level of patients with papillary thyroid carcinoma: comparison with ultrasound and contrast-enhanced CT. Clin Endocrinol (Oxf) **65:**402–407.
311. Kaplan SL, Mandel SJ, Muller R, Baloch ZW, Thaler ER, Loevner LA 2009 The role of MR imaging in detecting nodal disease in thyroidectomy patients with rising thyroglobulin levels. AJNR Am J Neuroradiol **30:**608–612.
312. Andersen PE, Kinsella J, Loree TR, Shaha AR, Shah JP 1995 Differentiated carcinoma of the thyroid with extrathyroidal extension. Am J Surg **170:**467–470.
313. Kim E, Park JS, Son KR, Kim JH, Jeon SJ, Na DG 2008 Preoperative diagnosis of cervical metastatic lymph nodes in papillary thyroid carcinoma: comparison of ultrasound, computed tomography, and combined ultrasound with computed tomography. Thyroid **18:**411–418.
314. Yeh MW, Bauer AJ, Bernet VA, Ferris RL, Loevner LA, Mandel SJ, Orloff LA, Randolph GW, Steward DL 2015 American Thyroid Association statement on preoperative imaging for thyroid cancer surgery. Thyroid **25:**3–14.
315. Padovani RP, Kasamatsu TS, Nakabashi CC, Camacho CP, Andreoni DM, Malouf EZ, Marone MM, Maciel RM, Biscolla RP 2012 One month is sufficient for urinary iodine to return to its baseline value after the use of water-soluble iodinated contrast agents in post-thyroidectomy patients requiring radioiodine therapy. Thyroid **22:**926–930.
316. Spencer CA, Bergoglio LM, Kazarosyan M, Fatemi S, LoPresti JS 2005 Clinical impact of thyroglobulin (Tg) and Tg autoantibody method differences on the management of patients with differentiated thyroid carcinomas. J Clin Endocrinol Metab **90:**5566–5575.
317. McLeod DS, Cooper DS, Ladenson PW, Ain KB, Brierley JD, Fein HG, Haugen BR, Jonklaas J, Magner J, Ross DS, Skarulis MC, Steward DL, Maxon HR, Sherman SI; for the National Thyroid Cancer Treatment Cooperative Study Group 2014 Prognosis of differentiated thyroid cancer in relation to serum thyrotropin and thyroglobulin antibody status at time of diagnosis. Thyroid **24:**35–42.
318. Bilimoria KY, Bentrem DJ, Ko CY, Stewart AK, Winchester DP, Talamonti MS, Sturgeon C 2007 Extent of surgery affects survival for papillary thyroid cancer. Ann Surg **246:**375–381.
319. Grant CS, Hay ID, Gough IR, Bergstralh EJ, Goellner JR, McConahey WM 1988 Local recurrence in papillary thyroid carcinoma: is extent of surgical resection important? Surgery **104:**954–962.
320. Hay ID, Grant CS, Bergstralh EJ, Thompson GB, van Heerden JA, Goellner JR 1998 Unilateral total lobectomy: is it sufficient surgical treatment for patients with AMES low-risk papillary thyroid carcinoma? Surgery **124:**958–964.
321. Mazzaferri EL, Kloos RT 2001 Clinical review 128: Current approaches to primary therapy for papillary and follicular thyroid cancer. J Clin Endocrinol Metab **86:** 1447–1463.
322. Matsuzu K, Sugino K, Masudo K, Nagahama M, Kitagawa W, Shibuya H, Ohkuwa K, Uruno T, Suzuki A, Magoshi S, Akaishi J, Masaki C, Kawano M, Suganuma N, Rino Y, Masuda M, Kameyama K, Takami H, Ito K 2014 Thyroid lobectomy for papillary thyroid cancer: long-term follow-up study of 1,088 cases. World J Surg **38:**68–79.
323. Barney BM, Hitchcock YJ, Sharma P, Shrieve DC, Tward JD 2011 Overall and cause-specific survival for patients undergoing lobectomy, near-total, or total thyroidectomy for differentiated thyroid cancer. Head Neck **33:**645–649.
324. Mendelsohn AH, Elashoff DA, Abemayor E, St John MA 2010 Surgery for papillary thyroid carcinoma: is lobectomy enough? Arch Otolaryngol Head Neck Surg **136:**1055–1061.
325. Haigh PI, Urbach DR, Rotstein LE 2005 Extent of thyroidectomy is not a major determinant of survival in low- or high-risk papillary thyroid cancer. Ann Surg Oncol **12:**81–89.
326. Nixon IJ, Ganly I, Patel SG, Palmer FL, Whitcher MM, Tuttle RM, Shaha A, Shah JP 2012 Thyroid lobectomy for treatment of well differentiated intrathyroid malignancy. Surgery **151:**571–579.
327. Adam MA, Pura J, Gu L, Dinan MA, Tyler DS, Reed SD, Scheri R, Roman SA, Sosa JA 2014 Extent of surgery for papillary thyroid cancer is not associated with survival: an analysis of 61,775 patients. Ann Surg **260:** 601–605.
328. Vaisman F, Shaha A, Fish S, Michael TR 2011 Initial therapy with either thyroid lobectomy or total thyroidectomy without radioactive iodine remnant ablation is associated with very low rates of structural disease recurrence in properly selected patients with differentiated thyroid cancer. Clin Endocrinol (Oxf) **75:**112–119.
329. Tuggle CT, Roman S, Udelsman R, Sosa JA 2011 Same-day thyroidectomy: a review of practice patterns and outcomes for 1,168 procedures in New York State. Ann Surg Oncol **18:**1035–1040.
330. Tuggle CT, Roman SA, Wang TS, Boudourakis L, Thomas DC, Udelsman R, Ann SJ 2008 Pediatric endocrine surgery: who is operating on our children? Surgery **144:**869–877.
331. Kandil E, Noureldine SI, Abbas A, Tufano RP 2013 The impact of surgical volume on patient outcomes following thyroid surgery. Surgery **154:**1346–1352.
332. Duclos A, Peix JL, Colin C, Kraimps JL, Menegaux F, Pattou F, Sebag F, Touzet S, Bourdy S, Voirin N, Lifante JC 2012 Influence of experience on performance of individual surgeons in thyroid surgery: prospective cross sectional multicentre study. BMJ **344:**d8041.
333. Hauch A, Al-Qurayshi Z, Randolph G, Kandil E 2014 Total thyroidectomy is associated with increased risk of complications for low- and high-volume surgeons. Ann Surg Oncol **21:**3844–3852.
334. Hughes DT, White ML, Miller BS, Gauger PG, Burney RE, Doherty GM 2010 Influence of prophylactic central lymph node dissection on postoperative thyroglobulin levels and radioiodine treatment in papillary thyroid cancer. Surgery **148:**1100–1106.

Downloaded by Memorial Sloan Kettering from www.liebertpub.com at 08/14/19. For personal use only.

335. Randolph GW, Duh QY, Heller KS, LiVolsi VA, Mandel SJ, Steward DL, Tufano RP, Tuttle RM 2012 The prognostic significance of nodal metastases from papillary thyroid carcinoma can be stratified based on the size and number of metastatic lymph nodes, as well as the presence of extranodal extension. Thyroid **22:**1144–1152.
336. Podnos YD, Smith D, Wagman LD, Ellenhorn JD 2005 The implication of lymph node metastasis on survival in patients with well-differentiated thyroid cancer. Am Surg **71:**731–734.
337. Zaydfudim V, Feurer ID, Griffin MR, Phay JE 2008 The impact of lymph node involvement on survival in patients with papillary and follicular thyroid carcinoma. Surgery **144:**1070–1077.
338. Leboulleux S, Rubino C, Baudin E, Caillou B, Hartl DM, Bidart JM, Travagli JP, Schlumberger M 2005 Prognostic factors for persistent or recurrent disease of papillary thyroid carcinoma with neck lymph node metastases and/or tumor extension beyond the thyroid capsule at initial diagnosis. J Clin Endocrinol Metab **90:**5723–5729.
339. Sugitani I, Kasai N, Fujimoto Y, Yanagisawa A 2004 A novel classification system for patients with PTC: addition of the new variables of large (3 cm or greater) nodal metastases and reclassification during the follow-up period. Surgery **135:**139–148.
340. Adam MA, Pura J, Goffredo P, Dinan MA, Reed SD, Scheri RP, Hyslop T, Roman SA, Sosa JA 2015 Presence and number of lymph node metastases are associated with compromised survival for patients younger than age 45 years with papillary thyroid cancer. J Clin Oncol **33:**2370–2375.
341. Robbins KT, Shaha AR, Medina JE, Califano JA, Wolf GT, Ferlito A, Som PM, Day TA 2008 Consensus statement on the classification and terminology of neck dissection. Arch Otolaryngol Head Neck Surg **134:**536–538.
342. Hwang HS, Orloff LA 2011 Efficacy of preoperative neck ultrasound in the detection of cervical lymph node metastasis from thyroid cancer. Laryngoscope **121:**487–491.
343. Mulla M, Schulte KM 2012 Central cervical lymph node metastases in papillary thyroid cancer: a systematic review of imaging-guided and prophylactic removal of the central compartment. Clin Endocrinol (Oxf) **76:**131–136.
344. Hartl DM, Leboulleux S, Al Ghuzlan A, Baudin E, Chami L, Schlumberger M, Travagli JP 2012 Optimization of staging of the neck with prophylactic central and lateral neck dissection for papillary thyroid carcinoma. Ann Surg **255:**777–783.
345. Popadich A, Levin O, Lee JC, Smooke-Praw S, Ro K, Fazel M, Arora A, Tolley NS, Palazzo F, Learoyd DL, Sidhu S, Delbridge L, Sywak M, Yeh MW 2011 A multicenter cohort study of total thyroidectomy and routine central lymph node dissection for cN0 papillary thyroid cancer. Surgery **150:**1048–1057.
346. Lang BH, Wong KP, Wan KY, Lo CY 2012 Impact of routine unilateral central neck dissection on preablative and postablative stimulated thyroglobulin levels after total thyroidectomy in papillary thyroid carcinoma. Ann Surg Oncol **19:**60–67.
347. Wang TS, Evans DB, Fareau GG, Carroll T, Yen TW 2012 Effect of prophylactic central compartment neck dissection on serum thyroglobulin and recommendations for adjuvant radioactive iodine in patients with differentiated thyroid cancer. Ann Surg Oncol **19:**4217–4222.
348. Carty SE, Cooper DS, Doherty GM, Duh QY, Kloos RT, Mandel SJ, Randolph GW, Stack BC Jr, Steward DL, Terris DJ, Thompson GB, Tufano RP, Tuttle RM, Udelsman R 2009 Consensus statement on the terminology and classification of central neck dissection for thyroid cancer. Thyroid **19:**1153–1158.
349. Chisholm EJ, Kulinskaya E, Tolley NS 2009 Systematic review and meta-analysis of the adverse effects of thyroidectomy combined with central neck dissection as compared with thyroidectomy alone. Laryngoscope **119:**1135–1139.
350. Bonnet S, Hartl D, Leboulleux S, Baudin E, Lumbroso JD, Al Ghuzlan A, Chami L, Schlumberger M, Travagli JP 2009 Prophylactic lymph node dissection for papillary thyroid cancer less than 2 cm: implications for radioiodine treatment. J Clin Endocrinol Metab **94:**1162–1167.
351. Sancho JJ, Lennard TW, Paunovic I, Triponez F, Sitges-Serra A 2014 Prophylactic central neck disection in papillary thyroid cancer: a consensus report of the European Society of Endocrine Surgeons (ESES). Langenbecks Arch Surg **399:**155–163.
352. Zetoune T, Keutgen X, Buitrago D, Aldailami H, Shao H, Mazumdar M, Fahey TJ III, Zarnegar R 2010 Prophylactic central neck dissection and local recurrence in papillary thyroid cancer: a meta-analysis. Ann Surg Oncol **17:**3287–3293.
353. Barczynski M, Konturek A, Stopa M, Nowak W 2013 Prophylactic central neck dissection for papillary thyroid cancer. Br J Surg **100:**410–418.
354. Hartl DM, Mamelle E, Borget I, Leboulleux S, Mirghani H, Schlumberger M 2013 Influence of prophylactic neck dissection on rate of retreatment for papillary thyroid carcinoma. World J Surg **37:**1951–1958.
355. Sywak M, Cornford L, Roach P, Stalberg P, Sidhu S, Delbridge L 2006 Routine ipsilateral level VI lymphadenectomy reduces postoperative thyroglobulin levels in papillary thyroid cancer. Surgery **140:**1000–1005.
356. Laird AM, Gauger PG, Miller BS, Doherty GM 2012 Evaluation of postoperative radioactive iodine scans in patients who underwent prophylactic central lymph node dissection. World J Surg **36:**1268–1273.
357. Costa S, Giugliano G, Santoro L, Ywata De Carvalho A, Massaro MA, Gibelli B, De Fiori E, Grosso E, Ansarin M, Calabrese L 2009 Role of prophylactic central neck dissection in cN0 papillary thyroid cancer. Acta Otorhinolaryngol Ital **29:**61–69.
358. Ryu IS, Song CI, Choi SH, Roh JL, Nam SY, Kim SY 2014 Lymph node ratio of the central compartment is a significant predictor for locoregional recurrence after prophylactic central neck dissection in patients with thyroid papillary carcinoma. Ann Surg Oncol **21:**277–283.
359. Moreno MA, Edeiken-Monroe BS, Siegel ER, Sherman SI, Clayman GL 2012 In papillary thyroid cancer, preoperative central neck ultrasound detects only macroscopic surgical disease, but negative findings predict excellent long-term regional control and survival. Thyroid **22:**347–355.
360. Yoo D, Ajmal S, Gowda S, Machan J, Monchik J, Mazzaglia P 2012 Level VI lymph node dissection does not decrease radioiodine uptake in patients undergoing

Downloaded by Memorial Sloan Kettering from www.liebertpub.com at 08/14/19. For personal use only.

radioiodine ablation for differentiated thyroid cancer. World J Surg **36:**1255–1261.

361. Roh JL, Park JY, Park CI 2007 Total thyroidectomy plus neck dissection in differentiated papillary thyroid carcinoma patients: pattern of nodal metastasis, morbidity, recurrence, and postoperative levels of serum parathyroid hormone. Ann Surg **245:**604–610.
362. Cavicchi O, Piccin O, Caliceti U, De Cataldis A, Pasquali R, Ceroni AR 2007 Transient hypoparathyroidism following thyroidectomy: a prospective study and multivariate analysis of 604 consecutive patients. Otolaryngol Head Neck Surg **137:**654–658.
363. Raffaelli M, De Crea C, Sessa L, Giustacchini P, Revelli L, Bellantone C, Lombardi CP 2012 Prospective evaluation of total thyroidectomy versus ipsilateral versus bilateral central neck dissection in patients with clinically node-negative papillary thyroid carcinoma. Surgery **152:**957–964.
364. Viola D, Materazzi G, Valerio L, Molinaro E, Agate L, Faviana P, Seccia V, Sensi E, Romei C, Piaggi P, Torregrossa L, Sellari-Franceschini S, Basolo F, Vitti P, Elisei R, Miccoli P 2015 Prophylactic central compartment lymph node dissection in papillary thyroid carcinoma: clinical implications derived from the first prospective randomized controlled single institution study. J Clin Endocrinol Metab **100:**1316–1324.
365. Lang BH, Ng SH, Lau LL, Cowling BJ, Wong KP, Wan KY 2013 A systematic review and meta-analysis of prophylactic central neck dissection on short-term locoregional recurrence in papillary thyroid carcinoma after total thyroidectomy. Thyroid **23:**1087–1098.
366. Wang TS, Cheung K, Farrokhyar F, Roman SA, Sosa JA 2013 A meta-analysis of the effect of prophylactic central compartment neck dissection on locoregional recurrence rates in patients with papillary thyroid cancer. Ann Surg Oncol **20:**3477–3483.
367. Gyorki DE, Untch B, Tuttle RM, Shaha AR 2013 Prophylactic central neck dissection in differentiated thyroid cancer: an assessment of the evidence. Ann Surg Oncol **20:**2285–2289.
368. Haymart MR, Banerjee M, Stewart AK, Koenig RJ, Birkmeyer JD, Griggs JJ 2011 Use of radioactive iodine for thyroid cancer. JAMA **306:**721–728.
369. Howell GM, Nikiforova MN, Carty SE, Armstrong MJ, Hodak SP, Stang MT, McCoy KL, Nikiforov YE, Yip L 2013 $BRAF^{V600E}$ mutation independently predicts central compartment lymph node metastasis in patients with papillary thyroid cancer. Ann Surg Oncol **20:**47–52.
370. Xing M, Alzahrani AS, Carson KA, Viola D, Elisei R, Bendlova B, Yip L, Mian C, Vianello F, Tuttle RM, Robenshtok E, Fagin JA, Puxeddu E, Fugazzola L, Czarniecka A, Jarzab B, O'Neill CJ, Sywak MS, Lam AK, Riesco-Eizaguirre G, Santisteban P, Nakayama H, Tufano RP, Pai SI, Zeiger MA, Westra WH, Clark DP, Clifton-Bligh R, Sidransky D, Ladenson PW, Sykorova V 2013 Association between $BRAF^{V600E}$ mutation and mortality in patients with papillary thyroid cancer. JAMA **309:**1493–1501.
371. Kim TH, Park YJ, Lim JA, Ahn HY, Lee EK, Lee YJ, Kim KW, Hahn SK, Youn YK, Kim KH, Cho BY, Park do J 2012 The association of the BRAF(V600E) mutation with prognostic factors and poor clinical outcome in papillary thyroid cancer: a meta-analysis. Cancer **118:**1764–1773.
372. Ito Y, Yoshida H, Kihara M, Kobayashi K, Miya A, Miyauchi A 2014 BRAF(V600E) mutation analysis in papillary thyroid carcinoma: is it useful for all patients? World J Surg **38:**679–687.
373. Gouveia C, Can NT, Bostrom A, Grenert JP, van Zante A, Orloff LA 2013 Lack of association of BRAF mutation with negative prognostic indicators in papillary thyroid carcinoma: the University of California, San Francisco, experience. JAMA Otolaryngol Head Neck Surg **139:**1164–1170.
374. Dutenhefner SE, Marui S, Santos AB, de Lima EU, Inoue M, Neto JS, Shiang C, Fukushima JT, Cernea CR, Friguglietti CU 2013 BRAF: a tool in the decision to perform elective neck dissection? Thyroid **23:**1541–1546.
375. Lee KC, Li C, Schneider EB, Wang Y, Somervell H, Krafft M, Umbricht CB, Zeiger MA 2012 Is BRAF mutation associated with lymph node metastasis in patients with papillary thyroid cancer? Surgery **152:** 977–983.
376. Xing M 2010 Prognostic utility of BRAF mutation in papillary thyroid cancer. Mol Cell Endocrinol **321:** 86–93.
377. Sugitani I, Fujimoto Y, Yamada K, Yamamoto N 2008 Prospective outcomes of selective lymph node dissection for papillary thyroid carcinoma based on preoperative ultrasonography. World J Surg **32:**2494–2502.
378. Ito Y, Miyauchi A 2007 Lateral and mediastinal lymph node dissection in differentiated thyroid carcinoma: indications, benefits, and risks. World J Surg **31:**905–915.
379. Gemsenjager E, Perren A, Seifert B, Schuler G, Schweizer I, Heitz PU 2003 Lymph node surgery in papillary thyroid carcinoma. J Am Coll Surg **197:**182–190.
380. Kouvaraki MA, Lee JE, Shapiro SE, Sherman SI, Evans DB 2004 Preventable reoperations for persistent and recurrent papillary thyroid carcinoma. Surgery **136:** 1183–1191.
381. Ito Y, Tomoda C, Uruno T, Takamura Y, Miya A, Kobayashi K, Matsuzuka F, Kuma K, Miyauchi A 2004 Preoperative ultrasonographic examination for lymph node metastasis: usefulness when designing lymph node dissection for papillary microcarcinoma of the thyroid. World J Surg **28:**498–501.
382. Erdem E, Gulcelik MA, Kuru B, Alagol H 2003 Comparison of completion thyroidectomy and primary surgery for differentiated thyroid carcinoma. Eur J Surg Oncol **29:**747–749.
383. Tan MP, Agarwal G, Reeve TS, Barraclough BH, Delbridge LW 2002 Impact of timing on completion thyroidectomy for thyroid cancer. Br J Surg **89:**802–804.
384. Untch BR, Palmer FL, Ganly I, Patel SG, Michael TR, Shah JP, Shaha AA 2014 Oncologic outcomes after completion thyroidectomy for patients with well-differentiated thyroid carcinoma. Ann Surg Oncol **21:** 1374–1378.
385. Barbesino G, Goldfarb M, Parangi S, Yang J, Ross DS, Daniels GH 2012 Thyroid lobe ablation with radioactive iodine as an alternative to completion thyroidectomy after hemithyroidectomy in patients with follicular thyroid carcinoma: long-term follow-up. Thyroid **22:**369–376.
386. Santra A, Bal S, Mahargan S, Bal C 2011 Long-term outcome of lobar ablation versus completion thyroidectomy in differentiated thyroid cancer. Nucl Med Commun **32:**52–58.
387. Giovanella L, Piccardo A, Paone G, Foppiani L, Treglia G, Ceriani L 2013 Thyroid lobe ablation with iodine-^{131}I

Downloaded by Memorial Sloan Kettering from www.liebertpub.com at 08/14/19. For personal use only.

in patients with differentiated thyroid carcinoma: a randomized comparison between 1.1 and 3.7 GBq activities. Nucl Med Commun **34:**767–770.
388. O'Connor AM, Bennett CL, Stacey D, Barry M, Col NF, Eden KB, Entwistle VA, Fiset V, Holmes-Rovner M, Khangura S, Llewellyn-Thomas H, Rovner D 2009 Decision aids for people facing health treatment or screening decisions. Cochrane Database Syst Rev **(3):** CD001431.
389. Feldman-Stewart D, Capirci C, Brennenstuhl S, Tong C, Abacioglu U, Gawkowska-Suwinska M, van Gils F, Heyda A, Igdem S, Macias V, Grillo IM, Moynihan C, Pijls-Johannesma M, Parker C, Pimentel N, Wördehoff H 2011 Information for decision making by patients with early-stage prostate cancer: a comparison across 9 countries. Med Decis Making **31:**754–766.
390. Haynes RB, McKibbon KA, Kanani R 1996 Systematic review of randomised trials of interventions to assist patients to follow prescriptions for medications. Lancet **348:**383–386.
391. Weiss SM, Wengert PA Jr, Martinez EM, Sewall W, Kopp E 1996 Patient satisfaction with decision-making for breast cancer therapy. Ann Surg Oncol **3:**285–289.
392. Street RL Jr, Voigt B 1997 Patient participation in deciding breast cancer treatment and subsequent quality of life. Med Decis Making **17:**298–306.
393. Abdul-Sater L, Henry M, Majdan A, Mijovic T, Franklin JH, Brandt MG, Black MJ, Hier MP, Payne RJ 2011 What are thyroidectomy patients really concerned about? Otolaryngol Head Neck Surg **144:**685–690.
394. Husson O, Haak HR, Oranje WA, Mols F, Reemst PH, van de Poll-Franse LV 2011 Health-related quality of life among thyroid cancer survivors: a systematic review. Clin Endocrinol (Oxf) **75:**544–554.
395. Stojadinovic A, Shaha AR, Orlikoff RF, Nissan A, Kornak MF, Singh B, Boyle JO, Shah JP, Brennan MF, Kraus DH 2002 Prospective functional voice assessment in patients undergoing thyroid surgery. Ann Surg **236:** 823–832.
396. Soylu L, Ozbas S, Uslu HY, Kocak S 2007 The evaluation of the causes of subjective voice disturbances after thyroid surgery. Am J Surg **194:**317–322.
397. Wilson JA, Deary IJ, Millar A, Mackenzie K 2002 The quality of life impact of dysphonia. Clin Otolaryngol Allied Sci **27:**179–182.
398. Jones SM, Carding PN, Drinnan MJ 2006 Exploring the relationship between severity of dysphonia and voice-related quality of life. Clin Otolaryngol **31:**411–417.
399. Munch S, deKryger L 2001 A piece of my mind. Moral wounds: complicated complications. JAMA **285:**1131–1132.
400. Cohen SM, Kim J, Roy N, Asche C, Courey M 2012 Prevalence and causes of dysphonia in a large treatment-seeking population. Laryngoscope **122:**343–348.
401. Singer MC, Iverson KC, Terris DJ 2012 Thyroidectomy-related malpractice claims. Otolaryngol Head Neck Surg **146:**358–361.
402. Chandrasekhar SS, Randolph GW, Seidman MD, Rosenfeld RM, Angelos P, Barkmeier-Kraemer J, Benninger MS, Blumin JH, Dennis G, Hanks J, Haymart MR, Kloos RT, Seals B, Schreibstein JM, Thomas MA, Waddington C, Warren B, Robertson PJ 2013 Clinical practice guideline: improving voice outcomes after thyroid surgery. Otolaryngol Head Neck Surg **148:** S1–37.
403. Farrag TY, Samlan RA, Lin FR, Tufano RP 2006 The utility of evaluating true vocal fold motion before thyroid surgery. Laryngoscope **116:**235–238.
404. Roh JL, Yoon YH, Park CI 2009 Recurrent laryngeal nerve paralysis in patients with papillary thyroid carcinomas: evaluation and management of resulting vocal dysfunction. Am J Surg **197:**459–465.
405. Randolph GW, Kamani D 2006 The importance of preoperative laryngoscopy in patients undergoing thyroidectomy: voice, vocal cord function, and the preoperative detection of invasive thyroid malignancy. Surgery **139:** 357–362.
406. Eadie TL, Kapsner M, Rosenzweig J, Waugh P, Hillel A, Merati A 2010 The role of experience on judgments of dysphonia. J Voice **24:**564–573.
407. Rowe-Jones JM, Rosswick RP, Leighton SE 1993 Benign thyroid disease and vocal cord palsy. Ann R Coll Surg Engl **75:**241–244.
408. Shin JJ, Grillo HC, Mathisen D, Katlic MR, Zurakowski D, Kamani D, Randolph GW 2011 The surgical management of goiter: Part I. Preoperative evaluation. Laryngoscope **121:**60–67.
409. Bergenfelz A, Jansson S, Kristoffersson A, Martensson H, Reihner E, Wallin G, Lausen I 2008 Complications to thyroid surgery: results as reported in a database from a multicenter audit comprising 3,660 patients. Langenbecks Arch Surg **393:**667–673.
410. Green KM, de Carpentier JP 1999 Are pre-operative vocal fold checks necessary? J Laryngol Otol **113:**642–644.
411. Cheng SP, Lee JJ, Liu TP, Lee KS, Liu CL 2012 Preoperative ultrasonography assessment of vocal cord movement during thyroid and parathyroid surgery. World J Surg **36:**2509–2515.
412. Terris DJ, Snyder S, Carneiro-Pla D, Inabnet WB III, Kandil E, Orloff L, Shindo M, Tufano RP, Tuttle RM, Urken M, Yeh MW 2013 American Thyroid Association statement on outpatient thyroidectomy. Thyroid **23:** 1193–1202.
413. Dralle H, Sekulla C, Haerting J, Timmermann W, Neumann HJ, Kruse E, Grond S, Muhlig HP, Richter C, Voss J, Thomusch O, Lippert H, Gastinger I, Brauckhoff M, Gimm O 2004 Risk factors of paralysis and functional outcome after recurrent laryngeal nerve monitoring in thyroid surgery. Surgery **136:**1310–1322.
414. Shindo ML, Caruana S, Kandil E, McCaffrey JC, Orloff L, Porterfield JR, Randolph G, Shaha A, Shin J, Terris D 2014 Management of invasive well-differentiated thyroid cancer an American Head and Neck Society consensus statement. Head Neck **36:**1379–1390.
415. Falk SA, McCaffrey TV 1995 Management of the recurrent laryngeal nerve in suspected and proven thyroid cancer. Otolaryngol Head Neck Surg **113:**42–48.
416. Jatzko GR, Lisborg PH, Muller MG, Wette VM 1994 Recurrent nerve palsy after thyroid operations—principal nerve identification and a literature review. Surgery **115:**139–144.
417. Lo CY, Kwok KF, Yuen PW 2000 A prospective evaluation of recurrent laryngeal nerve paralysis during thyroidectomy. Arch Surg **135:**204–207.
418. Curran AJ, Smyth D, Sheehan SJ, Joyce W, Hayes DB, Walsh MA 1997 Recurrent laryngeal nerve dysfunction

Downloaded by Memorial Sloan Kettering from www.liebertpub.com at 08/14/19. For personal use only.

following carotid endarterectomy. J R Coll Surg Edinb **42:**168–170.
419. Rosenthal LH, Benninger MS, Deeb RH 2007 Vocal fold immobility: a longitudinal analysis of etiology over 20 years. Laryngoscope **117:**1864–1870.
420. Kriskovich MD, Apfelbaum RI, Haller JR 2000 Vocal fold paralysis after anterior cervical spine surgery: incidence, mechanism, and prevention of injury. Laryngoscope **110:**1467–1473.
421. Benninger MS, Crumley RL, Ford CN, Gould WJ, Hanson DG, Ossoff RH, Sataloff RT 1994 Evaluation and treatment of the unilateral paralyzed vocal fold. Otolaryngol Head Neck Surg **111:**497–508.
422. Grundfast KM, Harley E 1989 Vocal cord paralysis. Otolaryngol Clin North Am **22:**569–597.
423. Hermann M, Alk G, Roka R, Glaser K, Freissmuth M 2002 Laryngeal recurrent nerve injury in surgery for benign thyroid diseases: effect of nerve dissection and impact of individual surgeon in more than 27,000 nerves at risk. Ann Surg **235:**261–268.
424. Randolph GW, Dralle H, Abdullah H, Barczynski M, Bellantone R, Brauckhoff M, Carnaille B, Cherenko S, Chiang FY, Dionigi G, Finck C, Hartl D, Kamani D, Lorenz K, Miccolli P, Mihai R, Miyauchi A, Orloff L, Perrier N, Poveda MD, Romanchishen A, Serpell J, Sitges-Serra A, Sloan T, Van SS, Snyder S, Takami H, Volpi E, Woodson G 2011 Electrophysiologic recurrent laryngeal nerve monitoring during thyroid and parathyroid surgery: international standards guideline statement. Laryngoscope **121(Suppl 1):**S1–S16.
425. Pisanu A, Porceddu G, Podda M, Cois A, Uccheddu A 2014 Systematic review with meta-analysis of studies comparing intraoperative neuromonitoring of recurrent laryngeal nerves versus visualization alone during thyroidectomy. J Surg Res **188:**152–161.
426. Barczynski M, Konturek A, Stopa M, Honowska A, Nowak W 2012 Randomized controlled trial of visualization versus neuromonitoring of the external branch of the superior laryngeal nerve during thyroidectomy. World J Surg **36:**1340–1347.
427. Chan WF, Lang BH, Lo CY 2006 The role of intraoperative neuromonitoring of recurrent laryngeal nerve during thyroidectomy: a comparative study on 1000 nerves at risk. Surgery **140:**866–872.
428. Musholt TJ, Clerici T, Dralle H, Frilling A, Goretzki PE, Hermann MM, Kussmann J, Lorenz K, Nies C, Schabram J, Schabram P, Scheuba C, Simon D, Steinmuller T, Trupka AW, Wahl RA, Zielke A, Bockisch A, Karges W, Luster M, Schmid KW 2011 German Association of Endocrine Surgeons practice guidelines for the surgical treatment of benign thyroid disease. Langenbecks Arch Surg **396:**639–649.
429. Sturgeon C, Sturgeon T, Angelos P 2009 Neuromonitoring in thyroid surgery: attitudes, usage patterns, and predictors of use among endocrine surgeons. World J Surg **33:**417–425.
430. Horne SK, Gal TJ, Brennan JA 2007 Prevalence and patterns of intraoperative nerve monitoring for thyroidectomy. Otolaryngol Head Neck Surg **136:**952–956.
431. Sadowski SM, Soardo P, Leuchter I, Robert JH, Triponez F 2013 Systematic use of recurrent laryngeal nerve neuromonitoring changes the operative strategy in planned bilateral thyroidectomy. Thyroid **23:**329–333.
432. Goretzki PE, Schwarz K, Brinkmann J, Wirowski D, Lammers BJ 2010 The impact of intraoperative neuromonitoring (IONM) on surgical strategy in bilateral thyroid diseases: is it worth the effort? World J Surg **34:**1274–1284.
433. Melin M, Schwarz K, Lammers BJ, Goretzki PE 2013 IONM-guided goiter surgery leading to two-stage thyroidectomy—indication and results. Langenbecks Arch Surg **398:**411–418.
434. Barczynski M, Randolph GW, Cernea CR, Dralle H, Dionigi G, Alesina PF, Mihai R, Finck C, Lombardi D, Hartl DM, Miyauchi A, Serpell J, Snyder S, Volpi E, Woodson G, Kraimps JL, Hisham AN 2013 External branch of the superior laryngeal nerve monitoring during thyroid and parathyroid surgery: International Neural Monitoring Study Group standards guideline statement. Laryngoscope **123(Suppl 4):**S1–S14.
435. Randolph GW, Clark OH 2013 Principles in thyroid surgery. In: Randolph GW (ed) Surgery of the Thyroid and Parathyroid Glands. 2nd edition. Elsevier, Philadelphia, PA, pp 273–293.
436. Lorente-Poch L, Sancho JJ, Ruiz S, Sitges-Serra A 2015 Importance of in situ preservation of parathyroid glands during total thyroidectomy. Br J Surg **102:**359–367.
437. Friedman AD, Burns JA, Heaton JT, Zeitels SM 2010 Early versus late injection medialization for unilateral vocal cord paralysis. Laryngoscope **120:**2042–2046.
438. Arviso LC, Johns MM III, Mathison CC, Klein AM 2010 Long-term outcomes of injection laryngoplasty in patients with potentially recoverable vocal fold paralysis. Laryngoscope **120:**2237–2240.
439. Yung KC, Likhterov I, Courey MS 2011 Effect of temporary vocal fold injection medialization on the rate of permanent medialization laryngoplasty in unilateral vocal fold paralysis patients. Laryngoscope **121:**2191–2194.
440. Carty SE, Doherty GM, Inabnet WB III, Pasieka JL, Randolph GW, Shaha AR, Terris DJ, Tufano RP, Tuttle RM 2012 American Thyroid Association statement on the essential elements of interdisciplinary communication of perioperative information for patients undergoing thyroid cancer surgery. Thyroid **22:**395–399.
441. DeLellis RA, Lloyd RV, Heitz PU, Eng C 2004 World Health Organization Classification of Tumours. Pathology and Genetics of Tumours of Endocrine Organs. IARC Press, Lyon.
442. Haigh PI, Urbach DR 2005 The treatment and prognosis of Hürthle cell follicular thyroid carcinoma compared with its non-Hürthle cell counterpart. Surgery **138:**1152–1157.
443. Shaha AR, Loree TR, Shah JP 1995 Prognostic factors and risk group analysis in follicular carcinoma of the thyroid. Surgery **118:**1131–1136.
444. Ganly I, Ricarte FJ, Eng S, Ghossein R, Morris LG, Liang Y, Socci N, Kannan K, Mo Q, Fagin JA, Chan TA 2013 Genomic dissection of Hürthle cell carcinoma reveals a unique class of thyroid malignancy. J Clin Endocrinol Metab **98:**E962–E972.
445. Baloch ZW, LiVolsi VA 2002 Follicular-patterned lesions of the thyroid: the bane of the pathologist. Am J Clin Pathol **117:**143–150.
446. D'Avanzo A, Treseler P, Ituarte PH, Wong M, Streja L, Greenspan FS, Siperstein AE, Duh QY, Clark OH 2004 Follicular thyroid carcinoma: histology and prognosis. Cancer **100:**1123–1129.

Downloaded by Memorial Sloan Kettering from www.liebertpub.com at 08/14/19. For personal use only.

447. Rosai J 2005 Handling of thyroid follicular patterned lesions. Endocr Pathol **16:**279–283.
448. Nikiforov YE, Ohori NP 2012 Follicular carcinoma. In: Nikiforov YE, Biddinger PW, Thompson LDR (eds) Diagnostic Pathology and Molecular Genetics of the Thyroid. 1st edition. Lippincott, Philadelphia, PA, pp 152–182.
449. Yamashita H, Noguchi S, Murakami N, Kawamoto H, Watanabe S 1997 Extracapsular invasion of lymph node metastasis is an indicator of distant metastasis and poor prognosis in patients with thyroid papillary carcinoma. Cancer **80:**2268–2272.
450. Lango M, Flieder D, Arrangoiz R, Veloski C, Yu JQ, Li T, Burtness B, Mehra R, Galloway T, Ridge JA 2013 Extranodal extension of metastatic papillary thyroid carcinoma: correlation with biochemical endpoints, nodal persistence, and systemic disease progression. Thyroid **23:**1099–1105.
451. Falvo L, Catania A, D'Andrea V, Marzullo A, Giustiniani MC, De Antoni E 2005 Prognostic importance of histologic vascular invasion in papillary thyroid carcinoma. Ann Surg **241:**640–646.
452. Gardner RE, Tuttle RM, Burman KD, Haddady S, Truman C, Sparling YH, Wartofsky L, Sessions RB, Ringel MD 2000 Prognostic importance of vascular invasion in papillary thyroid carcinoma. Arch Otolaryngol Head Neck Surg **126:**309–312.
453. Mete O, Asa SL 2011 Pathological definition and clinical significance of vascular invasion in thyroid carcinomas of follicular epithelial derivation. Mod Pathol **24:**1545–1552.
454. Brennan MD, Bergstralh EJ, van Heerden JA, McConahey WM 1991 Follicular thyroid cancer treated at the Mayo Clinic, 1946 through 1970: initial manifestations, pathologic findings, therapy, and outcome. Mayo Clin Proc **66:**11–22.
455. Collini P, Sampietro G, Pilotti S 2004 Extensive vascular invasion is a marker of risk of relapse in encapsulated non-Hürthle cell follicular carcinoma of the thyroid gland: a clinicopathological study of 18 consecutive cases from a single institution with a 11-year median follow-up. Histopathology **44:**35–39.
456. Lang W, Choritz H, Hundeshagen H 1986 Risk factors in follicular thyroid carcinomas. A retrospective follow-up study covering a 14-year period with emphasis on morphological findings. Am J Surg Pathol **10:**246–255.
457. Nikiforov YE, Ohori NP 2012 Papillary carcinoma. In: Nikiforov YE, Biddinger PW, Thompson LDR (eds) Diagnostic Pathology and Molecular Genetics of the Thyroid. 1st edition. Lippincott, Philadelphia, PA, pp 183–262.
458. Hawk WA, Hazard JB 1976 The many appearances of papillary carcinoma of the thyroid. Cleve Clin Q **43:**207–215.
459. Leung AK, Chow SM, Law SC 2008 Clinical features and outcome of the tall cell variant of papillary thyroid carcinoma. Laryngoscope **118:**32–38.
460. Moreno EA, Rodriguez Gonzalez JM, Sola PJ, Soria CT, Parrilla PP 1993 Prognostic value of the tall cell variety of papillary cancer of the thyroid. Eur J Surg Oncol **19:**517–521.
461. Ostrowski ML, Merino MJ 1996 Tall cell variant of papillary thyroid carcinoma: a reassessment and immunohistochemical study with comparison to the usual type of papillary carcinoma of the thyroid. Am J Surg Pathol **20:**964–974.
462. Johnson TL, Lloyd RV, Thompson NW, Beierwaltes WH, Sisson JC 1988 Prognostic implications of the tall cell variant of papillary thyroid carcinoma. Am J Surg Pathol **12:**22–27.
463. Michels JJ, Jacques M, Henry-Amar M, Bardet S 2007 Prevalence and prognostic significance of tall cell variant of papillary thyroid carcinoma. Hum Pathol **38:**212–219.
464. Ghossein RA, Leboeuf R, Patel KN, Rivera M, Katabi N, Carlson DL, Tallini G, Shaha A, Singh B, Tuttle RM 2007 Tall cell variant of papillary thyroid carcinoma without extrathyroid extension: biologic behavior and clinical implications. Thyroid **17:**655–661.
465. Morris LG, Shaha AR, Tuttle RM, Sikora AG, Ganly I 2010 Tall-cell variant of papillary thyroid carcinoma: a matched-pair analysis of survival. Thyroid **20:**153–158.
466. Xing M 2005 BRAF mutation in thyroid cancer. Endocr Relat Cancer **12:**245–262.
467. Chen JH, Faquin WC, Lloyd RV, Nose V 2011 Clinicopathological and molecular characterization of nine cases of columnar cell variant of papillary thyroid carcinoma. Mod Pathol **24:**739–749.
468. Evans HL 1986 Columnar-cell carcinoma of the thyroid. A report of two cases of an aggressive variant of thyroid carcinoma. Am J Clin Pathol **85:**77–80.
469. Evans HL 1996 Encapsulated columnar-cell neoplasms of the thyroid. A report of four cases suggesting a favorable prognosis. Am J Surg Pathol **20:**1205–1211.
470. Wenig BM, Thompson LD, Adair CF, Shmookler B, Heffess CS 1998 Thyroid papillary carcinoma of columnar cell type: a clinicopathologic study of 16 cases. Cancer **82:**740–753.
471. Asioli S, Erickson LA, Sebo TJ, Zhang J, Jin L, Thompson GB, Lloyd RV 2010 Papillary thyroid carcinoma with prominent hobnail features: a new aggressive variant of moderately differentiated papillary carcinoma. A clinicopathologic, immunohistochemical, and molecular study of eight cases. Am J Surg Pathol **34:**44–52.
472. Motosugi U, Murata S, Nagata K, Yasuda M, Shimizu M 2009 Thyroid papillary carcinoma with micropapillary and hobnail growth pattern: a histological variant with intermediate malignancy? Thyroid **19:**535–537.
473. Lubitz CC, Economopoulos KP, Pawlak AC, Lynch K, Dias-Santagata D, Faquin WC, Sadow PM 2014 Hobnail variant of papillary thyroid carcinoma: an institutional case series and molecular profile. Thyroid **24:**958–965.
474. Mizukami Y, Noguchi M, Michigishi T, Nonomura A, Hashimoto T, Otakes S, Nakamura S, Matsubara F 1992 Papillary thyroid carcinoma in Kanazawa, Japan: prognostic significance of histological subtypes. Histopathology **20:**243–250.
475. Nikiforov YE, Erickson LA, Nikiforova MN, Caudill CM, Lloyd RV 2001 Solid variant of papillary thyroid carcinoma: incidence, clinical-pathologic characteristics, molecular analysis, and biologic behavior. Am J Surg Pathol **25:**1478–1484.
476. Cardis E, Howe G, Ron E, Bebeshko V, Bogdanova T, Bouville A, Carr Z, Chumak V, Davis S, Demidchik Y, Drozdovitch V, Gentner N, Gudzenko N, Hatch M, Ivanov V, Jacob P, Kapitonova E, Kenigsberg Y, Kesminiene A, Kopecky KJ, Kryuchkov V, Loos A, Pinchera A, Reiners C, Repacholi M, Shibata Y, Shore RE, Thomas G, Tirmarche M, Yamashita S, Zvonova I 2006 Cancer consequences of the Chernobyl accident: 20 years on. J Radiol Prot **26:**127–140.

Downloaded by Memorial Sloan Kettering from www.liebertpub.com at 08/14/19. For personal use only.

477. Nikiforov YE 2006 Radiation-induced thyroid cancer: what we have learned from Chernobyl. Endocr Pathol **17:**307–317.
478. Volante M, Collini P, Nikiforov YE, Sakamoto A, Kakudo K, Katoh R, Lloyd RV, LiVolsi VA, Papotti M, Sobrinho-Simoes M, Bussolati G, Rosai J 2007 Poorly differentiated thyroid carcinoma: the Turin proposal for the use of uniform diagnostic criteria and an algorithmic diagnostic approach. Am J Surg Pathol **31:**1256–1264.
479. Asioli S, Erickson LA, Righi A, Jin L, Volante M, Jenkins S, Papotti M, Bussolati G, Lloyd RV 2010 Poorly differentiated carcinoma of the thyroid: validation of the Turin proposal and analysis of IMP3 expression. Mod Pathol **23:**1269–1278.
480. Fukushima M, Ito Y, Hirokawa M, Akasu H, Shimizu K, Miyauchi A 2009 Clinicopathologic characteristics and prognosis of diffuse sclerosing variant of papillary thyroid carcinoma in Japan: an 18-year experience at a single institution. World J Surg **33:**958–962.
481. Koo JS, Hong S, Park CS 2009 Diffuse sclerosing variant is a major subtype of papillary thyroid carcinoma in the young. Thyroid **19:**1225–1231.
482. Regalbuto C, Malandrino P, Tumminia A, Le Moli R, Vigneri R, Pezzino V 2011 A diffuse sclerosing variant of papillary thyroid carcinoma: clinical and pathologic features and outcomes of 34 consecutive cases. Thyroid **21:**383–389.
483. Lam AK, Lo CY 2006 Diffuse sclerosing variant of papillary carcinoma of the thyroid: a 35-year comparative study at a single institution. Ann Surg Oncol **13:** 176–181.
484. Rivera M, Ricarte-Filho J, Knauf J, Shaha A, Tuttle M, Fagin JA, Ghossein RA 2010 Molecular genotyping of papillary thyroid carcinoma follicular variant according to its histological subtypes (encapsulated vs infiltrative) reveals distinct BRAF and RAS mutation patterns. Mod Pathol **23:**1191–1200.
485. Howitt BE, Jia Y, Sholl LM, Barletta JA 2013 Molecular alterations in partially-encapsulated or well-circumscribed follicular variant of papillary thyroid carcinoma. Thyroid **23:**1256–1262.
486. Liu J, Singh B, Tallini G, Carlson DL, Katabi N, Shaha A, Tuttle RM, Ghossein RA 2006 Follicular variant of papillary thyroid carcinoma: a clinicopathologic study of a problematic entity. Cancer **107:**1255–1264.
487. Piana S, Frasoldati A, Di Felice E, Gardini G, Tallini G, Rosai J 2010 Encapsulated well-differentiated follicular-patterned thyroid carcinomas do not play a significant role in the fatality rates from thyroid carcinoma. Am J Surg Pathol **34:**868–872.
488. Proietti A, Giannini R, Ugolini C, Miccoli M, Fontanini G, Di Coscio G, Romani R, Berti P, Miccoli P, Basolo F 2010 BRAF status of follicular variant of papillary thyroid carcinoma and its relationship to its clinical and cytological features. Thyroid **20:**1263–1270.
489. Chan J 2002 Strict criteria should be applied in the diagnosis of encapsulated follicular variant of papillary thyroid carcinoma. Am J Clin Pathol **117:**16–18.
490. Vivero M, Kraft S, Barletta JA 2013 Risk stratification of follicular variant of papillary thyroid carcinoma. Thyroid **23:**273–279.
491. Baloch ZW, LiVolsi VA 2000 Encapsulated follicular variant of papillary thyroid carcinoma with bone metastases. Mod Pathol **13:**861–865.
492. Hunt JL, Dacic S, Barnes EL, Bures JC 2002 Encapsulated follicular variant of papillary thyroid carcinoma. Am J Clin Pathol **118:**602–603.
493. Rivera M, Ricarte-Filho J, Patel S, Tuttle M, Shaha A, Shah JP, Fagin JA, Ghossein RA 2010 Encapsulated thyroid tumors of follicular cell origin with high grade features (high mitotic rate/tumor necrosis): a clinicopathologic and molecular study. Hum Pathol **41:**172–180.
494. O'Neill CJ, Vaughan L, Learoyd DL, Sidhu SB, Delbridge LW, Sywak MS 2011 Management of follicular thyroid carcinoma should be individualised based on degree of capsular and vascular invasion. Eur J Surg Oncol **37:**181–185.
495. van Heerden JA, Hay ID, Goellner JR, Salomao D, Ebersold JR, Bergstralh EJ, Grant CS 1992 Follicular thyroid carcinoma with capsular invasion alone: a nonthreatening malignancy. Surgery **112:**1130–1136.
496. Goldstein NS, Czako P, Neill JS 2000 Metastatic minimally invasive (encapsulated) follicular and Hürthle cell thyroid carcinoma: a study of 34 patients. Mod Pathol **13:**123–130.
497. Sugino K, Ito K, Nagahama M, Kitagawa W, Shibuya H, Ohkuwa K, Yano Y, Uruno T, Akaishi J, Kameyama K, Ito K 2011 Prognosis and prognostic factors for distant metastases and tumor mortality in follicular thyroid carcinoma. Thyroid **21:**751–757.
498. Sugino K, Kameyama K, Ito K, Nagahama M, Kitagawa W, Shibuya H, Ohkuwa K, Yano Y, Uruno T, Akaishi J, Suzuki A, Masaki C, Ito K 2012 Outcomes and prognostic factors of 251 patients with minimally invasive follicular thyroid carcinoma. Thyroid **22:**798–804.
499. Ghossein RA, Hiltzik DH, Carlson DL, Patel S, Shaha A, Shah JP, Tuttle RM, Singh B 2006 Prognostic factors of recurrence in encapsulated Hürthle cell carcinoma of the thyroid gland: a clinicopathologic study of 50 cases. Cancer **106:**1669–1676.
500. Huang CC, Hsueh C, Liu FH, Chao TC, Lin JD 2011 Diagnostic and therapeutic strategies for minimally and widely invasive follicular thyroid carcinomas. Surg Oncol **20:**1–6.
501. Lo CY, Chan WF, Lam KY, Wan KY 2005 Follicular thyroid carcinoma: the role of histology and staging systems in predicting survival. Ann Surg **242:**708–715.
502. Slade I, Bacchelli C, Davies H, Murray A, Abbaszadeh F, Hanks S, Barfoot R, Burke A, Chisholm J, Hewitt M, Jenkinson H, King D, Morland B, Pizer B, Prescott K, Saggar A, Side L, Traunecker H, Vaidya S, Ward P, Futreal PA, Vujanic G, Nicholson AG, Sebire N, Turnbull C, Priest JR, Pritchard-Jones K, Houlston R, Stiller C, Stratton MR, Douglas J, Rahman N 2011 DICER1 syndrome: clarifying the diagnosis, clinical features and management implications of a pleiotropic tumour predisposition syndrome. J Med Genet **48:**273–278.
503. Cetta F, Montalto G, Gori M, Curia MC, Cama A, Olschwang S 2000 Germline mutations of the APC gene in patients with familial adenomatous polyposis-associated thyroid carcinoma: results from a European cooperative study. J Clin Endocrinol Metab **85:**286–292.
504. Harach HR, Williams GT, Williams ED 1994 Familial adenomatous polyposis associated thyroid carcinoma: a distinct type of follicular cell neoplasm. Histopathology **25:**549–561.
505. Hirokawa M, Maekawa M, Kuma S, Miyauchi A 2010 Cribriform-morular variant of papillary thyroid carcino-

Downloaded by Memorial Sloan Kettering from www.liebertpub.com at 08/14/19. For personal use only.

ma—cytological and immunocytochemical findings of 18 cases. Diagn Cytopathol **38:**890–896.
506. Jung CK, Choi YJ, Lee KY, Bae JS, Kim HJ, Yoon SK, Son YI, Chung JH, Oh YL 2009 The cytological, clinical, and pathological features of the cribriform-morular variant of papillary thyroid carcinoma and mutation analysis of CTNNB1 and BRAF genes. Thyroid **19:**905–913.
507. Koo JS, Jung W, Hong SW 2011 Cytologic characteristics and beta-catenin immunocytochemistry on smear slide of cribriform-morular variant of papillary thyroid carcinoma. Acta Cytol **55:**13–18.
508. Ito Y, Miyauchi A, Ishikawa H, Hirokawa M, Kudo T, Tomoda C, Miya A 2011 Our experience of treatment of cribriform morular variant of papillary thyroid carcinoma; difference in clinicopathological features of FAP-associated and sporadic patients. Endocr J **58:** 685–689.
509. Hollander MC, Blumenthal GM, Dennis PA 2011 PTEN loss in the continuum of common cancers, rare syndromes and mouse models. Nat Rev Cancer **11:**289–301.
510. Laury AR, Bongiovanni M, Tille JC, Kozakewich H, Nose V 2011 Thyroid pathology in PTEN-hamartoma tumor syndrome: characteristic findings of a distinct entity. Thyroid **21:**135–144.
511. Nose V 2011 Familial thyroid cancer: a review. Mod Pathol **24(Suppl 2):**S19–S33.
512. Harach HR, Soubeyran I, Brown A, Bonneau D, Longy M 1999 Thyroid pathologic findings in patients with Cowden disease. Ann Diagn Pathol **3:**331–340.
513. Hemmings CT 2003 Thyroid pathology in four patients with Cowden's disease. Pathology **35:**311–314.
514. Volante M, Landolfi S, Chiusa L, Palestini N, Motta M, Codegone A, Torchio B, Papotti MG 2004 Poorly differentiated carcinomas of the thyroid with trabecular, insular, and solid patterns: a clinicopathologic study of 183 patients. Cancer **100:**950–957.
515. Sakamoto A, Kasai N, Sugano H 1983 Poorly differentiated carcinoma of the thyroid. A clinicopathologic entity for a high-risk group of papillary and follicular carcinomas. Cancer **52:**1849–1855.
516. Carcangiu ML, Zampi G, Rosai J 1984 Poorly differentiated (''insular'') thyroid carcinoma. A reinterpretation of Langhans' ''wuchernde Struma''. Am J Surg Pathol **8:**655–668.
517. Pulcrano M, Boukheris H, Talbot M, Caillou B, Dupuy C, Virion A, De Vathaire F, Schlumberger M 2007 Poorly differentiated follicular thyroid carcinoma: prognostic factors and relevance of histological classification. Thyroid **17:**639–646.
518. Papotti M, Botto MF, Favero A, Palestini N, Bussolati G 1993 Poorly differentiated thyroid carcinomas with primordial cell component. A group of aggressive lesions sharing insular, trabecular, and solid patterns. Am J Surg Pathol **17:**291–301.
519. Decaussin M, Bernard MH, Adeleine P, Treilleux I, Peix JL, Pugeat M, Tourniaire J, Berger N 2002 Thyroid carcinomas with distant metastases: a review of 111 cases with emphasis on the prognostic significance of an insular component. Am J Surg Pathol **26:**1007–1015.
520. Hiltzik D, Carlson DL, Tuttle RM, Chuai S, Ishill N, Shaha A, Shah JP, Singh B, Ghossein RA 2006 Poorly differentiated thyroid carcinomas defined on the basis of mitosis and necrosis: a clinicopathologic study of 58 patients. Cancer **106:**1286–1295.
521. Gnemmi V, Renaud F, Do Cao C, Salleron J, Lion G, Wemeau JL, Copin MC, Carnaille B, Leteurtre E, Pattou F, Aubert S 2014 Poorly differentiated thyroid carcinomas: application of the Turin proposal provides prognostic results similar to those from the assessment of high-grade features. Histopathology **64:**263–273.
522. Sherman SI 1999 Toward a standard clinicopathologic staging approach for differentiated thyroid carcinoma. Semin Surg Oncol **16:**12–15.
523. Yang L, Shen W, Sakamoto N 2013 Population-based study evaluating and predicting the probability of death resulting from thyroid cancer and other causes among patients with thyroid cancer. J Clin Oncol **31:** 468–474.
524. Onitilo AA, Engel JM, Lundgren CI, Hall P, Thalib L, Doi SA 2009 Simplifying the TNM system for clinical use in differentiated thyroid cancer. J Clin Oncol **27:**1872–1878.
525. Mankarios D, Baade P, Youl P, Mortimer RH, Onitilo AA, Russell A, Doi SA 2013 Validation of the QTNM staging system for cancer-specific survival in patients with differentiated thyroid cancer. Endocrine **46:**300–308.
526. Sherman SI, Brierley JD, Sperling M, Ain KB, Bigos ST, Cooper DS, Haugen BR, Ho M, Klein I, Ladenson PW, Robbins J, Ross DS, Specker B, Taylor T, Maxon HR III 1998 Prospective multicenter study of thyroiscarcinoma treatment: initial analysis of staging and outcome. National Thyroid Cancer Treatment Cooperative Study Registry Group. Cancer **83:**1012–1021.
527. Lang BH, Chow SM, Lo CY, Law SC, Lam KY 2007 Staging systems for papillary thyroid carcinoma: a study of 2 tertiary referral centers. Ann Surg **246:**114–121.
528. Lang BH, Lo CY, Chan WF, Lam KY, Wan KY 2007 Staging systems for papillary thyroid carcinoma: a review and comparison. Ann Surg **245:**366–378.
529. Voutilainen PE, Siironen P, Franssila KO, Sivula A, Haapiainen RK, Haglund CH 2003 AMES, MACIS and TNM prognostic classifications in papillary thyroid carcinoma. Anticancer Res **23:**4283–4288.
530. Yildirim E 2005 A model for predicting outcomes in patients with differentiated thyroid cancer and model performance in comparison with other classification systems. J Am Coll Surg **200:**378–392.
531. Jonklaas J, Nogueras-Gonzalez G, Munsell M, Litofsky D, Ain KB, Bigos ST, Brierley JD, Cooper DS, Haugen BR, Ladenson PW, Magner J, Robbins J, Ross DS, Skarulis MC, Steward DL, Maxon HR, Sherman SI 2012 The impact of age and gender on papillary thyroid cancer survival. J Clin Endocrinol Metab **97:**E878–E887.
532. Bischoff LA, Curry J, Ahmed I, Pribitkin E, Miller JL 2013 Is above age 45 appropriate for upstaging well-differentiated papillary thyroid cancer? Endocr Pract **19:** 995–997.
533. Ganly I, Nixon IJ, Wang LY, Palmer FL, Migliacci JC, Aniss A, Sywak M, Eskander A, Freeman JL, Campbell MJ, Shen WT, Vaisman F, Momesso D, Corbo R, Vaisman M, Shaha AM, Tuttle RM, Shah JP, Patel SG 2015 Survival from differentiated thyroid cancer: what has age got to do with it? Thyroid **25:**1106–1114.
534. D'Avanzo A, Ituarte P, Treseler P, Kebebew E, Wu J, Wong M, Duh QY, Siperstein AE, Clark OH 2004 Prognostic scoring systems in patients with follicular thyroid cancer: a comparison of different staging systems in predicting the patient outcome. Thyroid **14:**453–458.

Downloaded by Memorial Sloan Kettering from www.liebertpub.com at 08/14/19. For personal use only.

535. Lang BH, Lo CY, Chan WF, Lam KY, Wan KY 2007 Staging systems for follicular thyroid carcinoma: application to 171 consecutive patients treated in a tertiary referral centre. Endocr Relat Cancer **14:**29–42.
536. Orlov S, Orlov D, Shaytzag M, Dowar M, Tabatabaie V, Dwek P, Yip J, Hu C, Freeman JL, Walfish PG 2009 Influence of age and primary tumor size on the risk for residual/recurrent well-differentiated thyroid carcinoma. Head Neck **31:**782–788.
537. Baek SK, Jung KY, Kang SM, Kwon SY, Woo JS, Cho SH, Chung EJ 2010 Clinical risk factors associated with cervical lymph node recurrence in papillary thyroid carcinoma. Thyroid **20:**147–152.
538. Tuttle RM, Tala H, Shah J, Leboeuf R, Ghossein R, Gonen M, Brokhin M, Omry G, Fagin JA, Shaha A 2010 Estimating risk of recurrence in differentiated thyroid cancer after total thyroidectomy and radioactive iodine remnant ablation: using response to therapy variables to modify the initial risk estimates predicted by the new American Thyroid Association staging system. Thyroid **20:**1341–1349.
539. Vaisman F, Momesso D, Bulzico DA, Pessoa CH, Dias F, Corbo R, Vaisman M, Tuttle RM 2012 Spontaneous remission in thyroid cancer patients after biochemical incomplete response to initial therapy. Clin Endocrinol (Oxf) **77:**132–138.
540. Pacini F, Schlumberger M, Dralle H, Elisei R, Smit JW, Wiersinga W 2006 European consensus for the management of patients with differentiated thyroid carcinoma of the follicular epithelium. Eur J Endocrinol **154:**787–803.
541. Camargo R, Corigliano S, Friguglietti C, Gauna A, Harach R, Munizaga F, Niepomniszcze H, Pitoia F, Pretell E, Vaisman M, Ward LS, Wohllk N, Tomimori E 2009 Latin American Thyroid Society recommendations for the management of thyroid nodules. Arq Bras Endocrinol Metabol **53:**1167–1175.
542. Castagna MG, Maino F, Cipri C, Belardini V, Theodoropoulou A, Cevenini G, Pacini F 2011 Delayed risk stratification, to include the response to initial treatment (surgery and radioiodine ablation), has better outcome predictivity in differentiated thyroid cancer patients. Eur J Endocrinol **165:**441–446.
543. Pitoia F, Bueno F, Urciuoli C, Abelleira E, Cross G, Tuttle RM 2013 Outcomes of patients with differentiated thyroid cancer risk-stratified according to the American Thyroid Association and Latin American Thyroid Society risk of recurrence classification systems. Thyroid **23:**1401–1407.
544. Schvartz C, Bonnetain F, Dabakuyo S, Gauthier M, Cueff A, Fieffe S, Pochart JM, Cochet I, Crevisy E, Dalac A, Papathanassiou D, Toubeau M 2012 Impact on overall survival of radioactive iodine in low-risk differentiated thyroid cancer patients. J Clin Endocrinol Metab **97:**1526–1535.
545. Durante C, Montesano T, Attard M, Torlontano M, Monzani F, Costante G, Meringolo D, Ferdeghini M, Tumino S, Lamartina L, Paciaroni A, Massa M, Giacomelli L, Ronga G, Filetti S 2012 Long-term surveillance of papillary thyroid cancer patients who do not undergo postoperative radioiodine remnant ablation: is there a role for serum thyroglobulin measurement? J Clin Endocrinol Metab **97:**2748–2753.
546. Kim KM, Park JB, Bae KS, Kim CB, Kang DR, Kang SJ 2013 Clinical prognostic index for recurrence of papillary thyroid carcinoma including intraoperative findings. Endocr J **60:**291–297.
547. Ito Y, Kudo T, Kihara M, Takamura Y, Kobayashi K, Miya A, Miyauchi A 2012 Prognosis of low-risk papillary thyroid carcinoma patients: its relationship with the size of primary tumors. Endocr J **59:**119–125.
548. Lee J, Song Y, Soh EY 2014 Prognostic significance of the number of metastatic lymph nodes to stratify the risk of recurrence. World J Surg **38:**858–862.
549. Clain JB, Scherl S, Dos RL, Turk A, Wenig BM, Mehra S, Karle WE, Urken ML 2014 Extrathyroidal extension predicts extranodal extension in patients with positive lymph nodes: an important association that may affect clinical management. Thyroid **24:**951–957.
550. Riemann B, Kramer JA, Schmid KW, Dralle H, Dietlein M, Schicha H, Sauerland C, Frankewitsch T, Schober O 2010 Risk stratification of patients with locally aggressive differentiated thyroid cancer. Results of the MSDS trial. Nuklearmedizin **49:**79–84.
551. Nixon IJ, Ganly I, Patel S, Palmer FL, Whitcher MM, Tuttle RM, Shaha AR, Shah JP 2011 The impact of microscopic extrathyroid extension on outcome in patients with clinical T1 and T2 well-differentiated thyroid cancer. Surgery **150:**1242–1249.
552. Jukkola A, Bloigu R, Ebeling T, Salmela P, Blanco G 2004 Prognostic factors in differentiated thyroid carcinomas and their implications for current staging classifications. Endocr Relat Cancer **11:**571–579.
553. Ito Y, Tomoda C, Uruno T, Takamura Y, Miya A, Kobayashi K, Matsuzuka F, Kuma K, Miyauchi A 2006 Prognostic significance of extrathyroid extension of papillary thyroid carcinoma: massive but not minimal extension affects the relapse-free survival. World J Surg **30:**780–786.
554. Radowsky JS, Howard RS, Burch HB, Stojadinovic A 2014 Impact of degree of extrathyroidal extension of disease on papillary thyroid cancer outcome. Thyroid **24:** 241–244.
555. Fukushima M, Ito Y, Hirokawa M, Miya A, Shimizu K, Miyauchi A 2010 Prognostic impact of extrathyroid extension and clinical lymph node metastasis in papillary thyroid carcinoma depend on carcinoma size. World J Surg **34:**3007–3014.
556. Baloch ZW, Shafique K, Flannagan M, LiVolsi VA 2010 Encapsulated classic and follicular variants of papillary thyroid carcinoma: comparative clinicopathologic study. Endocr Pract **16:**952–959.
557. Deleted.
558. Nishida T, Katayama S, Tsujimoto M 2002 The clinicopathological significance of histologic vascular invasion in differentiated thyroid carcinoma. Am J Surg **183:**80–86.
559. Akslen LA, Myking AO, Salvesen H, Varhaug JE 1992 Prognostic importance of various clinicopathological features in papillary thyroid carcinoma. Eur J Cancer **29A:**44–51.
560. Simpson WJ, McKinney SE, Carruthers JS, Gospodarowicz MK, Sutcliffe SB, Panzarella T 1987 Papillary and follicular thyroid cancer. Prognostic factors in 1,578 patients. Am J Med **83:**479–488.
561. Mai KT, Khanna P, Yazdi HM, Perkins DG, Veinot JP, Thomas J, Lamba M, Nair BD 2002 Differentiated thyroid carcinomas with vascular invasion: a comparative study of follicular, Hurthle cell and papillary thyroid carcinoma. Pathology **34:**239–244.

Downloaded by Memorial Sloan Kettering from www.liebertpub.com at 08/14/19. For personal use only.

562. Furlan JC, Bedard YC, Rosen IB 2004 Clinicopathologic significance of histologic vascular invasion in papillary and follicular thyroid carcinomas. J Am Coll Surg **198:** 341–348.
563. Tufano RP, Teixeira GV, Bishop J, Carson KA, Xing M 2012 BRAF mutation in papillary thyroid cancer and its value in tailoring initial treatment: a systematic review and meta-analysis. Medicine (Baltimore) **91:**274–286.
564. Xing M, Westra WH, Tufano RP, Cohen Y, Rosenbaum E, Rhoden KJ, Carson KA, Vasko V, Larin A, Tallini G, Tolaney S, Holt EH, Hui P, Umbricht CB, Basaria S, Ewertz M, Tufaro AP, Califano JA, Ringel MD, Zeiger MA, Sidransky D, Ladenson PW 2005 BRAF mutation predicts a poorer clinical prognosis for papillary thyroid cancer. J Clin Endocrinol Metab **90:**6373–6379.
565. Elisei R, Viola D, Torregrossa L, Giannini R, Romei C, Ugolini C, Molinaro E, Agate L, Biagini A, Lupi C, Valerio L, Materazzi G, Miccoli P, Piaggi P, Pinchera A, Vitti P, Basolo F 2012 The BRAF(V600E) mutation is an independent, poor prognostic factor for the outcome of patients with low-risk intrathyroid papillary thyroid carcinoma: single-institution results from a large cohort study. J Clin Endocrinol Metab **97:**4390–4398.
566. Kim TY, Kim WB, Rhee YS, Song JY, Kim JM, Gong G, Lee S, Kim SY, Kim SC, Hong SJ, Shong YK 2006 The BRAF mutation is useful for prediction of clinical recurrence in low-risk patients with conventional papillary thyroid carcinoma. Clin Endocrinol (Oxf) **65:**364–368.
567. Li C, Lee KC, Schneider EB, Zeiger MA 2012 $BRAF^{V600E}$ mutation and its association with clinicopathological features of papillary thyroid cancer: a meta-analysis. J Clin Endocrinol Metab **97:**4559–4570.
568. Fernandez IJ, Piccin O, Sciascia S, Cavicchi O, Repaci A, Vicennati V, Fiorentino M 2013 Clinical significance of BRAF mutation in thyroid papillary cancer. Otolaryngol Head Neck Surg **148:**919–925.
569. Prescott JD, Sadow PM, Hodin RA, Le LP, Gaz RD, Randolph GW, Stephen AE, Parangi S, Daniels GH, Lubitz CC 2012 $BRAF^{V600E}$ status adds incremental value to current risk classification systems in predicting papillary thyroid carcinoma recurrence. Surgery **152:** 984–990.
570. Sedliarou I, Saenko V, Lantsov D, Rogounovitch T, Namba H, Abrosimov A, Lushnikov E, Kumagai A, Nakashima M, Meirmanov S, Mine M, Hayashi T, Yamashita S 2004 The BRAFT1796A transversion is a prevalent mutational event in human thyroid microcarcinoma. Int J Oncol **25:**1729–1735.
571. Xing M 2007 BRAF mutation in papillary thyroid cancer: pathogenic role, molecular bases, and clinical implications. Endocr Rev **28:**742–762.
572. Park YJ, Kim YA, Lee YJ, Kim SH, Park SY, Kim KW, Chung JK, Youn YK, Kim KH, Park do J, Cho BY 2010 Papillary microcarcinoma in comparison with larger papillary thyroid carcinoma in BRAF(V600E) mutation, clinicopathological features, and immunohistochemical findings. Head Neck **32:**38–45.
573. Namba H, Nakashima M, Hayashi T, Hayashida N, Maeda S, Rogounovitch TI, Ohtsuru A, Saenko VA, Kanematsu T, Yamashita S 2003 Clinical implication of hot spot BRAF mutation, V599E, in papillary thyroid cancers. J Clin Endocrinol Metab **88:**4393–4397.
574. Kwak JY, Kim EK, Chung WY, Moon HJ, Kim MJ, Choi JR 2009 Association of BRAFV600E mutation with poor clinical prognostic factors and US features in Korean patients with papillary thyroid microcarcinoma. Radiology **253:**854–860.
575. Rodolico V, Cabibi D, Pizzolanti G, Richiusa P, Gebbia N, Martorana A, Russo A, Amato MC, Galluzzo A, Giordano C 2007 $BRAF^{V600E}$ mutation and p27 kip1 expression in papillary carcinomas of the thyroid <or= 1 cm and their paired lymph node metastases. Cancer **110:**1218–1226.
576. Kimura ET, Nikiforova MN, Zhu Z, Knauf JA, Nikiforov YE, Fagin JA 2003 High prevalence of BRAF mutations in thyroid cancer: genetic evidence for constitutive activation of the RET/PTC-RAS-BRAF signaling pathway in papillary thyroid carcinoma. Cancer Res **63:**1454–1457.
577. Henderson YC, Shellenberger TD, Williams MD, El-Naggar AK, Fredrick MJ, Cieply KM, Clayman GL 2009 High rate of BRAF and RET/PTC dual mutations associated with recurrent papillary thyroid carcinoma. Clin Cancer Res **15:**485–491.
578. Nikiforova MN, Wald AI, Roy S, Durso MB, Nikiforov YE 2013 Targeted next-generation sequencing panel (ThyroSeq) for detection of mutations in thyroid cancer. J Clin Endocrinol Metab **98:**E1852-E1860.
579. Liu X, Bishop J, Shan Y, Pai S, Liu D, Murugan AK, Sun H, El-Naggar AK, Xing M 2013 Highly prevalent TERT promoter mutations in aggressive thyroid cancers. Endocr Relat Cancer **20:**603–610.
580. Landa I, Ganly I, Chan TA, Mitsutake N, Matsuse M, Ibrahimpasic T, Ghossein RA, Fagin JA 2013 Frequent somatic TERT promoter mutations in thyroid cancer: higher prevalence in advanced forms of the disease. J Clin Endocrinol Metab **98:**E1562–E1566.
581. Liu X, Qu S, Liu R, Sheng C, Shi X, Zhu G, Murugan AK, Guan H, Yu H, Wang Y, Sun H, Shan Z, Teng W, Xing M 2014 TERT promoter mutations and their association with $BRAF^{V600E}$ mutation and aggressive clinicopathological characteristics of thyroid cancer. J Clin Endocrinol Metab **99:**E1130–E1136.
582. Tuttle RM, Leboeuf R 2008 Follow up approaches in thyroid cancer: a risk adapted paradigm. Endocrinol Metab Clin North Am **37:**419–435, ix–x.
583. Schlumberger M, Berg G, Cohen O, Duntas L, Jamar F, Jarzab B, Limbert E, Lind P, Pacini F, Reiners C, Sanchez FF, Toft A, Wiersinga WM 2004 Follow-up of low-risk patients with differentiated thyroid carcinoma: a European perspective. Eur J Endocrinol **150:**105–112.
584. Tuttle RM 2008 Risk-adapted management of thyroid cancer. Endocr Pract **14:**764–774.
585. Deleted.
586. Berger F, Friedrich U, Knesewitsch P, Hahn K 2011 Diagnostic 131I whole-body scintigraphy 1 year after thyroablative therapy in patients with differentiated thyroid cancer: correlation of results to the individual risk profile and long-term follow-up. Eur J Nucl Med Mol Imaging **38:**451–458.
587. Malandrino P, Latina A, Marescalco S, Spadaro A, Regalbuto C, Fulco RA, Scollo C, Vigneri R, Pellegriti G 2011 Risk-adapted management of differentiated thyroid cancer assessed by a sensitive measurement of basal serum thyroglobulin. J Clin Endocrinol Metab **96:**1703–1709.
588. Soyluk O, Boztepe H, Aral F, Alagol F, Ozbey NC 2011 Papillary thyroid carcinoma patients assessed to be at

Downloaded by Memorial Sloan Kettering from www.liebertpub.com at 08/14/19. For personal use only.

low or intermediary risk after primary treatment are at greater risk of long term recurrence if they are thyroglobulin antibody positive or do not have distinctly low thyroglobulin at initial assessment. Thyroid **21:**1301–1308.

589. Piccardo A, Arecco F, Morbelli S, Bianchi P, Barbera F, Finessi M, Corvisieri S, Pestarino E, Foppiani L, Villavecchia G, Cabria M, Orlandi F 2010 Low thyroglobulin concentrations after thyroidectomy increase the prognostic value of undetectable thyroglobulin levels on levo-thyroxine suppressive treatment in low-risk differentiated thyroid cancer. J Endocrinol Invest **33:**83–87.
590. Castagna MG, Brilli L, Pilli T, Montanaro A, Cipri C, Fioravanti C, Sestini F, Capezzone M, Pacini F 2008 Limited value of repeat recombinant human thyrotropin (rhTSH)-stimulated thyroglobulin testing in differentiated thyroid carcinoma patients with previous negative rhTSH-stimulated thyroglobulin and undetectable basal serum thyroglobulin levels. J Clin Endocrinol Metab **93:**76–81.
591. Kloos RT, Mazzaferri EL 2005 A single recombinant human thyrotropin-stimulated serum thyroglobulin measurement predicts differentiated thyroid carcinoma metastases three to five years later. J Clin Endocrinol Metab **90:**5047–5057.
592. Kloos RT 2010 Thyroid cancer recurrence in patients clinically free of disease with undetectable or very low serum thyroglobulin values. J Clin Endocrinol Metab **95:**5241–5248.
593. Han JM, Kim WB, Yim JH, Kim WG, Kim TY, Ryu JS, Gong G, Sung TY, Yoon JH, Hong SJ, Kim EY, Shong YK 2012 Long-term clinical outcome of differentiated thyroid cancer patients with undetectable stimulated thyroglobulin level one year after initial treatment. Thyroid **22:**784–790.
594. Rosario PW, Furtado MS, Mineiro Filho AF, Lacerda RX, Calsolari MR 2012 Value of repeat stimulated thyroglobulin testing in patients with differentiated thyroid carcinoma considered to be free of disease in the first year after ablation. Thyroid **22:**482–486.
595. Brassard M, Borget I, Edet-Sanson A, Giraudet AL, Mundler O, Toubeau M, Bonichon F, Borson-Chazot F, Leenhardt L, Schvartz C, Dejax C, Brenot-Rossi I, Toubert ME, Torlontano M, Benhamou E, Schlumberger M 2011 Long-term follow-up of patients with papillary and follicular thyroid cancer: a prospective study on 715 patients. J Clin Endocrinol Metab **96:**1352–1359.
596. Pelttari H, Valimaki MJ, Loyttyniemi E, Schalin-Jantti C 2010 Post-ablative serum thyroglobulin is an independent predictor of recurrence in low-risk differentiated thyroid carcinoma: a 16-year follow-up study. Eur J Endocrinol **163:**757–763.
597. Klubo-Gwiezdzinska J, Burman KD, Van Nostrand D, Wartofsky L 2011 Does an undetectable rhTSH-stimulated Tg level 12 months after initial treatment of thyroid cancer indicate remission? Clin Endocrinol (Oxf) **74:**111–117.
598. Crocetti U, Durante C, Attard M, Maniglia A, Tumino S, Bruno R, Bonfitto N, Dicembrino F, Varraso A, Meringolo D, Filetti S, Trischitta V, Torlontano M 2008 Predictive value of recombinant human TSH stimulation and neck ultrasonography in differentiated thyroid cancer patients. Thyroid **18:**1049–1053.
599. Torlontano M, Attard M, Crocetti U, Tumino S, Bruno R, Costante G, D'Azzo G, Meringolo D, Ferretti E, Sacco R, Arturi F, Filetti S 2004 Follow-up of low risk patients with papillary thyroid cancer: role of neck ultrasonography in detecting lymph node metastases. J Clin Endocrinol Metab **89:**3402–3407.
600. Verburg FA, Stokkel MP, Duren C, Verkooijen RB, Mader U, van Isselt JW, Marlowe RJ, Smit JW, Reiners C, Luster M 2010 No survival difference after successful (131)I ablation between patients with initially low-risk and high-risk differentiated thyroid cancer. Eur J Nucl Med Mol Imaging **37:**276–283.
601. Giovanella L, Maffioli M, Ceriani L, De PD, Spriano G 2009 Unstimulated high sensitive thyroglobulin measurement predicts outcome of differentiated thyroid carcinoma. Clin Chem Lab Med **47:**1001–1004.
602. Momesso DP, Tuttle RM 2014 Update on differentiated thyroid cancer staging. Endocrinol Metab Clin North Am **43:**401–421.
603. Lemb J, Hufner M, Meller B, Homayounfar K, Sahlmann C, Meller J 2013 How reliable is secondary risk stratification with stimulated thyroglobulin in patients with differentiated thyroid carcinoma? Results from a retrospective study. Nuklearmedizin **52:**88–96.
604. Nascimento C, Borget I, Al Ghuzlan A, Deandreis D, Chami L, Travagli JP, Hartl D, Lumbroso J, Chougnet C, Lacroix L, Baudin E, Schlumberger M, Leboulleux S 2011 Persistent disease and recurrence in differentiated thyroid cancer patients with undetectable postoperative stimulated thyroglobulin level. Endocr Relat Cancer **18:**R29–R40.
605. Webb RC, Howard RS, Stojadinovic A, Gaitonde DY, Wallace MK, Ahmed J, Burch HB 2012 The utility of serum thyroglobulin measurement at the time of remnant ablation for predicting disease-free status in patients with differentiated thyroid cancer: a meta-analysis involving 3947 patients. J Clin Endocrinol Metab **97:**2754–2763.
606. Chindris AM, Diehl NN, Crook JE, Fatourechi V, Smallridge RC 2012 Undetectable sensitive serum thyroglobulin (<0.1 ng/mL) in 163 patients with follicular cell-derived thyroid cancer: results of rhTSH stimulation and neck ultrasonography and long-term biochemical and clinical follow-up. J Clin Endocrinol Metab **97:**2714–2723.
607. Vaisman F, Tala H, Grewal R, Tuttle RM 2011 In differentiated thyroid cancer, an incomplete structural response to therapy is associated with significantly worse clinical outcomes than only an incomplete thyroglobulin response. Thyroid **21:**1317–1322.
608. Verburg FA, Luster M, Cupini C, Chiovato L, Duntas L, Elisei R, Feldt-Rasmussen U, Rimmele H, Seregni E, Smit JW, Theimer C, Giovanella L 2013 Implications of thyroglobulin antibody positivity in patients with differentiated thyroid cancer: a clinical position statement. Thyroid **23:**1211–1225.
609. Spencer CA, Takeuchi M, Kazarosyan M, Wang CC, Guttler RB, Singer PA, Fatemi S, LoPresti JS, Nicoloff JT 1998 Serum thyroglobulin autoantibodies: prevalence, influence on serum thyroglobulin measurement, and prognostic significance in patients with differentiated thyroid carcinoma. J Clin Endocrinol Metab **83:**1121–1127.
610. Chung JK, Park YJ, Kim TY, So Y, Kim SK, Park DJ, Lee DS, Lee MC, Cho BY 2002 Clinical significance of elevated level of serum antithyroglobulin antibody in patients with differentiated thyroid cancer after thyroid ablation. Clin Endocrinol (Oxf) **57:**215–221.

Downloaded by Memorial Sloan Kettering from www.liebertpub.com at 08/14/19. For personal use only.

611. Gorges R, Maniecki M, Jentzen W, Sheu SN, Mann K, Bockisch A, Janssen OE 2005 Development and clinical impact of thyroglobulin antibodies in patients with differentiated thyroid carcinoma during the first 3 years after thyroidectomy. Eur J Endocrinol **153:**49–55.
612. Seo JH, Lee SW, Ahn BC, Lee J 2010 Recurrence detection in differentiated thyroid cancer patients with elevated serum level of antithyroglobulin antibody: special emphasis on using (18)F-FDG PET/CT. Clin Endocrinol (Oxf) **72:**558–563.
613. Adil A, Jafri RA, Waqar A, Abbasi SA, Matiul H, Asghar AH, Jilani A, Naz I 2003 Frequency and clinical importance of anti-Tg auto-antibodies (ATG). J Coll Physicians Surg Pak **13:**504–506.
614. Kim WG, Yoon JH, Kim WB, Kim TY, Kim EY, Kim JM, Ryu JS, Gong G, Hong SJ, Shong YK 2008 Change of serum antithyroglobulin antibody levels is useful for prediction of clinical recurrence in thyroglobulin-negative patients with differentiated thyroid carcinoma. J Clin Endocrinol Metab **93:**4683–4689.
615. Chiovato L, Latrofa F, Braverman LE, Pacini F, Capezzone M, Masserini L, Grasso L, Pinchera A 2003 Disappearance of humoral thyroid autoimmunity after complete removal of thyroid antigens. Ann Intern Med **139:**346–351.
616. Thomas D, Liakos V, Vassiliou E, Hatzimarkou F, Tsatsoulis A, Kaldrimides P 2007 Possible reasons for different pattern disappearance of thyroglobulin and thyroid peroxidase autoantibodies in patients with differentiated thyroid carcinoma following total thyroidectomy and iodine-131 ablation. J Endocrinol Invest **30:** 173–180.
617. Castagna MG, Tala Jury HP, Cipri C, Belardini V, Fioravanti C, Pasqui L, Sestini F, Theodoropoulou A, Pacini F 2011 The use of ultrasensitive thyroglobulin assays reduces but does not abolish the need for TSH stimulation in patients with differentiated thyroid carcinoma. J Endocrinol Invest **34:**e219-e223.
618. Baudin E, Do Cao C, Cailleux AF, Leboulleux S, Travagli JP, Schlumberger M 2003 Positive predictive value of serum thyroglobulin levels, measured during the first year of follow-up after thyroid hormone withdrawal, in thyroid cancer patients. J Clin Endocrinol Metab **88:** 1107–1111.
619. Pineda JD, Lee T, Ain K, Reynolds JC, Robbins J 1995 Iodine-131 therapy for thyroid cancer patients with elevated thyroglobulin and negative diagnostic scan. J Clin Endocrinol Metab **80:**1488–1492.
620. Alzahrani AS, Mohamed G, Al Shammary A, Aldasouqi S, Abdal Salam S, Shoukri M 2005 Long-term course and predictive factors of elevated serum thyroglobulin and negative diagnostic radioiodine whole body scan in differentiated thyroid cancer. J Endocrinol Invest **28:**540–546.
621. Valadao MM, Rosario PW, Borges MA, Costa GB, Rezende LL, Padrao EL, Barroso AL, Purisch S 2006 Positive predictive value of detectable stimulated tg during the first year after therapy of thyroid cancer and the value of comparison with Tg-ablation and Tg measured after 24 months. Thyroid **16:**1145–1149.
622. Miyauchi A, Kudo T, Miya A, Kobayashi K, Ito Y, Takamura Y, Higashiyama T, Fukushima M, Kihara M, Inoue H, Tomoda C, Yabuta T, Masuoka H 2011 Prognostic impact of serum thyroglobulin doubling-time under thyrotropin suppression in patients with papillary thyroid carcinoma who underwent total thyroidectomy. Thyroid **21:**707–716.
623. Wong H, Wong KP, Yau T, Tang V, Leung R, Chiu J, Lang BH 2012 Is there a role for unstimulated thyroglobulin velocity in predicting recurrence in papillary thyroid carcinoma patients with detectable thyroglobulin after radioiodine ablation? Ann Surg Oncol **19:**3479–3485.
624. Padovani RP, Robenshtok E, Brokhin M, Tuttle RM 2012 Even without additional therapy, serum thyroglobulin concentrations often decline for years after total thyroidectomy and radioactive remnant ablation in patients with differentiated thyroid cancer. Thyroid **22:** 778–783.
625. Hsieh CJ, Wang PW 2014 Sequential changes of serum antithyroglobulin antibody levels are a good predictor of disease activity in thyroglobulin-negative patients with papillary thyroid carcinoma. Thyroid **24:**488–493.
626. Schuff KG, Weber SM, Givi B, Samuels MH, Andersen PE, Cohen JI 2008 Efficacy of nodal dissection for treatment of persistent/recurrent papillary thyroid cancer. Laryngoscope **118:**768–775.
627. Al-Saif O, Farrar WB, Bloomston M, Porter K, Ringel MD, Kloos RT 2010 Long-term efficacy of lymph node reoperation for persistent papillary thyroid cancer. J Clin Endocrinol Metab **95:**2187–2194.
628. Yim JH, Kim WB, Kim EY, Kim WG, Kim TY, Ryu JS, Gong G, Hong SJ, Shong YK 2011 The outcomes of first reoperation for locoregionally recurrent/persistent papillary thyroid carcinoma in patients who initially underwent total thyroidectomy and remnant ablation. J Clin Endocrinol Metab **96:**2049–2056.
629. Rondeau G, Fish S, Hann LE, Fagin JA, Tuttle RM 2011 Ultrasonographically detected small thyroid bed nodules identified after total thyroidectomy for differentiated thyroid cancer seldom show clinically significant structural progression. Thyroid **21:**845–853.
630. Giovanella L, Ceriani L, Suriano S, Ghelfo A, Maffioli M 2008 Thyroglobulin measurement before rhTSH-aided 131I ablation in detecting metastases from differentiated thyroid carcinoma. Clin Endocrinol (Oxf) **69:**659–663.
631. Giovanella L, Ceriani L, Ghelfo A, Keller F 2005 Thyroglobulin assay 4 weeks after thyroidectomy predicts outcome in low-risk papillary thyroid carcinoma. Clin Chem Lab Med **43:**843–847.
632. Phan HT, Jager PL, van der Wal JE, Sluiter WJ, Plukker JT, Dierckx RA, Wolffenbuttel BH, Links TP 2008 The follow-up of patients with differentiated thyroid cancer and undetectable thyroglobulin (Tg) and Tg antibodies during ablation. Eur J Endocrinol **158:**77–83.
633. Vaisman A, Orlov S, Yip J, Hu C, Lim T, Dowar M, Freeman JL, Walfish PG 2010 Application of post-surgical stimulated thyroglobulin for radioiodine remnant ablation selection in low-risk papillary thyroid carcinoma. Head Neck **32:**689–698.
634. Kim TY, Kim WB, Kim ES, Ryu JS, Yeo JS, Kim SC, Hong SJ, Shong YK 2005 Serum thyroglobulin levels at the time of 131I remnant ablation just after thyroidectomy are useful for early prediction of clinical recurrence in low-risk patients with differentiated thyroid carcinoma. J Clin Endocrinol Metab **90:**1440–1445.
635. Toubeau M, Touzery C, Arveux P, Chaplain G, Vaillant G, Berriolo A, Riedinger JM, Boichot C, Cochet A,

Downloaded by Memorial Sloan Kettering from www.liebertpub.com at 08/14/19. For personal use only.

Brunotte F 2004 Predictive value for disease progression of serum thyroglobulin levels measured in the postoperative period and after (131)I ablation therapy in patients with differentiated thyroid cancer. J Nucl Med **45:**988–994.

636. Piccardo A, Arecco F, Puntoni M, Foppiani L, Cabria M, Corvisieri S, Arlandini A, Altrinetti V, Bandelloni R, Orlandi F 2013 Focus on high-risk DTC patients: high postoperative serum thyroglobulin level is a strong predictor of disease persistence and is associated to progression-free survival and overall survival. Clin Nucl Med **38:**18–24.
637. Polachek A, Hirsch D, Tzvetov G, Grozinsky-Glasberg S, Slutski I, Singer J, Weinstein R, Shimon I, Benbassat CA 2011 Prognostic value of post-thyroidectomy thyroglobulin levels in patients with differentiated thyroid cancer. J Endocrinol Invest **34:**855–860.
638. Hall FT, Beasley NJ, Eski SJ, Witterick IJ, Walfish PG, Freeman JL 2003 Predictive value of serum thyroglobulin after surgery for thyroid carcinoma. Laryngoscope **113:**77–81.
639. Heemstra KA, Liu YY, Stokkel M, Kievit J, Corssmit E, Pereira AM, Romijn JA, Smit JW 2007 Serum thyroglobulin concentrations predict disease-free remission and death in differentiated thyroid carcinoma. Clin Endocrinol (Oxf) **66:**58–64.
640. Ronga G, Filesi M, Ventroni G, Vestri AR, Signore A 1999 Value of the first serum thyroglobulin level after total thyroidectomy for the diagnosis of metastases from differentiated thyroid carcinoma. Eur J Nucl Med **26:**1448–1452.
641. Lin JD, Huang MJ, Hsu BR, Chao TC, Hsueh C, Liu FH, Liou MJ, Weng HF 2002 Significance of postoperative serum thyroglobulin levels in patients with papillary and follicular thyroid carcinomas. J Surg Oncol **80:**45–51.
642. Ibrahimpasic T, Nixon IJ, Palmer FL, Whitcher MM, Tuttle RM, Shaha A, Patel SG, Shah JP, Ganly I 2012 Undetectable thyroglobulin after total thyroidectomy in patients with low- and intermediate-risk papillary thyroid cancer—is there a need for radioactive iodine therapy? Surgery **152:**1096–1105.
643. Avram AM, Fig LM, Frey KA, Gross MD, Wong KK 2013 Preablation 131-I scans with SPECT/CT in postoperative thyroid cancer patients: what is the impact on staging? J Clin Endocrinol Metab **98:**1163–1171.
644. Nascimento C, Borget I, Troalen F, Al Ghuzlan A, Deandreis D, Hartl D, Lumbroso J, Chougnet CN, Baudin E, Schlumberger M, Leboulleux S 2013 Ultrasensitive serum thyroglobulin measurement is useful for the follow-up of patients treated with total thyroidectomy without radioactive iodine ablation. Eur J Endocrinol **169:**689–693.
645. Rosario PW, Xavier AC, Calsolari MR 2011 Value of postoperative thyroglobulin and ultrasonography for the indication of ablation and 131I activity in patients with thyroid cancer and low risk of recurrence. Thyroid **21:**49–53.
646. Robenshtok E, Grewal RK, Fish S, Sabra M, Tuttle RM 2013 A low postoperative nonstimulated serum thyroglobulin level does not exclude the presence of radioactive iodine avid metastatic foci in intermediate-risk differentiated thyroid cancer patients. Thyroid **23:**436–442.
647. de Rosario PW, Guimaraes VC, Maia FF, Fagundes TA, Purisch S, Padrao EL, Rezende LL, Barroso AL 2005 Thyroglobulin before ablation and correlation with posttreatment scanning. Laryngoscope **115:**264–267.
648. Park EK, Chung JK, Lim IH, Park do J, Lee DS, Lee MC, Cho BY 2009 Recurrent/metastatic thyroid carcinomas false negative for serum thyroglobulin but positive by posttherapy I-131 whole body scans. Eur J Nucl Med Mol Imaging **36:**172–179.
649. Giovanella L, Suriano S, Ceriani L, Verburg FA 2011 Undetectable thyroglobulin in patients with differentiated thyroid carcinoma and residual radioiodine uptake on a postablation whole-body scan. Clin Nucl Med **36:**109–112.
650. Oyen WJ, Verhagen C, Saris E, van den Broek WJ, Pieters GF, Corsten FH 2000 Follow-up regimen of differentiated thyroid carcinoma in thyroidectomized patients after thyroid hormone withdrawal. J Nucl Med **41:**643–646.
651. Tamilia M, Al-Kahtani N, Rochon L, Hier MP, Payne RJ, Holcroft CA, Black MJ 2011 Serum thyroglobulin predicts thyroid remnant ablation failure with 30 mCi iodine-131 treatment in patients with papillary thyroid carcinoma. Nucl Med Commun **32:**212–220.
652. Bernier MO, Morel O, Rodien P, Muratet JP, Giraud P, Rohmer V, Jeanguillaume C, Bigorgne JC, Jallet P 2005 Prognostic value of an increase in the serum thyroglobulin level at the time of the first ablative radioiodine treatment in patients with differentiated thyroid cancer. Eur J Nucl Med Mol Imaging **32:**1418–1421.
653. Feldt-Rasmussen U, Petersen PH, Date J, Madsen CM 1982 Serum thyroglobulin in patients undergoing subtotal thyroidectomy for toxic and nontoxic goiter. J Endocrinol Invest **5:**161–164.
654. Feldt-Rasmussen U, Petersen PH, Nielsen H, Date J, Madsen CM 1978 Thyroglobulin of varying molecular sizes with different disappearance rates in plasma following subtotal thyroidectomy. Clin Endocrinol (Oxf) **9:**205–214.
655. Izumi M, Kubo I, Taura M, Yamashita S, Morimoto I, Ohtakara S, Okamoto S, Kumagai LF, Nagataki S 1986 Kinetic study of immunoreactive human thyroglobulin. J Clin Endocrinol Metab **62:**410–412.
656. Hocevar M, Auersperg M, Stanovnik L 1997 The dynamics of serum thyroglobulin elimination from the body after thyroid surgery. Eur J Surg Oncol **23:**208–210.
657. Gerfo PL, Colacchio T, Colacchio D, Feind C 1978 Serum clearance rates of immunologically reactive thyroglobulin. Cancer **42:**164–166.
658. Giovanella L, Ceriani L, Maffioli M 2010 Postsurgery serum thyroglobulin disappearance kinetic in patients with differentiated thyroid carcinoma. Head Neck **32:** 568–571.
659. Lee JI, Chung YJ, Cho BY, Chong S, Seok JW, Park SJ 2013 Postoperative-stimulated serum thyroglobulin measured at the time of 131I ablation is useful for the prediction of disease status in patients with differentiated thyroid carcinoma. Surgery **153:**828–835.
660. Lepoutre-Lussey C, Maddah D, Golmard JL, Russ G, Tissier F, Tresallet C, Menegaux F, Aurengo A, Leenhardt L 2014 Post-operative neck ultrasound and risk stratification in differentiated thyroid cancer patients with initial lymph node involvement. Eur J Endocrinol **170:**837–846.
661. Chen MK, Yasrebi M, Samii J, Staib LH, Doddamane I, Cheng DW 2012 The utility of I-123 pretherapy scan in

Downloaded by Memorial Sloan Kettering from www.liebertpub.com at 08/14/19. For personal use only.

I-131 radioiodine therapy for thyroid cancer. Thyroid **22:**304–309.
662. Van Nostrand D, Aiken M, Atkins F, Moreau S, Garcia C, Acio E, Burman K, Wartofsky L 2009 The utility of radioiodine scans prior to iodine 131 ablation in patients with well-differentiated thyroid cancer. Thyroid **19:**849–855.
663. Hu YH, Wang PW, Wang ST, Lee CH, Chen HY, Chou FF, Huang YE, Huang HH 2004 Influence of 131I diagnostic dose on subsequent ablation in patients with differentiated thyroid carcinoma: discrepancy between the presence of visually apparent stunning and the impairment of successful ablation. Nucl Med Commun **25:**793–797.
664. Morris LF, Waxman AD, Braunstein GD 2001 The nonimpact of thyroid stunning: remnant ablation rates in 131I-scanned and nonscanned individuals. J Clin Endocrinol Metab **86:**3507–3511.
665. Muratet JP, Daver A, Minier JF, Larra F 1998 Influence of scanning doses of iodine-131 on subsequent first ablative treatment outcome in patients operated on for differentiated thyroid carcinoma. J Nucl Med **39:**1546–1550.
666. Silberstein EB 2007 Comparison of outcomes after (123)I versus (131)I pre-ablation imaging before radioiodine ablation in differentiated thyroid carcinoma. J Nucl Med **48:**1043–1046.
667. Leger FA, Izembart M, Dagousset F, Barritault L, Baillet G, Chevalier A, Clerc J 1998 Decreased uptake of therapeutic doses of iodine-131 after 185-MBq iodine-131 diagnostic imaging for thyroid remnants in differentiated thyroid carcinoma. Eur J Nucl Med **25:**242–246.
668. Verkooijen RB, Verburg FA, van Isselt JW, Lips CJ, Smit JW, Stokkel MP 2008 The success rate of I-131 ablation in differentiated thyroid cancer: comparison of uptake-related and fixed-dose strategies. Eur J Endocrinol **159:**301–307.
669. Verburg FA, Verkooijen RB, Stokkel MP, van Isselt JW 2009 The success of 131I ablation in thyroid cancer patients is significantly reduced after a diagnostic activity of 40 MBq 131I. Nuklearmedizin **48:**138–142.
670. Yap BK, Murby B 2014 No adverse affect in clinical outcome using low preablation diagnostic (131)I activity in differentiated thyroid cancer: refuting thyroid-stunning effect. J Clin Endocrinol Metab **99:**2433–2440.
671. Jonklaas J, Sarlis NJ, Litofsky D, Ain KB, Bigos ST, Brierley JD, Cooper DS, Haugen BR, Ladenson PW, Magner J, Robbins J, Ross DS, Skarulis M, Maxon HR, Sherman SI 2006 Outcomes of patients with differentiated thyroid carcinoma following initial therapy. Thyroid **16:**1229–1242.
672. Jonklaas J, Cooper DS, Ain KB, Bigos T, Brierley JD, Haugen BR, Ladenson PW, Magner J, Ross DS, Skarulis MC, Steward DL, Maxon HR, Sherman SI 2010 Radioiodine therapy in patients with stage I differentiated thyroid cancer. Thyroid **20:**1423–1424.
673. Sacks W, Fung CH, Chang JT, Waxman A, Braunstein GD 2010 The effectiveness of radioactive iodine for treatment of low-risk thyroid cancer: a systematic analysis of the peer-reviewed literature from 1966 to April 2008. Thyroid **20:**1235–1245.
674. Sawka AM, Brierley JD, Tsang RW, Thabane L, Rotstein L, Gafni A, Straus S, Goldstein DP 2008 An updated systematic review and commentary examining the effectiveness of radioactive iodine remnant ablation in well-differentiated thyroid cancer. Endocrinol Metab Clin North Am **37:**457–480.
675. Lamartina L, Durante C, Filetti S, Cooper DS 2015 Low-risk differentiated thyroid cancer and radioiodine remnant ablation: a systematic review of the literature. J Clin Endocrinol Metab **100:**1748–1761.
676. Ross DS, Litofsky D, Ain KB, Bigos T, Brierley JD, Cooper DS, Haugen BR, Jonklaas J, Ladenson PW, Magner J, Robbins J, Skarulis MC, Steward DL, Maxon HR, Sherman SI 2009 Recurrence after treatment of micropapillary thyroid cancer. Thyroid **19:**1043–1048.
677. Kim HJ, Kim NK, Choi JH, Kim SW, Jin SM, Suh S, Bae JC, Min YK, Chung JH, Kim SW 2013 Radioactive iodine ablation does not prevent recurrences in patients with papillary thyroid microcarcinoma. Clin Endocrinol (Oxf) **78:**614–620.
678. Baudin E, Travagli JP, Ropers J, Mancusi F, Bruno-Bossio G, Caillou B, Cailleux AF, Lumbroso JD, Parmentier C, Schlumberger M 1998 Microcarcinoma of the thyroid gland: the Gustave-Roussy Institute experience. Cancer **83:**553–559.
679. Creach KM, Siegel BA, Nussenbaum B, Grigsby PW 2012 Radioactive iodine therapy decreases recurrence in thyroid papillary microcarcinoma. ISRN Endocrinol **2012:**816386.
680. Lin HW, Bhattacharyya N 2009 Survival impact of treatment options for papillary microcarcinoma of the thyroid. Laryngoscope **119:**1983–1987.
681. Kuo EJ, Roman SA, Sosa JA 2013 Patients with follicular and Hurthle cell microcarcinomas have compromised survival: a population level study of 22,738 patients. Surgery **154:**1246–1253.
682. Mallick U, Harmer C, Hackshaw A, Moss L 2012 Iodine or Not (IoN) for low-risk differentiated thyroid cancer: the next UK National Cancer Research Network randomised trial following HiLo. Clin Oncol (R Coll Radiol) **24:**159–161.
683. Kazaure HS, Roman SA, Sosa JA 2012 Aggressive variants of papillary thyroid cancer: incidence, characteristics and predictors of survival among 43,738 patients. Ann Surg Oncol **19:**1874–1880.
684. Kazaure HS, Roman SA, Sosa JA 2012 Insular thyroid cancer: a population-level analysis of patient characteristics and predictors of survival. Cancer **118:**3260–3267.
685. Ruel E, Thomas S, Dinan M, Perkins JM, Roman SA, Sosa JA 2015 Adjuvant radioactive iodine therapy is associated with improved survival for patients with intermediate-risk papillary thyroid cancer. J Clin Endocrinol Metab **100:**1529–1536.
686. Chow SM, Yau S, Kwan CK, Poon PC, Law SC 2006 Local and regional control in patients with papillary thyroid carcinoma: specific indications of external radiotherapy and radioactive iodine according to T and N categories in AJCC 6th edition. Endocr Relat Cancer **13:**1159–1172.
687. Podnos YD, Smith DD, Wagman LD, Ellenhorn JD 2007 Survival in patients with papillary thyroid cancer is not affected by the use of radioactive isotope. J Surg Oncol **96:**3–7.
688. Chakravarty D, Santos E, Ryder M, Knauf JA, Liao XH, West BL, Bollag G, Kolesnick R, Thin TH, Rosen N, Zanzonico P, Larson SM, Refetoff S, Ghossein R, Fagin JA 2011 Small-molecule MAPK inhibitors restore radioiodine incorporation in mouse thyroid cancers with conditional BRAF activation. J Clin Invest **121:**4700–4711.
689. Edmonds CJ, Hayes S, Kermode JC, Thompson BD 1977 Measurement of serum TSH and thyroid hormones in the

Downloaded by Memorial Sloan Kettering from www.liebertpub.com at 08/14/19. For personal use only.

management of treatment of thyroid carcinoma with radioiodine. Br J Radiol **50:**799–807.

690. Leboeuf R, Perron P, Carpentier AC, Verreault J, Langlois MF 2007 L-T3 preparation for whole-body scintigraphy: a randomized-controlled trial. Clin Endocrinol (Oxf) **67:**839–844.
691. Lee J, Yun MJ, Nam KH, Chung WY, Soh EY, Park CS 2010 Quality of life and effectiveness comparisons of thyroxine withdrawal, triiodothyronine withdrawal, and recombinant thyroid-stimulating hormone administration for low-dose radioiodine remnant ablation of differentiated thyroid carcinoma. Thyroid **20:**173–179.
692. Fallahi B, Beiki D, Takavar A, Fard-Esfahani A, Gilani KA, Saghari M, Eftekhari M 2012 Low versus high radioiodine dose in postoperative ablation of residual thyroid tissue in patients with differentiated thyroid carcinoma: a large randomized clinical trial. Nucl Med Commun **33:**275–282.
693. Goropoulos A, Karamoshos K, Christodoulou A, Ntitsias T, Paulou K, Samaras A, Xirou P, Efstratiou I 2004 Value of the cervical compartments in the surgical treatment of papillary thyroid carcinoma. World J Surg **28:**1275–1281.
694. Molinaro E, Giani C, Agate L, Biagini A, Pieruzzi L, Bianchi F, Brozzi F, Ceccarelli C, Viola D, Piaggi P, Vitti P, Pacini F, Elisei R 2013 Patients with differentiated thyroid cancer who underwent radioiodine thyroid remnant ablation with low-activity ^{131}I after either recombinant human TSH or thyroid hormone therapy withdrawal showed the same outcome after a 10-year follow-up. J Clin Endocrinol Metab **98:**2693–2700.
695. Prpic M, Dabelic N, Stanicic J, Jukic T, Milosevic M, Kusic Z 2012 Adjuvant thyroid remnant ablation in patients with differentiated thyroid carcinoma confined to the thyroid: a comparison of ablation success with different activities of radioiodine (I-131). Ann Nucl Med **26:**744–751.
696. Karam M, Gianoukakis A, Feustel PJ, Cheema A, Postal ES, Cooper JA 2003 Influence of diagnostic and therapeutic doses on thyroid remnant ablation rates. Nucl Med Commun **24:**489–495.
697. Robbins RJ, Driedger A, Magner J 2006 Recombinant human thyrotropin-assisted radioiodine therapy for patients with metastatic thyroid cancer who could not elevate endogenous thyrotropin or be withdrawn from thyroxine. Thyroid **16:**1121–1130.
698. Chianelli M, Todino V, Graziano FM, Panunzi C, Pace D, Guglielmi R, Signore A, Papini E 2009 Low-activity (2.0 GBq; 54 mCi) radioiodine post-surgical remnant ablation in thyroid cancer: comparison between hormone withdrawal and use of rhTSH in low-risk patients. Eur J Endocrinol **160:**431–436.
699. Mallick U, Harmer C, Yap B, Wadsley J, Clarke S, Moss L, Nicol A, Clark PM, Farnell K, McCready R, Smellie J, Franklyn JA, John R, Nutting CM, Newbold K, Lemon C, Gerrard G, Abdel-Hamid A, Hardman J, Macias E, Roques T, Whitaker S, Vijayan R, Alvarez P, Beare S, Forsyth S, Kadalayil L, Hackshaw A 2012 Ablation with low-dose radioiodine and thyrotropin alfa in thyroid cancer. N Engl J Med **366:**1674–1685.
700. Pacini F, Ladenson PW, Schlumberger M, Driedger A, Luster M, Kloos RT, Sherman S, Haugen B, Corone C, Molinaro E, Elisei R, Ceccarelli C, Pinchera A, Wahl RL, Leboulleux S, Ricard M, Yoo J, Busaidy NL, Delpassand E, Hanscheid H, Felbinger R, Lassmann M, Reiners C 2006 Radioiodine ablation of thyroid remnants after preparation with recombinant human thyrotropin in differentiated thyroid carcinoma: results of an international, randomized, controlled study. J Clin Endocrinol Metab **91:**926–932.
701. Schlumberger M, Catargi B, Borget I, Deandreis D, Zerdoud S, Bridji B, Bardet S, Leenhardt L, Bastie D, Schvartz C, Vera P, Morel O, Benisvy D, Bournaud C, Bonichon F, Dejax C, Toubert ME, Leboulleux S, Ricard M, Benhamou E 2012 Strategies of radioiodine ablation in patients with low-risk thyroid cancer. N Engl J Med **366:**1663–1673.
702. Taieb D, Sebag F, Cherenko M, Baumstarck-Barrau K, Fortanier C, Farman-Ara B, de Micco C, Vaillant J, Thomas S, Conte-Devolx B, Loundou A, Auquier P, Henry JF, Mundler O 2009 Quality of life changes and clinical outcomes in thyroid cancer patients undergoing radioiodine remnant ablation (RRA) with recombinant human TSH (rhTSH): a randomized controlled study. Clin Endocrinol (Oxf) **71:**115–123.
703. Emmanouilidis N, Muller JA, Jager MD, Kaaden S, Helfritz FA, Guner Z, Kespohl H, Knitsch W, Knapp WH, Klempnauer J, Scheumann GF 2009 Surgery and radioablation therapy combined: introducing a 1-week-condensed procedure bonding total thyroidectomy and radioablation therapy with recombinant human TSH. Eur J Endocrinol **161:**763–769.
704. Tu J, Wang S, Huo Z, Lin Y, Li X, Wang S 2014 Recombinant human thyrotropin-aided versus thyroid hormone withdrawal-aided radioiodine treatment for differentiated thyroid cancer after total thyroidectomy: a meta-analysis. Radiother Oncol **110:**25–30.
705. Pak K, Cheon GJ, Kang KW, Kim SJ, Kim IJ, Kim EE, Lee DS, Chung JK 2014 The effectiveness of recombinant human thyroid-stimulating hormone versus thyroid hormone withdrawal prior to radioiodine remnant ablation in thyroid cancer: a meta-analysis of randomized controlled trials. J Korean Med Sci **29:**811–817.
706. Elisei R, Schlumberger M, Driedger A, Reiners C, Kloos RT, Sherman SI, Haugen B, Corone C, Molinaro E, Grasso L, Leboulleux S, Rachinsky I, Luster M, Lassmann M, Busaidy NL, Wahl RL, Pacini F, Cho SY, Magner J, Pinchera A, Ladenson PW 2009 Follow-up of low-risk differentiated thyroid cancer patients who underwent radioiodine ablation of postsurgical thyroid remnants after either recombinant human thyrotropin or thyroid hormone withdrawal. J Clin Endocrinol Metab **94:**4171–4179.
707. Emmanouilidis N, Schrem H, Winkler M, Klempnauer J, Scheumann GF 2013 Long-term results after treatment of very low-, low-, and high-risk thyroid cancers in a combined setting of thyroidectomy and radio ablation therapy in euthyroidism. Int J Endocrinol **2013:**769473.
708. Hugo J, Robenshtok E, Grewal R, Larson S, Tuttle RM 2012 Recombinant human thyroid stimulating hormone-assisted radioactive iodine remnant ablation in thyroid cancer patients at intermediate to high risk of recurrence. Thyroid **22:**1007–1015.
709. Rosario PW, Mineiro Filho AF, Lacerda RX, Calsolari MR 2012 Long-term follow-up of at least five years after recombinant human thyrotropin compared to levothyroxine withdrawal for thyroid remnant ablation with radioactive iodine. Thyroid **22:**332–333.

Downloaded by Memorial Sloan Kettering from www.liebertpub.com at 08/14/19. For personal use only.

710. Pitoia F, Marlowe RJ, Abelleira E, Faure EN, Bueno F, Schwarzstein D, Lutfi RJ, Niepomniszcze H 2012 Radioiodine thyroid remnant ablation after recombinant human thyrotropin or thyroid hormone withdrawal in patients with high-risk differentiated thyroid cancer. J Thyroid Res **2012:**481568.
711. Bartenstein P, Calabuig EC, Maini CL, Mazzarotto R, Muros de Fuentes MA, Petrich T, Rodrigues FJ, Vallejo Casas JA, Vianello F, Basso M, Balaguer MG, Haug A, Monari F, Vano RS, Sciuto R, Magner J 2014 High-risk patients with differentiated thyroid cancer T4 primary tumors achieve remnant ablation equally well using rhTSH or thyroid hormone withdrawal. Thyroid **24:**480–487.
712. Tala H, Robbins R, Fagin JA, Larson SM, Tuttle RM 2011 Five-year survival is similar in thyroid cancer patients with distant metastases prepared for radioactive iodine therapy with either thyroid hormone withdrawal or recombinant human TSH. J Clin Endocrinol Metab **96:**2105–2111.
713. Klubo-Gwiezdzinska J, Burman KD, Van Nostrand D, Mete M, Jonklaas J, Wartofsky L 2012 Radioiodine treatment of metastatic thyroid cancer: relative efficacy and side effect profile of preparation by thyroid hormone withdrawal versus recombinant human thyrotropin. Thyroid **22:**310–317.
714. Maenpaa HO, Heikkonen J, Vaalavirta L, Tenhunen M, Joensuu H 2008 Low vs. high radioiodine activity to ablate the thyroid after thyroidectomy for cancer: a randomized study. PLoS One **3:**e1885.
715. Pilli T, Brianzoni E, Capoccetti F, Castagna MG, Fattori S, Poggiu A, Rossi G, Ferretti F, Guarino E, Burroni L, Vattimo A, Cipri C, Pacini F 2007 A comparison of 1850 (50 mCi) and 3700 MBq (100 mCi) 131-iodine administered doses for recombinant thyrotropin-stimulated postoperative thyroid remnant ablation in differentiated thyroid cancer. J Clin Endocrinol Metab **92:**3542–3546.
716. Zaman M, Toor R, Kamal S, Maqbool M, Habib S, Niaz K 2006 A randomized clinical trial comparing 50mCi and 100mCi of iodine-131 for ablation of differentiated thyroid cancers. J Pak Med Assoc **56:**353–356.
717. Kukulska A, Krajewska J, Gawkowska-Suwinska M, Puch Z, Paliczka-Cieslik E, Roskosz J, Handkiewicz-Junak D, Jarzab M, Gubala E, Jarzab B 2010 Radioiodine thyroid remnant ablation in patients with differentiated thyroid carcinoma (DTC): prospective comparison of long-term outcomes of treatment with 30, 60 and 100 mCi. Thyroid Res **3:**9.
718. Fang Y, Ding Y, Guo Q, Xing J, Long Y, Zong Z 2013 Radioiodine therapy for patients with differentiated thyroid cancer after thyroidectomy: direct comparison and network meta-analyses. J Endocrinol Invest **36:**896–902.
719. Ma C, Tang L, Fu H, Li J, Wang H 2013 rhTSH-aided low-activity versus high-activity regimens of radioiodine in residual ablation for differentiated thyroid cancer: a meta-analysis. Nucl Med Commun **34:**1150–1156.
720. Cheng W, Ma C, Fu H, Li J, Chen S, Wu S, Wang H 2013 Low- or high-dose radioiodine remnant ablation for differentiated thyroid carcinoma: a meta-analysis. J Clin Endocrinol Metab **98:**1353–1360.
721. Valachis A, Nearchou A 2013 High versus low radioiodine activity in patients with differentiated thyroid cancer: a meta-analysis. Acta Oncol **52:**1055–1061.
722. Verburg FA, Mader U, Reiners C, Hanscheid H 2014 Long term survival in DTC is worse after low-activity initial post-surgical I-131 therapy in both high and low risk patients. J Clin Endocrinol Metab **99:**4487–4496.
723. Castagna MG, Cevenini G, Theodoropoulou A, Maino F, Memmo S, Claudia C, Belardini V, Brianzoni E, Pacini F 2013 Post-surgical thyroid ablation with low or high radioiodine activities results in similar outcomes in intermediate risk differentiated thyroid cancer patients. Eur J Endocrinol **169:**23–29.
724. Han JM, Kim WG, Kim TY, Jeon MJ, Ryu JS, Song DE, Hong SJ, Shong YK, Kim WB 2014 Effects of low-dose and high-dose postoperative radioiodine therapy on the clinical outcome in patients with small differentiated thyroid cancer having microscopic extrathyroidal extension. Thyroid **24:**820–825.
725. Kruijff S, Aniss AM, Chen P, Sidhu SB, Delbridge LW, Robinson B, Clifton-Bligh RJ, Roach P, Gill AJ, Learoyd D, Sywak MS 2013 Decreasing the dose of radioiodine for remnant ablation does not increase structural recurrence rates in papillary thyroid carcinoma. Surgery **154:**1337–1344.
726. Sabra M, Grewal R, Ghossein RM, Tuttle RM 2014 Higher administered activities of radioactive iodine are associated with less structural persistent response in older, but not younger, papillary thyroid cancer patients with lateral neck lymph node metastases. Thyroid **24:**1088–1095.
727. Sawka AM, Ibrahim-Zada I, Galacgac P, Tsang RW, Brierley JD, Ezzat S, Goldstein DP 2010 Dietary iodine restriction in preparation for radioactive iodine treatment or scanning in well-differentiated thyroid cancer: a systematic review. Thyroid **20:**1129–1138.
728. Pluijmen MJ, Eustatia-Rutten C, Goslings BM, Stokkel MP, Arias AM, Diamant M, Romijn JA, Smit JW 2003 Effects of low-iodide diet on postsurgical radioiodide ablation therapy in patients with differentiated thyroid carcinoma. Clin Endocrinol (Oxf) **58:**428–435.
729. Morris LF, Wilder MS, Waxman AD, Braunstein GD 2001 Reevaluation of the impact of a stringent low-iodine diet on ablation rates in radioiodine treatment of thyroid carcinoma. Thyroid **11:**749–755.
730. Morsch EP, Vanacor R, Furlanetto TW, Schmid H 2011 Two weeks of a low-iodine diet are equivalent to 3 weeks for lowering urinary iodine and increasing thyroid radioactive iodine uptake. Thyroid **21:**61–67.
731. Tala Jury HP, Castagna MG, Fioravanti C, Cipri C, Brianzoni E, Pacini F 2010 Lack of association between urinary iodine excretion and successful thyroid ablation in thyroid cancer patients. J Clin Endocrinol Metab **95:**230–237.
732. Al Nozha OM, Vautour L, How J 2011 Life-threatening hyponatremia following a low-iodine diet: a case report and review of all reported cases. Endocr Pract **17:**e113-e117.
733. Sherman SI, Tielens ET, Sostre S, Wharam MD Jr, Ladenson PW 1994 Clinical utility of posttreatment radioiodine scans in the management of patients with thyroid carcinoma. J Clin Endocrinol Metab **78:**629–634.
734. Fatourechi V, Hay ID, Mullan BP, Wiseman GA, Eghbali-Fatourechi GZ, Thorson LM, Gorman CA 2000 Are posttherapy radioiodine scans informative and do they influence subsequent therapy of patients with differentiated thyroid cancer? Thyroid **10:**573–577.
735. Souza Rosario PW, Barroso AL, Rezende LL, Padrao EL, Fagundes TA, Penna GC, Purisch S 2004 Post I-131

Downloaded by Memorial Sloan Kettering from www.liebertpub.com at 08/14/19. For personal use only.

therapy scanning in patients with thyroid carcinoma metastases: an unnecessary cost or a relevant contribution? Clin Nucl Med **29:**795–798.
736. Spies WG, Wojtowicz CH, Spies SM, Shah AY, Zimmer AM 1989 Value of post-therapy whole-body I-131 imaging in the evaluation of patients with thyroid carcinoma having undergone high-dose I-131 therapy. Clin Nucl Med **14:**793–800.
737. Ciappuccini R, Heutte N, Trzepla G, Rame JP, Vaur D, Aide N, Bardet S 2011 Postablation (131)I scintigraphy with neck and thorax SPECT-CT and stimulated serum thyroglobulin level predict the outcome of patients with differentiated thyroid cancer. Eur J Endocrinol **164:**961–969.
738. Salvatori M, Perotti G, Villani MF, Mazza R, Maussier ML, Indovina L, Sigismondi A, Dottorini ME, Giordano A 2013 Determining the appropriate time of execution of an I-131 post-therapy whole-body scan: comparison between early and late imaging. Nucl Med Commun **34:**900–908.
739. Kohlfuerst S, Igerc I, Lobnig M, Gallowitsch HJ, Gomez-Segovia I, Matschnig S, Mayr J, Mikosch P, Beheshti M, Lind P 2009 Posttherapeutic (131)I SPECT-CT offers high diagnostic accuracy when the findings on conventional planar imaging are inconclusive and allows a tailored patient treatment regimen. Eur J Nucl Med Mol Imaging **36:**886–893.
740. Chen L, Luo Q, Shen Y, Yu Y, Yuan Z, Lu H, Zhu R 2008 Incremental value of 131I SPECT/CT in the management of patients with differentiated thyroid carcinoma. J Nucl Med **49:**1952–1957.
741. Schmidt D, Linke R, Uder M, Kuwert T 2010 Five months' follow-up of patients with and without iodine-positive lymph node metastases of thyroid carcinoma as disclosed by (131)I-SPECT/CT at the first radioablation. Eur J Nucl Med Mol Imaging **37:**699–705.
742. Maruoka Y, Abe K, Baba S, Isoda T, Sawamoto H, Tanabe Y, Sasaki M, Honda H 2012 Incremental diagnostic value of SPECT/CT with 131I scintigraphy after radioiodine therapy in patients with well-differentiated thyroid carcinoma. Radiology **265:**902–909.
743. Grewal RK, Tuttle RM, Fox J, Borkar S, Chou JF, Gonen M, Strauss HW, Larson SM, Schoder H 2010 The effect of posttherapy 131I SPECT/CT on risk classification and management of patients with differentiated thyroid cancer. J Nucl Med **51:**1361–1367.
744. Brabant G 2008 Thyrotropin suppressive therapy in thyroid carcinoma: what are the targets? J Clin Endocrinol Metab **93:**1167–1169.
745. McGriff NJ, Csako G, Gourgiotis L, Lori CG, Pucino F, Sarlis NJ 2002 Effects of thyroid hormone suppression therapy on adverse clinical outcomes in thyroid cancer. Ann Med **34:**554–564.
746. Diessl S, Holzberger B, Mader U, Grelle I, Smit JW, Buck AK, Reiners C, Verburg FA 2012 Impact of moderate vs stringent TSH suppression on survival in advanced differentiated thyroid carcinoma. Clin Endocrinol (Oxf) **76:**586–592.
747. Biondi B, Cooper DS 2010 Benefits of thyrotropin suppression versus the risks of adverse effects in differentiated thyroid cancer. Thyroid **20:**135–146.
748. Sugitani I, Fujimoto Y 2011 Effect of postoperative thyrotropin suppressive therapy on bone mineral density in patients with papillary thyroid carcinoma: a prospective controlled study. Surgery **150:**1250–1257.
749. Pujol P, Daures JP, Nsakala N, Baldet L, Bringer J, Jaffiol C 1996 Degree of thyrotropin suppression as a prognostic determinant in differentiated thyroid cancer. J Clin Endocrinol Metab **81:**4318–4323.
750. Hovens GC, Stokkel MP, Kievit J, Corssmit EP, Pereira AM, Romijn JA, Smit JW 2007 Associations of serum thyrotropin concentrations with recurrence and death in differentiated thyroid cancer. J Clin Endocrinol Metab **92:**2610–2615.
751. Sawin CT, Geller A, Wolf PA, Belanger AJ, Baker E, Bacharach P, Wilson PW, Benjamin EJ, D'Agostino RB 1994 Low serum thyrotropin concentrations as a risk factor for atrial fibrillation in older persons. N Engl J Med **331:**1249–1252.
752. Toft AD 2001 Clinical practice. Subclinical hyperthyroidism. N Engl J Med **345:**512–516.
753. Chen CH, Chen JF, Yang BY, Liu RT, Tung SC, Chien WY, Lu YC, Kuo MC, Hsieh CJ, Wang PW 2004 Bone mineral density in women receiving thyroxine suppressive therapy for differentiated thyroid carcinoma. J Formos Med Assoc **103:**442–447.
754. Panico A, Lupoli GA, Fonderico F, Marciello F, Martinelli A, Assante R, Lupoli G 2009 Osteoporosis and thyrotropin-suppressive therapy: reduced effectiveness of alendronate. Thyroid **19:**437–442.
755. Ebina A, Sugitani I, Fujimoto Y, Yamada K 2014 Risk-adapted management of papillary thyroid carcinoma according to our own risk group classification system: is thyroid lobectomy the treatment of choice for low-risk patients? Surgery **156:**1579–1588.
756. Ford D, Giridharan S, McConkey C, Hartley A, Brammer C, Watkinson JC, Glaholm J 2003 External beam radiotherapy in the management of differentiated thyroid cancer. Clin Oncol (R Coll Radiol) **15:**337–341.
757. Terezakis SA, Lee KS, Ghossein RA, Rivera M, Tuttle RM, Wolden SL, Zelefsky MJ, Wong RJ, Patel SG, Pfister DG, Shaha AR, Lee NY 2009 Role of external beam radiotherapy in patients with advanced or recurrent nonanaplastic thyroid cancer: Memorial Sloan-Kettering Cancer Center experience. Int J Radiat Oncol Biol Phys **73:**795–801.
758. Brierley J, Tsang R, Panzarella T, Bana N 2005 Prognostic factors and the effect of treatment with radioactive iodine and external beam radiation on patients with differentiated thyroid cancer seen at a single institution over 40 years. Clin Endocrinol (Oxf) **63:**418–427.
759. Sanders EM Jr, LiVolsi VA, Brierley J, Shin J, Randolph GW 2007 An evidence-based review of poorly differentiated thyroid cancer. World J Surg **31:**934–945.
760. Kim JH, Leeper RD 1987 Treatment of locally advanced thyroid carcinoma with combination doxorubicin and radiation therapy. Cancer **60:**2372–2375.
761. Links TP, van Tol KM, Jager PL, Plukker JT, Piers DA, Boezen HM, Dullaart RP, de Vries EG, Sluiter WJ 2005 Life expectancy in differentiated thyroid cancer: a novel approach to survival analysis. Endocr Relat Cancer **12:**273–280.
762. Brown AP, Chen J, Hitchcock YJ, Szabo A, Shrieve DC, Tward JD 2008 The risk of second primary malignancies up to three decades after the treatment of differentiated thyroid cancer. J Clin Endocrinol Metab **93:**504–515.
763. Rubino C, de Vathaire F, Dottorini ME, Hall P, Schvartz C, Couette JE, Dondon MG, Abbas MT, Langlois C,

Downloaded by Memorial Sloan Kettering from www.liebertpub.com at 08/14/19. For personal use only.

Schlumberger M 2003 Second primary malignancies in thyroid cancer patients. Br J Cancer **89:**1638–1644.
764. Berthe E, Henry-Amar M, Michels JJ, Rame JP, Berthet P, Babin E, Icard P, Samama G, Galateau-Salle F, Mahoudeau J, Bardet S 2004 Risk of second primary cancer following differentiated thyroid cancer. Eur J Nucl Med Mol Imaging **31:**685–691.
765. Kim S, Wei JP, Braveman JM, Brams DM 2004 Predicting outcome and directing therapy for papillary thyroid carcinoma. Arch Surg **139:**390–394.
766. Iyer NG, Morris LG, Tuttle RM, Shaha AR, Ganly I 2011 Rising incidence of second cancers in patients with low-risk (T1N0) thyroid cancer who receive radioactive iodine therapy. Cancer **117:**4439–4446.
767. Biondi B, Filetti S, Schlumberger M 2005 Thyroid-hormone therapy and thyroid cancer: a reassessment. Nat Clin Pract Endocrinol Metab **1:**32–40.
768. Diaz-Soto G, Puig-Domingo M, Martinez-Pino I, Martinez de Osaba MJ, Mora M, Rivera-Fillat F, Halperin I 2011 Do thyroid cancer patients with basal undetectable Tg measured by current immunoassays require rhTSH testing? Exp Clin Endocrinol Diabetes **119:**348–352.
769. Smallridge RC, Meek SE, Morgan MA, Gates GS, Fox TP, Grebe S, Fatourechi V 2007 Monitoring thyroglobulin in a sensitive immunoassay has comparable sensitivity to recombinant human TSH-stimulated thyroglobulin in follow-up of thyroid cancer patients. J Clin Endocrinol Metab **92:**82–87.
770. Schlumberger M, Hitzel A, Toubert ME, Corone C, Troalen F, Schlageter MH, Claustrat F, Koscielny S, Taieb D, Toubeau M, Bonichon F, Borson-Chazot F, Leenhardt L, Schvartz C, Dejax C, Brenot-Rossi I, Torlontano M, Tenenbaum F, Bardet S, Bussiere F, Girard JJ, Morel O, Schneegans O, Schlienger JL, Prost A, So D, Archambeaud F, Ricard M, Benhamou E 2007 Comparison of seven serum thyroglobulin assays in the follow-up of papillary and follicular thyroid cancer patients. J Clin Endocrinol Metab **92:**2487–2495.
771. Spencer CA 2011 Clinical review: Clinical utility of thyroglobulin antibody (TgAb) measurements for patients with differentiated thyroid cancers (DTC). J Clin Endocrinol Metab **96:**3615–3627.
772. Taylor KP, Parkington D, Bradbury S, Simpson HL, Jefferies SJ, Halsall DJ 2011 Concordance between thyroglobulin antibody assays. Ann Clin Biochem **48:** 367–369.
773. Giovanella L, Keller F, Ceriani L, Tozzoli R 2009 Heterophile antibodies may falsely increase or decrease thyroglobulin measurement in patients with differentiated thyroid carcinoma. Clin Chem Lab Med **47:**952–954.
774. Verburg FA, Waschle K, Reiners C, Giovanella L, Lentjes EG 2010 Heterophile antibodies rarely influence the measurement of thyroglobulin and thyroglobulin antibodies in differentiated thyroid cancer patients. Horm Metab Res **42:**736–739.
775. Latrofa F, Ricci D, Montanelli L, Rocchi R, Piaggi P, Sisti E, Grasso L, Basolo F, Ugolini C, Pinchera A, Vitti P 2012 Lymphocytic thyroiditis on histology correlates with serum thyroglobulin autoantibodies in patients with papillary thyroid carcinoma: impact on detection of serum thyroglobulin. J Clin Endocrinol Metab **97:**2380–2387.
776. Giovanella L, Ceriani L 2011 Comparison of thyroglobulin antibody interference in first- and second-generation thyroglobulin immunoassays. Clin Chem Lab Med **49:**1025–1027.
777. Stanojevic M, Savin S, Cvejic D, Djukic A, Jeremic M, Zivancevic SS 2009 Comparison of the influence of thyroglobulin antibodies on serum thyroglobulin values from two different immunoassays in post surgical differentiated thyroid carcinoma patients. J Clin Lab Anal **23:**341–346.
778. Stanojevic M, Savin S, Cvejic D, Dukic A, Zivancevic SS 2009 Correlation of thyroglobulin concentrations measured by radioimmunoassay and immunoradiometric assay and the influence of thyroglobulin antibody. J Immunoassay Immunochem **30:**197–207.
779. Eustatia-Rutten CF, Smit JW, Romijn JA, van der Kleij-Corssmit EP, Pereira AM, Stokkel MP, Kievit J 2004 Diagnostic value of serum thyroglobulin measurements in the follow-up of differentiated thyroid carcinoma, a structured meta-analysis. Clin Endocrinol (Oxf) **61:** 61–74.
780. Bachelot A, Leboulleux S, Baudin E, Hartl DM, Caillou B, Travagli JP, Schlumberger M 2005 Neck recurrence from thyroid carcinoma: serum thyroglobulin and high-dose total body scan are not reliable criteria for cure after radioiodine treatment. Clin Endocrinol (Oxf) **62:**376–379.
781. Cherk MH, Francis P, Topliss DJ, Bailey M, Kalff V 2012 Incidence and implications of negative serum thyroglobulin but positive I-131 whole-body scans in patients with well-differentiated thyroid cancer prepared with rhTSH or thyroid hormone withdrawal. Clin Endocrinol (Oxf) **76:**734–740.
782. Pacini F, Agate L, Elisei R, Capezzone M, Ceccarelli C, Lippi F, Molinaro E, Pinchera A 2001 Outcome of differentiated thyroid cancer with detectable serum Tg and negative diagnostic (131)I whole body scan: comparison of patients treated with high (131)I activities versus untreated patients. J Clin Endocrinol Metab **86:**4092–4097.
783. Torlontano M, Crocetti U, Augello G, D'Aloiso L, Bonfitto N, Varraso A, Dicembrino F, Modoni S, Frusciante V, Di GA, Bruno R, Filetti S, Trischitta V 2006 Comparative evaluation of recombinant human thyrotropin-stimulated thyroglobulin levels, 131I whole-body scintigraphy, and neck ultrasonography in the follow-up of patients with papillary thyroid microcarcinoma who have not undergone radioiodine therapy. J Clin Endocrinol Metab **91:**60–63.
784. Robbins RJ, Srivastava S, Shaha A, Ghossein R, Larson SM, Fleisher M, Tuttle RM 2004 Factors influencing the basal and recombinant human thyrotropin-stimulated serum thyroglobulin in patients with metastatic thyroid carcinoma. J Clin Endocrinol Metab **89:**6010–6016.
785. Mazzaferri EL, Robbins RJ, Spencer CA, Braverman LE, Pacini F, Wartofsky L, Haugen BR, Sherman SI, Cooper DS, Braunstein GD, Lee S, Davies TF, Arafah BM, Ladenson PW, Pinchera A 2003 A consensus report of the role of serum thyroglobulin as a monitoring method for low-risk patients with papillary thyroid carcinoma. J Clin Endocrinol Metab **88:**1433–1441.
786. Deleted.
787. Iervasi A, Iervasi G, Ferdeghini M, Solimeo C, Bottoni A, Rossi L, Colato C, Zucchelli GC 2007 Clinical relevance of highly sensitive Tg assay in monitoring patients treated for differentiated thyroid cancer. Clin Endocrinol (Oxf) **67:**434–441.

Downloaded by Memorial Sloan Kettering from www.liebertpub.com at 08/14/19. For personal use only.

788. Spencer C, Fatemi S, Singer P, Nicoloff J, Lopresti J 2010 Serum basal thyroglobulin measured by a second-generation assay correlates with the recombinant human thyrotropin-stimulated thyroglobulin response in patients treated for differentiated thyroid cancer. Thyroid **20:** 587–595.
789. Haugen BR, Pacini F, Reiners C, Schlumberger M, Ladenson PW, Sherman SI, Cooper DS, Graham KE, Braverman LE, Skarulis MC, Davies TF, DeGroot LJ, Mazzaferri EL, Daniels GH, Ross DS, Luster M, Samuels MH, Becker DV, Maxon HR III, Cavalieri RR, Spencer CA, McEllin K, Weintraub BD, Ridgway EC 1999 A comparison of recombinant human thyrotropin and thyroid hormone withdrawal for the detection of thyroid remnant or cancer. J Clin Endocrinol Metab **84:** 3877–3885.
790. David A, Blotta A, Bondanelli M, Rossi R, Roti E, Braverman LE, Busutti L, degli Uberti EC 2001 Serum thyroglobulin concentrations and (131)I whole-body scan results in patients with differentiated thyroid carcinoma after administration of recombinant human thyroid-stimulating hormone. J Nucl Med **42:**1470–1475.
791. Mazzaferri EL, Kloos RT 2002 Is diagnostic iodine-131 scanning with recombinant human TSH useful in the follow-up of differentiated thyroid cancer after thyroid ablation? J Clin Endocrinol Metab **87:**1490–1498.
792. Haugen BR, Ridgway EC, McLaughlin BA, McDermott MT 2002 Clinical comparison of whole-body radioiodine scan and serum thyroglobulin after stimulation with recombinant human thyrotropin. Thyroid **12:**37–43.
793. Lima N, Cavaliere H, Tomimori E, Knobel M, Medeiros-Neto G 2002 Prognostic value of serial serum thyroglobulin determinations after total thyroidectomy for differentiated thyroid cancer. J Endocrinol Invest **25:** 110–115.
794. Wartofsky L 2002 Management of low-risk well-differentiated thyroid cancer based only on thyroglobulin measurement after recombinant human thyrotropin. Thyroid **12:**583–590.
795. Schaap J, Eustatia-Rutten CF, Stokkel M, Links TP, Diamant M, van der Velde EA, Romijn JA, Smit JW 2002 Does radioiodine therapy have disadvantageous effects in non-iodine accumulating differentiated thyroid carcinoma? Clin Endocrinol (Oxf) **57:**117–124.
796. Pacini F, Sabra MM, Tuttle RM 2011 Clinical relevance of thyroglobulin doubling time in the management of patients with differentiated thyroid cancer. Thyroid **21:** 691–692.
797. Spencer CA, LoPresti JS, Fatemi S, Nicoloff JT 1999 Detection of residual and recurrent differentiated thyroid carcinoma by serum thyroglobulin measurement. Thyroid **9:**435–441.
798. Hollowell JG, Staehling NW, Flanders WD, Hannon WH, Gunter EW, Spencer CA, Braverman LE 2002 Serum TSH, T(4), and thyroid antibodies in the United States population (1988 to 1994): National Health and Nutrition Examination Survey (NHANES III). J Clin Endocrinol Metab **87:**489–499.
799. Spencer CA 2004 Challenges of serum thyroglobulin (Tg) measurement in the presence of Tg autoantibodies. J Clin Endocrinol Metab **89:**3702–3704.
800. Bachelot A, Cailleux AF, Klain M, Baudin E, Ricard M, Bellon N, Caillou B, Travagli JP, Schlumberger M 2002 Relationship between tumor burden and serum thyroglobulin level in patients with papillary and follicular thyroid carcinoma. Thyroid **12:**707–711.
801. Spencer C, Fatemi S 2013 Thyroglobulin antibody (TgAb) methods—strengths, pitfalls and clinical utility for monitoring TgAb-positive patients with differentiated thyroid cancer. Best Pract Res Clin Endocrinol Metab **27:**701–712.
802. Nygaard B, Bentzen J, Laurberg P, Pedersen SM, Bastholt L, Handberg A, Rytter C, Godballe C, Faber J 2012 Large discrepancy in the results of sensitive measurements of thyroglobulin antibodies in the follow-up on thyroid cancer: a diagnostic dilemma. Eur Thyroid J **1:** 193–197.
803. Hoofnagle AN, Becker JO, Wener MH, Heinecke JW 2008 Quantification of thyroglobulin, a low-abundance serum protein, by immunoaffinity peptide enrichment and tandem mass spectrometry. Clin Chem **54:**1796–1804.
804. Clarke NJ, Zhang Y, Reitz RE 2012 A novel mass spectrometry-based assay for the accurate measurement of thyroglobulin from patient samples containing antithyroglobulin autoantibodies. J Investig Med **60:**1157–1163.
805. Kushnir MM, Rockwood AL, Roberts WL, Abraham D, Hoofnagle AN, Meikle AW 2013 Measurement of thyroglobulin by liquid chromatography-tandem mass spectrometry in serum and plasma in the presence of antithyroglobulin autoantibodies. Clin Chem **59:**982–990.
806. Hoofnagle AN, Roth MY 2013 Clinical review: improving the measurement of serum thyroglobulin with mass spectrometry. J Clin Endocrinol Metab **98:**1343–1352.
807. Pacini F, Molinaro E, Castagna MG, Agate L, Elisei R, Ceccarelli C, Lippi F, Taddei D, Grasso L, Pinchera A 2003 Recombinant human thyrotropin-stimulated serum thyroglobulin combined with neck ultrasonography has the highest sensitivity in monitoring differentiated thyroid carcinoma. J Clin Endocrinol Metab **88:**3668–3673.
808. Shin JH, Han BK, Ko EY, Kang SS 2007 Sonographic findings in the surgical bed after thyroidectomy: comparison of recurrent tumors and nonrecurrent lesions. J Ultrasound Med **26:**1359–1366.
809. Bardet S, Malville E, Rame JP, Babin E, Samama G, De RD, Michels JJ, Reznik Y, Henry-Amar M 2008 Macroscopic lymph-node involvement and neck dissection predict lymph-node recurrence in papillary thyroid carcinoma. Eur J Endocrinol **158:**551–560.
810. Torres MR, Nobrega Neto SH, Rosas RJ, Martins AL, Ramos AL, da Cruz TR 2014 Thyroglobulin in the washout fluid of lymph-node biopsy: what is its role in the follow-up of differentiated thyroid carcinoma? Thyroid **24:**7–18.
811. Frasoldati A, Toschi E, Zini M, Flora M, Caroggio A, Dotti C, Valcavi R 1999 Role of thyroglobulin measurement in fine-needle aspiration biopsies of cervical lymph nodes in patients with differentiated thyroid cancer. Thyroid **9:**105–111.
812. Baloch ZW, Barroeta JE, Walsh J, Gupta PK, LiVolsi VA, Langer JE, Mandel SJ 2008 Utility of thyroglobulin measurement in fine-needle aspiration biopsy specimens of lymph nodes in the diagnosis of recurrent thyroid carcinoma. Cytojournal **5:**1–8.
813. Pacini F, Capezzone M, Elisei R, Ceccarelli C, Taddei D, Pinchera A 2002 Diagnostic 131-iodine whole-body scan

Downloaded by Memorial Sloan Kettering from www.liebertpub.com at 08/14/19. For personal use only.

may be avoided in thyroid cancer patients who have undetectable stimulated serum Tg levels after initial treatment. J Clin Endocrinol Metab **87:**1499–1501.
814. Torlontano M, Crocetti U, D'Aloiso L, Bonfitto N, Di GA, Modoni S, Valle G, Frusciante V, Bisceglia M, Filetti S, Schlumberger M, Trischitta V 2003 Serum thyroglobulin and 131I whole body scan after recombinant human TSH stimulation in the follow-up of low-risk patients with differentiated thyroid cancer. Eur J Endocrinol **148:**19–24.
815. Aide N, Heutte N, Rame JP, Rousseau E, Loiseau C, Henry-Amar M, Bardet S 2009 Clinical relevance of single-photon emission computed tomography/computed tomography of the neck and thorax in postablation (131)I scintigraphy for thyroid cancer. J Clin Endocrinol Metab **94:**2075–2084.
816. Schmidt D, Szikszai A, Linke R, Bautz W, Kuwert T 2009 Impact of 131I SPECT/spiral CT on nodal staging of differentiated thyroid carcinoma at the first radioablation. J Nucl Med **50:**18–23.
817. Jeong SY, Lee SW, Kim HW, Song BI, Ahn BC, Lee J 2014 Clinical applications of SPECT/CT after first I-131 ablation in patients with differentiated thyroid cancer. Clin Endocrinol (Oxf) **81:**445–451.
818. Tharp K, Israel O, Hausmann J, Bettman L, Martin WH, Daitzchman M, Sandler MP, Delbeke D 2004 Impact of 131I-SPECT/CT images obtained with an integrated system in the follow-up of patients with thyroid carcinoma. Eur J Nucl Med Mol Imaging **31:**1435–1442.
819. Freudenberg LS, Jentzen W, Stahl A, Bockisch A, Rosenbaum-Krumme SJ 2011 Clinical applications of 124I-PET/CT in patients with differentiated thyroid cancer. Eur J Nucl Med Mol Imaging **38(Suppl 1):**S48–S56.
820. Van Nostrand D, Moreau S, Bandaru VV, Atkins F, Chennupati S, Mete M, Burman K, Wartofsky L 2010 (124)I positron emission tomography versus (131)I planar imaging in the identification of residual thyroid tissue and/or metastasis in patients who have well-differentiated thyroid cancer. Thyroid **20:**879–883.
821. Phan HT, Jager PL, Paans AM, Plukker JT, Sturkenboom MG, Sluiter WJ, Wolffenbuttel BH, Dierckx RA, Links TP 2008 The diagnostic value of 124I-PET in patients with differentiated thyroid cancer. Eur J Nucl Med Mol Imaging **35:**958–965.
822. Leboulleux S, Schroeder PR, Schlumberger M, Ladenson PW 2007 The role of PET in follow-up of patients treated for differentiated epithelial thyroid cancers. Nat Clin Pract Endocrinol Metab **3:**112–121.
823. Robbins RJ, Wan Q, Grewal RK, Reibke R, Gonen M, Strauss HW, Tuttle RM, Drucker W, Larson SM 2006 Real-time prognosis for metastatic thyroid carcinoma based on 2-[18F]fluoro-2-deoxy-D-glucose-positron emission tomography scanning. J Clin Endocrinol Metab **91:**498–505.
824. Deandreis D, Al Ghuzlan A, Leboulleux S, Lacroix L, Garsi JP, Talbot M, Lumbroso J, Baudin E, Caillou B, Bidart JM, Schlumberger M 2011 Do histological, immunohistochemical, and metabolic (radioiodine and fluorodeoxyglucose uptakes) patterns of metastatic thyroid cancer correlate with patient outcome? Endocr Relat Cancer **18:**159–169.
825. Leboulleux S, Schroeder PR, Busaidy NL, Auperin A, Corone C, Jacene HA, Ewertz ME, Bournaud C, Wahl RL, Sherman SI, Ladenson PW, Schlumberger M 2009 Assessment of the incremental value of recombinant thyrotropin stimulation before 2-[18F]-fluoro-2-deoxy-D-glucose positron emission tomography/computed tomography imaging to localize residual differentiated thyroid cancer. J Clin Endocrinol Metab **94:**1310–1316.
826. Yoon DY, Hwang HS, Chang SK, Rho YS, Ahn HY, Kim JH, Lee IJ 2009 CT, MR, US,18F-FDG PET/CT, and their combined use for the assessment of cervical lymph node metastases in squamous cell carcinoma of the head and neck. Eur Radiol **19:**634–642.
827. Takashima S, Sone S, Takayama F, Wang Q, Kobayashi T, Horii A, Yoshida JI 1998 Papillary thyroid carcinoma: MR diagnosis of lymph node metastasis. AJNR Am J Neuroradiol **19:**509–513.
828. Gross ND, Weissman JL, Talbot JM, Andersen PE, Wax MK, Cohen JI 2001 MRI detection of cervical metastasis from differentiated thyroid carcinoma. Laryngoscope **111:**1905–1909.
829. Toubert ME, Cyna-Gorse F, Zagdanski AM, Noel-Wekstein S, Cattan P, Billotey C, Sarfati E, Rain JD 1999 Cervicomediastinal magnetic resonance imaging in persistent or recurrent papillary thyroid carcinoma: clinical use and limits. Thyroid **9:**591–597.
830. Wang JC, Takashima S, Takayama F, Kawakami S, Saito A, Matsushita T, Matsuba H, Kobayashi S 2001 Tracheal invasion by thyroid carcinoma: prediction using MR imaging. AJR Am J Roentgenol **177:**929–936.
831. Wang J, Takashima S, Matsushita T, Takayama F, Kobayashi T, Kadoya M 2003 Esophageal invasion by thyroid carcinomas: prediction using magnetic resonance imaging. J Comput Assist Tomogr **27:**18–25.
832. Lee DH, Kang WJ, Seo HS, Kim E, Kim JH, Son KR, Na DG 2009 Detection of metastatic cervical lymph nodes in recurrent papillary thyroid carcinoma: computed tomography versus positron emission tomography-computed tomography. J Comput Assist Tomogr **33:**805–810.
833. Rosario PW, Mourao GF, dos Santos JB, Calsolari MR 2014 Is empirical radioactive iodine therapy still a valid approach to patients with thyroid cancer and elevated thyroglobulin? Thyroid **24:**533–536.
834. Leboulleux S, El Bez I, I, Borget I, Elleuch M, Déandreis D, Al Ghuzlan A, Chougnet C, Bidault F, Mirghani H, Lumbroso J, Hartl D, Baudin E, Schlumberger M 2012 Postradioiodine treatment whole-body scan in the era of 18-fluorodeoxyglucose positron emission tomography for differentiated thyroid carcinoma with elevated serum thyroglobulin levels. Thyroid **22:**832–838.
835. Wang PW, Wang ST, Liu RT, Chien WY, Tung SC, Lu YC, Chen HY, Lee CH 1999 Levothyroxine suppression of thyroglobulin in patients with differentiated thyroid carcinoma. J Clin Endocrinol Metab **84:**4549–4553.
836. Sugitani I, Fujimoto Y 2010 Does postoperative thyrotropin suppression therapy truly decrease recurrence in papillary thyroid carcinoma? A randomized controlled trial. J Clin Endocrinol Metab **95:**4576–4583.
837. Klein Hesselink EN, Klein Hesselink MS, de Bock GH, Gansevoort RT, Bakker SJ, Vredeveld EJ, van der Horst-Schrivers AN, van der Horst IC, Kamphuisen PW, Plukker JT, Links TP, Lefrandt JD 2013 Long-term cardiovascular mortality in patients with differentiated thyroid carcinoma: an observational study. J Clin Oncol **31:**4046–4053.

Downloaded by Memorial Sloan Kettering from www.liebertpub.com at 08/14/19. For personal use only.

838. Shargorodsky M, Serov S, Gavish D, Leibovitz E, Harpaz D, Zimlichman R 2006 Long-term thyrotropin-suppressive therapy with levothyroxine impairs small and large artery elasticity and increases left ventricular mass in patients with thyroid carcinoma. Thyroid **16:**381–386.
839. Taillard V, Sardinoux M, Oudot C, Fesler P, Rugale C, Raingeard I, Renard E, Ribstein J, du CG 2011 Early detection of isolated left ventricular diastolic dysfunction in high-risk differentiated thyroid carcinoma patients on TSH-suppressive therapy. Clin Endocrinol (Oxf) **75:** 709–714.
840. Leeper RD 1973 The effect of 131 I therapy on survival of patients with metastatic papillary or follicular thyroid carcinoma. J Clin Endocrinol Metab **36:**1143–1152.
841. Beierwaltes WH, Nishiyama RH, Thompson NW, Copp JE, Kubo A 1982 Survival time and ''cure'' in papillary and follicular thyroid carcinoma with distant metastases: statistics following University of Michigan therapy. J Nucl Med **23:**561–568.
842. Bernier MO, Leenhardt L, Hoang C, Aurengo A, Mary JY, Menegaux F, Enkaoua E, Turpin G, Chiras J, Saillant G, Hejblum G 2001 Survival and therapeutic modalities in patients with bone metastases of differentiated thyroid carcinomas. J Clin Endocrinol Metab **86:**1568–1573.
843. Sampson E, Brierley JD, Le LW, Rotstein L, Tsang RW 2007 Clinical management and outcome of papillary and follicular (differentiated) thyroid cancer presenting with distant metastasis at diagnosis. Cancer **110:**1451–1456.
844. Durante C, Haddy N, Baudin E, Leboulleux S, Hartl D, Travagli JP, Caillou B, Ricard M, Lumbroso JD, De Vathaire F, Schlumberger M 2006 Long-term outcome of 444 patients with distant metastases from papillary and follicular thyroid carcinoma: benefits and limits of radioiodine therapy. J Clin Endocrinol Metab **91:**2892–2899.
845. Dupuy DE, Monchik JM, Decrea C, Pisharodi L 2001 Radiofrequency ablation of regional recurrence from well-differentiated thyroid malignancy. Surgery **130:**971–977.
846. Lewis BD, Hay ID, Charboneau JW, McIver B, Reading CC, Goellner JR 2002 Percutaneous ethanol injection for treatment of cervical lymph node metastases in patients with papillary thyroid carcinoma. AJR Am J Roentgenol **178:**699–704.
847. Eustatia-Rutten CF, Romijn JA, Guijt MJ, Vielvoye GJ, van den Berg R, Corssmit EP, Pereira AM, Smit JW 2003 Outcome of palliative embolization of bone metastases in differentiated thyroid carcinoma. J Clin Endocrinol Metab **88:**3184–3189.
848. Misra S, Meiyappan S, Heus L, Freeman J, Rotstein L, Brierley JD, Tsang RW, Rodin G, Ezzat S, Goldstein DP, Sawka AM 2013 Patients' experiences following local-regional recurrence of thyroid cancer: a qualitative study. J Surg Oncol **108:**47–51.
849. Robenshtok E, Fish S, Bach A, Dominguez JM, Shaha A, Tuttle RM 2012 Suspicious cervical lymph nodes detected after thyroidectomy for papillary thyroid cancer usually remain stable over years in properly selected patients. J Clin Endocrinol Metab **97:**2706–2713.
850. Ito Y, Higashiyama T, Takamura Y, Kobayashi K, Miya A, Miyauchi A 2011 Prognosis of patients with papillary thyroid carcinoma showing postoperative recurrence to the central neck. World J Surg **35:**767–772.
851. Uchida H, Imai T, Kikumori T, Hayashi H, Sato S, Noda S, Idota A, Kiuchi T 2013 Long-term results of surgery for papillary thyroid carcinoma with local recurrence. Surg Today **43:**848–853.
852. Newman KD, Black T, Heller G, Azizkhan RG, Holcomb GW III, Sklar C, Vlamis V, Haase GM, La Quaglia MP 1998 Differentiated thyroid cancer: determinants of disease progression in patients <21 years of age at diagnosis: a report from the Surgical Discipline Committee of the Children's Cancer Group. Ann Surg **227:**533–541.
853. Robie DK, Dinauer CW, Tuttle RM, Ward DT, Parry R, McClellan D, Svec R, Adair C, Francis G 1998 The impact of initial surgical management on outcome in young patients with differentiated thyroid cancer. J Pediatr Surg **33:**1134–1138.
854. Chadwick D, Kinsman R, Walton P 2012 The British Association of Endocrine and Thyroid Surgeons 2012. 4th edition. Dendrite Clinical Systems, Ltd, Oxfordshire, United Kingdom, pp 3–188.
855. Rosenthal MS, Angelos P, Cooper DS, Fassler C, Finder SG, Hays MT, Tendler B, Braunstein GD 2013 Clinical and professional ethics guidelines for the practice of thyroidology. Thyroid **23:**1203–1210.
856. Yeh M, Bernet V, Ferris R, Loevner L, Mandel S, Orloff L, Randolph G, Steward D 2015 American Thyroid Association statement on preoperative imaging for thyroid cancer surgery. Thyroid **25:**3–14.
857. Tufano RP, Clayman G, Heller KS, Inabnet WB, Kebebew E, Shaha A, Steward DL, Tuttle RM 2014 Management of recurrent/persistent nodal disease in patients with differentiated thyroid cancer: a critical review of the risks and benefits of surgical intervention versus active surveillance. Thyroid **25:**15–27.
858. Phelan E, Kamani D, Shin J, Randolph GW 2013 Neural monitored revision thyroid cancer surgery: surgical safety and thyroglobulin response. Otolaryngol Head Neck Surg **149:**47–52.
859. Urken ML, Milas M, Randolph GW, Tufano R, Bergman D, Bernet V, Brett EM, Brierley JD, Cobin R, Doherty G, Klopper J, Lee S, Machac J, Mechanick JI, Orloff LA, Ross D, Smallridge RC, Terris DJ, Clain JB, Tuttle M 2015 A review of the management of recurrent and persistent metastatic lymph nodes in well differentiated thyroid cancer: a multifactorial decision making guide created for the Thyroid Cancer Care Collaborative. Head Neck **37:**605–614.
860. Merdad M, Eskander A, Kroeker T, Freeman JL 2012 Predictors of level II and Vb neck disease in metastatic papillary thyroid cancer. Arch Otolaryngol Head Neck Surg **138:**1030–1033.
861. Eskander A, Merdad M, Freeman JL, Witterick IJ 2013 Pattern of spread to the lateral neck in metastatic well-differentiated thyroid cancer: a systematic review and meta-analysis. Thyroid **23:**583–592.
862. Schuff KG 2011 Management of recurrent/persistent papillary thyroid carcinoma: efficacy of the surgical option. J Clin Endocrinol Metab **96:**2038–2039.
863. McCoy KL, Yim JH, Tublin ME, Burmeister LA, Ogilvie JB, Carty SE 2007 Same-day ultrasound guidance in reoperation for locally recurrent papillary thyroid cancer. Surgery **142:**965–972.
864. Hughes DT, Laird AM, Miller BS, Gauger PG, Doherty GM 2012 Reoperative lymph node dissection for recurrent papillary thyroid cancer and effect on serum thyroglobulin. Ann Surg Oncol **19:**2951–2957.

Downloaded by Memorial Sloan Kettering from www.liebertpub.com at 08/14/19. For personal use only.

865. Roh JL, Kim JM, Park CI 2011 Central compartment reoperation for recurrent/persistent differentiated thyroid cancer: patterns of recurrence, morbidity, and prediction of postoperative hypocalcemia. Ann Surg Oncol **18:**1312–1318.
866. Shaha AR 2012 Recurrent differentiated thyroid cancer. Endocr Pract **18:**600–603.
867. Palme CE, Waseem Z, Raza SN, Eski S, Walfish P, Freeman JL 2004 Management and outcome of recurrent well-differentiated thyroid carcinoma. Arch Otolaryngol Head Neck Surg **130:**819–824.
868. Clayman GL, Agarwal G, Edeiken BS, Waguespack SG, Roberts DB, Sherman SI 2011 Long-term outcome of comprehensive central compartment dissection in patients with recurrent/persistent papillary thyroid carcinoma. Thyroid **21:**1309–1316.
869. Clayman GL, Shellenberger TD, Ginsberg LE, Edeiken BS, El-Naggar AK, Sellin RV, Waguespack SG, Roberts DB, Mishra A, Sherman SI 2009 Approach and safety of comprehensive central compartment dissection in patients with recurrent papillary thyroid carcinoma. Head Neck **31:**1152–1163.
870. Chao TC, Jeng LB, Lin JD, Chen MF 1997 Reoperative thyroid surgery. World J Surg **21:**644–647.
871. Erbil Y, Sari S, Agcaoglu O, Ersoz F, Bayraktar A, Salmaslioglu A, Gozkun O, Adalet I, Ozarmagan S 2010 Radio-guided excision of metastatic lymph nodes in thyroid carcinoma: a safe technique for previously operated neck compartments. World J Surg **34:**2581–2588.
872. Alzahrani AS, Raef H, Sultan A, Al Sobhi S, Ingemansson S, Ahmed M, Al Mahfouz A 2002 Impact of cervical lymph node dissection on serum TG and the course of disease in TG-positive, radioactive iodine whole body scan-negative recurrent/persistent papillary thyroid cancer. J Endocrinol Invest **25:**526–531.
873. Travagli JP, Cailleux AF, Ricard M, Baudin E, Caillou B, Parmentier C, Schlumberger M 1998 Combination of radioiodine (131I) and probe-guided surgery for persistent or recurrent thyroid carcinoma. J Clin Endocrinol Metab **83:**2675–2680.
874. Lee L, Steward DL 2008 Sonographically-directed neck dissection for recurrent thyroid carcinoma. Laryngoscope **118:**991–994.
875. Steward DL 2012 Update in utility of secondary node dissection for papillary thyroid cancer. J Clin Endocrinol Metab **97:**3393–3398.
876. Rubello D, Salvatori M, Casara D, Piotto A, Toniato A, Gross MD, Al-Nahhas A, Muzzio PC, Pelizzo MR 2007 99mTc-sestamibi radio-guided surgery of loco-regional 131Iodine-negative recurrent thyroid cancer. Eur J Surg Oncol **33:**902–906.
877. Deleted.
878. Heilo A, Sigstad E, Fagerlid KH, Haskjold OI, Groholt KK, Berner A, Bjoro T, Jorgensen LH 2011 Efficacy of ultrasound-guided percutaneous ethanol injection treatment in patients with a limited number of metastatic cervical lymph nodes from papillary thyroid carcinoma. J Clin Endocrinol Metab **96:**2750–2755.
879. Hay ID, Lee RA, Davidge-Pitts C, Reading CC, Charboneau JW 2013 Long-term outcome of ultrasound-guided percutaneous ethanol ablation of selected ''recurrent'' neck nodal metastases in 25 patients with TNM stages III or IVA papillary thyroid carcinoma previously treated by surgery and 131I therapy. Surgery **154:**1448–1454.
880. Guenette JP, Monchik JM, Dupuy DE 2013 Image-guided ablation of postsurgical locoregional recurrence of biopsy-proven well-differentiated thyroid carcinoma. J Vasc Interv Radiol **24:**672–679.
881. Park KW, Shin JH, Han BK, Ko EY, Chung JH 2011 Inoperable symptomatic recurrent thyroid cancers: preliminary result of radiofrequency ablation. Ann Surg Oncol **18:**2564–2568.
882. Baek JH, Kim YS, Sung JY, Choi H, Lee JH 2011 Locoregional control of metastatic well-differentiated thyroid cancer by ultrasound-guided radiofrequency ablation. AJR Am J Roentgenol **197:**W331-W336.
883. Monchik JM, Donatini G, Iannuccilli J, Dupuy DE 2006 Radiofrequency ablation and percutaneous ethanol injection treatment for recurrent local and distant well-differentiated thyroid carcinoma. Ann Surg **244:**296–304.
884. Shin JE, Baek JH, Lee JH 2013 Radiofrequency and ethanol ablation for the treatment of recurrent thyroid cancers: current status and challenges. Curr Opin Oncol **25:**14–19.
885. Na DG, Lee JH, Jung SL, Kim JH, Sung JY, Shin JH, Kim EK, Lee JH, Kim DW, Park JS, Kim KS, Baek SM, Lee Y, Chong S, Sim JS, Huh JY, Bae JI, Kim KT, Han SY, Bae MY, Kim YS, Baek JH 2012 Radiofrequency ablation of benign thyroid nodules and recurrent thyroid cancers: consensus statement and recommendations. Korean J Radiol **13:**117–125.
886. Papini E, Bizzarri G, Bianchini A, Valle D, Misischi I, Guglielmi R, Salvatori M, Solbiati L, Crescenzi A, Pacella CM, Gharib H 2013 Percutaneous ultrasound-guided laser ablation is effective for treating selected nodal metastases in papillary thyroid cancer. J Clin Endocrinol Metab **98:**E92–E97.
887. Sabra MM, Grewal RK, Tala H, Larson SM, Tuttle RM 2012 Clinical outcomes following empiric radioiodine therapy in patients with structurally identifiable metastatic follicular cell-derived thyroid carcinoma with negative diagnostic but positive post-therapy 131I whole-body scans. Thyroid **22:**877–883.
888. Schwartz DL, Lobo MJ, Ang KK, Morrison WH, Rosenthal DI, Ahamad A, Evans DB, Clayman G, Sherman SI, Garden AS 2009 Postoperative external beam radiotherapy for differentiated thyroid cancer: outcomes and morbidity with conformal treatment. Int J Radiat Oncol Biol Phys **74:**1083–1091.
889. Romesser PB, Sherman EJ, Shaha AR, Lian M, Wong RJ, Sabra M, Rao SS, Fagin JA, Tuttle RM, Lee NY 2014 External beam radiotherapy with or without concurrent chemotherapy in advanced or recurrent non-anaplastic non-medullary thyroid cancer. J Surg Oncol **110:**375–382.
890. Ge JH, Zhao RL, Hu JL, Zhou WA 2004 Surgical treatment of advanced thyroid carcinoma with aerodigestive invasion. Zhonghua Er Bi Yan Hou Ke Za Zhi **39:**237–240. (In Chinese.)
891. Avenia N, Ragusa M, Monacelli M, Calzolari F, Daddi N, Di CL, Semeraro A, Puma F 2004 Locally advanced thyroid cancer: therapeutic options. Chir Ital **56:**501–508.
892. McCaffrey JC 2000 Evaluation and treatment of aerodigestive tract invasion by well-differentiated thyroid carcinoma. Cancer Control **7:**246–252.

Downloaded by Memorial Sloan Kettering from www.liebertpub.com at 08/14/19. For personal use only.

893. Musholt TJ, Musholt PB, Behrend M, Raab R, Scheumann GF, Klempnauer J 1999 Invasive differentiated thyroid carcinoma: tracheal resection and reconstruction procedures in the hands of the endocrine surgeon. Surgery **126:**1078–1087.
894. Czaja JM, McCaffrey TV 1997 The surgical management of laryngotracheal invasion by well-differentiated papillary thyroid carcinoma. Arch Otolaryngol Head Neck Surg **123:**484–490.
895. Haymart MR, Muenz DG, Stewart AK, Griggs JJ, Banerjee M 2013 Disease severity and radioactive iodine use for thyroid cancer. J Clin Endocrinol Metab **98:**678–686.
896. Van Nostrand D 2009 The benefits and risks of I-131 therapy in patients with well-differentiated thyroid cancer. Thyroid **19:**1381–1391.
897. Higashi T, Nishii R, Yamada S, Nakamoto Y, Ishizu K, Kawase S, Togashi K, Itasaka S, Hiraoka M, Misaki T, Konishi J 2011 Delayed initial radioactive iodine therapy resulted in poor survival in patients with metastatic differentiated thyroid carcinoma: a retrospective statistical analysis of 198 cases. J Nucl Med **52:**683–689.
898. Yim JH, Kim WB, Kim EY, Kim WG, Kim TY, Ryu JS, Moon DH, Sung TY, Yoon JH, Kim SC, Hong SJ, Shong YK 2011 Adjuvant radioactive therapy after reoperation for locoregionally recurrent papillary thyroid cancer in patients who initially underwent total thyroidectomy and high-dose remnant ablation. J Clin Endocrinol Metab **96:**3695–3700.
899. Van Nostrand D, Wartofsky L 2007 Radioiodine in the treatment of thyroid cancer. Endocrinol Metab Clin North Am **36:**807–822, vii–viii.
900. Van Nostrand D, Atkins F, Yeganeh F, Acio E, Bursaw R, Wartofsky L 2002 Dosimetrically determined doses of radioiodine for the treatment of metastatic thyroid carcinoma. Thyroid **12:**121–134.
901. Chiesa C, Castellani MR, Vellani C, Orunesu E, Negri A, Azzeroni R, Botta F, Maccauro M, Aliberti G, Seregni E, Lassmann M, Bombardieri E 2009 Individualized dosimetry in the management of metastatic differentiated thyroid cancer. Q J Nucl Med Mol Imaging **53:**546–561.
902. Lassmann M, Reiners C, Luster M 2010 Dosimetry and thyroid cancer: the individual dosage of radioiodine. Endocr Relat Cancer **17:**R161-R172.
903. Verburg FA, Hanscheid H, Biko J, Hategan MC, Lassmann M, Kreissl MC, Reiners C, Luster M 2010 Dosimetry-guided high-activity (131)I therapy in patients with advanced differentiated thyroid carcinoma: initial experience. Eur J Nucl Med Mol Imaging **37:**896–903.
904. Lassmann M, Hanscheid H, Chiesa C, Hindorf C, Flux G, Luster M 2008 EANM Dosimetry Committee series on standard operational procedures for pre-therapeutic dosimetry I: blood and bone marrow dosimetry in differentiated thyroid cancer therapy. Eur J Nucl Med Mol Imaging **35:**1405–1412.
905. Robbins RJ, Schlumberger MJ 2005 The evolving role of (131)I for the treatment of differentiated thyroid carcinoma. J Nucl Med **46 Suppl 1:**28S-37S.
906. Van Nostrand D, Atkins F, Moreau S, Aiken M, Kulkarni K, Wu JS, Burman KD, Wartofsky L 2009 Utility of the radioiodine whole-body retention at 48 hours for modifying empiric activity of 131-iodine for the treatment of metastatic well-differentiated thyroid carcinoma. Thyroid **19:**1093–1098.
907. Dorn R, Kopp J, Vogt H, Heidenreich P, Carroll RG, Gulec SA 2003 Dosimetry-guided radioactive iodine treatment in patients with metastatic differentiated thyroid cancer: largest safe dose using a risk-adapted approach. J Nucl Med **44:**451–456.
908. Maxon HR, Thomas SR, Hertzberg VS, Kereiakes JG, Chen IW, Sperling MI, Saenger EL 1983 Relation between effective radiation dose and outcome of radioiodine therapy for thyroid cancer. N Engl J Med **309:**937–941.
909. Thomas SR, Maxon HR, Kereiakes JG 1976 In vivo quantitation of lesion radioactivity using external counting methods. Med Phys **03:**253–255.
910. Holst JP, Burman KD, Atkins F, Umans JG, Jonklaas J 2005 Radioiodine therapy for thyroid cancer and hyperthyroidism in patients with end-stage renal disease on hemodialysis. Thyroid **15:**1321–1331.
911. Driedger AA, Quirk S, McDonald TJ, Ledger S, Gray D, Wall W, Yoo J 2006 A pragmatic protocol for I-131 rhTSH-stimulated ablation therapy in patients with renal failure. Clin Nucl Med **31:**454–457.
912. Jarzab B, Handkiewicz-Junak D, Wloch J 2005 Juvenile differentiated thyroid carcinoma and the role of radioiodine in its treatment: a qualitative review. Endocr Relat Cancer **12:**773–803.
913. Verburg FA, Biko J, Diessl S, Demidchik Y, Drozd V, Rivkees SA, Reiners C, Hanscheid H 2011 I-131 activities as high as safely administrable (AHASA) for the treatment of children and adolescents with advanced differentiated thyroid cancer. J Clin Endocrinol Metab **96:**E1268–E1271.
914. Ma C, Xie J, Liu W, Wang G, Zuo S, Wang X, Wu F 2010 Recombinant human thyrotropin (rhTSH) aided radioiodine treatment for residual or metastatic differentiated thyroid cancer. Cochrane Database Syst Rev **(11):**CD008302.
915. Klubo-Gwiezdzinska J, Van Nostrand D, Atkins F, Burman K, Jonklaas J, Mete M, Wartofsky L 2011 Efficacy of dosimetric versus empiric prescribed activity of 131I for therapy of differentiated thyroid cancer. J Clin Endocrinol Metab **96:**3217–3225.
916. Lee JJ, Chung JK, Kim SE, Kang WJ, Park do J, Lee DS, Cho BY, Lee MC 2008 Maximal safe dose of I-131 after failure of standard fixed dose therapy in patients with differentiated thyroid carcinoma. Ann Nucl Med **22:**727–734.
917. Samuel AM, Rajashekharrao B, Shah DH 1998 Pulmonary metastases in children and adolescents with well-differentiated thyroid cancer. J Nucl Med **39:**1531–1536.
918. Sgouros G, Kolbert KS, Sheikh A, Pentlow KS, Mun EF, Barth A, Robbins RJ, Larson SM 2004 Patient-specific dosimetry for 131I thyroid cancer therapy using 124I PET and 3-dimensional-internal dosimetry (3D-ID) software. J Nucl Med **45:**1366–1372.
919. Jentzen W, Freudenberg L, Eising EG, Sonnenschein W, Knust J, Bockisch A 2008 Optimized 124I PET dosimetry protocol for radioiodine therapy of differentiated thyroid cancer. J Nucl Med **49:**1017–1023.
920. Pettinato C, Monari F, Nanni C, Allegri V, Marcatili S, Civollani S, Cima S, Spezi E, Mazzarotto R, Fanti S 2012 Usefulness of 124I PET/CT imaging to predict absorbed doses in patients affected by metastatic thyroid cancer and treated with 131I. Q J Nucl Med Mol Imaging **56:**509–514.

Downloaded by Memorial Sloan Kettering from www.liebertpub.com at 08/14/19. For personal use only.

921. Reiners C, Biko J, Haenscheid H, Hebestreit H, Kirinjuk S, Baranowski O, Marlowe RJ, Demidchik E, Drozd V, Demidchik Y 2013 Twenty-five years after Chernobyl: outcome of radioiodine treatment in children and adolescents with very high-risk radiation-induced differentiated thyroid carcinoma. J Clin Endocrinol Metab **98:** 3039–3048.
922. Schlumberger M, Lacroix L, Russo D, Filetti S, Bidart JM 2007 Defects in iodide metabolism in thyroid cancer and implications for the follow-up and treatment of patients. Nat Clin Pract Endocrinol Metab **3:**260–269.
923. Kulkarni K, Van Nostrand D, Atkins F, Aiken M, Burman K, Wartofsky L 2006 The relative frequency in which empiric dosages of radioiodine would potentially overtreat or undertreat patients who have metastatic well-differentiated thyroid cancer. Thyroid **16:**1019–1023.
924. Tuttle RM, Leboeuf R, Robbins RJ, Qualey R, Pentlow K, Larson SM, Chan CY 2006 Empiric radioactive iodine dosing regimens frequently exceed maximum tolerated activity levels in elderly patients with thyroid cancer. J Nucl Med **47:**1587–1591.
925. Rudavsky AZ, Freeman LM 1997 Treatment of scan-negative, thyroglobulin-positive metastatic thyroid cancer using radioiodine 131I and recombinant human thyroid stimulating hormone. J Clin Endocrinol Metab **82:** 11–14.
926. Ringel MD, Ladenson PW 1996 Diagnostic accuracy of 131I scanning with recombinant human thyrotropin versus thyroid hormone withdrawal in a patient with metastatic thyroid carcinoma and hypopituitarism. J Clin Endocrinol Metab **81:**1724–1725.
927. Luster M, Lassmann M, Haenscheid H, Michalowski U, Incerti C, Reiners C 2000 Use of recombinant human thyrotropin before radioiodine therapy in patients with advanced differentiated thyroid carcinoma. J Clin Endocrinol Metab **85:**3640–3645.
928. Mariani G, Ferdeghini M, Augeri C, Villa G, Taddei GZ, Scopinaro G, Boni G, Bodei L, Rabitti C, Molinari E, Bianchi R 2000 Clinical experience with recombinant human thyrotrophin (rhTSH) in the management of patients with differentiated thyroid cancer. Cancer Biother Radiopharm **15:**211–217.
929. Perros P 1999 Recombinant human thyroid-stimulating hormone (rhTSH) in the radioablation of well-differentiated thyroid cancer: preliminary therapeutic experience. J Endocrinol Invest **22:**30–34.
930. Lippi F, Capezzone M, Angelini F, Taddei D, Molinaro E, Pinchera A, Pacini F 2001 Radioiodine treatment of metastatic differentiated thyroid cancer in patients on L-thyroxine, using recombinant human TSH. Eur J Endocrinol **144:**5–11.
931. Pellegriti G, Scollo C, Giuffrida D, Vigneri R, Squatrito S, Pezzino V 2001 Usefulness of recombinant human thyrotropin in the radiometabolic treatment of selected patients with thyroid cancer. Thyroid **11:**1025–1030.
932. Adler ML, Macapinlac HA, Robbins RJ 1998 Radioiodine treatment of thyroid cancer with the aid of recombinant human thyrotropin. Endocr Pract **4:**282–286.
933. Chiu AC, Delpassand ES, Sherman SI 1997 Prognosis and treatment of brain metastases in thyroid carcinoma. J Clin Endocrinol Metab **82:**3637–3642.
934. Lau WF, Zacharin MR, Waters K, Wheeler G, Johnston V, Hicks RJ 2006 Management of paediatric thyroid carcinoma: recent experience with recombinant human thyroid stimulating hormone in preparation for radioiodine therapy. Intern Med J **36:**564–570.
935. Potzi C, Moameni A, Karanikas G, Preitfellner J, Becherer A, Pirich C, Dudczak R 2006 Comparison of iodine uptake in tumour and nontumour tissue under thyroid hormone deprivation and with recombinant human thyrotropin in thyroid cancer patients. Clin Endocrinol (Oxf) **65:**519–523.
936. Vargas GE, Uy H, Bazan C, Guise TA, Bruder JM 1999 Hemiplegia after thyrotropin alfa in a hypothyroid patient with thyroid carcinoma metastatic to the brain. J Clin Endocrinol Metab **84:**3867–3871.
937. Robbins RJ, Voelker E, Wang W, Macapinlac HA, Larson SM 2000 Compassionate use of recombinant human thyrotropin to facilitate radioiodine therapy: case report and review of literature. Endocr Pract **6:**460–464.
938. Braga M, Ringel MD, Cooper DS 2001 Sudden enlargement of local recurrent thyroid tumor after recombinant human TSH administration. J Clin Endocrinol Metab **86:**5148–5151.
939. Pons F, Carrio I, Estorch M, Ginjaume M, Pons J, Milian R 1987 Lithium as an adjuvant of iodine-131 uptake when treating patients with well-differentiated thyroid carcinoma. Clin Nucl Med **12:**644–647.
940. Koong SS, Reynolds JC, Movius EG, Keenan AM, Ain KB, Lakshmanan MC, Robbins J 1999 Lithium as a potential adjuvant to 131I therapy of metastatic, well differentiated thyroid carcinoma. J Clin Endocrinol Metab **84:**912–916.
941. Liu YY, van der Pluijm G, Karperien M, Stokkel MP, Pereira AM, Morreau J, Kievit J, Romijn JA, Smit JW 2006 Lithium as adjuvant to radioiodine therapy in differentiated thyroid carcinoma: clinical and in vitro studies. Clin Endocrinol (Oxf) **64:**617–624.
942. Ronga G, Filesi M, Montesano T, Di Nicola AD, Pace C, Travascio L, Ventroni G, Antonaci A, Vestri AR 2004 Lung metastases from differentiated thyroid carcinoma. A 40 years' experience. Q J Nucl Med Mol Imaging **48:** 12–19.
943. Lin JD, Chao TC, Chou SC, Hsueh C 2004 Papillary thyroid carcinomas with lung metastases. Thyroid **14:** 1091–1096.
944. Shoup M, Stojadinovic A, Nissan A, Ghossein RA, Freedman S, Brennan MF, Shah JP, Shaha AR 2003 Prognostic indicators of outcomes in patients with distant metastases from differentiated thyroid carcinoma. J Am Coll Surg **197:**191–197.
945. Zettinig G, Fueger BJ, Passler C, Kaserer K, Pirich C, Dudczak R, Niederle B 2002 Long-term follow-up of patients with bone metastases from differentiated thyroid carcinoma—surgery or conventional therapy? Clin Endocrinol (Oxf) **56:**377–382.
946. Pittas AG, Adler M, Fazzari M, Tickoo S, Rosai J, Larson SM, Robbins RJ 2000 Bone metastases from thyroid carcinoma: clinical characteristics and prognostic variables in one hundred forty-six patients. Thyroid **10:** 261–268.
947. Schlumberger M, Challeton C, De Vathaire F, Travagli JP, Gardet P, Lumbroso JD, Francese C, Fontaine F, Ricard M, Parmentier C 1996 Radioactive iodine treatment and external radiotherapy for lung and bone metastases from thyroid carcinoma. J Nucl Med **37:**598–605.

Downloaded by Memorial Sloan Kettering from www.liebertpub.com at 08/14/19. For personal use only.

948. Dinneen SF, Valimaki MJ, Bergstralh EJ, Goellner JR, Gorman CA, Hay ID 1995 Distant metastases in papillary thyroid carcinoma: 100 cases observed at one institution during 5 decades. J Clin Endocrinol Metab **80:** 2041–2045.
949. Foote RL, Brown PD, Garces YI, McIver B, Kasperbauer JL 2003 Is there a role for radiation therapy in the management of Hürthle cell carcinoma? Int J Radiat Oncol Biol Phys **56:**1067–1072.
950. Pak H, Gourgiotis L, Chang WI, Guthrie LC, Skarulis MC, Reynolds JC, Merino MJ, Schrump DS, Libutti SK, Alexander HR Jr, Sarlis NJ 2003 Role of metastasectomy in the management of thyroid carcinoma: the NIH experience. J Surg Oncol **82:**10–18.
951. Vitale G, Fonderico F, Martignetti A, Caraglia M, Ciccarelli A, Nuzzo V, Abbruzzese A, Lupoli G 2001 Pamidronate improves the quality of life and induces clinical remission of bone metastases in patients with thyroid cancer. Br J Cancer **84:**1586–1590.
952. Kitamura Y, Shimizu K, Nagahama M, Sugino K, Ozaki O, Mimura T, Ito K, Ito K, Tanaka S 1999 Immediate causes of death in thyroid carcinoma: clinicopathological analysis of 161 fatal cases. J Clin Endocrinol Metab **84:** 4043–4049.
953. Brose MS, Smit J, Capdevila J, Elisei R, Nutting C, Pitoia F, Robinson B, Schlumberger M, Shong YK, Takami H 2012 Regional approaches to the management of patients with advanced, radioactive iodine-refractory differentiated thyroid carcinoma. Expert Rev Anticancer Ther **12:**1137–1147.
954. Sabra MM, Dominguez JM, Grewal RK, Larson SM, Ghossein RA, Tuttle RM, Fagin JA 2013 Clinical outcomes and molecular profile of differentiated thyroid cancers with radioiodine-avid distant metastases. J Clin Endocrinol Metab **98:**E829–E836.
955. Benua RS, Cicale NR, Sonenberg M, Rawson RW 1962 The relation of radioiodine dosimetry to results and complications in the treatment of metastatic thyroid cancer. Am J Roentgenol Radium Ther Nucl Med **87:**171–182.
956. Hebestreit H, Biko J, Drozd V, Demidchik Y, Burkhardt A, Trusen A, Beer M, Reiners C 2011 Pulmonary fibrosis in youth treated with radioiodine for juvenile thyroid cancer and lung metastases after Chernobyl. Eur J Nucl Med Mol Imaging **38:**1683–1690.
957. Ilgan S, Karacalioglu AO, Pabuscu Y, Atac GK, Arslan N, Ozturk E, Gunalp B, Ozguven MA 2004 Iodine-131 treatment and high-resolution CT: results in patients with lung metastases from differentiated thyroid carcinoma. Eur J Nucl Med Mol Imaging **31:**825–830.
958. Hod N, Hagag P, Baumer M, Sandbank J, Horne T 2005 Differentiated thyroid carcinoma in children and young adults: evaluation of response to treatment. Clin Nucl Med **30:**387–390.
959. Van Nostrand D, Freitas J 2006 Side effects of 131I for ablation and treatment of well differentiated thyroid carcinoma. In: Wartofsky L, Van Nostrand D (eds) Thyroid Cancer: A Comprehensive Guide to Clinical Management. 2nd edition. Humana Press, Totowa, NJ, pp 459–485.
960. Lang BH, Wong IO, Wong KP, Cowling BJ, Wan KY 2012 Risk of second primary malignancy in differentiated thyroid carcinoma treated with radioactive iodine therapy. Surgery **151:**844–850.
961. Sawka AM, Thabane L, Parlea L, Ibrahim-Zada I, Tsang RW, Brierley JD, Straus S, Ezzat S, Goldstein DP 2009 Second primary malignancy risk after radioactive iodine treatment for thyroid cancer: a systematic review and meta-analysis. Thyroid **19:**451–457.
962. Fatourechi V, Hay ID, Javedan H, Wiseman GA, Mullan BP, Gorman CA 2002 Lack of impact of radioiodine therapy in tg-positive, diagnostic whole-body scan-negative patients with follicular cell-derived thyroid cancer. J Clin Endocrinol Metab **87:**1521–1526.
963. Koh JM, Kim ES, Ryu JS, Hong SJ, Kim WB, Shong YK 2003 Effects of therapeutic doses of 131I in thyroid papillary carcinoma patients with elevated thyroglobulin level and negative 131I whole-body scan: comparative study. Clin Endocrinol (Oxf) **58:**421–427.
964. Ma C, Kuang A, Xie J 2009 Radioiodine therapy for differentiated thyroid carcinoma with thyroglobulin positive and radioactive iodine negative metastases. Cochrane Database Syst Rev1–38.
965. Wang W, Larson SM, Tuttle RM, Kalaigian H, Kolbert K, Sonenberg M, Robbins RJ 2001 Resistance of [18f]-fluorodeoxyglucose-avid metastatic thyroid cancer lesions to treatment with high-dose radioactive iodine. Thyroid **11:**1169–1175.
966. Salvatore B, Paone G, Klain M, Storto G, Nicolai E, D'Amico D, Della Morte AM, Pace L, Salvatore M 2008 Fluorodeoxyglucose PET/CT in patients with differentiated thyroid cancer and elevated thyroglobulin after total thyroidectomy and (131)I ablation. Q J Nucl Med Mol Imaging **52:**2–8.
967. Kloos RT 2008 Approach to the patient with a positive serum thyroglobulin and a negative radioiodine scan after initial therapy for differentiated thyroid cancer. J Clin Endocrinol Metab **93:**1519–1525.
968. van Tol KM, Jager PL, de Vries EG, Piers DA, Boezen HM, Sluiter WJ, Dullaart RP, Links TP 2003 Outcome in patients with differentiated thyroid cancer with negative diagnostic whole-body scanning and detectable stimulated thyroglobulin. Eur J Endocrinol **148:**589–596.
969. Kabasakal L, Selcuk NA, Shafipour H, Ozmen O, Onsel C, Uslu I 2004 Treatment of iodine-negative thyroglobulin-positive thyroid cancer: differences in outcome in patients with macrometastases and patients with micrometastases. Eur J Nucl Med Mol Imaging **31:**1500–1504.
970. Yim JH, Kim EY, Bae KW, Kim WG, Kim TY, Ryu JS, Gong G, Hong SJ, Yoon JH, Shong YK 2013 Long-term consequence of elevated thyroglobulin in differentiated thyroid cancer. Thyroid **23:**58–63.
971. Black EG, Sheppard MC, Hoffenberg R 1987 Serial serum thyroglobulin measurements in the management of differentiated thyroid carcinoma. Clin Endocrinol (Oxf) **27:**115–120.
972. Huang SH, Wang PW, Huang YE, Chou FF, Liu RT, Tung SC, Chen JF, Kuo MC, Hsieh JR, Hsieh HH 2006 Sequential follow-up of serum thyroglobulin and whole body scan in thyroid cancer patients without initial metastasis. Thyroid **16:**1273–1278.
973. Schlumberger M, Mancusi F, Baudin E, Pacini F 1997 131I therapy for elevated thyroglobulin levels. Thyroid **7:**273–276.
974. Ma C, Xie J, Kuang A 2005 Is empiric 131I therapy justified for patients with positive thyroglobulin and negative 131I whole-body scanning results? J Nucl Med **46:**1164–1170.
975. Chao M 2010 Management of differentiated thyroid cancer with rising thyroglobulin and negative diagnostic

Downloaded by Memorial Sloan Kettering from www.liebertpub.com at 08/14/19. For personal use only.

radioiodine whole body scan. Clin Oncol (R Coll Radiol) **22:**438–447.
976. Sinha P, Conrad GR, West HC 2011 Response of thyroglobulin to radioiodine therapy in thyroglobulin-elevated negative iodine scintigraphy (TENIS) syndrome. Anticancer Res **31:**2109–2112.
977. Ozata M, Suzuki S, Miyamoto T, Liu RT, Fierro-Renoy F, DeGroot LJ 1994 Serum thyroglobulin in the follow-up of patients with treated differentiated thyroid cancer. J Clin Endocrinol Metab **79:**98–105.
978. Kim WG, Ryu JS, Kim EY, Lee JH, Baek JH, Yoon JH, Hong SJ, Kim ES, Kim TY, Kim WB, Shong YK 2010 Empiric high-dose 131-iodine therapy lacks efficacy for treated papillary thyroid cancer patients with detectable serum thyroglobulin, but negative cervical sonography and 18F-fluorodeoxyglucose positron emission tomography scan. J Clin Endocrinol Metab **95:**1169–1173.
979. Biko J, Reiners C, Kreissl MC, Verburg FA, Demidchik Y, Drozd V 2011 Favourable course of disease after incomplete remission on (131)I therapy in children with pulmonary metastases of papillary thyroid carcinoma: 10 years follow-up. Eur J Nucl Med Mol Imaging **38:**651–655.
980. Schlumberger M, Arcangioli O, Piekarski JD, Tubiana M, Parmentier C 1988 Detection and treatment of lung metastases of differentiated thyroid carcinoma in patients with normal chest X-rays. J Nucl Med **29:**1790–1794.
981. Walter MA, Turtschi CP, Schindler C, Minnig P, Muller-Brand J, Muller B 2007 The dental safety profile of high-dose radioiodine therapy for thyroid cancer: long-term results of a longitudinal cohort study. J Nucl Med **48:**1620–1625.
982. Kloos RT, Duvuuri V, Jhiang SM, Cahill KV, Foster JA, Burns JA 2002 Nasolacrimal drainage system obstruction from radioactive iodine therapy for thyroid carcinoma. J Clin Endocrinol Metab **87:**5817–5820.
983. Sandeep TC, Strachan MW, Reynolds RM, Brewster DH, Scelo G, Pukkala E, Hemminki K, Anderson A, Tracey E, Friis S, McBride ML, Kee-Seng C, Pompe-Kirn V, Kliewer EV, Tonita JM, Jonasson JG, Martos C, Boffetta P, Brennan P 2006 Second primary cancers in thyroid cancer patients: a multinational record linkage study. J Clin Endocrinol Metab **91:**1819–1825.
984. Subramanian S, Goldstein DP, Parlea L, Thabane L, Ezzat S, Ibrahim-Zada I, Straus S, Brierley JD, Tsang RW, Gafni A, Rotstein L, Sawka AM 2007 Second primary malignancy risk in thyroid cancer survivors: a systematic review and meta-analysis. Thyroid **17:**1277–1288.
985. Almeida JP, Sanabria AE, Lima EN, Kowalski LP 2011 Late side effects of radioactive iodine on salivary gland function in patients with thyroid cancer. Head Neck **33:**686–690.
986. Mandel SJ, Mandel L 2003 Radioactive iodine and the salivary glands. Thyroid **13:**265–271.
987. Nakada K, Ishibashi T, Takei T, Hirata K, Shinohara K, Katoh S, Zhao S, Tamaki N, Noguchi Y, Noguchi S 2005 Does lemon candy decrease salivary gland damage after radioiodine therapy for thyroid cancer? J Nucl Med **46:**261–266.
988. Jentzen W, Balschuweit D, Schmitz J, Freudenberg L, Eising E, Hilbel T, Bockisch A, Stahl A 2010 The influence of saliva flow stimulation on the absorbed radiation dose to the salivary glands during radioiodine therapy of thyroid cancer using 124I PET(/CT) imaging. Eur J Nucl Med Mol Imaging **37:**2298–2306.
989. Van Nostrand D, Bandaru V, Chennupati S, Wexler J, Kulkarni K, Atkins F, Mete M, Gadwale G 2010 Radiopharmacokinetics of radioiodine in the parotid glands after the administration of lemon juice. Thyroid **20:**1113–1119.
990. Bomeli SR, Schaitkin B, Carrau RL, Walvekar RR 2009 Interventional sialendoscopy for treatment of radioiodine-induced sialadenitis. Laryngoscope **119:**864–867.
991. Prendes BL, Orloff LA, Eisele DW 2012 Therapeutic sialendoscopy for the management of radioiodine sialadenitis. Arch Otolaryngol Head Neck Surg **138:**15–19.
992. Bhayani MK, Acharya V, Kongkiatkamon S, Farah S, Roberts DB, Sterba J, Chambers MS, Lai SY 2015 Sialendoscopy for patients with radioiodine-induced sialadenitis and xerostomia. Thyroid **25:**834–838.
993. Chen AY, Levy L, Goepfert H, Brown BW, Spitz MR, Vassilopoulou-Sellin R 2001 The development of breast carcinoma in women with thyroid carcinoma. Cancer **92:**225–231.
994. Perry WF, Hughes JF 1952 The urinary excretion and thyroid uptake of iodine in renal disease. J Clin Invest **31:**457–463.
995. Vini L, Hyer S, Al-Saadi A, Pratt B, Harmer C 2002 Prognosis for fertility and ovarian function after treatment with radioiodine for thyroid cancer. Postgrad Med J **78:**92–93.
996. Dottorini ME, Lomuscio G, Mazzucchelli L, Vignati A, Colombo L 1995 Assessment of female fertility and carcinogenesis after iodine-131 therapy for differentiated thyroid carcinoma. J Nucl Med **36:**21–27.
997. Sawka AM, Lakra DC, Lea J, Alshehri B, Tsang RW, Brierley JD, Straus S, Thabane L, Gafni A, Ezzat S, George SR, Goldstein DP 2008 A systematic review examining the effects of therapeutic radioactive iodine on ovarian function and future pregnancy in female thyroid cancer survivors. Clin Endocrinol (Oxf) **69:**479–490.
998. Wu JX, Young S, Ro K, Li N, Leung AM, Chiu HK, Harari A, Yeh MW 2015 Reproductive outcomes and nononcologic complications after radioactive iodine ablation for well-differentiated thyroid cancer. Thyroid **25:**133–138.
999. Schlumberger M, De Vathaire F, Ceccarelli C, Delisle MJ, Francese C, Couette JE, Pinchera A, Parmentier C 1996 Exposure to radioactive iodine-131 for scintigraphy or therapy does not preclude pregnancy in thyroid cancer patients. J Nucl Med **37:**606–612.
1000. Garsi JP, Schlumberger M, Rubino C, Ricard M, Labbe M, Ceccarelli C, Schvartz C, Henri-Amar M, Bardet S, De Vathaire F 2008 Therapeutic administration of 131I for differentiated thyroid cancer: radiation dose to ovaries and outcome of pregnancies. J Nucl Med **49:**845–852.
1001. Ceccarelli C, Bencivelli W, Morciano D, Pinchera A, Pacini F 2001 131I therapy for differentiated thyroid cancer leads to an earlier onset of menopause: results of a retrospective study. J Clin Endocrinol Metab **86:**3512–3515.
1002. Bakheet SM, Powe J, Hammami MM 1998 Unilateral radioiodine breast uptake. Clin Nucl Med **23:**170–171.
1003. Sisson JC, Freitas J, McDougall IR, Dauer LT, Hurley JR, Brierley JD, Edinboro CH, Rosenthal D, Thomas MJ,

Downloaded by Memorial Sloan Kettering from www.liebertpub.com at 08/14/19. For personal use only.

Wexler JA, Asamoah E, Avram AM, Milas M, Greenlee C 2011 Radiation safety in the treatment of patients with thyroid diseases by radioiodine 131I : practice recommendations of the American Thyroid Association. Thyroid **21:**335–346.

1004. Bernard N, Jantzem H, Becker M, Pecriaux C, Benard-Laribiere A, Montastruc JL, Descotes J, Vial T 2015 Severe adverse effects of bromocriptine in lactation inhibition: a pharmacovigilance survey. BJOG **122:**1244–1251.
1005. Wichers M, Benz E, Palmedo H, Biersack HJ, Grunwald F, Klingmuller D 2000 Testicular function after radioiodine therapy for thyroid carcinoma. Eur J Nucl Med **27:**503–507.
1006. Hyer S, Vini L, O'Connell M, Pratt B, Harmer C 2002 Testicular dose and fertility in men following I(131) therapy for thyroid cancer. Clin Endocrinol (Oxf) **56:** 755–758.
1007. Lushbaugh CC, Casarett GW 1976 The effects of gonadal irradiation in clinical radiation therapy: a review. Cancer **37:**1111–1125.
1008. Sarkar SD, Beierwaltes WH, Gill SP, Cowley BJ 1976 Subsequent fertility and birth histories of children and adolescents treated with 131I for thyroid cancer. J Nucl Med **17:**460–464.
1009. Mazzaferri EL 2002 Gonadal damage from 131I therapy for thyroid cancer. Clin Endocrinol (Oxf) **57:**313–314.
1010. Schlumberger M, Brose M, Elisei R, Leboulleux S, Luster M, Pitoia F, Pacini F 2014 Definition and management of radioactive iodine-refractory differentiated thyroid cancer. Lancet Diabetes Endocrinol **2:**356–358.
1011. Eisenhauer EA, Therasse P, Bogaerts J, Schwartz LH, Sargent D, Ford R, Dancey J, Arbuck S, Gwyther S, Mooney M, Rubinstein L, Shankar L, Dodd L, Kaplan R, Lacombe D, Verweij J 2009 New response evaluation criteria in solid tumours: revised RECIST guideline (version 1.1). Eur J Cancer **45:**228–247.
1012. Schlumberger M, Sherman SI 2012 Approach to the patient with advanced differentiated thyroid cancer. Eur J Endocrinol **166:**5–11.
1013. Brose MS, Nutting CM, Jarzab B, Elisei R, Siena S, Bastholt L, de la Fouchardiere C, Pacini F, Paschke R, Shong YK, Sherman SI, Smit JW, Chung J, Kappeler C, Pena C, Molnar I, Schlumberger MJ 2014 Sorafenib in radioactive iodine-refractory, locally advanced or metastatic differentiated thyroid cancer: a randomised, double-blind, phase 3 trial. Lancet **384:**319–328.
1014. Schlumberger M, Tahara M, Wirth LJ, Robinson B, Brose MS, Elisei R, Dutcus CE, de las Heras B, Zhu J, Habra MA, Newbold K, Shah MH, Hoff AO, Gianoukakis AG, Kiyota N, Hiram M, Kim SB, Krzyzanowska MK, Sherman SI 2014 A phase 3, multicenter, double-blind, placebo-controlled trial of lenvatinib (E7080) in patients with 131I-refractory differentiated thyroid cancer (SELECT). J Clin Oncol **32:**5S. (Abstract.).
1015. Kocher M, Soffietti R, Abacioglu U, Villa S, Fauchon F, Baumert BG, Fariselli L, Tzuk-Shina T, Kortmann RD, Carrie C, Ben HM, Kouri M, Valeinis E, van den Berge D, Collette S, Collette L, Mueller RP 2011 Adjuvant whole-brain radiotherapy versus observation after radiosurgery or surgical resection of one to three cerebral metastases: results of the EORTC 22952-26001 study. J Clin Oncol **29:**134–141.
1016. Bonichon F, Palussière J, Godbert Y, Pulido M, Descat E, Devillers A, Meunier C, Leboulleux S, de Baère T, Galy-Lacour C, Lagoarde-Segot L, Cazeau AL 2013 Diagnostic accuracy of 18F-FDG PET/CT for assessing response to radiofrequency ablation treatment in lung metastases: a multicentre prospective study. Eur J Nucl Med Mol Imaging **40:**1817–1827.
1017. Lo SS, Fakiris AJ, Chang EL, Mayr NA, Wang JZ, Papiez L, Teh BS, μgarry RC, Cardenes HR, Timmerman RD 2010 Stereotactic body radiation therapy: a novel treatment modality. Nat Rev Clin Oncol **7:**44–54.
1018. Lo SS, Fakiris AJ, Teh BS, Cardenes HR, Henderson MA, Forquer JA, Papiez L, μgarry RC, Wang JZ, Li K, Mayr NA, Timmerman RD 2009 Stereotactic body radiation therapy for oligometastases. Expert Rev Anticancer Ther **9:**621–635.
1019. de Baere T, Elias D, Dromain C, Din MG, Kuoch V, Ducreux M, Boige V, Lassau N, Marteau V, Lasser P, Roche A 2000 Radiofrequency ablation of 100 hepatic metastases with a mean follow-up of more than 1 year. AJR Am J Roentgenol **175:**1619–1625.
1020. Solbiati L, Livraghi T, Goldberg SN, Ierace T, Meloni F, Dellanoce M, Cova L, Halpern EF, Gazelle GS 2001 Percutaneous radio-frequency ablation of hepatic metastases from colorectal cancer: long-term results in 117 patients. Radiology **221:**159–166.
1021. de Baere T, Palussiere J, Auperin A, Hakime A, Abdel-Rehim M, Kind M, Dromain C, Ravaud A, Tebboune N, Boige V, Malka D, Lafont C, Ducreux M 2006 Midterm local efficacy and survival after radiofrequency ablation of lung tumors with minimum follow-up of 1 year: prospective evaluation. Radiology **240:**587–596.
1022. Lencioni R, Crocetti L, Cioni R, Suh R, Glenn D, Regge D, Helmberger T, Gillams AR, Frilling A, Ambrogi M, Bartolozzi C, Mussi A 2008 Response to radiofrequency ablation of pulmonary tumours: a prospective, intention-to-treat, multicentre clinical trial (the RAPTURE study). Lancet Oncol **9:**621–628.
1023. Goetz MP, Callstrom MR, Charboneau JW, Farrell MA, Maus TP, Welch TJ, Wong GY, Sloan JA, Novotny PJ, Petersen IA, Beres RA, Regge D, Capanna R, Saker MB, Gronemeyer DH, Gevargez A, Ahrar K, Choti MA, de Baere TJ, Rubin J 2004 Percutaneous image-guided radiofrequency ablation of painful metastases involving bone: a multicenter study. J Clin Oncol **22:**300–306.
1024. Dupuy DE, Liu D, Hartfeil D, Hanna L, Blume JD, Ahrar K, Lopez R, Safran H, DiPetrillo T 2010 Percutaneous radiofrequency ablation of painful osseous metastases: a multicenter American College of Radiology Imaging Network trial. Cancer **116:**989–997.
1025. Deandreis D, Leboulleux S, Dromain C, Auperin A, Coulot J, Lumbroso J, Deschamps F, Rao P, Schlumberger M, de Baere T 2011 Role of FDG PET/CT and chest CT in the follow-up of lung lesions treated with radiofrequency ablation. Radiology **258:**270–276.
1026. Wertenbroek MW, Links TP, Prins TR, Plukker JT, van der Jagt EJ, de Jong KP 2008 Radiofrequency ablation of hepatic metastases from thyroid carcinoma. Thyroid **18:**1105–1110.
1027. Quan GM, Pointillart V, Palussiere J, Bonichon F 2012 Multidisciplinary treatment and survival of patients with vertebral metastases from thyroid carcinoma. Thyroid **22:**125–130.
1028. Kurup AN, Callstrom MR 2010 Ablation of skeletal metastases: current status. J Vasc Interv Radiol **21:**S242-S250.

Downloaded by Memorial Sloan Kettering from www.liebertpub.com at 08/14/19. For personal use only.

1029. McWilliams RR, Giannini C, Hay ID, Atkinson JL, Stafford SL, Buckner JC 2003 Management of brain metastases from thyroid carcinoma: a study of 16 pathologically confirmed cases over 25 years. Cancer **98:** 356–362.
1030. Henriques de Figueiredo B, Godbert Y, Soubeyran I, Carrat X, Lagarde P, Cazeau AL, Italiano A, Sargos P, Kantor G, Loiseau H, Bonichon F 2014 Brain metastases from thyroid carcinoma: a retrospective study of 21 patients. Thyroid **24:**270–276.
1031. Chow CJ, Habermann EB, Abraham A, Zhu Y, Vickers SM, Rothenberger DA, Al-Refaie WB 2013 Does enrollment in cancer trials improve survival? J Am Coll Surg **216:**774–780.
1032. Anderson RT, Linnehan JE, Tongbram V, Keating K, Wirth LJ 2013 Clinical, safety, and economic evidence in radioactive iodine-refractory differentiated thyroid cancer: a systematic literature review. Thyroid **23:**392–407.
1033. Leboulleux S, Bastholt L, Krause T, de la Fouchardiere C, Tennvall J, Awada A, Gomez JM, Bonichon F, Leenhardt L, Soufflet C, Licour M, Schlumberger MJ 2012 Vandetanib in locally advanced or metastatic differentiated thyroid cancer: a randomised, double-blind, phase 2 trial. Lancet Oncol **13:**897–905.
1034. Schlumberger M, Tahara M, Wirth LJ, Robinson B, Brose MS, Elisei R, Habra MA, Newbold K, Shah MH, Hoff AO, Gianoukakis AG, Kiyota N, Taylor MH, Kim SB, Krzyzanowska MK, Dutcus CE, de las Heras B, Zhu J, Sherman SI 2015 Lenvatinib versus placebo in radioiodine-refractory thyroid cancer. N Engl J Med **372:**621–630.
1035. Cohen EE, Rosen LS, Vokes EE, Kies MS, Forastiere AA, Worden FP, Kane MA, Sherman E, Kim S, Bycott P, Tortorici M, Shalinsky DR, Liau KF, Cohen RB 2008 Axitinib is an active treatment for all histologic subtypes of advanced thyroid cancer: results from a phase II study. J Clin Oncol **26:**4708–4713.
1036. Bible KC, Suman VJ, Molina JR, Smallridge RC, Maples WJ, Menefee ME, Rubin J, Sideras K, Morris JC III, McIver B, Burton JK, Webster KP, Bieber C, Traynor AM, Flynn PJ, Goh BC, Tang H, Ivy SP, Erlichman C 2010 Efficacy of pazopanib in progressive, radioiodine-refractory, metastatic differentiated thyroid cancers: results of a phase 2 consortium study. Lancet Oncol **11:**962–972.
1037. Carr LL, Mankoff DA, Goulart BH, Eaton KD, Capell PT, Kell EM, Bauman JE, Martins RG 2010 Phase II study of daily sunitinib in FDG-PET-positive, iodine-refractory differentiated thyroid cancer and metastatic medullary carcinoma of the thyroid with functional imaging correlation. Clin Cancer Res **16:**5260–5268.
1038. Droz JP, Schlumberger M, Rougier P, Ghosn M, Gardet P, Parmentier C 1990 Chemotherapy in metastatic non-anaplastic thyroid cancer: experience at the Institut Gustave-Roussy. Tumori **76:**480–483.
1039. Schutz FA, Je Y, Richards CJ, Choueiri TK 2012 Meta-analysis of randomized controlled trials for the incidence and risk of treatment-related mortality in patients with cancer treated with vascular endothelial growth factor tyrosine kinase inhibitors. J Clin Oncol **30:**871–877.
1040. Schneider TC, Abdulrahman RM, Corssmit EP, Morreau H, Smit JW, Kapiteijn E 2012 Long-term analysis of the efficacy and tolerability of sorafenib in advanced radioiodine refractory differentiated thyroid carcinoma: final results of a phase II trial. Eur J Endocrinol **167:**643–650.
1041. Ahmed M, Barbachano Y, Riddell A, Hickey J, Newbold KL, Viros A, Harrington KJ, Marais R, Nutting CM 2011 Analysis of the efficacy and toxicity of sorafenib in thyroid cancer: a phase II study in a UK based population. Eur J Endocrinol **165:**315–322.
1042. Kloos RT, Ringel MD, Knopp MV, Hall NC, King M, Stevens R, Liang J, Wakely PE Jr, Vasko VV, Saji M, Rittenberry J, Wei L, Arbogast D, Collamore M, Wright JJ, Grever M, Shah MH 2009 Phase II trial of sorafenib in metastatic thyroid cancer. J Clin Oncol **27:**1675–1684.
1043. Gupta-Abramson V, Troxel AB, Nellore A, Puttaswamy K, Redlinger M, Ransone K, Mandel SJ, Flaherty KT, Loevner LA, O'Dwyer PJ, Brose MS 2008 Phase II trial of sorafenib in advanced thyroid cancer. J Clin Oncol **26:**4714–4719.
1044. Carhill AA, Cabanillas ME, Jimenez C, Waguespack SG, Habra MA, Hu M, Ying A, Vassilopoulou-Sellin R, Gagel RF, Sherman SI, Busaidy NL 2013 The non-investigational use of tyrosine kinase inhibitors in thyroid cancer: establishing a standard for patient safety and monitoring. J Clin Endocrinol Metab **98:**31–42.
1045. Bible KC, Ain KB, Rosenthal MS 2014 Protein kinase inhibitor therapy in advanced thyroid cancer: ethical challenges and potential solutions. Int J Endocr Oncol **1:**145–151.
1046. Massicotte MH, Brassard M, Claude-Desroches M, Borget I, Bonichon F, Giraudet AL, Do Cao C, Chougnet CN, Leboulleux S, Baudin E, Schlumberger M, de la Fouchardiere C 2014 Tyrosine kinase inhibitor treatments in patients with metastatic thyroid carcinomas: a retrospective study of the TUTHYREF network. Eur J Endocrinol **170:**575–582.
1047. Di Lorenzo G, Autorino R, Bruni G, Carteni G, Ricevuto E, Tudini M, Ficorella C, Romano C, Aieta M, Giordano A, Giuliano M, Gonnella A, De Nunzio C, Rizzo M, Montesarchio V, Ewer M, De Placido S 2009 Cardiovascular toxicity following sunitinib therapy in metastatic renal cell carcinoma: a multicenter analysis. Ann Oncol **20:**1535–1542.
1048. Harris PJ, Bible KC 2011 Emerging therapeutics for advanced thyroid malignancies: rationale and targeted approaches. Expert Opin Investig Drugs **20:** 1357–1375.
1049. Hauschild A, Grob JJ, Demidov LV, Jouary T, Gutzmer R, Millward M, Rutkowski P, Blank CU, Miller WH Jr, Kaempgen E, Martin-Algarra S, Karaszewska B, Mauch C, Chiarion-Sileni V, Martin AM, Swann S, Haney P, Mirakhur B, Guckert ME, Goodman V, Chapman PB 2012 Dabrafenib in BRAF-mutated metastatic melanoma: a multicentre, open-label, phase 3 randomised controlled trial. Lancet **380:**358–365.
1050. Falchook GS, Long GV, Kurzrock R, Kim KB, Arkenau TH, Brown MP, Hamid O, Infante JR, Millward M, Pavlick AC, O'Day SJ, Blackman SC, Curtis CM, Lebowitz P, Ma B, Ouellet D, Kefford RF 2012 Dabrafenib in patients with melanoma, untreated brain metastases, and other solid tumours: a phase 1 dose-escalation trial. Lancet **379:**1893–1901.
1051. Kudchadkar R, Paraiso KH, Smalley KS 2012 Targeting mutant BRAF in melanoma: current status and future development of combination therapy strategies. Cancer J **18:**124–131.

Downloaded by Memorial Sloan Kettering from www.liebertpub.com at 08/14/19. For personal use only.

1052. Ho AL, Grewal RK, Leboeuf R, Sherman EJ, Pfister DG, Deandreis D, Pentlow KS, Zanzonico PB, Haque S, Gavane S, Ghossein RA, Ricarte-Filho JC, Dominguez JM, Shen R, Tuttle RM, Larson SM, Fagin JA 2013 Selumetinib-enhanced radioiodine uptake in advanced thyroid cancer. N Engl J Med **368:**623–632.
1053. Spano JP, Vano Y, Vignot S, De La Motte RT, Hassani L, Mouawad R, Menegaux F, Khayat D, Leenhardt L 2012 GEMOX regimen in the treatment of metastatic differentiated refractory thyroid carcinoma. Med Oncol **29:**1421–1428.
1054. Farooki A, Leung V, Tala H, Tuttle RM 2012 Skeletal-related events due to bone metastases from differentiated thyroid cancer. J Clin Endocrinol Metab **97:** 2433–2439.
1055. Coleman R, Woodward E, Brown J, Cameron D, Bell R, Dodwell D, Keane M, Gil M, Davies C, Burkinshaw R, Houston SJ, Grieve RJ, Barrett-Lee PJ, Thorpe H 2011 Safety of zoledronic acid and incidence of osteonecrosis of the jaw (ONJ) during adjuvant therapy in a randomised phase III trial (AZURE: BIG 01-04) for women with stage II/III breast cancer. Breast Cancer Res Treat **127:**429–438.
1056. Wardley A, Davidson N, Barrett-Lee P, Hong A, Mansi J, Dodwell D, Murphy R, Mason T, Cameron D 2005 Zoledronic acid significantly improves pain scores and quality of life in breast cancer patients with bone metastases: a randomised, crossover study of community vs hospital bisphosphonate administration. Br J Cancer **92:**1869–1876.
1057. Orita Y, Sugitani I, Toda K, Manabe J, Fujimoto Y 2011 Zoledronic acid in the treatment of bone metastases from differentiated thyroid carcinoma. Thyroid **21:**31–35.
1058. Lipton A, Fizazi K, Stopeck AT, Henry DH, Brown JE, Yardley DA, Richardson GE, Siena S, Maroto P, Clemens M, Bilynskyy B, Charu V, Beuzeboc P, Rader M, Viniegra M, Saad F, Ke C, Braun A, Jun S 2012 Superiority of denosumab to zoledronic acid for prevention of skeletal-related events: a combined analysis of 3 pivotal, randomised, phase 3 trials. Eur J Cancer **48:**3082–3092.
1059. Cancer Genome Atlas Research Network 2014 Integrated genomic characterization of papillary thyroid carcinoma. Cell **159:**676–690.
1060. Goldfarb M, Casillas J 2014 Unmet information and support needs in newly diagnosed thyroid cancer: comparison of adolescents/young adults (AYA) and older patients. J Cancer Surviv **8:**394–401.
1061. Banach R, Bartes B, Farnell K, Rimmele H, Shey J, Singer S, Verburg FA, Luster M 2013 Results of the Thyroid Cancer Alliance international patient/survivor survey: Psychosocial/informational support needs, treatment side effects and international differences in care. Hormones (Athens) **12:**428–438.
1062. O'Brien MA, Whelan TJ, Villasis-Keever M, Gafni A, Charles C, Roberts R, Schiff S, Cai W 2009 Are cancer-related decision aids effective? A systematic review and meta-analysis. J Clin Oncol **27:**974–985.
1063. Spiegle G, Al-Sukhni E, Schmocker S, Gagliardi AR, Victor JC, Baxter NN, Kennedy ED 2013 Patient decision aids for cancer treatment: are there any alternatives? Cancer **119:**189–200.
1064. Sawka AM, Straus S, Rotstein L, Brierley JD, Tsang RW, Asa S, Segal P, Kelly C, Zahedi A, Freeman J, Solomon P, Anderson J, Thorpe KE, Gafni A, Rodin G, Goldstein DP 2012 Randomized controlled trial of a computerized decision aid on adjuvant radioactive iodine treatment for patients with early-stage papillary thyroid cancer. J Clin Oncol **30:**2906–2911.
1065. Spencer C, Petrovic I, Fatemi S 2011 Current thyroglobulin autoantibody (TgAb) assays often fail to detect interfering TgAb that can result in the reporting of falsely low/undetectable serum Tg IMA values for patients with differentiated thyroid cancer. J Clin Endocrinol Metab **96:**1283–1291.
1066. Ito Y, Tomoda C, Uruno T, Takamura Y, Miya A, Kobayashi K, Matsuzuka F, Kuma K, Miyauchi A 2005 Ultrasonographically and anatomopathologically detectable node metastases in the lateral compartment as indicators of worse relapse-free survival in patients with papillary thyroid carcinoma. World J Surg **29:**917–920.
1067. Ito Y, Tomoda C, Uruno T, Takamura Y, Miya A, Kobayashi K, Matsuzuka F, Kuma K, Miyauchi A 2006 Clinical significance of metastasis to the central compartment from papillary microcarcinoma of the thyroid. World J Surg **30:**91–99.
1068. Rothenberg SM, McFadden DG, Palmer EL, Daniels GH, Wirth LJ 2015 Redifferentiation of iodine-refractory $BRAF^{V600E}$-mutant metastatic papillary thyroid cancer with dabrafenib. Clin Cancer Res **21:**1028–1035.
1069. Topalian SL, Hodi FS, Brahmer JR, Gettinger SN, Smith DC, McDermott DF, Powderly JD, Carvajal RD, Sosman JA, Atkins MB, Leming PD, Spigel DR, Antonia SJ, Horn L, Drake CG, Pardoll DM, Chen L, Sharfman WH, Anders RA, Taube JM, McMiller TL, Xu H, Korman AJ, Jure-Kunkel M, Agrawal S, McDonald D, Kollia GD, Gupta A, Wigginton JM, Sznol M 2012 Safety, activity, and immune correlates of anti-PD-1 antibody in cancer. N Engl J Med **366:**2443–2454.
1070. Brahmer JR, Tykodi SS, Chow LQ, Hwu WJ, Topalian SL, Hwu P, Drake CG, Camacho LH, Kauh J, Odunsi K, Pitot HC, Hamid O, Bhatia S, Martins R, Eaton K, Chen S, Salay TM, Alaparthy S, Grosso JF, Korman AJ, Parker SM, Agrawal S, Goldberg SM, Pardoll DM, Gupta A, Wigginton JM 2012 Safety and activity of anti-PD-L1 antibody in patients with advanced cancer. N Engl J Med **366:**2455–2465.
1071. Hamid O, Robert C, Daud A, Hodi FS, Hwu WJ, Kefford R, Wolchok JD, Hersey P, Joseph RW, Weber JS, Dronca R, Gangadhar TC, Patnaik A, Zarour H, Joshua AM, Gergich K, Elassaiss-Schaap J, Algazi A, Mateus C, Boasberg P, Tumeh PC, Chmielowski B, Ebbinghaus SW, Li XN, Kang SP, Ribas A 2013 Safety and tumor responses with lambrolizumab (anti-PD-1) in melanoma. N Engl J Med **369:**134–144.
1072. Husson O, Haak HR, Mols F, Nieuwenhuijzen GA, Nieuwlaat WA, Reemst PH, Huysmans DA, Toorians AW, van de Poll-Franse LV 2013 Development of a disease-specific health-related quality of life questionnaire (THYCA-QoL) for thyroid cancer survivors. Acta Oncol **52:**447–454.
1073. Sawka AM, Naeem A, Jones J, Lowe J, Segal P, Goguen J, Gilbert J, Zahedi A, Kelly C, Ezzat S 2014 Persistent posttreatment fatigue in thyroid cancer survivors: a scoping review. Endocrinol Metab Clin North Am **43:** 475–494.
1074. To J, Goldberg AS, Jones J, Zhang J, Lowe J, Ezzat S, Gilbert J, Zahedi A, Segal P, Sawka AM 2014 A systematic review of randomized controlled trials for man-

Downloaded by Memorial Sloan Kettering from www.liebertpub.com at 08/14/19. For personal use only.

agement of persistent post-treatment fatigue in thyroid cancer survivors. Thyroid **25:**198–210.
1075. Bresner L, Banach R, Rodin G, Thabane L, Ezzat S, Sawka AM 2015 Cancer-related worry in Canadian thyroid cancer survivors. J Clin Endocrinol Metab **100:**977–985.
1076. Cibas ES, Ali SZ 2009 The Bethesda System For Reporting Thyroid Cytopathology. Am J Clin Pathol **132:** 658–665.
1077. Edge SB, Byrd DR, Compton CC, Fritz AG, Greene FL, Trotti A 2010 Thyroid cancer staging. In: Edge SB, Byrd DR, Compton CC, Fritz AG, Greene FL, Trotti A (eds) AJCC Cancer Staging Manual. 7th edition. Springer-Verlag, New York, pp 59–64.
1078. Rosario PW, Mineiro Filho AF, Prates BS, Silva LC, Calsolari MR 2012 Postoperative stimulated thyroglobulin of less than 1 ng/mL as a criterion to spare low-risk patients with papillary thyroid cancer from radioactive iodine ablation. Thyroid **22:**1140–1143.

Address correspondence to:
Bryan R. Haugen, MD
University of Colorado School of Medicine
Aurora, CO

E-mail: bryan.haugen@ucdenver.edu

Downloaded by Memorial Sloan Kettering from www.liebertpub.com at 08/14/19. For personal use only.

This article has been cited by:

1. David Jackson, Rachel S. Handelsman, Josefina C. Farrá, John I. Lew. 2020. Increased Incidental Thyroid Cancer in Patients With Subclinical Chronic Lymphocytic Thyroiditis. *Journal of Surgical Research* **245**, 115. [Crossref]
2. Yvette J. E. Sloot, Marcel J. R. Janssen, Antonius E. van Herwaarden, Robin P. Peeters, Romana T. Netea-Maier, Johannes W. A. Smit. 2019. The Influence of Energy Depletion by Metformin or Hypocaloric Diet on Thyroid Iodine Uptake in Healthy Volunteers: a Randomized Trial. *Scientific Reports* **9**:1. . [Crossref]
3. Shin Young Jeong, Sang-Woo Lee, Wan Wook Kim, Jin Hyang Jung, Won Kee Lee, Byeong-Cheol Ahn, Jaetae Lee. 2019. Clinical outcomes of patients with T4 or N1b well-differentiated thyroid cancer after different strategies of adjuvant radioiodine therapy. *Scientific Reports* **9**:1. . [Crossref]
4. Krzysztof Kaliszewski, Dorota Diakowska, Beata Wojtczak, Krzysztof Sutkowski, Bartłomiej Knychalski, Zdzisław Forkasiewicz. 2019. Patients with III and IV category of the Bethesda System under levothyroxine non-suppressive therapy have a lower rate of thyroid malignancy. *Scientific Reports* **9**:1. . [Crossref]
5. Su Min Ha, Yun Jae Chung, Hye Shin Ahn, Jung Hwan Baek, Sung Bin Park. 2019. Echogenic foci in thyroid nodules: diagnostic performance with combination of TIRADS and echogenic foci. *BMC Medical Imaging* **19**:1. . [Crossref]
6. Yinlong Zhao, Lingzhi Zhao, Tiezhu Mao, Lili Zhong. 2019. Assessment of risk based on variant pathways and establishment of an artificial neural network model of thyroid cancer. *BMC Medical Genetics* **20**:1. . [Crossref]
7. Andrew Riley, Victoria Green, Ramsah Cheah, Gordon McKenzie, Laszlo Karsai, James England, John Greenman. 2019. A novel microfluidic device capable of maintaining functional thyroid carcinoma specimens ex vivo provides a new drug screening platform. *BMC Cancer* **19**:1. . [Crossref]
8. Bin Song, Rurun Li, Zhihua Zuo, Juan Tan, Ling Liu, Dafa Ding, Yibing Lu, Dawei Hou. 2019. LncRNA ENST00000539653 acts as an oncogenic factor via MAPK signalling in papillary thyroid cancer. *BMC Cancer* **19**:1. . [Crossref]
9. Young Jae Ryu, Jin Seong Cho, Min Ho Park, Jung Han Yoon. 2019. Identifying risk factors of recurrence for clinically node negative papillary thyroid carcinoma with pathologic N1a. *BMC Surgery* **19**:1. . [Crossref]
10. John E. M. Midgley, Anthony D. Toft, Rolf Larisch, Johannes W. Dietrich, Rudolf Hoermann. 2019. Time for a reassessment of the treatment of hypothyroidism. *BMC Endocrine Disorders* **19**:1. . [Crossref]
11. Lei Wang, Shujian Yang, Shan Yang, Cheng Zhao, Guangye Tian, Yuxiu Gao, Yongjian Chen, Yun Lu. 2019. Automatic thyroid nodule recognition and diagnosis in ultrasound imaging with the YOLOv2 neural network. *World Journal of Surgical Oncology* **17**:1. . [Crossref]
12. Krzysztof Kaliszewski, Dorota Diakowska, Beata Wojtczak, Zdzisław Forkasiewicz, Dominika Pupka, Łukasz Nowak, Jerzy Rudnicki. 2019. Which papillary thyroid microcarcinoma should be treated as "true cancer" and which as "precancer"?. *World Journal of Surgical Oncology* **17**:1. . [Crossref]
13. Muhammad Kassim Javaid, Alison Boyce, Natasha Appelman-Dijkstra, Juling Ong, Patrizia Defabianis, Amaka Offiah, Paul Arunde, Nick Shaw, Valter Dal Pos, Ann Underhil, Deanna Portero, Lisa Heral, Anne-Marie Heegaard, Laura Masi, Fergal Monsell, Robert Stanton, Pieter Durk Sander Dijkstra, Maria Luisa Brandi, Roland Chapurlat, Neveen Agnes Therese Hamdy, Michael Terrence Collins. 2019. Best practice management guidelines for fibrous dysplasia/McCune-Albright syndrome: a consensus statement from the FD/MAS international consortium. *Orphanet Journal of Rare Diseases* **14**:1. . [Crossref]
14. Arjun Kundra, David P. Goldstein, Kimberly Wintemute, Sangeet Ghai, Richard W. Tsang, Karuna Gupta, Donatus R. Mutasingwa, Jeff Weissberger, Ella Huszti, Patrick Brown, Huan Jiang, Anna M. Sawka. 2019. A pilot study examining Toronto-area family physician perspectives on thyroid neoplasm evaluation. *Journal of Otolaryngology - Head & Neck Surgery* **48**:1. . [Crossref]
15. Jien Shim, Tiffany Lin, Cody Dashiell-Earp, Meghan Nechrebecki, Angela M. Leung. 2019. Endocrinology practice patterns of hypothyroidism and osteoporosis management in a U.S. tertiary academic medical center. *Clinical Diabetes and Endocrinology* **5**:1. . [Crossref]
16. Chunlei Fan, Xin Zhou, Guoqiang Su, Yanming Zhou, Jingjun Su, Mingxu Luo, Hui Li. 2019. Risk factors for neck hematoma requiring surgical re-intervention after thyroidectomy: a systematic review and meta-analysis. *BMC Surgery* **19**:1. . [Crossref]
17. Lan Jiang, Cortney Y. Lee, David A. Sloan, Reese W. Randle. 2019. Variation in the Quality of Thyroid Nodule Evaluations Before Surgical Referral. *Journal of Surgical Research* **244**, 9-14. [Crossref]
18. Keven S.Y. Ji, Taofik O. Oyekunle, Samantha M. Thomas, Randall Scheri, Michael Stang, Sanziana A. Roman, Julie A. Sosa. 2019. Adequacy of Lymph Node Yield for Papillary Thyroid Cancer: An Analysis of 23,131 Patients. *Journal of Surgical Research* **244**, 566-573. [Crossref]

Downloaded by Memorial Sloan Kettering from www.liebertpub.com at 08/14/19. For personal use only.

19. Ana Germano, Willian Schmitt, Manuel Rio Carvalho, Rui M. Marques. 2019. Normal ultrasound anatomy and common anatomical variants of the thyroid gland plus adjacent structures — A pictorial review. *Clinical Imaging* **58**, 114-128. [Crossref]

20. Alan Zambeli-Ljepović, Frances Wang, Michaela A. Dinan, Terry Hyslop, Sanziana A. Roman, Julie A. Sosa, Randall P. Scheri. 2019. Low-Risk Thyroid Cancer in Elderly: Total Thyroidectomy/RAI Predominates but Lacks Survival Advantage. *Journal of Surgical Research* **243**, 189-197. [Crossref]

21. Mathilde Bauriaud-Mallet, Lavinia Vija-Racaru, Séverine Brillouet, Arnaud Mallinger, Philippe de Medina, Arnaud Rives, Bruno Payre, Marc Poirot, Fréderic Courbon, Sandrine Silvente-Poirot. 2019. The cholesterol-derived metabolite dendrogenin A functionally reprograms breast adenocarcinoma and undifferentiated thyroid cancer cells. *The Journal of Steroid Biochemistry and Molecular Biology* **192**, 105390. [Crossref]

22. Ergin Sağtaş, Erkan Demirci. 2019. Avrupa tiroid görüntüleme raporlama ve veri sistemi (EU-TIRADS) kullanılarak benign ve malign tiroid nodüllerinin ayırımı. *Pamukkale Medical Journal* . [Crossref]

23. Trevor E. Angell, Erik K. Alexander. 2019. Thyroid Nodules and Thyroid Cancer in the Pregnant Woman. *Endocrinology and Metabolism Clinics of North America* **48**:3, 557-567. [Crossref]

24. Tuba ÇANDAR, Zekiye Hasbek, Gülhan Duman, Seyit Ahmet Ertürk, Ali Çakmakcılar. 2019. SERUM GALEKTİN-3 VE DİFERANSİYE TİROİD KANSER İLİŞKİSİ. *Bozok Tıp Dergisi* . [Crossref]

25. Ana Lopez-Campistrous, Aducio Thiesen, Anthony J Gill, Sunita Ghosh, Todd PW McMullen. 2019. Loss of nuclear localization of thyroid transcription factor 1 and adverse outcomes in papillary thyroid cancer. *Human Pathology* **91**, 36-42. [Crossref]

26. Dominik A. Jakob, Philipp Riss, Christian Scheuba, Michael Hermann, Corina Kim-Fuchs, Christian A. Seiler, Martin A. Walter, Reto M. Kaderli. 2019. Association of Surgical Volume and Quality Management in Thyroid Surgery: A Two-Nation Multicenter Study. *World Journal of Surgery* **43**:9, 2218-2227. [Crossref]

27. Maria Heikkinen, Kimmo Mäkinen, Elina Penttilä, Mari Qvarnström, Tatu Kemppainen, Heikki Löppönen, Jussi M. Kärkkäinen. 2019. Incidence, Risk Factors, and Natural Outcome of Vocal Fold Paresis in 920 Thyroid Operations with Routine Pre- and Postoperative Laryngoscopic Evaluation. *World Journal of Surgery* **43**:9, 2228-2234. [Crossref]

28. M. Ding, X. Tang, D. Cui, J. Chi, Y. Shi, T. Wang, B. Zhai, P. Li. 2019. Clinical outcomes of ultrasound-guided radiofrequency ablation for the treatment of primary papillary thyroid microcarcinoma. *Clinical Radiology* **74**:9, 712-717. [Crossref]

29. H. Al-Chalabi, S. Karthik, S. Vaidyanathan. 2019. Radiological–pathological correlation of the British Thyroid Association ultrasound classification of thyroid nodules: a real-world validation study. *Clinical Radiology* **74**:9, 702-711. [Crossref]

30. Jing-liang Ruan, Hai-yun Yang, Rong-bin Liu, Ming Liang, Ping Han, Xiao-lin Xu, Bao-ming Luo. 2019. Fine needle aspiration biopsy indications for thyroid nodules: compare a point-based risk stratification system with a pattern-based risk stratification system. *European Radiology* **29**:9, 4871-4878. [Crossref]

31. Sae Rom Chung, Jung Hwan Baek, Young Jun Choi, Jeong Hyun Lee. 2019. Longer-term outcomes of radiofrequency ablation for locally recurrent papillary thyroid cancer. *European Radiology* **29**:9, 4897-4903. [Crossref]

32. Se Jin Cho, Chong Hyun Suh, Jung Hwan Baek, Sae Rom Chung, Young Jun Choi, Jeong Hyun Lee. 2019. Diagnostic performance of CT in detection of metastatic cervical lymph nodes in patients with thyroid cancer: a systematic review and meta-analysis. *European Radiology* **29**:9, 4635-4647. [Crossref]

33. Tong Gan, Bin Huang, Quan Chen, Heather F. Sinner, Cortney Y. Lee, David A. Sloan, Reese W. Randle. 2019. Risk of Recurrence in Differentiated Thyroid Cancer: A Population-Based Comparison of the 7th and 8th Editions of the American Joint Committee on Cancer Staging Systems. *Annals of Surgical Oncology* **26**:9, 2703-2710. [Crossref]

34. Hunter J. Underwood, Kepal N. Patel. 2019. Comparing the 7th and 8th Editions of the American Joint Committee on Cancer Staging Systems for Differentiated Thyroid Cancer: Improvements Observed and Future Horizons. *Annals of Surgical Oncology* **26**:9, 2653-2654. [Crossref]

35. Ye Won Jeon, Hong Gi Gwak, Seung Taek Lim, Jean Schneider, Young Jin Suh. 2019. Long-Term Prognosis of Unilateral and Multifocal Papillary Thyroid Microcarcinoma After Unilateral Lobectomy Versus Total Thyroidectomy. *Annals of Surgical Oncology* **26**:9, 2952-2958. [Crossref]

36. Ora Israel, O. Pellet, L. Biassoni, D. De Palma, E. Estrada-Lobato, G. Gnanasegaran, T. Kuwert, C. la Fougère, G. Mariani, S. Massalha, D. Paez, F. Giammarile. 2019. Two decades of SPECT/CT – the coming of age of a technology: An updated review of literature evidence. *European Journal of Nuclear Medicine and Molecular Imaging* **46**:10, 1990-2012. [Crossref]

37. Ming-hui Song, Yan-fang Jin, Jin-song Guo, Lili Zuo, Hong Xie, Kaining Shi, Yun-long Yue. 2019. Application of whole-lesion intravoxel incoherent motion analysis using iZOOM DWI to differentiate malignant from benign thyroid nodules. *Acta Radiologica* **60**:9, 1127-1134. [Crossref]

Downloaded by Memorial Sloan Kettering from www.liebertpub.com at 08/14/19. For personal use only.

38. L.D. Locati, A. Piovesan, C. Durante, M. Bregni, M.G. Castagna, S. Zovato, M. Giusti, T. Ibrahim, E. Puxeddu, G. Fedele, G. Pellegriti, G. Rinaldi, D. Giuffrida, F. Verderame, F. Bertolini, C. Bergamini, A. Nervo, G. Grani, S. Rizzati, S. Morelli, I. Puliafito, R. Elisei. 2019. Real-world efficacy and safety of lenvatinib: data from a compassionate use in the treatment of radioactive iodine-refractory differentiated thyroid cancer patients in Italy. *European Journal of Cancer* **118**, 35-40. [Crossref]

39. Kwangsoon Kim, Sang-Wook Kang, Woong Youn Chung. 2019. Robotic-Assisted Modified Radical Neck Dissection: Transaxillary, Bilateral Axill-Breast Approach (BABA), Facelift. *Current Surgery Reports* **7**:9. . [Crossref]

40. Philipp Seifert, Thomas Winkens, Christian Kühnel, Falk Gühne, Martin Freesmeyer. 2019. I-124-PET/US Fusion Imaging in Comparison to Conventional Diagnostics and Tc-99m Pertechnetate SPECT/US Fusion Imaging for the Function Assessment of Thyroid Nodules. *Ultrasound in Medicine & Biology* **45**:9, 2298-2308. [Crossref]

41. Yunlin Huang, Hang Zhou, Chao Zhang, Yurong Hong, Qin Ye, Pintong Huang. 2019. Diagnostic Performance of Ultrasound Strain Elastography in Transverse and Longitudinal Views in Predicting Malignant Thyroid Nodules. *Ultrasound in Medicine & Biology* **45**:9, 2289-2297. [Crossref]

42. Juanita K. Hodax, Kimberly Bowerman, Jose Bernardo Quintos. 2019. Benign thyroid nodules in pediatric patients: determining best practices for repeat ultrasound evaluations. *Journal of Pediatric Endocrinology and Metabolism* **32**:8, 895-901. [Crossref]

43. Mijin Kim, Bo Hyun Kim, Jeong Mi Kim, Eun Heui Kim, Keunyoung Kim, Kyoungjune Pak, Yun Kyung Jeon, Sang Soo Kim, Heeseung Park, Taewoo Kang, Byung Joo Lee, In Joo Kim. 2019. Concordance in postsurgical radioactive iodine therapy recommendations between Watson for Oncology and clinical practice in patients with differentiated thyroid carcinoma. *Cancer* **125**:16, 2803-2809. [Crossref]

44. Tommaso Porcelli, Francesca Sessa, Carla Gambale, Cristina Luongo, Domenico Salvatore. 2019. Management of one patient with oligoprogressive thyroid cancer during treatment with lenvatinib. *Future Oncology* **17**. . [Crossref]

45. Vera Wenter, Annamirl Jellinek, Marcus Unterrainer, Freba Ahmaddy, Sebastian Lehner, Nathalie Lisa Albert, Peter Bartenstein, Thomas Knösel, Christine Spitzweg, Harun Ilhan, Andrei Todica. 2019. Long-term outcome of rare oncocytic papillary (Hürthle cell) thyroid carcinoma following (adjuvant) initial radioiodine therapy. *European Journal of Nuclear Medicine and Molecular Imaging* **132**. . [Crossref]

46. Anastasios Papanastasiou, Konstantinos Sapalidis, Dimitrios G. Goulis, Nikolaos Michalopoulos, Evangelia Mareti, Stylianos Mantalovas, Isaak Kesisoglou. 2019. Thyroid nodules as a risk factor for thyroid cancer in patients with Grave's disease: A systematic review and meta-analysis of observational studies in surgically treated patients. *Clinical Endocrinology* **375**. . [Crossref]

47. Peter Zbären, Jatin P. Shah, Gregory W. Randolph, Carl E. Silver, Kerry D. Olsen, Ashok R. Shaha, Mark Zafereo, Luiz P. Kowalski, Carlos Suarez, Alvaro Sanabria, Vincent Vander Poorten, Iain Nixon, Alessandra Rinaldo, Alfio Ferlito. 2019. Thyroid Surgery: Whose Domain Is It?. *Advances in Therapy* **19**. . [Crossref]

48. Lei Min, Brian H. H. Lang, Weichun Chen, Qing Ai, Jiang Jiang, Zhi Heng Huang. 2019. Utility of Activated Carbon Nanoparticle (CNP) During total Thyroidectomy for Clinically Nodal Positive Papillary Thyroid Carcinoma (PTC). *World Journal of Surgery* **26**. . [Crossref]

49. Chia-Chi Tsai, Ming-Nan Chien, Yuan-Ching Chang, Jie-Jen Lee, Shuen-Han Dai, Shih-Ping Cheng. 2019. Overexpression of Histone H3 Lysine 27 Trimethylation Is Associated with Aggressiveness and Dedifferentiation of Thyroid Cancer. *Endocrine Pathology* **469**. . [Crossref]

50. Chong-Ke Zhao, Jia-Yi Zheng, Li-Ping Sun, Rong-Ying Xu, Qing Wei, Hui-Xiong Xu. 2019. BRAF V600E mutation analysis in fine-needle aspiration cytology specimens for diagnosis of thyroid nodules: The influence of false-positive and false-negative results. *Cancer Medicine* **26**. . [Crossref]

51. Luca Giovanella, Anca M. Avram, Ioannis Iakovou, Jennifer Kwak, Susan A. Lawson, Elizabeth Lulaj, Markus Luster, Arnoldo Piccardo, Matthias Schmidt, Mark Tulchinsky, Frederick A. Verburg, Ely Wolin. 2019. EANM practice guideline/SNMMI procedure standard for RAIU and thyroid scintigraphy. *European Journal of Nuclear Medicine and Molecular Imaging* **4**. . [Crossref]

52. Rajshri M. Gartland, Jordan P. Bloom, Sareh Parangi, Richard Hodin, Courtney DeRoo, Antonia E. Stephen, Vinod Narra, Carrie C. Lubitz, Elizabeth Mort. 2019. A Long, Unnerving Road: Malpractice Claims Involving the Surgical Management of Thyroid and Parathyroid Disease. *World Journal of Surgery* **154**. . [Crossref]

53. Hye Min Kim, Ja Seung Koo. 2019. Immunohistochemical Analysis of Cancer Stem Cell Marker Expression in Papillary Thyroid Cancer. *Frontiers in Endocrinology* **10**. . [Crossref]

54. Hyung Kwon Byeon, Sang Bin Kim, Hyeon Seok Oh, Hong Kyu Kim, In Hak Choi, Hyunjung Kim, Jae-Gu Cho, Kyung Ho Oh, Seung-Kuk Baek, Jeong-Soo Woo, Soon-Young Kwon, Hoon Yub Kim, Kwang Yoon Jung. 2019. Clinical Analysis of Pediatric Thyroid Cancer: A Single Medical Institution Experience of 18Years. *Annals of Otology, Rhinology & Laryngology* **16**, 000348941986825. [Crossref]

Downloaded by Memorial Sloan Kettering from www.liebertpub.com at 08/14/19. For personal use only.

55. Cedric O. Renaud, Panos G. Ziros, Dionysios V. Chartoumpekis, Massimo Bongiovanni, Gerasimos P. Sykiotis. 2019. Keap1/Nrf2 Signaling: A New Player in Thyroid Pathophysiology and Thyroid Cancer. *Frontiers in Endocrinology* **10**. . [Crossref]

56. Earl Abraham, David Roshan, Bryan Tran, Susannah Graham, Christopher Lehane, James Wykes, Peter Campbell, Ardalan Ebrahimi. 2019. Microscopic positive margins strongly predict reduced disease-free survival in pT4a papillary thyroid cancer. *Head & Neck* **41**:8, 2549-2554. [Crossref]

57. Ali Abbasian Ardakani, Ahmad Bitarafan-Rajabi, Afshin Mohammadi, Sepideh Hekmat, Aylin Tahmasebi, Mohammad Bagher Shiran, Ali Mohammadzadeh. 2019. CAD system based on B-mode and color Doppler sonographic features may predict if a thyroid nodule is hot or cold. *European Radiology* **29**:8, 4258-4265. [Crossref]

58. Keri Detweiler, Dawn M. Elfenbein, Daniel Mayers. 2019. Evaluation of Thyroid Nodules. *Surgical Clinics of North America* **99**:4, 571-586. [Crossref]

59. Janeil Mitchell, Linwah Yip. 2019. Decision Making in Indeterminate Thyroid Nodules and the Role of Molecular Testing. *Surgical Clinics of North America* **99**:4, 587-598. [Crossref]

60. Alexandria D. McDow, Susan C. Pitt. 2019. Extent of Surgery for Low-Risk Differentiated Thyroid Cancer. *Surgical Clinics of North America* **99**:4, 599-610. [Crossref]

61. Mamoona Khokhar, Mira Milas. 2019. Management of Nodal Disease in Thyroid Cancer. *Surgical Clinics of North America* **99**:4, 611-632. [Crossref]

62. Agnieszka Walczyk, Janusz Kopczyński, Danuta Gąsior-Perczak, Iwona Pałyga, Artur Kowalik, Magdalena Chrapek, Maria Hejnold, Stanisław Góźdź, Aldona Kowalska. 2019. Poorly differentiated thyroid cancer in the context of the revised 2015 American Thyroid Association Guidelines and the Updated American Joint Committee on Cancer/Tumor-Node-Metastasis Staging System (eighth edition). *Clinical Endocrinology* **91**:2, 331-339. [Crossref]

63. Konstantinos A. Toulis, David Viola, George Gkoutos, Deepiksana Keerthy, Kristien Boelaert, Krishnarajah Nirantharakumar. 2019. Risk of incident circulatory disease in patients treated for differentiated thyroid carcinoma with no history of cardiovascular disease. *Clinical Endocrinology* **91**:2, 323-330. [Crossref]

64. Pierpaolo Trimboli, Rose Ngu, Benedicte Royer, Luca Giovanella, Claude Bigorgne, Ricard Simo, Paul Carroll, Gilles Russ. 2019. A multicentre validation study for the EU-TIRADS using histological diagnosis as a gold standard. *Clinical Endocrinology* **91**:2, 340-347. [Crossref]

65. QingAn Yu, KunPeng Liu, ChangMing Xie, DaKun Ma, YaoHua Wu, HongChi Jiang, WenJie Dai. 2019. Development and validation of a preoperative prediction model for follicular thyroid carcinoma. *Clinical Endocrinology* **91**:2, 348-355. [Crossref]

66. Pim J. Bongers, Wouter P. Kluijfhout, Raoul Verzijl, Mattan Lustgarten, Marloes Vermeer, David P. Goldstein, Karen Devon, Lorne E. Rotstein, Sylvia L. Asa, James D. Brierley, Richard W. Tsang, Shereen Ezzat, Menno R. Vriens, Ozgur Mete, Jesse D. Pasternak. 2019. Papillary Thyroid Cancers with Focal Tall Cell Change are as Aggressive as Tall Cell Variants and Should Not be Considered as Low-Risk Disease. *Annals of Surgical Oncology* **26**:8, 2533-2539. [Crossref]

67. T. Porcelli, F. Sessa, C. Luongo, D. Salvatore. 2019. Local ablative therapy of oligoprogressive TKI-treated thyroid cancer. *Journal of Endocrinological Investigation* **42**:8, 871-879. [Crossref]

68. Kayoko Mizuno, Masato Takeuchi, Yuji Kanazawa, Morimasa Kitamura, Kazuki Ide, Koichi Omori, Koji Kawakami. 2019. Recurrent laryngeal nerve paralysis after thyroid cancer surgery and intraoperative nerve monitoring. *The Laryngoscope* **129**:8, 1954-1960. [Crossref]

69. So Jin Yoon, Dong Gyu Na, Hye Yun Gwon, Wooyul Paik, Won Jun Kim, Jae Seok Song, Myoung Sook Shim. 2019. Similarities and Differences Between Thyroid Imaging Reporting and Data Systems. *American Journal of Roentgenology* **213**:2, W76-W84. [Crossref]

70. Young Ki Lee, Hokyou Lee, Seunghee Han, Hyein Jung, Dong Yeob Shin, Kee-Hyun Nam, Woong Youn Chung, Eun Jig Lee. 2019. Association between Thyroid-Stimulating Hormone Level after Total Thyroidectomy and Hypercholesterolemia in Female Patients with Differentiated Thyroid Cancer: A Retrospective Study. *Journal of Clinical Medicine* **8**:8, 1106. [Crossref]

71. Salvatore Gitto, Sotirios Bisdas, Ilaria Emili, Luca Nicosia, Lorenzo Carlo Pescatori, Kunwar Bhatia, Ravi K. Lingam, Francesco Sardanelli, Luca Maria Sconfienza, Giovanni Mauri. 2019. Clinical practice guidelines on ultrasound-guided fine needle aspiration biopsy of thyroid nodules: a critical appraisal using AGREE II. *Endocrine* **65**:2, 371-378. [Crossref]

72. Pierpaolo Trimboli, Federico Pelloni, Fabiano Bini, Franco Marinozzi, Luca Giovanella. 2019. High-intensity focused ultrasound (HIFU) for benign thyroid nodules: 2-year follow-up results. *Endocrine* **65**:2, 312-317. [Crossref]

73. Lei Zheng, Guiyu Wang, Wei Guo, Deng Pan, Laiping Xie, Song He, Chaoxue Luo, Hongmin Li, Yaling Ran, Shiyang Wu, Fang Liu, Xiaoli Zhang, Dingde Huang. 2019. NIS and epithelial-mesenchymal transition marker expression of circulating tumor cells for predicting and monitoring the radioactive iodine-131 therapy effect in differentiated thyroid cancers. *Molecular Biology Reports* **46**:4, 4201-4212. [Crossref]

Downloaded by Memorial Sloan Kettering from www.liebertpub.com at 08/14/19. For personal use only.

74. Carlos Gustavo Rivera-Robledo, David Velázquez-Fernández, Juan Pablo Pantoja, Mauricio Sierra, Bernardo Pérez-Enriquez, Raul Rivera-Moscoso, Mónica Chapa, Miguel F. Herrera. 2019. Recurrent Papillary Thyroid Carcinoma to the Cervical Lymph Nodes: Outcomes of Compartment-Oriented Lymph Node Resection. *World Journal of Surgery* **23**. . [Crossref]

75. Bin Xu, Ronald Ghossein. 2019. Critical Prognostic Parameters in the Anatomic Pathology Reporting of Differentiated Follicular Cell-Derived Thyroid Carcinoma. *Cancers* **11**:8, 1100. [Crossref]

76. Kim Brian W.. 2019. A Gene Expression Classifier Can Predict Lateral Nodal Involvement in Papillary Thyroid Microcarcinoma. *Clinical Thyroidology* **31**:8, 336-338. [Citation] [Full Text] [PDF] [PDF Plus]

77. Angell Trevor E.. 2019. Thyroid Cancer Patients with Good Prognosis Continue to Worry Years after Diagnosis. *Clinical Thyroidology* **31**:8, 346-348. [Citation] [Full Text] [PDF] [PDF Plus]

78. Emerson Charles H.. 2019. Tumor Volume Doubling Time Is Useful in the Active Surveillance of Papillary Thyroid Microcarcinomas. *Clinical Thyroidology* **31**:8, 339-342. [Citation] [Full Text] [PDF] [PDF Plus]

79. Orr Lauren E., Yeh Michael W., Livhits Masha J.. 2019. Do Patients with Low- and Intermediate-Risk Thyroid Cancer Need Continuing Postoperative Neck Surveillance Ultrasounds?. *Clinical Thyroidology* **31**:8, 343-345. [Citation] [Full Text] [PDF] [PDF Plus]

80. Mikhail Fridman, Olga Krasko, Daniel Igor Branovan, Sviatlana Dabryian, Arthur Pisarenko, Chung Yau Lo, Alfred King-yin Lam. 2019. Factors affecting the approaches and complications of surgery in childhood papillary thyroid carcinomas. *European Journal of Surgical Oncology* . [Crossref]

81. Lin Chen, Jia Zhan, Xue-Hong Diao, Ying-Chun Liu, Yi-Xin Shi, Yue Chen, Wei-Wei Zhan. 2019. Additional Value of Superb Microvascular Imaging for Thyroid Nodule Classification with the Thyroid Imaging Reporting and Data System. *Ultrasound in Medicine & Biology* **45**:8, 2040-2048. [Crossref]

82. Eleonora Molinaro. 2019. Impatto della estensione extralinfodale nella stratificazione del rischio del carcinoma papillare della tiroide. *L'Endocrinologo* **20**:4, 255-256. [Crossref]

83. Eleonora Monti, Mariella Dono, Edoardo Gonella, Bruno Spina, Francesca Pitto, Floriana Petrogalli, Lucia Conte, Eleonora Ambrosetti, Michele N. Minuto, Gian Luca Ansaldo, Silvia Morbelli, Simona Zupo, Massimo Giusti. 2019. An H-TERT Mutated Skin Metastasis as First Occurrence in a Case of Follicular Thyroid Carcinoma. *Frontiers in Endocrinology* **10**. . [Crossref]

84. Yan Zhang, Ming-bo Zhang, Yu-kun Luo, Jie Li, Ying Zhang, Jie Tang. 2019. Effect of chronic lymphocytic thyroiditis on the efficacy and safety of ultrasound-guided radiofrequency ablation for papillary thyroid microcarcinoma. *Cancer Medicine* **40**. . [Crossref]

85. Allen L. Feng, Sidharth V. Puram, Michael C. Singer, Rahul Modi, Dipti Kamani, Gregory W. Randolph. 2019. Increased prevalence of neural monitoring during thyroidectomy: Global surgical survey. *The Laryngoscope* **263**. . [Crossref]

86. Shobha Parajuli, Rachel Jug, Sara Ahmadi, Xiaoyin "Sara" Jiang. 2019. Hurthle cell predominance impacts results of Afirma gene expression classifier and ThyroSeq molecular panel performance in indeterminate thyroid nodules. *Diagnostic Cytopathology* **125**. . [Crossref]

87. Luca Giovanella, Frederik A. Verburg, Pierpaolo Trimboli, Mauro Imperiali, Franco Keller, Luca Ceriani. 2019. Measuring thyroglobulin in patients with thyroglobulin autoantibodies: evaluation of the clinical impact of BRAHMS Kryptor® Tg-minirecovery test in a large series of patients with differentiated thyroid carcinoma. *Clinical Chemistry and Laboratory Medicine (CCLM)* **57**:8, 1185-1191. [Crossref]

88. Papaleontiou Maria, Reyes-Gastelum David, Gay Brittany L., Ward Kevin C., Hamilton Ann S., Hawley Sarah T., Haymart Megan R.. Worry in Thyroid Cancer Survivors with a Favorable Prognosis. *Thyroid*, ahead of print. [Abstract] [Full Text] [PDF] [PDF Plus]

89. Haiqing Sun, Haitao Zheng, Xiaojie Wang, Qingdong Zeng, Ping Wang, Yong Wang. 2019. Comparison of transoral endoscopic thyroidectomy vestibular approach, total endoscopic thyroidectomy via areola approach, and conventional open thyroidectomy: a retrospective analysis of safety, trauma, and feasibility of central neck dissection in the treatment of papillary thyroid carcinoma. *Surgical Endoscopy* **155**. . [Crossref]

90. Jia Zhan, Xuehong Diao, Yue Chen, Wenping Wang, Hong Ding. 2019. Predicting cervical lymph node metastasis in patients with papillary thyroid cancer (PTC) - Why contrast-enhanced ultrasound (CEUS) was performed before thyroidectomy. *Clinical Hemorheology and Microcirculation* **72**:1, 61-73. [Crossref]

91. Hui-Xiong Xu, Kun Yan, Bo-Ji Liu, Wen-Ying Liu, Li-Na Tang, Qi Zhou, Jin-Yu Wu, En-Sheng Xue, Bin Shen, Qing Tang, Qin Chen, Hong-Yuan Xue, Ying-Jia Li, Jun Guo, Bin Wang, Fang Li, Chun-Yang Yan, Quan-Shui Li, Yan-Qing Wang, Wei Zhang, Chang-Jun Wu, Wen-Hui Yu, Su-Jin Zhou. 2019. Guidelines and recommendations on the clinical use of shear wave elastography for evaluating thyroid nodule1. *Clinical Hemorheology and Microcirculation* **72**:1, 39-60. [Crossref]

Downloaded by Memorial Sloan Kettering from www.liebertpub.com at 08/14/19. For personal use only.

92. P. Premoli, M. L. Tanda, E. Piantanida, G. Veronesi, D. Gallo, E. Masiello, S. Rosetti, C. Cusini, F. Boi, J. Bulla, R. Rodia, S. Mariotti, V. Capelli, M. Rotondi, F. Magri, L. Chiovato, R. Rocchi, M. C. Campopiano, R. Elisei, P. Vitti, F. Barbato, T. Pilli, M. G. Castagna, F. Pacini, L. Bartalena. 2019. Features and outcome of differentiated thyroid carcinoma associated with Graves' disease: results of a large, retrospective, multicenter study. *Journal of Endocrinological Investigation* **41**. . [Crossref]

93. Pierpaolo Trimboli, Marco Castellana, Luca Maria Sconfienza, Camilla Virili, Lorenzo Carlo Pescatori, Roberto Cesareo, Francesco Giorgino, Roberto Negro, Luca Giovanella, Giovanni Mauri. 2019. Efficacy of thermal ablation in benign non-functioning solid thyroid nodule: A systematic review and meta-analysis. *Endocrine* **69**. . [Crossref]

94. Anabela Zunino, Fabián Pitoia, Eduardo Faure, Adriana Reyes, Mónica Sala, Rosana Sklate, Verónica Ilera, Inés Califano. 2019. Unusual metastases from differentiated thyroid carcinoma: analysis of 36 cases. *Endocrine* **12**. . [Crossref]

95. Xin-Yun Zhang, Jian-Wen Sun, Zhong-Ling Qiu, Yang Wang, Xiao-Yue Chen, Jin-Hua Zhao, Quan-Yong Luo. 2019. Clinical outcomes and prognostic factors in patients with no less than three distant organ system metastases from differentiated thyroid carcinoma. *Endocrine* **68**. . [Crossref]

96. van Velsen Evert F.S., Stegenga Merel T., van Kemenade Folkert J., Kam Boen L.R., van Ginhoven Tessa M., Visser W. Edward, Peeters Robin P.. Evaluating the 2015 American Thyroid Association Risk Stratification System in High-Risk Papillary and Follicular Thyroid Cancer Patients. *Thyroid*, ahead of print. [Abstract] [Full Text] [PDF] [PDF Plus] [Supplementary Material]

97. K. Passek, N. Zulauf, M. H. Bendels, D. Quarcoo, G. M. Oremek. 2019. Der Tumormarker Thyreoglobulin. *Zentralblatt für Arbeitsmedizin, Arbeitsschutz und Ergonomie* **67**. . [Crossref]

98. Yibo Ma, Feng Qian, Jianfeng Wang, Yanping Liu, Shuiqing Liu. 2019. Primary accessory thyroid carcinoma with negative 99m TcO 4 - SPECT/CTimaging: a case report and literature review. *Journal of International Medical Research* **57**, 030006051985973. [Crossref]

99. Jennifer L Sauter, Heidi Lehrke, Xiaotun Zhang, Osamah T Al Badri, Rene Rodriguez-Gutierrez, Danae A Delivanis, Naykky Singh Ospina, Diane Donegan, Oksana Hamidi, Nicole Iñiguez-Ariza, Anu Sharma, Nana Esi N Kittah, Shrikant U Tamhane, Maria D Hurtado Andrade, Anupam Kotwal, Sarah M Jenkins, Grant Spears, Michael Rivera, Diana S Dean, Michael R Henry. 2019. Assessment of The Bethesda System for Reporting Thyroid Cytopathology. *American Journal of Clinical Pathology* **87**. . [Crossref]

100. Kong Sung Hye, Ryu Junsun, Kim Min Joo, Cho Sun Wook, Song Young Shin, Yi Ka Hee, Park Do Joon, Hwangbo Yul, Lee You Jin, Lee Kyu Eun, Kim Su-jin, Jeong Woo-Jin, Chung Eun-Jae, Hah Jeong Hun, Choi June Young, Ryu Chang Hwan, Jung Yuh-Seog, Moon Jae Hoon, Lee Eun Kyung, Park Young Joo. Longitudinal Assessment of Quality of Life According to Treatment Options in Low-Risk Papillary Thyroid Microcarcinoma Patients: Active Surveillance or Immediate Surgery (Interim Analysis of MAeSTro). *Thyroid*, ahead of print. [Abstract] [Full Text] [PDF] [PDF Plus] [Supplementary Material]

101. Dr. Christine E Cherella, Dr. Trevor E Angell, Dr. Danielle M Richman, Dr. Mary C Frates, Dr. Carol B Benson, Dr. Francis D Moore, Jr., Dr. Justine A Barletta, Dr. Monica Hollowell, Dr. Jessica R. Smith, Dr. Erik K Alexander, Dr. Edmund S Cibas, Dr. Ari J Wassner. Differences in Thyroid Nodule Cytology and Malignancy Risk between Children and Adults. *Thyroid* **0**:ja. . [Abstract] [PDF] [PDF Plus]

102. Cesar A. Lam, Melissa J. McGettigan, Zachary J. Thompson, Laila Khazai, Christine H. Chung, Barbara A. Centeno, Bryan McIver, Pablo Valderrabano. 2019. Ultrasound characterization for thyroid nodules with indeterminate cytology: inter-observer agreement and impact of combining pattern-based and scoring-based classifications in risk stratification. *Endocrine* **371**. . [Crossref]

103. Hongxun Wu, Bingjie Zhang, Gangming Cai, Jie Li, Xiaobo Gu. 2019. American College of Radiology thyroid imaging report and data system combined with K-RAS mutation improves the management of cytologically indeterminate thyroid nodules. *PLOS ONE* **14**:7, e0219383. [Crossref]

104. G Nakache, G Yahav, G H Siloni, I Barshack, E Alon, M Wolf, D Fixler. 2019. The use of fluorescence lifetime technology in benign and malignant thyroid tissues. *The Journal of Laryngology & Otology* **9**, 1-4. [Crossref]

105. Ilze Fridrihsone, Arnis Abolins, Andrejs Vanags, Dzeina Mezale, Guntis Bahs. Liquid Biopsy in Patients with Thyroid Carcinoma . [Crossref]

106. Qin Liu, Liang-zhi Pan, Min Hu, Jian-ying Ma. 2019. Molecular Network-Based Identification of Circular RNA-Associated ceRNA Network in Papillary Thyroid Cancer. *Pathology & Oncology Research* **68**. . [Crossref]

107. Mateusz Buda, Benjamin Wildman-Tobriner, Jenny K. Hoang, David Thayer, Franklin N. Tessler, William D. Middleton, Maciej A. Mazurowski. 2019. Management of Thyroid Nodules Seen on US Images: Deep Learning May Match Performance of Radiologists. *Radiology* 181343. [Crossref]

108. Ohad Ronen, Hector Cohen, Mor Abu. 2019. Review of a single institution's fine needle aspiration results for thyroid nodules: Initial observations and lessons for the future. *Cytopathology* . [Crossref]

Downloaded by Memorial Sloan Kettering from www.liebertpub.com at 08/14/19. For personal use only.

109. Lauren P. Wallner, David Reyes-Gastelum, Ann S. Hamilton, Kevin C. Ward, Sarah T. Hawley, Megan R. Haymart. 2019. Patient-Perceived Lack of Choice in Receipt of Radioactive Iodine for Treatment of Differentiated Thyroid Cancer. *Journal of Clinical Oncology* JCO.18.02228. [Crossref]

110. Sergiy V. Kushchayev, Yevgeniya S. Kushchayeva, Sri Harsha Tella, Tetiana Glushko, Karel Pacak, Oleg M. Teytelboym. 2019. Medullary Thyroid Carcinoma: An Update on Imaging. *Journal of Thyroid Research* **2019**, 1-17. [Crossref]

111. Hye Seung Lee, Jae-Wook Lee, Ji Hyun Park, Wan-Seop Kim, Hye Seung Han, Seung Eun Lee. 2019. Comprehensive analysis for diagnosis of preoperative non-invasive follicular thyroid neoplasm with papillary-like nuclear features. *PLOS ONE* **14**:7, e0218046. [Crossref]

112. Alexandria D. McDow, Cynthia M. Shumway, Susan C. Pitt, David F. Schneider, Rebecca S. Sippel, Kristin L. Long. 2019. Utility of Early Postoperative Unstimulated Thyroglobulin in Influencing Decision Making in Patients with Papillary Thyroid Carcinoma. *Annals of Surgical Oncology* **33**. . [Crossref]

113. A. M. Belyaev, L. M. Berstein, D. A. Vasilyev, E. V. Kostromina, L. A. Krasilnikova, Z. A. Radzhabova, A. S. Artemyeva, E. V. Tsyrlina, P. I. Krzhivitsky, A. A. Mikhetko, A. V. Mishchenko. 2019. Petrov Thyroid Cancer Score (PTCS): evaluation of practical significance on the basis of postsurgical morphological analysis. *Head and Neck Tumors (HNT)* **9**:2, 10-16. [Crossref]

114. Orloff Lisa A.. 2019. Not So Fast: Nuclear Medicine Societies Espouse Collaboration while Countering Swing of the 131I Pendulum in Differentiated Thyroid Cancer. *Clinical Thyroidology* **31**:7, 272-275. [Citation] [Full Text] [PDF] [PDF Plus]

115. Biermann Martin. 2019. New Radiolabeled Proteins May Hold Promise for PET Imaging of Recurrent Differentiated Thyroid Cancer. *Clinical Thyroidology* **31**:7, 279-281. [Citation] [Full Text] [PDF] [PDF Plus]

116. Angell Trevor E.. 2019. Initial Treatment of Thyroid Cancer with Levothyroxine Results in Metabolic Changes Among Women. *Clinical Thyroidology* **31**:7, 282-284. [Citation] [Full Text] [PDF] [PDF Plus]

117. Berna İmge Aydoğan, Mustafa Şahin, Koray Ceyhan, Olgun Deniz, Özgür Demir, Rifat Emral, Vedia Tonyukuk Gedik, Ali Rıza Uysal, Demet Çorapçıoğlu. 2019. The influence of thyroid nodule size on the diagnostic efficacy and accuracy of ultrasound guided fine-needle aspiration cytology. *Diagnostic Cytopathology* **47**:7, 682-687. [Crossref]

118. Su Min Ha, Dong Gyu Na, Ji-Hoon Kim, Soo Chin Kim, Jung Hwan Baek. 2019. Validation of web-based thyroid imaging reporting and data system in atypia or follicular lesion of undetermined significance thyroid nodules. *Head & Neck* **41**:7, 2215-2224. [Crossref]

119. Ming-Jun Hu, Chi Zhang, Ling Liang, Sheng-Ying Wang, Xu-Cai Zheng, Qian Zhang, Chun-Xiao Jiang, Qi Zhong, Fen Huang. 2019. Fasting serum glucose, thyroid-stimulating hormone, and thyroid hormones and risk of papillary thyroid cancer: A case-control study. *Head & Neck* **41**:7, 2277-2284. [Crossref]

120. Zeyad T. Sahli, Ashwyn K. Sharma, Joseph K. Canner, Farah Karipineni, Osama Ali, Satomi Kawamoto, Jen-Fan Hang, Aarti Mathur, Syed Z. Ali, Martha A. Zeiger, Sheila Sheth. 2019. TIRADS Interobserver Variability Among Indeterminate Thyroid Nodules: A Single-Institution Study. *Journal of Ultrasound in Medicine* **38**:7, 1807-1813. [Crossref]

121. Sophie Gorostis, Thibaut Raguin, Olivier Schneegans, Catherine Takeda, Christian Debry, Agnès Dupret-Bories. 2019. Incidental thyroid papillary microcarcinoma: survival and follow-up. *The Laryngoscope* **129**:7, 1722-1726. [Crossref]

122. Brian H. H. Lang, Yu-Cho Woo, Keith Wan-Hang Chiu. 2019. Two sequential applications of high-intensity focused ultrasound (HIFU) ablation for large benign thyroid nodules. *European Radiology* **29**:7, 3626-3634. [Crossref]

123. Viktoria F. Koehler, James Nagarajah, Michael C. Kreißl, C. Benedikt Westphalen, Andrei Todica, Christine Spitzweg. 2019. Medikamentöse Therapieoptionen beim radioiodrefraktären differenzierten Schilddrüsenkarzinom. *Der Onkologe* **25**:7, 601-608. [Crossref]

124. Julia Isabelle Staubitz, Thomas Johannes Musholt. 2019. Risikoadaptiertes chirurgisches Vorgehen beim differenzierten Schilddrüsenkarzinom – ist weniger mehr?. *Der Onkologe* **25**:7, 596-600. [Crossref]

125. Si Hyoung Kim, Jun Goo Kang, Chul Sik Kim, Sung-Hee Ihm, Moon Gi Choi, Seong Jin Lee. 2019. Evodiamine in combination with histone deacetylase inhibitors has synergistic cytotoxicity in thyroid carcinoma cells. *Endocrine* **65**:1, 110-120. [Crossref]

126. Xiao-Li Wu, Jia-Rui Du, Hui Wang, Chun-Xiang Jin, Guo-Qing Sui, Dong-Yan Yang, Yuan-Qiang Lin, Qiang Luo, Ping Fu, He-Qun Li, Deng-Ke Teng. 2019. Comparison and preliminary discussion of the reasons for the differences in diagnostic performance and unnecessary FNA biopsies between the ACR TIRADS and 2015 ATA guidelines. *Endocrine* **65**:1, 121-131. [Crossref]

127. Alfredo Campennì, Ernesto Amato, Riccardo Laudicella, Angela Alibrandi, Davide Cardile, Salvatore Antonio Pignata, Francesco Trimarchi, Rosaria Maddalena Ruggeri, Lucrezia Auditore, Sergio Baldari. 2019. Recombinant human thyrotropin (rhTSH) versus Levo-thyroxine withdrawal in radioiodine therapy of differentiated thyroid cancer patients: differences in abdominal absorbed dose. *Endocrine* **65**:1, 132-137. [Crossref]

Downloaded by Memorial Sloan Kettering from www.liebertpub.com at 08/14/19. For personal use only.

128. Tian Tian, Rui Huang, Bin Liu. 2019. Is TSH suppression still necessary in intermediate- and high-risk papillary thyroid cancer patients with pre-ablation stimulated thyroglobulin <1 ng/mL before the first disease assessment?. *Endocrine* **65**:1, 149-154. [Crossref]

129. Lei Yan, Jayjay Blanco, Vijaya Reddy, Samer Al-Khudari, Bobby Tajudeen, Paolo Gattuso. 2019. Clinicopathological features of papillary thyroid microcarcinoma with a diameter less than or equal to 5 mm. *American Journal of Otolaryngology* **40**:4, 560-563. [Crossref]

130. Julia I. Staubitz, Petra B. Musholt, Thomas J. Musholt. 2019. The surgical dilemma of primary surgery for follicular thyroid neoplasms. *Best Practice & Research Clinical Endocrinology & Metabolism* 101292. [Crossref]

131. Ashok R. Shaha, R. Michael Tuttle. 2019. Completion thyroidectomy-indications and complications. *European Journal of Surgical Oncology* **45**:7, 1129-1131. [Crossref]

132. Woo Ri Choi, Jong-Lyel Roh, Gyungyup Gong, Kyung-Ja Cho, Seung-Ho Choi, Soon Yuhl Nam, Sang Yoon Kim. 2019. Multifocality of papillary thyroid carcinoma as a risk factor for disease recurrence. *Oral Oncology* **94**, 106-110. [Crossref]

133. Laura Fernández-Vañes, José Luis Llorente, Patricia García-Cabo, Marta Menéndez, Daniel Pedregal, Juan Pablo Rodrigo, Fernando López. 2019. Manejo de los carcinomas diferenciados de tiroides. *Acta Otorrinolaringológica Española* **70**:4, 200-206. [Crossref]

134. Benjamin C. James, Lava Timsina, Ryan Graham, Peter Angelos, David A. Haggstrom. 2019. Changes in total thyroidectomy versus thyroid lobectomy for papillary thyroid cancer during the past 15 years. *Surgery* **166**:1, 41-47. [Crossref]

135. Hengqiang Zhao, Tao Huang, Hehe Li. 2019. Risk factors for skip metastasis and lateral lymph node metastasis of papillary thyroid cancer. *Surgery* **166**:1, 55-60. [Crossref]

136. Ashok R. Shaha, R. Michael Tuttle. 2019. Commentary "Incidence of total thyroidectomy and lobectomy". *Surgery* **166**:1, 48-49. [Crossref]

137. Sneha Goswami, Benjamin J. Peipert, Michael N. Mongelli, Sasha K. Kurumety, Irene B. Helenowski, Susan E. Yount, Cord Sturgeon. 2019. Clinical factors associated with worse quality-of-life scores in United States thyroid cancer survivors. *Surgery* **166**:1, 69-74. [Crossref]

138. Alan Zambeli-Ljepović, Frances Wang, Michaela A. Dinan, Terry Hyslop, Michael T. Stang, Sanziana A. Roman, Julie A. Sosa, Randall P. Scheri. 2019. Extent of surgery for low-risk thyroid cancer in the elderly: Equipoise in survival but not in short-term outcomes. *Surgery* . [Crossref]

139. Zhan-Qiang Jin, Hong-Zhen Yu, Chun-Jian Mo, Rong-Qing Su. 2019. Clinical Study of the Prediction of Malignancy in Thyroid Nodules: Modified Score versus 2017 American College of Radiology's Thyroid Imaging Reporting and Data System Ultrasound Lexicon. *Ultrasound in Medicine & Biology* **45**:7, 1627-1637. [Crossref]

140. Anqi Jin, Yi Li, Jian Shen, Yichun Zhang, Yan Wang. 2019. Clinical Value of a Computer-Aided Diagnosis System in Thyroid Nodules: Analysis of a Reading Map Competition. *Ultrasound in Medicine & Biology* . [Crossref]

141. Raquel Andrade de Siqueira, Ana Paula dos Santos Rodrigues, Lucas Massao Miamae, Eduardo Kiyoshi Tomimori, Erika Aparecida Silveira. 2019. Thyroid Nodules in Severely Obese Patients: Frequency and Risk of Malignancy on Ultrasonography. *Endocrine Research* 1-8. [Crossref]

142. Nobuya Monden, Takahiro Asakage, Naomi Kiyota, Akihiro Homma, Kazuto Matsuura, Nobuhiro Hanai, Takeshi Kodaira, Sadamoto Zenda, Hirofumi Fujii, Makoto Tahara, Tomoya Yokota, Tetsuo Akimoto, Shigemichi Iwae, Tetsuro Onitsuka, Takenori Ogawa, Susumu Okano, Shunji Takahashi, Yasushi Shimizu, Koichiro Yonezawa, Ryuichi Hayashi. 2019. A review of head and neck cancer staging system in the TNM classification of malignant tumors (eighth edition). *Japanese Journal of Clinical Oncology* **49**:7, 589-595. [Crossref]

143. Xing-Jia Li, Xiao-dong Mao, Guo-fang Chen, Qi-feng Wang, Xiao-qiu Chu, Xin Hu, Wen-bo Ding, Zheng Zeng, Jian-hua Wang, Shu-hang Xu, Chao Liu. 2019. High BRAFV600E mutation frequency in Chinese patients with papillary thyroid carcinoma increases diagnostic efficacy in cytologically indeterminate thyroid nodules. *Medicine* **98**:28, e16343. [Crossref]

144. Xin Wu, Binglu Li, Chaoji Zheng, Xiaodong He. 2019. Predicting factors of lateral neck lymph node metastases in patients with papillary thyroid microcarcinoma. *Medicine* **98**:27, e16386. [Crossref]

145. Ting Yang, Shi-Yang Zheng, Ju Jiao, Qiong Zou, Yong Zhang. 2019. Radioiodine remnant ablation in papillary thyroid microcarcinoma. *Nuclear Medicine Communications* **40**:7, 711-719. [Crossref]

146. Ivan Šamija, Neven Mateša, Sanja Kožaj, Ivana Majstorović, Ante Bolanča, Zvonko Kusić. 2019. HMGA2 Gene Expression in Fine-needle Aspiration Samples of Thyroid Nodules as a Marker for Preoperative Diagnosis of Thyroid Cancer. *Applied Immunohistochemistry & Molecular Morphology* **27**:6, 471-476. [Crossref]

Downloaded by Memorial Sloan Kettering from www.liebertpub.com at 08/14/19. For personal use only.

147. Brenda French, Georgette Hattier, Stacey K. Mardekian. 2019. Utility of Tumor Capsule Thickness as a Predictor of Invasion in Encapsulated Follicular Variant of Papillary Thyroid Carcinoma and a Diagnostic Tool for Noninvasive Follicular Thyroid Neoplasm With Papillary-Like Nuclear Features. *International Journal of Surgical Pathology* **8**, 106689691985908. [Crossref]

148. Young Ki Lee, Daham Kim, Dong Yeob Shin, Cho Rok Lee, Eun Jig Lee, Sang-Wook Kang, Jandee Lee, Jong Ju Jeong, Kee-Hyun Nam, Woong Youn Chung, Cheong Soo Park. 2019. The Prognosis of Papillary Thyroid Cancer with Initial Distant Metastasis is Strongly Associated with Extensive Extrathyroidal Extension: A Retrospective Cohort Study. *Annals of Surgical Oncology* **26**:7, 2200-2209. [Crossref]

149. Valeria Ramundo, Livia Lamartina, Rosa Falcone, Laura Ciotti, Cristiano Lomonaco, Marco Biffoni, Laura Giacomelli, Marianna Maranghi, Cosimo Durante, Giorgio Grani. 2019. Is thyroid nodule location associated with malignancy risk?. *Ultrasonography* **38**:3, 231-235. [Crossref]

150. Orit Twito, Simona Grozinsky-Glasberg, Sigal Levy, Gideon Bachar, David J Gross, Carlos Benbassat, Alon Rozental, Dania Hirsch. 2019. Clinico-pathologic and dynamic prognostic factors in sporadic and familial medullary thyroid carcinoma: an Israeli multi-center study. *European Journal of Endocrinology* **181**:1, 13-21. [Crossref]

151. Simona Censi, Susi Barollo, Elisabetta Grespan, Sara Watutantrige-Fernando, Jacopo Manso, Maurizio Iacobone, Eric Casal Ide, Francesca Galuppini, Ambrogio Fassina, Loris Bertazza, Federica Vianello, Gianmaria Pennelli, Caterina Mian. 2019. Prognostic significance of TERT promoter and BRAF mutations in TIR-4 and TIR-5 thyroid cytology. *European Journal of Endocrinology* **181**:1, 1-11. [Crossref]

152. Jae Hyun Park, Jong Ho Yoon. 2019. Lobectomy in patients with differentiated thyroid cancer: indications and follow-up. *Endocrine-Related Cancer* **26**:7, R381-R393. [Crossref]

153. Carles Zafon, Joan Gil, Beatriz Pérez-González, Mireia Jordà. 2019. DNA methylation in thyroid cancer. *Endocrine-Related Cancer* **26**:7, R415-R439. [Crossref]

154. Hao Fu, Lin Cheng, Yuchen Jin, Libo Chen. 2019. Thyrotoxicosis with concomitant thyroid cancer. *Endocrine-Related Cancer* **26**:7, R395-R413. [Crossref]

155. Jordi L. Reverter, Federico Vázquez, Manuel Puig-Domingo. 2019. Diagnostic Performance Evaluation of a Computer-Assisted Imaging Analysis System for Ultrasound Risk Stratification of Thyroid Nodules. *American Journal of Roentgenology* **213**:1, 169-174. [Crossref]

156. Jae Park, Jun Lee, Jae Won Cho, Jong Yoon. 2019. The Learning Curve of Robotic Thyroid Surgery and the Avoidance of Temporary Hypoparathyroidism after Total Thyroidectomy and Concomitant Central Compartment Node Dissection: A Single Surgeon's Experience. *Applied Sciences* **9**:13, 2594. [Crossref]

157. Mara Ventura, Miguel Melo, Graça Fernandes, Francisco Carrilho. 2019. RISK OF MALIGNANCY IN THYROID CYTOLOGY: THE IMPACT OF THE RECLASSIFICATION OF NONINVASIVE FOLLICULAR THYROID NEOPLASM WITH PAPILLARY-LIKE NUCLEAR FEATURES (NIFTP). *Endocrine Practice* **25**:7, 642-647. [Crossref]

158. Kennichi Kakudo, Andrey Bychkov. 2019. Cytologically Borderline Thyroid Nodules as a Key Target to Reduce Overdiagnosis and Overtreatment of Thyroid Cancer. *Archives of Pathology & Laboratory Medicine* **143**:7, 784-785. [Crossref]

159. Laura Fernández-Vañes, José Luis Llorente, Patricia García-Cabo, Marta Menéndez, Daniel Pedregal, Juan Pablo Rodrigo, Fernando López. 2019. Management of Differentiated Thyroid Carcinomas. *Acta Otorrinolaringologica (English Edition)* **70**:4, 200-206. [Crossref]

160. Jeon Min Ji, Lee Yu-Mi, Sung Tae-Yon, Han Minkyu, Shin Yong-Wook, Kim Won Gu, Kim Tae Yong, Chung Ki-Wook, Shong Young Kee, Kim Won Bae. 2019. Quality of Life in Patients with Papillary Thyroid Microcarcinoma Managed by Active Surveillance or Lobectomy: A Cross-Sectional Study. *Thyroid* **29**:7, 956-962. [Abstract] [Full Text] [PDF] [PDF Plus]

161. Wu Di, Gomes Lima Cristiane J., Moreau Shari L., Kulkarni Kanchan, Zeymo Alexander, Burman Kenneth D., Wartofsky Leonard, Van Nostrand Douglas. 2019. Improved Survival After Multimodal Approach with 131I Treatment in Patients with Bone Metastases Secondary to Differentiated Thyroid Cancer. *Thyroid* **29**:7, 971-978. [Abstract] [Full Text] [PDF] [PDF Plus]

162. Kim Hye In, Hyeon Jiyeon, Park So Young, Ahn Hyeon Seon, Kim Kyunga, Han Ji Min, Bae Ji Cheol, Shin Jung Hee, Kim Jee Soo, Kim Sun Wook, Chung Jae Hoon, Kim Tae Hyuk, Oh Young Lyun. 2019. Impact of Extranodal Extension on Risk Stratification in Papillary Thyroid Carcinoma. *Thyroid* **29**:7, 963-970. [Abstract] [Full Text] [PDF] [PDF Plus] [Supplementary Material]

163. Z. Jason Qian, Michael C. Jin, Kara D. Meister, Uchechukwu C. Megwalu. 2019. Pediatric Thyroid Cancer Incidence and Mortality Trends in the United States, 1973-2013. *JAMA Otolaryngology–Head & Neck Surgery* **145**:7, 617. [Crossref]

164. Ruisheng Liu, Huijuan Li, Fuxiang Liang, Liang Yao, Jieting Liu, Meixuan Li, Liujiao Cao, Bing Song. 2019. Diagnostic accuracy of different computer-aided diagnostic systems for malignant and benign thyroid nodules classification in ultrasound images. *Medicine* **98**:29, e16227. [Crossref]

Downloaded by Memorial Sloan Kettering from www.liebertpub.com at 08/14/19. For personal use only.

165. Kristina J. Nicholson, Cindy Y. Teng, Kelly L. McCoy, Sally E. Carty, Linwah Yip. 2019. Completion thyroidectomy: A risky undertaking?. *The American Journal of Surgery* . [Crossref]

166. Miao Ying, Zhang Ling-Fei, Zhang Min, Guo Rui, Liu Mo-Fang, Li Biao. 2019. Therapeutic Delivery of miR-143 Targeting Tumor Metabolism in Poorly Differentiated Thyroid Cancer Xenografts and Efficacy Evaluation Using 18F-FDG MicroPET-CT. *Human Gene Therapy* **30**:7, 882-892. [Abstract] [Full Text] [PDF] [PDF Plus] [Supplementary Material]

167. Oded Cohen, Yonatan Lahav, Doron Halperin, Moshe Yehuda. 2019. Surgeon-Performed Ultrasonographic Evaluation and Predication for Large Thyroid Nodules—A Case-Control Study. *Surgery* . [Crossref]

168. M Zalzali, A Debreuve, C Richard, C Filieri, C Schvartz. 2019. Micropapillary carcinoma: description and rise in incidence in the French Marne-Ardennes thyroid cancer registry. *Annales d'Endocrinologie* . [Crossref]

169. Xiao-Wen Liang, Yong-Yi Cai, Jin-Sui Yu, Jian-Yi Liao, Zhi-Yi Chen. 2019. Update on thyroid ultrasound. *Chinese Medical Journal* 1. [Crossref]

170. S. Dwamena, N. Patel, R. Egan, M. Stechman, D. Scott-Coombes. 2019. Impact of the change from the seventh to eighth edition of the AJCC TNM classification of malignant tumours and comparison with the MACIS prognostic scoring system in non-medullary thyroid cancer. *BJS Open* **22**. . [Crossref]

171. Jing Yang, Rong Zheng, Meng Liang, Yingying Jia, Lin Lin, Jianhua Geng, Shengzu Chen, Ye-Xiong Li. 2019. Association of the Cumulative Dose of Radioactive Iodine Therapy With Overall Survival in Patients With Differentiated Thyroid Cancer and Pulmonary Metastases. *Frontiers in Oncology* **9**. . [Crossref]

172. M. A. Kropotov, E. A. Grivachev, L. P. Yakovleva, A. V. Khodos, M. S. Tigrov. 2019. Central neck lymph node dissection for papillary thyroid cancer. *Malignant tumours* **9**:2, 27-34. [Crossref]

173. Kristen L. Partyka, Karen Trevino, Melissa L. Randolph, Harvey Cramer, Howard H. Wu. 2019. Risk of malignancy and neoplasia predicted by three molecular testing platforms in indeterminate thyroid nodules on fine-needle aspiration. *Diagnostic Cytopathology* **56**. . [Crossref]

174. Shuai Xue, Li Zhang, Peisong Wang, Jia Liu, Yue Yin, Meishan Jin, Liang Guo, Yuhua Zhou, Guang Chen. 2019. Predictive Factors of Recurrence for Multifocal Papillary Thyroid Microcarcinoma With Brafv600e Mutation: A Single Center Study of 1,207 Chinese Patients. *Frontiers in Endocrinology* **10**. . [Crossref]

175. Seo Young Kang, Ji-In Bang, Keon Wook Kang, Ho-young Lee, June-Key Chung. 2019. FDG PET/CT for the early prediction of RAI therapy response in patients with metastatic differentiated thyroid carcinoma. *PLOS ONE* **14**:6, e0218416. [Crossref]

176. Izkhakov Elena, Vaisman Nachum, Barnes Sophie, Barchana Micha, Stern Naftali, Keinan-Boker Lital. Body Composition, Resting Energy Expenditure, and Metabolic Changes in Women Diagnosed with Differentiated Thyroid Carcinoma. *Thyroid*, ahead of print. [Abstract] [Full Text] [PDF] [PDF Plus]

177. Qingqing He, Jian Zhu, Dayong Zhuang, Ziyi Fan, Luming Zheng, Peng Zhou, Fang Yu, Gang Wang, Gaofeng Ni, Xuefeng Dong, Meng Wang, Xiaolei Li, Changrui Liu, Dan Wang, Tao Yue, Lei Hou, Mengdi Wang, Dandan Li. 2019. Robotic lateral cervical lymph node dissection via bilateral axillo-breast approach for papillary thyroid carcinoma: a single-center experience of 260 cases. *Journal of Robotic Surgery* **19**. . [Crossref]

178. Jia-Wei Feng, Hua Pan, Lei Wang, Jing Ye, Yong Jiang, Zhen Qu. 2019. Determine the Optimal Extent of Thyroidectomy and Lymphadenectomy for Patients With Papillary Thyroid Microcarcinoma. *Frontiers in Endocrinology* **10**. . [Crossref]

179. Jong Heon Lim, Dong Wook Kim, Jin Young Park, Yoo Jin Lee, Ha Kyoung Park, Tae Kwun Ha, Do Hun Kim, Soo Jin Jung, Ji Sun Park, Sung Ho Moon, Ki Jung Ahn, Hye Jin Baek. 2019. Ultrasonography, Cytology, and Thyroglobulin Measurement Results of Cervical Nodal Metastasis in Patients With Unclear Papillary Thyroid Carcinoma. *Frontiers in Endocrinology* **10**. . [Crossref]

180. Jia-wei LI, Cai Chang, Jia-ying Chen, Zhao-ting Shi, Min Chen. 2019. Nodule Size Effect on Diagnostic Performance of Ultrasonography and Computed Tomography for Papillary Thyroid Carcinoma. *Current Medical Imaging Formerly: Current Medical Imaging Reviews* **15**:5, 489-495. [Crossref]

181. Fu Li, Denghua Pan, Yuquan Wu, Jinbo Peng, Qing Li, Xiaolong Gui, Wei Ma, Hong Yang, Yun He, Junqiang Chen. 2019. Ultrasound characteristics of thyroid nodules facilitate interpretation of the malignant risk of Bethesda system III/IV thyroid nodules and inform therapeutic schedule. *Diagnostic Cytopathology* **19**. . [Crossref]

182. Eva Krcalova, Jiri Horacek, Filip Gabalec, Pavel Zak, Jiri Dolezal. 2019. Salivary gland function in thyroid cancer patients with radioiodine administration history. *Biomedical Papers* . [Crossref]

183. Martin Freesmeyer, Christian Kühnel, Falk Gühne, Philipp Seifert. 2019. Standard Needle Magnetization for Ultrasound Needle Guidance: First Clinical Experiences in Fine-Needle Aspiration Cytology of Thyroid Nodules. *Journal of Ultrasound in Medicine* **32**. . [Crossref]

Downloaded by Memorial Sloan Kettering from www.liebertpub.com at 08/14/19. For personal use only.

184. Husniye Baser, Oya Topaloglu, Muhammet C. Bilginer, Serap Ulusoy, Aydan Kılıcarslan, Elif Ozdemir, Reyhan Ersoy, Bekir Cakir. 2019. Are cytologic and histopathologic features of hot thyroid nodules different from cold thyroid nodules?. *Diagnostic Cytopathology* **159**. . [Crossref]

185. D. Zhang, E. Caruso, H. Sun, A. Anuwong, R. Tufano, G. Materazzi, G. Dionigi, H. Y. Kim. 2019. Classifying pain in transoral endoscopic thyroidectomy. *Journal of Endocrinological Investigation* **28**. . [Crossref]

186. Jesper Roed Sorensen, Trine Printz, Jenny Iwarsson, Ågot Møller Grøntved, Helle Døssing, Laszlo Hegedüs, Steen Joop Bonnema, Christian Godballe, Camilla Slot Mehlum. 2019. The Impact of Post-thyroidectomy Paresis on Quality of Life in Patients with Nodular Thyroid Disease. *Otolaryngology–Head and Neck Surgery* **375**, 019459981985537. [Crossref]

187. Yoshiyuki Saito, Hirofumi Kawakubo, Hiroshi Takami, Junya Aoyama, Shuhei Mayanagi, Tomoyuki Irino, Kazumasa Fukuda, Koichi Suda, Rieko Nakamura, Norihito Wada, Yuko Kitagawa. 2019. Thyroid and Parathyroid Functions After Pharyngo-Laryngo-Esophagectomy for Cervical Esophageal Cancer. *Annals of Surgical Oncology* **4**. . [Crossref]

188. Kimberly D. Miller, Leticia Nogueira, Angela B. Mariotto, Julia H. Rowland, K. Robin Yabroff, Catherine M. Alfano, Ahmedin Jemal, Joan L. Kramer, Rebecca L. Siegel. 2019. Cancer treatment and survivorship statistics, 2019. *CA: A Cancer Journal for Clinicians* **8**. . [Crossref]

189. Vera Kachko, Andrew Zaretsky, Vladimir Vanushko, Nadezhda Platonova, Aleksandr Abrosimov, Galina Semkina. 2019. Somatic mutation testing: the role in differential diagnosis of thyroid neoplasms. *Endocrine Surgery* . [Crossref]

190. Harshawn S. Malhi, Erik Velez, Brittany Kazmierski, Mittul Gulati, Corinne Deurdulian, Steven Y. Cen, Edward G. Grant. 2019. Peripheral Thyroid Nodule Calcifications on Sonography: Evaluation of Malignant Potential. *American Journal of Roentgenology* 1-4. [Crossref]

191. Chadi Nimeh Abdel-Halim, Tine Rosenberg, Kristine Bjørndal, Anders Rørbæk Madsen, John Jakobsen, Helle Døssing, Mette Bay, Anders Thomassen, Anne Lerberg Nielsen, Christian Godballe. 2019. Risk of Malignancy in FDG-Avid Thyroid Incidentalomas on PET/CT: A Prospective Study. *World Journal of Surgery* **71**. . [Crossref]

192. Raad Alwithenani, Sarah DeBrabandere, Irina Rachinsky, S. Danielle MacNeil, Mahmoud Badreddine, Stan Van Uum. 2019. Performance of the American Thyroid Association Risk Classification in a Single Center Cohort of Pediatric Patients with Differentiated Thyroid Cancer: A Retrospective Study. *Journal of Thyroid Research* **2019**, 1-7. [Crossref]

193. Zhu Catherine, Livhits Masha J., Yeh Michael W.. 2019. Differentiated Thyroid Management of Thyroid Nodules and Differentiated Thyroid Cancer According to the 2015 ATA Guidelines Is More Cost-Effective than Using the 2009 Guidelines. *Clinical Thyroidology* **31**:6, 244-246. [Citation] [Full Text] [PDF] [PDF Plus]

194. Kim Brian W.. 2019. Multimodal Treatment of Thyroid Cancer Bone Metastases Appears to Improve Survival as Compared to I-131 Alone. *Clinical Thyroidology* **31**:6, 250-252. [Citation] [Full Text] [PDF] [PDF Plus]

195. Dong Wenwu, Horiuchi Kiyomi, Tokumitsu Hiroki, Sakamoto Akiko, Noguchi Eiichiro, Ueda Yoshinori, Okamoto Takahiro. 2019. Time-Varying Pattern of Mortality and Recurrence from Papillary Thyroid Cancer: Lessons from a Long-Term Follow-Up. *Thyroid* **29**:6, 802-808. [Abstract] [Full Text] [PDF] [PDF Plus]

196. Zhang Bin, Tian Jie, Pei Shufang, Chen Yubing, He Xin, Dong Yuhao, Zhang Lu, Mo Xiaokai, Huang Wenhui, Cong Shuzhen, Zhang Shuixing. 2019. Machine Learning–Assisted System for Thyroid Nodule Diagnosis. *Thyroid* **29**:6, 858-867. [Abstract] [Full Text] [PDF] [PDF Plus] [Supplementary Material]

197. Korevaar Tim I.M., Haymart Megan R.. 2019. A History of Thyroid Cancer Does Not Meaningfully Complicate Pregnancy. *Thyroid* **29**:6, 758-759. [Citation] [Full Text] [PDF] [PDF Plus]

198. Daniels Gilbert H., Kopp Peter A.. 2019. Guidelines Are Not Gospel!. *Thyroid* **29**:6, 753-757. [Citation] [Full Text] [PDF] [PDF Plus]

199. QuNing, ZhangTing-ting, WenShi-shuai, SunGuo-hua, ShiRong-liang, XiangJun, WangYu-long, ShenQiang, LiDuan-shu, ZhuYong-xue, WangYu, JiQing-hai. 2019. The Application of Hemithyroidectomy Plus Central Neck Dissection in the Initial Surgical Treatment of Papillary Thyroid Microcarcinoma. *VideoEndocrinology* **6**:2. . [Abstract] [Full Text] [PDF] [PDF Plus]

200. ChiofaloMaria G., PezzulloLuciano. 2019. Papillary Thyroid Cancer with Synchronous Lymph Nodes Metastases: Left Lateral Neck Dissection and Total Thyroidectomy with Continuous Intraoperative Nerve. *VideoEndocrinology* **6**:2. . [Abstract] [Full Text] [PDF] [PDF Plus]

201. Peter R. Dixon, George Tomlinson, Jesse David Pasternak, Ozgur Mete, Chaim M. Bell, Anna M. Sawka, David P. Goldstein, David R. Urbach. 2019. The Role of Disease Label in Patient Perceptions and Treatment Decisions in the Setting of Low-Risk Malignant Neoplasms. *JAMA Oncology* **5**:6, 817. [Crossref]

202. Saad A. Khan, Bo Ci, Yang Xie, David E. Gerber, Muhammad S. Beg, Steven I. Sherman, Maria E. Cabanillas, Naifa L. Busaidy, Barbara A. Burtness, Andreas M. Heilmann, Mark Bailey, Jeffrey S. Ross, David J. Sher, Siraj M. Ali. 2019. Unique mutation patterns in anaplastic thyroid cancer identified by comprehensive genomic profiling. *Head & Neck* **41**:6, 1928-1934. [Crossref]

Downloaded by Memorial Sloan Kettering from www.liebertpub.com at 08/14/19. For personal use only.

203. Uchechukwu C. Megwalu, Lisa A. Orloff, Yifei Ma. 2019. Adjuvant external beam radiotherapy for locally invasive papillary thyroid cancer. *Head & Neck* **41**:6, 1719-1724. [Crossref]

204. Oded Cohen, Taiba Zornitzki, Tom Raz Yarkoni, Yonatan Lahav, Doron Schindel, Doron Halperin, Moshe Yehuda. 2019. Follow-up of large thyroid nodules without surgery: Patient selection and long-term outcomes. *Head & Neck* **41**:6, 1696-1702. [Crossref]

205. Hyeon Jin Lee, Young Joong Kim, Hye Yeon Han, Jae Young Seo, Cheol Mog Hwang, KeumWon Kim. 2019. Ultrasound-guided needle biopsy of large thyroid nodules: Core needle biopsy yields more reliable results than fine needle aspiration. *Journal of Clinical Ultrasound* **47**:5, 255-260. [Crossref]

206. Gali Shapira-Zaltsberg, Elka Miller, Claudia Martinez-Rios, Juan Bass, Ellen B. Goldbloom, Ken Tang, Lamia Hayawi, Kerri Highmore. 2019. Comparison of the diagnostic performance of the 2017 ACR TI-RADS guideline to the Kwak guideline in children with thyroid nodules. *Pediatric Radiology* **49**:7, 862-868. [Crossref]

207. Jennifer E. Lim-Dunham. 2019. Ultrasound guidelines for pediatric thyroid nodules: proceeding with caution. *Pediatric Radiology* **49**:7, 851-853. [Crossref]

208. Murat Tuncel, Nilda Süslü. 2019. Radioguided occult lesion localization in patients with recurrent thyroid cancer. *European Archives of Oto-Rhino-Laryngology* **276**:6, 1757-1766. [Crossref]

209. Rachel Jug, Shobha Parajuli, Sara Ahmadi, Xiaoyin "Sara" Jiang. 2019. Negative Results on Thyroid Molecular Testing Decrease Rates of Surgery for Indeterminate Thyroid Nodules. *Endocrine Pathology* **30**:2, 134-137. [Crossref]

210. Esther Diana Rossi, William C. Faquin, Zubair Baloch, Guido Fadda, Lester Thompson, Luigi Maria Larocca, Liron Pantanowitz. 2019. Noninvasive Follicular Thyroid Neoplasm with Papillary-Like Nuclear Features (NIFTP): Update and Diagnostic Considerations—a Review. *Endocrine Pathology* **30**:2, 155-162. [Crossref]

211. Jose R. W. Martínez, Sergio Vargas-Salas, Soledad Urra Gamboa, Estefanía Muñoz, José Miguel Domínguez, Augusto León, Nicolás Droppelmann, Antonieta Solar, Mark Zafereo, F. Christopher Holsinger, Hernán E. González. 2019. The Combination of RET, BRAF and Demographic Data Identifies Subsets of Patients with Aggressive Papillary Thyroid Cancer. *Hormones and Cancer* **10**:2-3, 97-106. [Crossref]

212. Seong Young Kwon, Yingjie Zhang, Yansong Lin, Byeong-Cheol Ahn, Hee-Seung Bom. 2019. Role of thyroglobulin in the management of patients with differentiated thyroid cancer. *Clinical and Translational Imaging* **7**:3, 209-217. [Crossref]

213. P. W. Rosario, G. Mourão, M. R. Calsolari. 2019. Risk of recurrence in patients with papillary thyroid carcinoma and minimal extrathyroidal extension not treated with radioiodine. *Journal of Endocrinological Investigation* **42**:6, 687-692. [Crossref]

214. H. Liu, Y. Li, Y. Mao. 2019. Local lymph node recurrence after central neck dissection in papillary thyroid cancers: A meta analysis. *European Annals of Otorhinolaryngology, Head and Neck Diseases* . [Crossref]

215. Marcin Barczyński, Małgorzata Stopa-Barczyńska. 2019. Hemithyroidectomy for benign euthyroid asymmetric nodular goitre. *Best Practice & Research Clinical Endocrinology & Metabolism* 101288. [Crossref]

216. Christelle de la Fouchardiere, Abir Alghuzlan, Stéphane Bardet, Isabelle Borget, Françoise Borson Chazot, Christine Do Cao, Yann Godbert, Laurence Leenhardt, Slimane Zerdoud, Sophie Leboulleux. 2019. The medical treatment of radioiodine-refractory differentiated thyroid cancers in 2019. A TUTHYREF® network review. *Bulletin du Cancer* . [Crossref]

217. Rasmus Reinke, Jes Sloth Mathiesen, Stine Rosenkilde Larsen, Christoffer Holst Hahn, Henrik Baymler Pedersen, Jens Bentzen, Sten Schytte, Christian Godballe, Stefano Christian Londero. 2019. Incidental and Non-incidental Papillary Thyroid Microcarcinoma in Denmark 1996–2015: A national study on incidence, outcome and thoughts on active surveillance. *Cancer Epidemiology* **60**, 46-50. [Crossref]

218. Thomas Johannes Musholt, Julia Isabelle Staubitz, Rafael Jaime Antonio Cámara, Petra Brigitta Musholt, Diana Humberg, Erik Springer, Arno Schad. 2019. Detection of RET rearrangements in papillary thyroid carcinoma using RT-PCR and FISH techniques - A molecular and clinical analysis. *European Journal of Surgical Oncology* **45**:6, 1018-1024. [Crossref]

219. Hu Hei, Yongping Song, Jianwu Qin. 2019. Individual prediction of lateral neck metastasis risk in patients with unifocal papillary thyroid carcinoma. *European Journal of Surgical Oncology* **45**:6, 1039-1045. [Crossref]

220. Ambria S. Moten, Huaqing Zhao, Charles M. Intenzo, Alliric I. Willis. 2019. Disparity in the use of adjuvant radioactive iodine ablation among high-risk papillary thyroid cancer patients. *European Journal of Surgical Oncology* . [Crossref]

221. Anu Sharma, Marius N. Stan. 2019. Thyrotoxicosis: Diagnosis and Management. *Mayo Clinic Proceedings* **94**:6, 1048-1064. [Crossref]

222. Min Gao, Wen Chen, Hao Sun, Lili Fan, Wei Wang, Cong Du, Yanting Chen, Laixiang Lin, Elizabeth N. Pearce, Jun Shen, Yuangui Cheng, Chongdan Wang, Wanqi Zhang. 2019. Excessive iodine intake is associated with formation of thyroid nodules in pregnant Chinese women. *Nutrition Research* **66**, 61-67. [Crossref]

Downloaded by Memorial Sloan Kettering from www.liebertpub.com at 08/14/19. For personal use only.

223. Rodis D. Paparodis, Dimitra Bantouna, Shahnawaz Imam, Juan Carlos Jaume. 2019. The non-interventional approach to papillary thyroid microcarcinomas. An "active surveillance" dilemma. *Surgical Oncology* **29**, 113-117. [Crossref]

224. Ambria S. Moten, Huaqing Zhao, Alliric I. Willis. 2019. The overuse of radioactive iodine in low-risk papillary thyroid cancer patients. *Surgical Oncology* **29**, 184-189. [Crossref]

225. Hyeong Won Yu, Maqbool Hussain, Muhammad Afzal, Taqdir Ali, June Young Choi, Ho-Seong Han, Sungyoung Lee. 2019. Use of mind maps and iterative decision trees to develop a guideline-based clinical decision support system for routine surgical practice: case study in thyroid nodules. *Journal of the American Medical Informatics Association* **26**:6, 524-536. [Crossref]

226. SCOTT A. SULLIVAN. 2019. Thyroid Nodules and Thyroid Cancer in Pregnancy. *Clinical Obstetrics and Gynecology* **62**:2, 365-372. [Crossref]

227. SCOTT A. SULLIVAN, RYAN D. CUFF, CHRISTOPHER G. GOODIER, ALISON K. CHAPMAN, SANJITA B. CHITTIMOJU, MARY STERRETT. 2019. Case Studies in Thyroid Dysfunction and Pregnancy. *Clinical Obstetrics and Gynecology* **62**:2, 388-397. [Crossref]

228. Dapeng Xiang, Bin Tian, Tianyao Yang, Zhiyu Li. 2019. miR-222 expression is correlated with the ATA risk stratifications in papillary thyroid carcinomas*. *Medicine* **98**:25, e16050. [Crossref]

229. Y.-H. Huang, C. Chen, C.-H. Lee, E.-W. Loh, K.-W. Tam. 2019. Wound Closure after Thyroid and Parathyroid Surgery: A Meta-Analysis of Randomized Controlled Trials. *Scandinavian Journal of Surgery* **108**:2, 101-108. [Crossref]

230. Judith Gebauer, Claire Higham, Thorsten Langer, Christian Denzer, Georg Brabant. 2019. Long-Term Endocrine and Metabolic Consequences of Cancer Treatment: A Systematic Review. *Endocrine Reviews* **40**:3, 711-767. [Crossref]

231. Amblessed E. Onuma, Eliza W. Beal, Fadi Nabhan, Tasha Hughes, William B. Farrar, John Phay, Matthew D. Ringel, Richard T. Kloos, Lawrence A. Shirley. 2019. Long-Term Efficacy of Lymph Node Reoperation for Persistent Papillary Thyroid Cancer: 13-Year Follow-Up. *Annals of Surgical Oncology* **26**:6, 1737-1743. [Crossref]

232. Myung Hi Yoo, Hye Jeong Kim, In Ho Choi, Ji-Oh Mok, Hyeong Kyu Park, Dong Won Byun, Kyoil Suh. 2019. Differential Diagnosis of Thyroid Follicular Neoplasm from Nodular Hyperplasia by Shear Wave Elastography. *Soonchunhyang Medical Science* **25**:1, 10-19. [Crossref]

233. Gustavo Bittar Cunha, Luciana Cristante Izar Marino, André Yamaya, Cristiane Kochi, Osmar Monte, Carlos Alberto Longui, Adriano Namo Cury, Eduardo de Faria Castro Fleury. 2019. Elastography for the evaluation of thyroid nodules in pediatric patients. *Radiologia Brasileira* **52**:3, 141-147. [Crossref]

234. M. Angelyn Bethel, Rishi A. Patel, Vivian P. Thompson, Peter Merrill, Shelby D. Reed, Yanhong Li, Sara Ahmadi, Brian G. Katona, Stephanie M. Gustavson, Peter Ohman, Nayyar Iqbal, Robert F. Gagel, Adrian F. Hernandez, John B. Buse, Rury R. Holman. 2019. Changes in Serum Calcitonin Concentrations, Incidence of Medullary Thyroid Carcinoma, and Impact of Routine Calcitonin Concentration Monitoring in the EXenatide Study of Cardiovascular Event Lowering (EXSCEL). *Diabetes Care* **42**:6, 1075-1080. [Crossref]

235. Li Zhang, Guilan Zou. 2019. Role of thyroid ultrasound combined with thyroglobulin in the diagnosis of postoperative recurrence of thyroid cancer. *Minerva Endocrinologica* **44**:2. . [Crossref]

236. Zeng Z. Yap, Won W. Kim, Sang-Wook Kang, Cho R. Lee, Jandee Lee, Jong J. Jeong, Kee-Hyun Nam, Woong Y. Chung. 2019. Level V lymph node metastasis in N1b papillary thyroid carcinoma patients: contributing factors and pattern of metastasis. *Chirurgia* **32**:3. . [Crossref]

237. Ji Eun Choi, Ja Seong Bae, Dong-Jun Lim, So Lyung Jung, Chan Kwon Jung. 2019. Atypical Histiocytoid Cells and Multinucleated Giant Cells in Fine-Needle Aspiration Cytology of the Thyroid Predict Lymph Node Metastasis of Papillary Thyroid Carcinoma. *Cancers* **11**:6, 816. [Crossref]

238. Stéphanie Servagi Vernat, Jonathan Khalifa, Xu-Shan Sun, Emmanuel Kammerer, Eivind Blais, Jean-Christophe Faivre, Terence Tai-Weng Sio, Jianji Pan, Hao Qiu, Gil Bar-Sela, Jean-Marc Simon, Julia Salleron, Juliette Thariat. 2019. 10-Year Locoregional Control with Postoperative External Beam Radiotherapy in Patients with Locally Advanced High-Risk Non-Anaplastic Thyroid Carcinoma De Novo or at Relapse, a Propensity Score Analysis. *Cancers* **11**:6, 849. [Crossref]

239. Laura A. Boos, Anja Schmitt, Holger Moch, Paul Komminoth, Cedric Simillion, Ilaria Marinoni, Yuri E. Nikiforov, Marina N. Nikiforova, Aurel Perren, Matthias S. Dettmer. 2019. MiRNAs Are Involved in Tall Cell Morphology in Papillary Thyroid Carcinoma. *Cancers* **11**:6, 885. [Crossref]

240. Andrea Tumminia, Federica Vinciguerra, Miriam Parisi, Marco Graziano, Laura Sciacca, Roberto Baratta, Lucia Frittitta. 2019. Adipose Tissue, Obesity and Adiponectin: Role in Endocrine Cancer Risk. *International Journal of Molecular Sciences* **20**:12, 2863. [Crossref]

241. Cristian M. Slough, Dipti Kamani, Gregory W. Randolph. 2019. In-Office Ultrasonographic Evaluation of Neck Masses/Thyroid Nodules. *Otolaryngologic Clinics of North America* **52**:3, 559-575. [Crossref]

Downloaded by Memorial Sloan Kettering from www.liebertpub.com at 08/14/19. For personal use only.

242. Yotsapon Thewjitcharoen, Siriwan Butadej, Soontaree Nakasatien, Phawinpon Chotwanvirat, Sriurai Porramatikul, Sirinate Krittiyawong, Nampetch Lekpittaya, Thep Himathongkam. 2019. Incidence and malignancy rates classified by The Bethesda System for Reporting Thyroid Cytopathology (TBSRTC) – An 8-year tertiary center experience in Thailand. *Journal of Clinical & Translational Endocrinology* **16**, 100175. [Crossref]

243. Eugene Jeong, Joon-Kee Yoon, Su Jin Lee, Euy Young Soh, Jeonghun Lee, Young-Sil An. 2019. Risk Factors for Indeterminate Response After Radioactive Iodine Therapy in Patients With Differentiated Thyroid Cancer. *Clinical Nuclear Medicine* 1. [Crossref]

244. J. Vance, S. M. Gilani. 2019. Thyroid cytopathology: updates and molecular testing. *Pathologica* **111**:2, 51-57. [Crossref]

245. Marika D. Russell, Dipti Kamani, Gregory W. Randolph. 2019. Surgical management of the compromised recurrent laryngeal nerve in thyroid cancer. *Best Practice & Research Clinical Endocrinology & Metabolism* 101282. [Crossref]

246. Dana M. Hartl, Julien Hadoux, Joanne Guerlain, Ingrid Breuskin, Fabienne Haroun, Sophie Bidault, Sophie Leboulleux, Livia Lamartina. 2019. Risk-oriented concept of treatment for intrathyroid papillary thyroid cancer. *Best Practice & Research Clinical Endocrinology & Metabolism* 101281. [Crossref]

247. Krista Chain, Teklu Legesse, Jonathon E. Heath, Paul N. Staats. 2019. Digital image-assisted quantitative nuclear analysis improves diagnostic accuracy of thyroid fine needle aspiration cytology. *Cancer Cytopathology* **2**. . [Crossref]

248. Muhammed Kizilgul, Rupendra Shrestha, Angela Radulescu, Maria R. Evasovich, Lynn A. Burmeister. 2019. Thyroid nodules over 4 cm do not have higher malignancy or benign cytology false-negative rates. *Endocrine* **22**. . [Crossref]

249. Kyle A. Zanocco, Jerome M. Hershman, Angela M. Leung. 2019. Active Surveillance of Low-Risk Thyroid Cancer. *JAMA* **321**:20, 2020. [Crossref]

250. Marco Dell'Aquila, Carmen Gravina, Alessandra Cocomazzi, Sara Capodimonti, Teresa Musarra, Stefania Sfregola, Vincenzo Fiorentino, Luca Revelli, Maurizio Martini, Guido Fadda, Liron Pantanowitz, Luigi Maria Larocca, Esther Diana Rossi. 2019. A large series of hyalinizing trabecular tumors: Cytomorphology and ancillary techniques on fine needle aspiration. *Cancer Cytopathology* **182**. . [Crossref]

251. Jong-hyuk Ahn, Jin Wook Yi. 2019. Transoral endoscopic thyroidectomy for thyroid carcinoma: outcomes and surgical completeness in 150 single-surgeon cases. *Surgical Endoscopy* **136**. . [Crossref]

252. Mijin Kim, Minkyu Han, Min Ji Jeon, Won Gu Kim, In Joo Kim, Jin-Sook Ryu, Won Bae Kim, Young Kee Shong, Tae Yong Kim, Bo Hyun Kim. 2019. Impact of delayed radioiodine therapy in intermediate-/high-risk papillary thyroid carcinoma. *Clinical Endocrinology* **26**. . [Crossref]

253. Kelsey L. Corrigan, Hannah Williamson, Danielle Elliott Range, Donna Niedzwiecki, David M. Brizel, Yvonne M. Mowery. 2019. Treatment Outcomes in Anaplastic Thyroid Cancer. *Journal of Thyroid Research* **2019**, 1-11. [Crossref]

254. 2019. ##########. *Nippon Jibiinkoka Gakkai Kaiho* **122**:5, 724-727. [Crossref]

255. Alexandria D. McDow, Whitney E. Zahnd, Peter Angelos, John D. Mellinger, Sabha Ganai. 2019. Impact of Rurality on National Trends in Thyroid Cancer Incidence and Long-Term Survival. *The Journal of Rural Health* **69**. . [Crossref]

256. Yan Shen, Miao Liu, Jie He, Shu Wu, Ming Chen, Yonglin Wan, Linjun Gao, Xiaoyan Cai, Jun Ding, Xiaohong Fu. 2019. Comparison of Different Risk-Stratification Systems for the Diagnosis of Benign and Malignant Thyroid Nodules. *Frontiers in Oncology* **9**. . [Crossref]

257. So Yeon Yang, Jung Hee Shin, Soo Yeon Hahn, Yaeji Lim, Seok Young Hwang, Tae Hyuk Kim, Jee Soo Kim. 2019. Comparison of ultrasonography and CT for preoperative nodal assessment of patients with papillary thyroid cancer: diagnostic performance according to primary tumor size. *Acta Radiologica* **77**, 028418511984767. [Crossref]

258. Jiang Ke, Lei Jianyong, Liu Ying, Li Genpeng, Song Linlin, Li Zhihui, Li Jinnan, Su Xueying, Jiang Yong, Zhu Jingqiang. 2019. The use of The Bethesda System for Reporting Thyroid Cytopathology in a Chinese population: An analysis of 13 351 specimens. *Diagnostic Cytopathology* **7**. . [Crossref]

259. Aslihan Semiz-Oysu, Mustafa Demir, Fatma Kulali, Yasar Bukte, Cagatay Oysu. 2019. The Sonographic Findings of Papillary Thyroid Microcarcinomas. *Journal of Diagnostic Medical Sonography* **11**, 875647931984764. [Crossref]

260. Yijie Dong, Jianqiao Zhou, Zhenhua Liu, Ting Luo, Weiwei Zhan. 2019. Efficacy Assessment of Ultrasound Guided Lauromacrogol Injection for Ablation of Benign Cystic and Predominantly Cystic Thyroid Nodules. *Frontiers in Pharmacology* **10**. . [Crossref]

261. Se Hyun Paek, Hye Ah Lee, Hyungju Kwon, Kyung Ho Kang, Sung Jun Park. 2019. Comparison of robot-assisted modified radical neck dissection using a bilateral axillary breast approach with a conventional open procedure after propensity score matching. *Surgical Endoscopy* **23**. . [Crossref]

Downloaded by Memorial Sloan Kettering from www.liebertpub.com at 08/14/19. For personal use only.

262. Lin Chen, Yi-xin Shi, Ying-chun Liu, Jia Zhan, Xue-hong Diao, Yue Chen, Wei-wei Zhan. 2019. The values of shear wave elastography in avoiding repeat fine-needle aspiration for thyroid nodules with nondiagnostic and undetermined cytology. *Clinical Endocrinology* **36**. . [Crossref]

263. Fish Stephanie A.. 2019. Afirma GSC Shows Improved Results in Evaluating Indeterminate Thyroid Nodules, Especially Hürthle-Cell Lesions. *Clinical Thyroidology* **31**:5, 198-200. [Citation] [Full Text] [PDF] [PDF Plus]

264. Toft Daniel J.. 2019. Reconsidering the Treatment of Multifocal Papillary Thyroid Carcinoma. *Clinical Thyroidology* **31**:5, 204-206. [Citation] [Full Text] [PDF] [PDF Plus]

265. Van Nostrand Douglas. 2019. Should Radioiodine Scanning Be Considered in a Patient Who Has Been Started on a BRAF and/or MEK Inhibitor?. *Clinical Thyroidology* **31**:5, 211-215. [Citation] [Full Text] [PDF] [PDF Plus]

266. Duskin-Bitan Hadar, Leibner Anat, Amitai Oren, Diker-Cohen Talia, Hirsch Dania, Benbassat Carlos, Shimon Ilan, Robenshtok Eyal. 2019. Bone-Marrow Suppression in Elderly Patients Following Empiric Radioiodine Therapy: Real-Life Data. *Thyroid* **29**:5, 683-691. [Abstract] [Full Text] [PDF] [PDF Plus]

267. Mauri Giovanni, Pacella Claudio Maurizio, Papini Enrico, Solbiati Luigi, Goldberg Shraga Nahum, Ahmed Muneeb, Sconfienza Luca Maria. 2019. Image-Guided Thyroid Ablation: Proposal for Standardization of Terminology and Reporting Criteria. *Thyroid* **29**:5, 611-618. [Abstract] [Full Text] [PDF] [PDF Plus]

268. Oh Hye-Seon, Kwon Hyemi, Song Eyun, Jeon Min Ji, Kim Tae Yong, Lee Jeong Hyun, Kim Won Bae, Shong Young Kee, Chung Ki-Wook, Baek Jung Hwan, Kim Won Gu. 2019. Tumor Volume Doubling Time in Active Surveillance of Papillary Thyroid Carcinoma. *Thyroid* **29**:5, 642-649. [Abstract] [Full Text] [PDF] [PDF Plus] [Supplementary Material]

269. Angell Trevor E., Heller Howard T., Cibas Edmund S., Barletta Justine A., Kim Matthew I., Krane Jeffrey F., Marqusee Ellen. 2019. Independent Comparison of the Afirma Genomic Sequencing Classifier and Gene Expression Classifier for Cytologically Indeterminate Thyroid Nodules. *Thyroid* **29**:5, 650-656. [Abstract] [Full Text] [PDF] [PDF Plus]

270. Berna Evranos, Sefika Burcak Polat, Fatma Neslihan Cuhaci, Husniye Baser, Oya Topaloglu, Aydan Kilicarslan, Mehmet Kilic, Reyhan Ersoy, Bekir Cakir. 2019. A cancer of undetermined significance: Incidental thyroid carcinoma. *Diagnostic Cytopathology* **47**:5, 412-416. [Crossref]

271. Tiara Grossi Rocha, Pedro Weslley Rosario, Alexandre Lemos Silva, Maurício Buzelin Nunes, Maria Regina Calsolari. 2019. Thyroid imaging reporting and data system (TI-RADS) of the American College of Radiology (ACR) for predicting malignancy in thyroid nodules >1 cm with indeterminate cytology. *Diagnostic Cytopathology* **47**:5, 523-525. [Crossref]

272. Soumaya Rammeh, Emna Romdhane, Asma Sassi, Linda Belhajkacem, Ahlem Blel, Meriem Ksentini, Rim Lahiani, Faten Farah, Mamia Ben Salah, Mohamed Ferjaoui. 2019. Accuracy of fine-needle aspiration cytology of head and neck masses. *Diagnostic Cytopathology* **47**:5, 394-399. [Crossref]

273. Eun Kyoung Hong, Ji-hoon Kim, Joongyub Lee, Roh-Eul Yoo, Soo Chin Kim, Min Joo Kim, Young Joo Park, Eun-Jae Chung, Young Jin Ryu, Eunjung Lee, Koung Mi Kang, Tae Jin Yun, Seung Hong Choi, Chul-Ho Sohn. 2019. Diagnostic value of computed tomography combined with ultrasonography in detecting cervical recurrence in patients with thyroid cancer. *Head & Neck* **41**:5, 1206-1212. [Crossref]

274. Joon-Hyop Lee, Yong Soon Chun, Yoo Seung Chung. 2019. Extent of lateral neck dissection for papillary thyroid microcarcinomas. *Head & Neck* **41**:5, 1367-1371. [Crossref]

275. Peng Ng, Cheryl Ho, Wee Boon Tan, Kee Yuan Ngiam, Chwee Ming Lim, Kwok Seng Thomas Loh, Min En Nga, Rajeev Parameswaran. 2019. Predictors of thyroxine replacement following hemithyroidectomy in a south east Asian cohort. *Head & Neck* **41**:5, 1463-1467. [Crossref]

276. Hong Kyu Kim, Dawon Park, Hoon Yub Kim. 2019. Robotic transoral thyroidectomy: Total thyroidectomy and ipsilateral central neck dissection with da Vinci Xi Surgical System. *Head & Neck* **41**:5, 1536-1540. [Crossref]

277. Seth Kay, Robert Miller, Dennis Kraus, David J. Terris. 2019. Evolving phenotype of the head and neck surgeon. *The Laryngoscope* **129**:5, 1150-1154. [Crossref]

278. Kenan Çetin, Hasan E. Sıkar, Şule Temizkan, Cem B. Ofluoğlu, Ayşenur Özderya, Kadriye Aydın, Aylin E. Gül, Hasan F. Küçük. 2019. Does Primary Hyperparathyroidism Have an Association with Thyroid Papillary Cancer? A Retrospective Cohort Study. *World Journal of Surgery* **43**:5, 1243-1248. [Crossref]

279. Lan Wei, Lin Bai, Lina Zhao, Tianyu Yu, Qingjie Ma, Bin Ji. 2019. High-Dose RAI Therapy Justified by Pathological N1a Disease Revealed by Prophylactic Central Neck Dissection for cN0 Papillary Thyroid Cancer Patients: Is it Superior to Low-Dose RAI Therapy?. *World Journal of Surgery* **43**:5, 1256-1263. [Crossref]

280. Nicolas Guignard, Guillaume Chambon, Benjamin Chambert, Yaser Najaf, Benjamin Lallemant. 2019. Fortuitous discovery of non-fluorocholine-fixing papillary carcinoma of vesicular variant of the thyroid. *European Archives of Oto-Rhino-Laryngology* **276**:5, 1541-1544. [Crossref]

Downloaded by Memorial Sloan Kettering from www.liebertpub.com at 08/14/19. For personal use only.

281. Ting Xu, Ya Wu, Run-Xin Wu, Yu-Zhi Zhang, Jing-Yu Gu, Xin-Hua Ye, Wei Tang, Shu-Hang Xu, Chao Liu, Xiao-Hong Wu. 2019. Validation and comparison of three newly-released Thyroid Imaging Reporting and Data Systems for cancer risk determination. *Endocrine* **64**:2, 299-307. [Crossref]

282. Giulia Sapuppo, Martina Tavarelli, Antonino Belfiore, Riccardo Vigneri, Gabriella Pellegriti. 2019. Persistenza vs Recidiva di malattia nel Carcinoma Differenziato della Tiroide. *L'Endocrinologo* **20**:S1, 42-43. [Crossref]

283. Hyun Joo Nahm, Sung Jun Choi, Young Chang Lim. 2019. Conservative thyroidectomy for papillary thyroid microcarcinoma. *American Journal of Otolaryngology* **40**:3, 427-430. [Crossref]

284. Florentino Carral, María del Carmen Ayala, Ana Isabel Jiménez, Concepción García, María Isabel Robles, Eulalia Porras, Vicente Vega. 2019. Rendimiento diagnóstico del sistema de evaluación de riesgo ecográfico del nódulo tiroideo de la American Thyroid Association en endocrinología (estudio ETIEN 3). *Endocrinología, Diabetes y Nutrición* . [Crossref]

285. Lu Li, Yingxia Ying, Changrun Zhang, Wei Wang, Yan Li, Yan Feng, Jun Liang, Huaidong Song, Yan Wang. 2019. Bisphenol A exposure and risk of thyroid nodules in Chinese women: A case-control study. *Environment International* **126**, 321-328. [Crossref]

286. Wei Li, Bin Wang, Zhi-guo Jiang, Yun-jie Feng, Wei Zhang, Ming Qiu. 2019. The role of thymus preservation in parathyroid gland function and surgical completeness after bilateral central lymph node dissection for papillary thyroid cancer: A randomized controlled study. *International Journal of Surgery* **65**, 1-6. [Crossref]

287. Stella K. Kang, Lincoln L. Berland, William W. Mayo-Smith, Jenny K. Hoang, Brian R. Herts, Alec J. Megibow, Pari V. Pandharipande. 2019. Navigating Uncertainty in the Management of Incidental Findings. *Journal of the American College of Radiology* **16**:5, 700-708. [Crossref]

288. Jenny K. Hoang, Jorge D. Oldan, Susan J. Mandel, Bruno Policeni, Vikas Agarwal, Judah Burns, Julie Bykowski, H. Benjamin Harvey, Amy F. Juliano, Tabassum A. Kennedy, Gul Moonis, Jeffrey S. Pannell, Matthew S. Parsons, Jason W. Schroeder, Rathan M. Subramaniam, Matthew T. Whitehead, Amanda S. Corey. 2019. ACR Appropriateness Criteria® Thyroid Disease. *Journal of the American College of Radiology* **16**:5, S300-S314. [Crossref]

289. Joseph M. Aulino, Claudia F.E. Kirsch, Judah Burns, Paul M. Busse, Santanu Chakraborty, Asim F. Choudhri, David B. Conley, Christopher U. Jones, Ryan K. Lee, Michael D. Luttrull, Toshio Moritani, Bruno Policeni, Maura E. Ryan, Lubdha M. Shah, Aseem Sharma, Robert Y. Shih, Rathan M. Subramaniam, Sophia C. Symko, Julie Bykowski. 2019. ACR Appropriateness Criteria® Neck Mass-Adenopathy. *Journal of the American College of Radiology* **16**:5, S150-S160. [Crossref]

290. Khurram Shafique, Zubair Baloch. 2019. Risk stratification of papillary thyroid carcinoma and its variants; from clinicopathologic features to molecular profiling. *Diagnostic Histopathology* **25**:5, 143-153. [Crossref]

291. Sule Canberk, Ana Rita Lima, Marcelo Correia, Rui Batista, Paula Soares, Valdemar Máximo, Manuel Sobrinho Simões. 2019. Oncocytic thyroid neoplasms: from histology to molecular biology. *Diagnostic Histopathology* **25**:5, 154-165. [Crossref]

292. José Manuel Cameselle-Teijeiro, María Rosa Bella Cueto, Catarina Eloy, Ihab Abdulkader, Isabel Amendoeira, Xavier Matías-Guiu, Manuel Sobrinho-Simões. 2019. Tumores de la glándula tiroides. Propuesta para el manejo y estudio de las muestras de pacientes con neoplasias tiroideas. *Revista Española de Patología* . [Crossref]

293. Jill E. Langer. 2019. Sonography of the Thyroid. *Radiologic Clinics of North America* **57**:3, 469-483. [Crossref]

294. M. Estorch, M. Mitjavila, M.A. Muros, E. Caballero. 2019. Tratamiento del cáncer diferenciado de tiroides con radioyodo a la luz de las guías y de la literatura científica. *Revista Española de Medicina Nuclear e Imagen Molecular* **38**:3, 195-203. [Crossref]

295. M. Estorch, M. Mitjavila, M.A. Muros, E. Caballero. 2019. Radioiodine treatment of differentiated thyroid cancer related to guidelines and scientific literature. *Revista Española de Medicina Nuclear e Imagen Molecular (English Edition)* **38**:3, 195-203. [Crossref]

296. Martin Freesmeyer, Thomas Winkens, Christian Kühnel, Thomas Opfermann, Philipp Seifert. 2019. Technetium-99m SPECT/US Hybrid Imaging Compared with Conventional Diagnostic Thyroid Imaging with Scintigraphy and Ultrasound. *Ultrasound in Medicine & Biology* **45**:5, 1243-1252. [Crossref]

297. Wei Zheng, Xuan Wang, Zhongying Rui, Yi Wang, Zhaowei Meng, Renfei Wang. 2019. Clinical features and therapeutic outcomes of patients with papillary thyroid microcarcinomas and larger tumors. *Nuclear Medicine Communications* **40**:5, 477-483. [Crossref]

298. Marco Puccini, Gianpiero Manca, Carlo Maria Neri, Giuseppe Boni, Virginia Coli, Ludovico Maria Garau, Patrick M. Colletti, Domenico Rubello, Piero Buccianti. 2019. Effect of Sentinel Node Biopsy in Clinically N0, BRAF V600E–Mutated, Small Papillary Thyroid Carcinoma. *Clinical Nuclear Medicine* **44**:5, 359-364. [Crossref]

299. Sang Hun Lee, Jong-Lyel Roh, Gyungyup Gong, Kyung-Ja Cho, Seung-Ho Choi, Soon Yuhl Nam, Sang Yoon Kim. 2019. Risk Factors for Recurrence After Treatment of N1b Papillary Thyroid Carcinoma. *Annals of Surgery* **269**:5, 966-971. [Crossref]

Downloaded by Memorial Sloan Kettering from www.liebertpub.com at 08/14/19. For personal use only.

300. Kate Hulse, Adam Williamson, Fraser W. Gibb, Brendan Conn, Iain J. Nixon. 2019. Evaluating the predicted impact of changes to the AJCC/TMN staging system for differentiated thyroid cancer (DTC): A prospective observational study of patients in South East Scotland. *Clinical Otolaryngology* **44**:3, 330-335. [Crossref]

301. Eugenie S Lim, Shanty G Shah, Mona Waterhouse, Scott Akker, William Drake, Nick Plowman, Daniel M Berney, Polly Richards, Ashok Adams, Ewa Nowosinska, Carmel Brennan, Maralyn Druce. 2019. Impact of thyroiditis on 131I uptake during ablative therapy for differentiated thyroid cancer. *Endocrine Connections* **8**:5, 571-578. [Crossref]

302. Pedro Weslley Rosario, Gabriela Franco Mourão. 2019. Noninvasive follicular thyroid neoplasm with papillary-like nuclear features (NIFTP): a review for clinicians. *Endocrine-Related Cancer* **26**:5, R259-R266. [Crossref]

303. Jamie Kaplan, Helmi Khadra, Andrew B. Sholl, Emad Kandil. 2019. DIAGNOSTIC UTILITY OF HUMAN CHORIONIC GONADOTROPIN WASHOUT IN CERVICAL LYMPH NODE FINE-NEEDLE ASPIRATION FOR METASTATIC TESTICULAR CANCER. *AACE Clinical Case Reports* **5**:3, e201-e203. [Crossref]

304. Sara Ahmadi, Taofik Oyekunle, Xiaoyin 'Sara' Jiang, Randall Scheri, Jennifer Perkins, Michael Stang, Sanziana Roman, Julie A. Sosa. 2019. A DIRECT COMPARISON OF THE ATA AND TI-RADS ULTRASOUND SCORING SYSTEMS. *Endocrine Practice* **25**:5, 413-422. [Crossref]

305. Huy Gia Vuong, Thao T. K. Tran, Andrey Bychkov, Chan Kwon Jung, Tadao Nakazawa, Kennichi Kakudo, Ryohei Katoh, Tetsuo Kondo. 2019. CLINICAL IMPACT OF NON-INVASIVE FOLLICULAR THYROID NEOPLASM WITH PAPILLARY-LIKE NUCLEAR FEATURES ON THE RISK OF MALIGNANCY IN THE BETHESDA SYSTEM FOR REPORTING THYROID CYTOPATHOLOGY: A META-ANALYSIS OF 14,153 RESECTED THYROID NODULES. *Endocrine Practice* **25**:5, 491-502. [Crossref]

306. Timothy M. Ullmann, Katherine D. Gray, Dessislava Stefanova, Jessica Limberg, Jessica L. Buicko, Brendan Finnerty, Rasa Zarnegar, Thomas J. Fahey, Toni Beninato. 2019. The 2015 American Thyroid Association guidelines are associated with an increasing rate of hemithyroidectomy for thyroid cancer. *Surgery* . [Crossref]

307. Abbas Ali Tam, Didem Ozdemir, Afra Alkan, Omer Yazicioglu, Nilufer Yildirim, Aylin Kilicyazgan, Reyhan Ersoy, Bekir Cakir. 2019. Toxic nodular goiter and thyroid cancer: Is hyperthyroidism protective against thyroid cancer?. *Surgery* . [Crossref]

308. Yoshiyuki Saito, Kenichi Matsuzu, Kiminori Sugino, Hiroshi Takami, Wataru Kitagawa, Mitsuji Nagahama, Koichi Ito. 2019. The impact of completion thyroidectomy followed by radioactive iodine ablation for patients with lymph node recurrence of papillary thyroid carcinoma. *Surgery* . [Crossref]

309. Marek Ruchala, Kosma Wolinski. 2019. Health-Related Complications of Acromegaly—Risk of Malignant Neoplasms. *Frontiers in Endocrinology* **10**. . [Crossref]

310. Hyun Sook Hong, Ji Ye Lee. 2019. Diagnostic Performance of Ultrasound Patterns by K-TIRADS and 2015 ATA Guidelines in Risk Stratification of Thyroid Nodules and Follicular Lesions of Undetermined Significance. *American Journal of Roentgenology* 1-7. [Crossref]

311. Zhaowei Meng, Michiko Matsuse, Vladimir Saenko, Shunichi Yamashita, Peng Ren, Xiangqian Zheng, Qiang Jia, Jian Tan, Ning Li, Wei Zheng, Li Zhao, Norisato Mitsutake. 2019. TERT promoter mutation in primary papillary thyroid carcinoma lesions predicts absent or lower 131 i uptake in metastases. *IUBMB Life* **26**. . [Crossref]

312. Thasneem Jainulabdeen, Balakrishnan Ramaswamy, K. Devaraja, Samir M. Paruthikunnan, Ajay M. Bhandarkar. 2019. Preoperative Staging of Differentiated Thyroid Carcinomas: Comparison of USG and CT with Intraoperative Findings and Histopathology. *Indian Journal of Otolaryngology and Head & Neck Surgery* **26**. . [Crossref]

313. Mira Siderova. Thyroid Cancer: Diagnosis, Treatment and Follow-Up . [Crossref]

314. N. Chereau, T. O. Oyekunle, A. Zambeli-Ljepović, H. S. Kazaure, S. A. Roman, F. Menegaux, J. A. Sosa. 2019. Predicting recurrence of papillary thyroid cancer using the eighth edition of the AJCC/UICC staging system. *BJS* **317**. . [Crossref]

315. John Woody Sistrunk, Alexander Shifrin, Marc Frager, Ricardo H. Bardales, Johnson Thomas, Norman Fishman, Philip Goldberg, Richard Guttler, Edward Grant. 2019. Clinical impact of testing for mutations and microRNAs in thyroid nodules. *Diagnostic Cytopathology* **16**. . [Crossref]

316. Patrizia Straccia, Chiara Brunelli, Esther D. Rossi, Paola Lanza, Maurizio Martini, Teresa Musarra, Celestino Pio Lombardi, Alfredo Pontecorvi, Guido Fadda. 2019. The immunocytochemical expression of VE -1 (BRAF V600E-related) antibody identifies the aggressive variants of papillary thyroid carcinoma on liquid-based cytology. *Cytopathology* **3**. . [Crossref]

317. David S. Cohen, Jane E. Tongson-Ignacio, Christopher M. Lolachi, Vanessa S. Ghaderi, Babak Jahan-Parwar, Lester D. R. Thompson. 2019. Rethinking Malignancy Risk in Indeterminate Thyroid Nodules with Positive Molecular Studies: Southern California Permanente Experience. *Otolaryngology–Head and Neck Surgery* **124**, 019459981984285. [Crossref]

Downloaded by Memorial Sloan Kettering from www.liebertpub.com at 08/14/19. For personal use only.

318. Chang-Hee Lee, Sang-Woo Lee, Seung Hyun Son, Chae Moon Hong, Ju Hye Jeong, Shin Young Jeong, Byeong-Cheol Ahn, Jaetae Lee. 2019. PROGNOSTIC VALUE OF LYMPH NODE UPTAKE ON PRETREATMENT F-18 FDG PET/CT IN PATIENTS WITH N1B PAPILLARY THYROID CARCINOMA. *Endocrine Practice* . [Crossref]

319. Luis Felipe Zavala, María Inés Barra, Roberto Olmos, Michael Tuttle, Hernán González, Nicolás Droppelmann, Lorena Mosso, José M. Domínguez. 2019. In properly selected patients with differentiated thyroid cancer, antithyroglobulin antibodies decline after thyroidectomy and their sole presence should not be an indication for radioiodine ablation. *Archives of Endocrinology and Metabolism* . [Crossref]

320. Nathalie Oliveira Santana, Ricardo Miguel Costa Freitas, Vinicius Neves Marcos, Maria Cristina Chammas, Rosalinda Yossie Asato Camargo, Cláudia Kliemann Schmerling, Felipe Augusto Brasileiro Vanderlei, Ana Oliveira Hoff, Suemi Marui, Debora Lucia Seguro Danilovic. 2019. Diagnostic performance of thyroid ultrasound in Hürthle cell carcinomas. *Archives of Endocrinology and Metabolism* . [Crossref]

321. Ana María Gómez-Pérez, Isabel María Cornejo Pareja, Jorge García Alemán, Leticia Coín Aragüez, Arantzazu Sebastián Ochoa, Juan Alcaide Torres, María Molina Vega, Carlos Clu Fernández, Isabel Mancha Doblas, Francisco J. Tinahones. 2019. New molecular biomarkers in differentiated thyroid carcinoma: Impact of miR-146, miR-221 and miR-222 levels in the evolution of the disease. *Clinical Endocrinology* **157**. . [Crossref]

322. Jiapeng Huang, Wei Sun, Hao Zhang, Ping Zhang, Zhihong Wang, Wenwu Dong, Liang He, Ting Zhang. 2019. Use of Delphian lymph node metastasis to predict central and lateral involvement in papillary thyroid carcinoma: A systematic review and meta-analysis. *Clinical Endocrinology* **68**. . [Crossref]

323. Mehrdad Nabahati, Zoleika Moazezi, Soude Fartookzadeh, Rahele Mehraeen, Naser Ghaemian, Majid Sharbatdaran. 2019. The comparison of accuracy of ultrasonographic features versus ultrasound-guided fine-needle aspiration cytology in diagnosis of malignant thyroid nodules. *Journal of Ultrasound* **43**. . [Crossref]

324. Maria V. Deligiorgi, Dimitrios T. Trafalis. Papillary Thyroid Carcinoma Intertwined with Hashimoto's Thyroiditis: An Intriguing Correlation . [Crossref]

325. P. Malandrino, D. Tumino, M. Russo, S. Marescalco, R. A. Fulco, F. Frasca. 2019. Surveillance of patients with differentiated thyroid cancer and indeterminate response: a longitudinal study on basal thyroglobulin trend. *Journal of Endocrinological Investigation* **26**. . [Crossref]

326. Andrea Repaci, Valentina Vicennati, Alexandro Paccapelo, Ottavio Cavicchi, Nicola Salituro, Fabio Monari, Dario de Biase, Giovanni Tallini, Annalisa Altimari, Elisa Gruppioni, Michelangelo Fiorentino, Uberto Pagotto. 2019. BRAF V600E Status and Stimulated Thyroglobulin at Ablation Time Increase Prognostic Value of American Thyroid Association Classification Systems for Persistent Disease in Differentiated Thyroid Carcinoma. *International Journal of Endocrinology* **2019**, 1-7. [Crossref]

327. Colin Davenport, Jack Alderson, Ivan G. Yu, Aoiffe C Magner, Diarmuid M. O'Brien, Meabh Ni Ghiollagain, Sinead Kileen, Mark Heneghan, Muna Sabah, Eamon Leen, John H. McDermott, Seamus Sreenan, Neil Hickey, Tommy Kyaw-Tun. 2019. A review of the propriety of thyroid ultrasound referrals and their follow-up burden. *Endocrine* **347**. . [Crossref]

328. Tingting Ji, Jun Chen, Jianing Mou, Xin Ni, Yongli Guo, Jie Zhang, Shengcai Wang, Wei Wang, Xin Zhang, Jun Tai. 2019. The optimal surgical approach for papillary thyroid carcinoma with pathological n1 metastases: An analysis from the SEER database. *The Laryngoscope* **216**. . [Crossref]

329. Jason E. Cohn. 2019. Introducing a Novel Diagnostic Modality for Thyroid Cancer: Thyroidography. *Journal of Investigative Surgery* 1-2. [Crossref]

330. Jun Jiang, Hui Lu. 2019. Immediate Surgery Might Be a Better Option for Subcapsular Thyroid Microcarcinomas. *International Journal of Endocrinology* **2019**, 1-6. [Crossref]

331. Shaohua Zhan, Dan Luo, Wei Ge, Bin Zhang, Tianxiao Wang. 2019. Clinicopathological predictors of occult lateral neck lymph node metastasis in papillary thyroid cancer: A meta-analysis. *Head & Neck* **12**. . [Crossref]

332. Biermann Martin. 2019. Ultrasound-Guided Core Needle Biopsy Does Not Help Avert Diagnostic Hemithyroidectomy in Cytologically Indeterminate Thyroid Nodules. *Clinical Thyroidology* **31**:4, 151-154. [Citation] [Full Text] [PDF] [PDF Plus]

333. Geron Yossi, Benbassat Carlos, Shteinshneider Miriam, Or Keren, Markus Efrat, Hirsch Dania, Levy Sigal, Ziv-Baran Tomer, Muallem-Kalmovich Limor. 2019. Multifocality Is not an Independent Prognostic Factor in Papillary Thyroid Cancer: A Propensity Score–Matching Analysis. *Thyroid* **29**:4, 513-522. [Abstract] [Full Text] [PDF] [PDF Plus]

334. Piccardo Arnoldo, Trimboli Pierpaolo, Puntoni Matteo, Foppiani Luca, Treglia Giorgio, Naseri Mehrdad, Bottoni Gian Luca, Massollo Michela, Sola Simona, Ferrarazzo Giulia, Bruzzone Martina, Catrambone Ugo, Arlandini Anselmo, Paone Gaetano, Ceriani Luca, Cabria Manlio, Giovanella Luca. 2019. Role of 18F-Choline Positron Emission Tomography/Computed Tomography to Detect Structural Relapse in High-Risk Differentiated Thyroid Cancer Patients. *Thyroid* **29**:4, 549-556. [Abstract] [Full Text] [PDF] [PDF Plus]

Downloaded by Memorial Sloan Kettering from www.liebertpub.com at 08/14/19. For personal use only.

335. Tuttle R. Michael, Ahuja Sukhjeet, Avram Anca M., Bernet Victor J., Bourguet Patrick, Daniels Gilbert H., Dillehay Gary, Draganescu Ciprian, Flux Glenn, Führer Dagmar, Giovanella Luca, Greenspan Bennett, Luster Markus, Muylle Kristoff, Smit Johannes W.A., Van Nostrand Douglas, Verburg Frederik A., Hegedüs Laszlo. 2019. Controversies, Consensus, and Collaboration in the Use of 131I Therapy in Differentiated Thyroid Cancer: A Joint Statement from the American Thyroid Association, the European Association of Nuclear Medicine, the Society of Nuclear Medicine and Molecular Imaging, and the European Thyroid Association. *Thyroid* **29**:4, 461-470. [Abstract] [Full Text] [PDF] [PDF Plus]

336. Allen S. Ho, Timothy J. Daskivich, Wendy L. Sacks, Zachary S. Zumsteg. 2019. Parallels Between Low-Risk Prostate Cancer and Thyroid Cancer. *JAMA Oncology* **5**:4, 556. [Crossref]

337. Louise Davies, Benjamin R. Roman, Mitsuhiro Fukushima, Yasuhiro Ito, Akira Miyauchi. 2019. Patient Experience of Thyroid Cancer Active Surveillance in Japan. *JAMA Otolaryngology–Head & Neck Surgery* **145**:4, 363. [Crossref]

338. Huiying Wang, Mitra Mehrad, Kim A. Ely, Jiancong Liang, Carmen C. Solórzano, Wallace W. Neblett, Alice C. Coogan, Vivian L. Weiss. 2019. Incidence and malignancy rates of indeterminate pediatric thyroid nodules. *Cancer Cytopathology* **127**:4, 231-239. [Crossref]

339. Anna B. Banizs, Jan F. Silverman. 2019. The utility of combined mutation analysis and microRNA classification in reclassifying cancer risk of cytologically indeterminate thyroid nodules. *Diagnostic Cytopathology* **47**:4, 268-274. [Crossref]

340. Su Yeon Ko, Ji Hye Lee, Jung Hyun Yoon, Hyesun Na, Eunhye Hong, Kyunghwa Han, Inkyung Jung, Eun-Kyung Kim, Hee Jung Moon, Vivian Y. Park, Eunjung Lee, Jin Young Kwak. 2019. Deep convolutional neural network for the diagnosis of thyroid nodules on ultrasound. *Head & Neck* **41**:4, 885-891. [Crossref]

341. Charles J. Meltzer, Jonathan Irish, Peter Angelos, Naifa L. Busaidy, Louise Davies, Sunshine Dwojak, Robert L. Ferris, Bryan R. Haugen, Richard M. Harrell, Megan R. Haymart, Bryan McIver, Jeffrey I. Mechanick, Eric Monteiro, John C. Morris, Luc G. T. Morris, Michael Odell, Joseph Scharpf, Ashok Shaha, Jennifer J. Shin, David C. Shonka, Geoffrey B. Thompson, R. Michael Tuttle, Mark L. Urken, Sam M. Wiseman, Richard J. Wong, Gregory Randolph. 2019. American Head and Neck Society Endocrine Section clinical consensus statement: North American quality statements and evidence-based multidisciplinary workflow algorithms for the evaluation and management of thyroid nodules. *Head & Neck* **41**:4, 843-856. [Crossref]

342. Hye Shin Ahn, Dong Gyu Na, Jung Hwan Baek, Jin Yong Sung, Ji-Hoon Kim. 2019. False negative rate of fine-needle aspiration in thyroid nodules: impact of nodule size and ultrasound pattern. *Head & Neck* **41**:4, 967-973. [Crossref]

343. Jeong Mi Kim, Ji Won Kim, Mi Eun Choi, Seok-Ki Kim, Young-Mo Kim, Jeong-Seok Choi. 2019. Protective effects of curcumin on radioiodine-induced salivary gland dysfunction in mice. *Journal of Tissue Engineering and Regenerative Medicine* **13**:4, 674-681. [Crossref]

344. Wei Zhou, Yudong Chen, Lu Zhang, Xiaofeng Ni, Shangyan Xu, Weiwei Zhan. 2019. Percutaneous Microwave Ablation of Metastatic Lymph Nodes from Papillary Thyroid Carcinoma: Preliminary Results. *World Journal of Surgery* **43**:4, 1029-1037. [Crossref]

345. Jian Yu, Shangrui Rao, Zhe Lin, Zhongliang Pan, Xiangjian Zheng, Zhonglin Wang. 2019. The learning curve of endoscopic thyroid surgery for papillary thyroid microcarcinoma: CUSUM analysis of a single surgeon's experience. *Surgical Endoscopy* **33**:4, 1284-1289. [Crossref]

346. Omar Saeed, Lori J. Bernstein, Rouhi Fazelzad, Mary Samuels, Lynn A. Burmeister, Lehana Thabane, Shereen Ezzat, David P. Goldstein, Jennifer Jones, Anna M. Sawka. 2019. Cognitive functioning in thyroid cancer survivors: a systematic review and meta-analysis. *Journal of Cancer Survivorship* **13**:2, 231-243. [Crossref]

347. Bin Xu, Ed Reznik, R. Michael Tuttle, Jeffrey Knauf, James A. Fagin, Nora Katabi, Snjezana Dogan, Nathaniel Aleynick, Venkatraman Seshan, Sumit Middha, Danny Enepekides, Gian Piero Casadei, Erica Solaroli, Giovanni Tallini, Ronald Ghossein, Ian Ganly. 2019. Outcome and molecular characteristics of non-invasive encapsulated follicular variant of papillary thyroid carcinoma with oncocytic features. *Endocrine* **64**:1, 97-108. [Crossref]

348. Ewelina Szczepanek-Parulska, Martyna Borowczyk, Alina Kluk, Grzegorz Dworacki, Marcin Orłowski, Katarzyna Ziemnicka, Marek Ruchała. 2019. Concomitant Occurrence of Papillary Thyroid Cancer (PTC) in a Branchial Cleft Cyst and an Occult Multifocal PTC of the Thyroid Gland. *Indian Journal of Surgery* **81**:2, 199-200. [Crossref]

349. Stacey A. Dacosta Byfield, Oluwakayode Adejoro, Ronda Copher, Debanjana Chatterjee, Prashant R. Joshi, Francis P. Worden. 2019. Real-World Treatment Patterns Among Patients Initiating Small Molecule Kinase Inhibitor Therapies for Thyroid Cancer in the United States. *Advances in Therapy* **36**:4, 896-915. [Crossref]

350. Roland Ladurner, Klaus Hallfeldt, Martin Angele, Jens Werner, Martin Reincke, Christine Spitzweg, Christian Lottspeich. 2019. Zufallsbefund Schilddrüsenknoten: Wie geht es nun weiter?. *MMW - Fortschritte der Medizin* **161**:7, 38-43. [Crossref]

351. Anton Staudenherz, Thomas Leitha. 2019. Thyroid Sonography: Nuclear Medicine Point of View. *Current Radiology Reports* **7**:4. . [Crossref]

Downloaded by Memorial Sloan Kettering from www.liebertpub.com at 08/14/19. For personal use only.

352. Allan Hackshaw, Hakim-Moulay Dehbi. 2019. Thyroid cancer recurrence in the HiLo trial – Authors' reply. *The Lancet Diabetes & Endocrinology* **7**:4, 252-253. [Crossref]

353. Marine Sarfati-Lebreton, Laurence Toqué, Jean-Baptiste Philippe, Jean-Baptiste Finel, Antoine Hamy, Stéphanie Mucci. 2019. Does hemithyroidectomy still provide any benefit?. *Annales d'Endocrinologie* **80**:2, 101-109. [Crossref]

354. Xi Zhang, Li Zhang, Shuai Xue, Peisong Wang, Guang Chen. 2019. Predictive factors of lateral lymph node metastasis in solitary papillary thyroid microcarcinoma without gross extrathyroidal extension. *Asian Journal of Surgery* **42**:4, 563-570. [Crossref]

355. Qiang Zhang, Zhengmin Wang, Xianying Meng, Quan-Yang Duh, Guang Chen. 2019. Predictors for central lymph node metastases in CN0 papillary thyroid microcarcinoma (mPTC): A retrospective analysis of 1304 cases. *Asian Journal of Surgery* **42**:4, 571-576. [Crossref]

356. Shun-Siang Chong, Siew-Yep Hoh, Shih-Ming Huang. 2019. Post-hemithyroidectomy hypothyroidism in non autoimmune thyroiditis patients: Incidence, risk factors and duration of follow up. *Asian Journal of Surgery* . [Crossref]

357. K. Seejore, G.E. Gerrard, V.M. Gill, R.D. Murray. 2019. Can We Discharge Dynamically Risk-Stratified Low-Risk (Excellent Response to Treatment) Thyroid Cancer Patients After 5 Years of Follow-Up?. *Clinical Oncology* **31**:4, 219-224. [Crossref]

358. Reema Mallick, Todd M. Stevens, Thomas S. Winokur, Ammar Asban, Thomas N. Wang, Brenessa M. Lindeman, John R. Porterfield, Herbert Chen. 2019. Is Frozen-Section Analysis During Thyroid Operation Useful in the Era of Molecular Testing?. *Journal of the American College of Surgeons* **228**:4, 474-479. [Crossref]

359. Michael S. Landau, Thomas M. Pearce, Sally E. Carty, Jenna Wolfe, Linwah Yip, Kelly L. McCoy, Shane O. LeBeau, Mitchell E. Tublin, N. Paul Ohori. 2019. Comparison of the collection approaches of 2 large thyroid fine-needle aspiration practices reveals differing advantages for cytology and molecular testing adequacy rates. *Journal of the American Society of Cytopathology* . [Crossref]

360. Eyun Song, Jonghwa Ahn, Hye-Seon Oh, Min Ji Jeon, Won Gu Kim, Won Bae Kim, Young Kee Shong, Jung Hwan Baek, Jeong Hyun Lee, Jin Sook Ryu, Ki Wook Chung, Suck Joon Hong, Tae Yong Kim. 2019. Time trends of thyroglobulin antibody in ablated papillary thyroid carcinoma patients: Can we predict the rate of negative conversion?. *Oral Oncology* **91**, 29-34. [Crossref]

361. Sonsoles Guadalix Iglesias, María Luisa De Mingo Dominguez, Eduardo Ferrero Herrero, José Ignacio Martinez-Pueyo, Cristina Martín-Arriscado Arroba, Guillermo Martínez Diaz-Guerra, Federico Hawkins Carranza. 2019. Trabecular bone score and bone mineral density in patients with postsurgical hypoparathyroidism after total thyroidectomy for differentiated thyroid carcinoma. *Surgery* **165**:4, 814-819. [Crossref]

362. A.G. Williamson, V. Wilmot, C. Ntala, F.W. Gibb, B. Conn, I.J. Nixon. 2019. Differentiated thyroid cancer: A retrospective evaluation of the impact of changes to disease management guidelines on patients in South East Scotland. *The Surgeon* **17**:2, 73-79. [Crossref]

363. Sang-Geon Cho, Seong Young Kwon, Jahae Kim, Dong-Hyeok Cho, Myung Hwan Na, Sae-Ryung Kang, Su Woong Yoo, Ho-Chun Song. 2019. Risk factors of malignant fluorodeoxyglucose-avid lymph node on preablation positron emission tomography in patients with papillary thyroid cancer undergoing radioiodine ablation therapy. *Medicine* **98**:16, e14858. [Crossref]

364. Junho Song, Young Jun Chai, Hiroo Masuoka, Sun-Won Park, Su-jin Kim, June Young Choi, Hyoun-Joong Kong, Kyu Eun Lee, Joongseek Lee, Nojun Kwak, Ka Hee Yi, Akira Miyauchi. 2019. Ultrasound image analysis using deep learning algorithm for the diagnosis of thyroid nodules. *Medicine* **98**:15, e15133. [Crossref]

365. Aleix Rovira, Iain J. Nixon, Ricard Simo. 2019. Papillary microcarcinoma of the thyroid gland. *Current Opinion in Otolaryngology & Head and Neck Surgery* **27**:2, 110-116. [Crossref]

366. Il-Hyun Kim, Joon-Kee Yoon, Su Jin Lee, Eugene Jeong, Young-Sil An. 2019. A Case of Radioactive Iodine Uptake Found in Artificial Eye. *Clinical Nuclear Medicine* **44**:4, 317-318. [Crossref]

367. Rosa Cervelli, Salvatore Mazzeo, Giuseppe Boni, Antonio Boccuzzi, Francesca Bianchi, Federica Brozzi, Pierina Santini, Paolo Vitti, Roberto Cioni, Davide Caramella. 2019. Comparison between radioiodine therapy and single-session radiofrequency ablation of autonomously functioning thyroid nodules: A retrospective study. *Clinical Endocrinology* **90**:4, 608-616. [Crossref]

368. Mona M. Sabra, Eric Sherman, Robert Michael Tuttle. 2019. Prolongation of tumour volume doubling time (midDT) is associated with improvement in disease-specific survival in patients with rapidly progressive radioactive iodine refractory differentiated thyroid cancer selected for molecular targeted therapy. *Clinical Endocrinology* **90**:4, 617-622. [Crossref]

369. Sebastiao N Martins-Filho, Venancio A F Alves, Alda Wakamatsu, Miho Maeda, Amanda J Craig, Aline K Assato, Carlos Villacorta-Martin, Delia D'Avola, Ismail Labgaa, Flair J Carrilho, Swan N Thung, Augusto Villanueva. 2019. A phenotypical map of disseminated hepatocellular carcinoma suggests clonal constraints in metastatic sites. *Histopathology* **74**:5, 718-730. [Crossref]

370. Kyoungjune Pak, Yun Hak Kim, Sunghwan Suh, Tae Sik Goh, Dae Cheon Jeong, Seong Jang Kim, In Joo Kim, Myoung-Eun Han, Sae-Ock Oh. 2019. Development of a risk scoring system for patients with papillary thyroid cancer. *Journal of Cellular and Molecular Medicine* **23**:4, 3010-3015. [Crossref]

Downloaded by Memorial Sloan Kettering from www.liebertpub.com at 08/14/19. For personal use only.

371. Su Min Ha, Jung Hwan Baek, Dong Gyu Na, Chong Hyun Suh, Sae Rom Chung, Young Jun Choi, Jeong Hyun Lee. 2019. Diagnostic Performance of Practice Guidelines for Thyroid Nodules: Thyroid Nodule Size versus Biopsy Rates. *Radiology* **291**:1, 92-99. [Crossref]

372. W. Dennis Foley. 2019. Thyroid Nodules by US: More Imaging and/or More Intervention?. *Radiology* **291**:1, 100-101. [Crossref]

373. Andrea Attard, Nunzia Cinzia Paladino, Attilio Ignazio Lo Monte, Nicola Falco, Giuseppina Melfa, Giulia Rotolo, Stefano Rizzuto, Eliana Gulotta, Giuseppe Salamone, Sebastiano Bonventre, Gregorio Scerrino, Gianfranco Cocorullo. 2019. Skip metastases to lateral cervical lymph nodes in differentiated thyroid cancer: a systematic review. *BMC Surgery* **18**:S1. . [Crossref]

374. Aldo Bove, Paolo Panaccio, Gino Palone, Ludovica Esposito, Lucia Marino, Giuseppe Bongarzoni. 2019. Impact of the new guidelines of the American Thyroid Association on the treatment of the differentiated thyroid tumor in an Italian center with medium-high volume thyroid surgery. *BMC Surgery* **18**:S1. . [Crossref]

375. Francesco Paolo Prete, Rinaldo Marzaioli, Serafina Lattarulo, Daniele Paradies, Graziana Barile, Maria Vittoria d'Addetta, Giovanni Tomasicchio, Angela Gurrado, Angela Pezzolla. 2019. Transaxillary robotic-assisted thyroid surgery: technique and results of a preliminary experience on the Da Vinci Xi platform. *BMC Surgery* **18**:S1. . [Crossref]

376. Andrea Polistena, Alessandro Sanguinetti, Roberta Lucchini, Stefano Avenia, Sergio Galasse, Raffaele Farabi, Massimo Monacelli, Nicola Avenia. 2019. Follicular proliferation TIR3B: the role of total thyroidectomy vs lobectomy. *BMC Surgery* **18**:S1. . [Crossref]

377. Yangyang Hao, Quan-Yang Duh, Richard T. Kloos, Joshua Babiarz, R. Mack Harrell, S. Thomas Traweek, Su Yeon Kim, Grazyna Fedorowicz, P. Sean Walsh, Peter M. Sadow, Jing Huang, Giulia C. Kennedy. 2019. Identification of Hürthle cell cancers: solving a clinical challenge with genomic sequencing and a trio of machine learning algorithms. *BMC Systems Biology* **13**:S2. . [Crossref]

378. Laurence Leenhardt, Sophie Leboulleux, Claire Bournaud, Slimane Zerdoud, Claire Schvartz, Renaud Ciappuccini, Antony Kelly, Olivier Morel, Inna Dygai-Cochet, Daniela Rusu, Cécile N Chougnet, Georges Lion, Marie-Claude Eberlé-Pouzeratte, Bogdan Catargi, Marmar Kabir-Ahmadi, Eliane Le Peillet Feuillet, David Taïeb. 2019. Recombinant Thyrotropin vs Levothyroxine Withdrawal in 131I Therapy of N1 Thyroid Cancer: A Large Matched Cohort Study (ThyrNod). *The Journal of Clinical Endocrinology & Metabolism* **104**:4, 1020-1028. [Crossref]

379. Hye Sun Park, Younghee Yim, Jung Hwan Baek, Young Jun Choi, Young Kee Shong, Jeong Hyun Lee. 2019. Ethanol ablation as a treatment strategy for benign cystic thyroid nodules: a comparison of the ethanol retention and aspiration techniques. *Ultrasonography* **38**:2, 166-171. [Crossref]

380. Chong-Ke Zhao, Hui-Xiong Xu. 2019. Ultrasound elastography of the thyroid: principles and current status. *Ultrasonography* **38**:2, 106-124. [Crossref]

381. Nicholas Kotewall, Brian H. H. Lang. 2019. High-intensity focused ultrasound ablation as a treatment for benign thyroid diseases: the present and future. *Ultrasonography* **38**:2, 135-142. [Crossref]

382. Ji-hoon Kim, Jung Hwan Baek, Hyun Kyung Lim, Dong Gyu Na. 2019. Summary of the 2017 thyroid radiofrequency ablation guideline and comparison with the 2012 guideline. *Ultrasonography* **38**:2, 125-134. [Crossref]

383. Elena Izkhakov, Joseph Meyerovitch, Micha Barchana, Yacov Shacham, Naftali Stern, Lital Keinan-Boker. 2019. Long-term cardiovascular and cerebrovascular morbidity in Israeli thyroid cancer survivors. *Endocrine Connections* **8**:4, 398-406. [Crossref]

384. K van der Tuin, M Ventayol Garcia, W E Corver, M N Khalifa, D Ruano Neto, E P M Corssmit, F J Hes, T P Links, J W A Smit, T S Plantinga, E Kapiteijn, T van Wezel, H Morreau. 2019. Targetable gene fusions identified in radioactive iodine refractory advanced thyroid carcinoma. *European Journal of Endocrinology* **8**, 235-241. [Crossref]

385. Jeongmin Lee, Hye Lim Park, Chan-Wook Jeong, Jeonghoon Ha, Kwanhoon Jo, Min-Hee Kim, Jeong-Sun Han, Sohee Lee, Jaseong Bae, Chan Kwon Jung, So Lyung Jung, Moo Il Kang, Dong-Jun Lim. 2019. CYFRA 21-1 in Lymph Node Fine Needle Aspiration Washout Improves Diagnostic Accuracy for Metastatic Lymph Nodes of Differentiated Thyroid Cancer. *Cancers* **11**:4, 487. [Crossref]

386. Davide Lombardi, Stefano Taboni, Alberto Paderno, Davide Giordano, Francesco Bertagna, Domenico Albano, Verter Barbieri, Giuseppe Spriano, Giuseppe Mercante, Simonetta Piana, Salvatore Bellafiore, Carlo Cappelli, Piero Nicolai. 2019. LATERAL NECK DISSECTION FOR AGGRESSIVE VARIANTS OF WELL-DIFFERENTIATED THYROID CANCER. *Endocrine Practice* **25**:4, 328-334. [Crossref]

387. M. Capezzone, C. Secchi, N. Fralassi, S. Cantara, L. Brilli, C. Ciuoli, T. Pilli, F. Maino, R. Forleo, F. Pacini, M. G. Castagna. 2019. Should familial disease be considered as a negative prognostic factor in micropapillary thyroid carcinoma?. *Journal of Endocrinological Investigation* **140**. . [Crossref]

388. Brian H. H. Lang, Yu-Cho Woo, Keith Wan-Hang Chiu. 2019. Effect of perithyroidal lignocaine infusion (PLI) to pain experienced during high-intensity focused ultrasound (HIFU) ablation of benign thyroid nodules. *European Radiology* **26**. . [Crossref]

Downloaded by Memorial Sloan Kettering from www.liebertpub.com at 08/14/19. For personal use only.

389. Nenia Baerbock, Anke Mittelstädt, Joachim Jähne. 2019. Morbidity and long-term survival in patients with cervical re-exploration for papillary thyroid carcinoma. *Innovative Surgical Sciences*, ahead of print. [Crossref]

390. Abdulhalim Senyigit, Esra HATIPOGLU, Okan GURKAN, İlhami GULTEPE, Timur ORHANOGLU, Yeltekin DEMIREL. 2019. Utility of screening asymptomatic adults with thyroid ultrasonography. *Cumhuriyet Medical Journal* . [Crossref]

391. Carlo Cappelli, Ilenia Pirola, Elena Gandossi, Fiorella Marini, Alessandra Cristiano, Claudio Casella, Davide Lombardi, Barbara Agosti, Alberto Ferlin, Maurizio Castellano. 2019. Ultrasound Microvascular Blood Flow Evaluation: A New Tool for the Management of Thyroid Nodule?. *International Journal of Endocrinology* **2019**, 1-6. [Crossref]

392. Hankyul Kim, Jung Hee Shin, Soo Yeon Hahn, Young Lyun Oh, Sun Wook Kim, Ko Woon Park, Yaeji Lim. 2019. Prediction of follicular thyroid carcinoma associated with distant metastasis in the preoperative and postoperative model. *Head & Neck* **194**. . [Crossref]

393. Tatiana Marina Vieira Giorgenon, Fabiane Tavares Carrijo, Maurício Alamos Arruda, Taíse Lima Oliveira Cerqueira, Haiara Ramos Barreto, Juliana Brandão Cabral, Thiago Magalhães da Silva, Patrícia Künzle Ribeiro Magalhães, Léa Maria Zanini Maciel, Helton Estrela Ramos. 2019. Preoperative detection of TERT promoter and BRAFV600E mutations in papillary thyroid carcinoma in high-risk thyroid nodules. *Archives of Endocrinology and Metabolism* . [Crossref]

394. Danielle Pessôa-Pereira, Mateus Fernandes da Silva Medeiros, Virna Mendonça Sampaio Lima, Joaquim Custódio da Silva, Taíse Lima de Oliveira Cerqueira, Igor Campos da Silva, Luciano Espinheira Fonseca, Luiz José Lobão Sampaio, Cláudio Rogério Alves de Lima, Helton Estrela Ramos. 2019. Association between BRAF (V600E) mutation and clinicopathological features of papillary thyroid carcinoma: a Brazilian single-centre case series. *Archives of Endocrinology and Metabolism* . [Crossref]

395. He Xiaowei, Wu Dan, Hu Cuining, Xu Ting, Liu Yuanxin, Liu Chao, Xu Bo, Tang Wei. 2019. Role of Metformin in the Treatment of Patients with Thyroid Nodules and Insulin Resistance: A Systematic Review and Meta-Analysis. *Thyroid* **29**:3, 359-367. [Abstract] [Full Text] [PDF] [PDF Plus] [Supplementary Material]

396. Ollero M. Dolores, Toni Marta, Pineda José Javier, Martínez Juan Pablo, Espada Mercedes, Anda Emma. 2019. Thyroid Function Reference Values in Healthy Iodine-Sufficient Pregnant Women and Influence of Thyroid Nodules on Thyrotropin and Free Thyroxine Values. *Thyroid* **29**:3, 421-429. [Abstract] [Full Text] [PDF] [PDF Plus]

397. Ibrahimpasic Tihana, Ghossein Ronald, Shah Jatin P., Ganly Ian. 2019. Poorly Differentiated Carcinoma of the Thyroid Gland: Current Status and Future Prospects. *Thyroid* **29**:3, 311-321. [Abstract] [Full Text] [PDF] [PDF Plus]

398. Rahman Sabbir T., McLeod Donald S.A., Pandeya Nirmala, Neale Rachel E., Bain Chris J., Baade Peter, Youl Philippa H., Jordan Susan J.. 2019. Understanding Pathways to the Diagnosis of Thyroid Cancer: Are There Ways We Can Reduce Over-Diagnosis?. *Thyroid* **29**:3, 341-348. [Abstract] [Full Text] [PDF] [PDF Plus] [Supplementary Material]

399. Jeong Hoon Lee, Eun Ju Ha, Ju Han Kim. 2019. Application of deep learning to the diagnosis of cervical lymph node metastasis from thyroid cancer with CT. *European Radiology* **140**. . [Crossref]

400. Kenji Ohba, Norisato Mitsutake, Michiko Matsuse, Tatiana Rogounovitch, Nobuhiko Nishino, Yutaka Oki, Yoshie Goto, Kennichi Kakudo. 2019. Encapsulated Papillary Thyroid Tumor with Delicate Nuclear Changes and a KRAS Mutation as a Possible Novel Subtype of Borderline Tumor. *Journal of Pathology and Translational Medicine* **53**:2, 136-141. [Crossref]

401. R Michael Tuttle, Ali S Alzahrani. 2019. Risk Stratification in Differentiated Thyroid Cancer: From Detection to Final Follow-up. *The Journal of Clinical Endocrinology & Metabolism* . [Crossref]

402. Bita Geramizadeh, Zahra Maleki. 2019. Non-invasive follicular thyroid neoplasm with papillary-like nuclearfeatures (NIFTP): a review and update. *Endocrine* **2**. . [Crossref]

403. Michele Klain, Leonardo Pace, Emilia Zampella, Teresa Mannarino, Simona Limone, Emanuela Mazziotti, Giovanni De Simini, Alberto Cuocolo. 2019. Outcome of Patients With Differentiated Thyroid Cancer Treated With 131-Iodine on the Basis of a Detectable Serum Thyroglobulin Level After Initial Treatment. *Frontiers in Endocrinology* **10**. . [Crossref]

404. Katarzyna Sylwia Dobruch-Sobczak, Agnieszka Krauze, Bartosz Migda, Krzysztof Mlosek, Rafał Zenon Słapa, Elwira Bakuła-Zalewska, Zbigniew Adamczewski, Andrzej Lewiński, Wiesław Jakubowski, Marek Dedecjus. 2019. Integration of Sonoelastography Into the TIRADS Lexicon Could Influence the Classification. *Frontiers in Endocrinology* **10**. . [Crossref]

405. Celeste Nagy, Zachary Kelly, Steven Keilin, Field Willingham, Amy Chen. 2019. Barriers to thyroid cancer screening with ultrasound in patients with familial adenomatous polyposis. *The Laryngoscope* **2**. . [Crossref]

406. Xiang Li, Xiu-Juan Hou, Lin-Yao Du, Jia-Qi Wu, Luo Wang, Hong Wang, Xian-Li Zhou. 2019. Virtual Touch Tissue Imaging and Quantification (VTIQ) combined with the American College of Radiology Thyroid Imaging Reporting and Data System (ACR TI-RADS) for malignancy risk stratification of thyroid nodules. *Clinical Hemorheology and Microcirculation* **16**, 1-13. [Crossref]

407. Fish Stephanie A.. 2019. ACR TIRADS is Best to Decrease the Number of Thyroid Biopsies and Maintain Accuracy. *Clinical Thyroidology* **31**:3, 113-116. [Citation] [Full Text] [PDF] [PDF Plus]

Downloaded by Memorial Sloan Kettering from www.liebertpub.com at 08/14/19. For personal use only.

408. Papaleontiou Maria. 2019. Active Surveillance for T1bN0M0 Papillary Thyroid Carcinoma Can Be Feasibly Considered in Select Patients. *Clinical Thyroidology* **31**:3, 117-119. [Citation] [Full Text] [PDF] [PDF Plus]

409. Orloff Lisa A.. 2019. Levothyroxine Use Following Even Partial Thyroidectomy May Increase the Risk of Osteoporosis. *Clinical Thyroidology* **31**:3, 123-125. [Citation] [Full Text] [PDF] [PDF Plus]

410. Brooke Nickel, Tessa Tan, Erin Cvejic, Peter Baade, Donald S. A. McLeod, Nirmala Pandeya, Philippa Youl, Kirsten McCaffery, Susan Jordan. 2019. Health-Related Quality of Life After Diagnosis and Treatment of Differentiated Thyroid Cancer and Association With Type of Surgical Treatment. *JAMA Otolaryngology–Head & Neck Surgery* **145**:3, 231. [Crossref]

411. N. Paul Ohori, Michael S. Landau, Sally E. Carty, Linwah Yip, Shane O. LeBeau, Pooja Manroa, Raja R. Seethala, Karen E. Schoedel, Marina N. Nikiforova, Yuri E. Nikiforov. 2019. Benign call rate and molecular test result distribution of ThyroSeq v3. *Cancer Cytopathology* **127**:3, 161-168. [Crossref]

412. Ali Abbasian Ardakani, Ahmad Bitarafan-Rajabi, Ali Mohammadzadeh, Afshin Mohammadi, Reza Riazi, Jamileh Abolghasemi, Amir Homayoun Jafari, Mohammad Bagher Shiran. 2019. A Hybrid Multilayer Filtering Approach for Thyroid Nodule Segmentation on Ultrasound Images. *Journal of Ultrasound in Medicine* **38**:3, 629-640. [Crossref]

413. Hélène Bohec, Ingrid Breuskin, Julien Hadoux, Martin Schlumberger, Sophie Leboulleux, Dana M. Hartl. 2019. Occult Contralateral Lateral Lymph Node Metastases in Unilateral N1b Papillary Thyroid Carcinoma. *World Journal of Surgery* **43**:3, 818-823. [Crossref]

414. Bao-liang Guo, Fu-sheng Ouyang, Li-zhu Ouyang, Zi-wei Liu, Shao-jia Lin, Wei Meng, Xi-yi Huang, Hai-xiong Chen, Shao-ming Yang, Qiu-gen Hu. 2019. Development and validation of an ultrasound-based nomogram to improve the diagnostic accuracy for malignant thyroid nodules. *European Radiology* **29**:3, 1518-1526. [Crossref]

415. Arnoldo Piccardo, Pierpaolo Trimboli, Luca Foppiani, Giorgio Treglia, Giulia Ferrarazzo, Michela Massollo, Gianluca Bottoni, Luca Giovanella. 2019. PET/CT in thyroid nodule and differentiated thyroid cancer patients. The evidence-based state of the art. *Reviews in Endocrine and Metabolic Disorders* **20**:1, 47-64. [Crossref]

416. Valentina Maggisano, Marilena Celano, Saverio Massimo Lepore, Marialuisa Sponziello, Francesca Rosignolo, Valeria Pecce, Antonella Verrienti, Federica Baldan, Catia Mio, Lorenzo Allegri, Marianna Maranghi, Rosa Falcone, Giuseppe Damante, Diego Russo, Stefania Bulotta. 2019. Human telomerase reverse transcriptase in papillary thyroid cancer: gene expression, effects of silencing and regulation by BET inhibitors in thyroid cancer cells. *Endocrine* **63**:3, 545-553. [Crossref]

417. Martin Freesmeyer, Falk Gühne, Christian Kühnel, Thomas Opfermann, Thomas Winkens, Anke Werner. 2019. Determination of effective half-life of 131I in patients with differentiated thyroid carcinoma: comparison of cystatin C and creatinine-based estimation of renal function. *Endocrine* **63**:3, 554-562. [Crossref]

418. Pierpaolo Trimboli, Anna Crescenzi, Marco Castellana, Francesco Giorgino, Luca Giovanella, Massimo Bongiovanni. 2019. Italian consensus for the classification and reporting of thyroid cytology: the risk of malignancy between indeterminate lesions at low or high risk. A systematic review and meta-analysis. *Endocrine* **63**:3, 430-438. [Crossref]

419. Linjue Shangguan, Shengwei Fang, Peipei Zhang, Suyang Han, Xiaodong Shen, Yawen Geng, Dingcun Luo, Chunlei Zhao. 2019. Impact factors for the outcome of the first 131I radiotherapy in patients with papillary thyroid carcinoma after total thyroidectomy. *Annals of Nuclear Medicine* **33**:3, 177-183. [Crossref]

420. Vincenzo Marotta, Giacomo Russo, Claudio Gambardella, Marica Grasso, Domenico La Sala, Maria Grazia Chiofalo, Raffaella D'Anna, Alessandro Puzziello, Giovanni Docimo, Stefania Masone, Francesco Barbato, Annamaria Colao, Antongiulio Faggiano, Lucia Grumetto. 2019. Human exposure to bisphenol AF and diethylhexylphthalate increases susceptibility to develop differentiated thyroid cancer in patients with thyroid nodules. *Chemosphere* **218**, 885-894. [Crossref]

421. Sylvia L. Asa. 2019. The Current Histologic Classification of Thyroid Cancer. *Endocrinology and Metabolism Clinics of North America* **48**:1, 1-22. [Crossref]

422. Carolyn Dacey Seib, Julie Ann Sosa. 2019. Evolving Understanding of the Epidemiology of Thyroid Cancer. *Endocrinology and Metabolism Clinics of North America* **48**:1, 23-35. [Crossref]

423. Sarah E. Mayson, Bryan R. Haugen. 2019. Molecular Diagnostic Evaluation of Thyroid Nodules. *Endocrinology and Metabolism Clinics of North America* **48**:1, 85-97. [Crossref]

424. Juan P. Brito, Ian D. Hay. 2019. Management of Papillary Thyroid Microcarcinoma. *Endocrinology and Metabolism Clinics of North America* **48**:1, 199-213. [Crossref]

425. Akira Miyauchi, Yasuhiro Ito. 2019. Conservative Surveillance Management of Low-Risk Papillary Thyroid Microcarcinoma. *Endocrinology and Metabolism Clinics of North America* **48**:1, 215-226. [Crossref]

426. Bernadette Biondi, David S. Cooper. 2019. Thyroid Hormone Suppression Therapy. *Endocrinology and Metabolism Clinics of North America* **48**:1, 227-237. [Crossref]

Downloaded by Memorial Sloan Kettering from www.liebertpub.com at 08/14/19. For personal use only.

427. Steven P. Weitzman, Steven I. Sherman. 2019. Novel Drug Treatments of Progressive Radioiodine-Refractory Differentiated Thyroid Cancer. *Endocrinology and Metabolism Clinics of North America* **48**:1, 253-268. [Crossref]

428. Carolyn Maxwell, Jennifer A. Sipos. 2019. Clinical Diagnostic Evaluation of Thyroid Nodules. *Endocrinology and Metabolism Clinics of North America* **48**:1, 61-84. [Crossref]

429. Fernanda Vaisman, R. Michael Tuttle. 2019. Clinical Assessment and Risk Stratification in Differentiated Thyroid Cancer. *Endocrinology and Metabolism Clinics of North America* **48**:1, 99-108. [Crossref]

430. Benjamin R. Roman, Gregory W. Randolph, Dipti Kamani. 2019. Conventional Thyroidectomy in the Treatment of Primary Thyroid Cancer. *Endocrinology and Metabolism Clinics of North America* **48**:1, 125-141. [Crossref]

431. Ahmad M. Eltelety, David J. Terris. 2019. Neck Dissection in the Surgical Treatment of Thyroid Cancer. *Endocrinology and Metabolism Clinics of North America* **48**:1, 143-151. [Crossref]

432. Dorina Ylli, Douglas Van Nostrand, Leonard Wartofsky. 2019. Conventional Radioiodine Therapy for Differentiated Thyroid Cancer. *Endocrinology and Metabolism Clinics of North America* **48**:1, 181-197. [Crossref]

433. Mingzhao Xing. 2019. Genetic-guided Risk Assessment and Management of Thyroid Cancer. *Endocrinology and Metabolism Clinics of North America* **48**:1, 109-124. [Crossref]

434. Prasanna Santhanam, Paul W. Ladenson. 2019. Surveillance for Differentiated Thyroid Cancer Recurrence. *Endocrinology and Metabolism Clinics of North America* **48**:1, 239-252. [Crossref]

435. Isariya Jongekkasit, Pornpeera Jitpratoom, Thanyawat Sasanakietkul, Angkoon Anuwong. 2019. Transoral Endoscopic Thyroidectomy for Thyroid Cancer. *Endocrinology and Metabolism Clinics of North America* **48**:1, 165-180. [Crossref]

436. Hengqiang Zhao, Hehe Li. 2019. Meta-analysis of ultrasound for cervical lymph nodes in papillary thyroid cancer: Diagnosis of central and lateral compartment nodal metastases. *European Journal of Radiology* **112**, 14-21. [Crossref]

437. Julia Sastre Marcos, Silvia Aznar, Visitación Álvarez, Belvis Torres, Manuel Delgado, Javier González, Iván Quiroga. 2019. Follow-up and results in patients with differentiated thyroid carcinoma in Castilla-La Mancha (2001–2015). The CADIT-CAM study. *Endocrinología, Diabetes y Nutrición (English ed.)* **66**:3, 164-172. [Crossref]

438. Julia Sastre Marcos, Silvia Aznar, Visitación Álvarez, Belvis Torres, Manuel Delgado, Javier González, Iván Quiroga. 2019. Resultados del seguimiento de pacientes con carcinoma diferenciado de tiroides en Castilla-La Mancha (2001-2015). Estudio CADIT-CAM. *Endocrinología, Diabetes y Nutrición* **66**:3, 164-172. [Crossref]

439. Luis García Pascual, Maria Lluïsa Surralles, Xavier Morlius, Clarisa González Mínguez, Guillem Viscasillas, Xavier Lao. 2019. Punción-aspiración con aguja fina ecoguiada de nódulos tiroideos con valoración citológica in situ: eficacia diagnóstica, prevalencia y factores predictores de los resultados de categoría Bethesda I. *Endocrinología, Diabetes y Nutrición* . [Crossref]

440. Manuel António Campos, Sofia Macedo, Margarida Fernandes, Ana Pestana, Joana Pardal, Rui Batista, João Vinagre, Agostinho Sanches, Armando Baptista, José Manuel Lopes, Paula Soares. 2019. TERT promoter mutations are associated with poor prognosis in cutaneous squamous cell carcinoma. *Journal of the American Academy of Dermatology* **80**:3, 660-669.e6. [Crossref]

441. Hyun-Soo Zhang, Eun-Kyung Lee, Yuh-Seog Jung, Byung-Ho Nam, Kyu-Won Jung, Hyun-Joo Kong, Young-Joo Won, Boyoung Park. 2019. Total thyroidectomy's association with survival in papillary thyroid cancers and the high proportion of total thyroidectomy in low-risk patients: Analysis of Korean nationwide data. *Surgery* **165**:3, 629-636. [Crossref]

442. Franklin N. Tessler, William D. Middleton, Edward G. Grant, Jenny K. Hoang. 2019. Re: Cost-effectiveness of immediate biopsy versus surveillance of intermediate-suspicion thyroid nodules. *Surgery* **165**:3, 664-667. [Crossref]

443. Yu-Mi Lee, Jae Hyun Park, Jae Won Cho, Suck Joon Hong, Jong Ho Yoon. 2019. The definition of lymph node micrometastases in pathologic N1a papillary thyroid carcinoma should be revised. *Surgery* **165**:3, 652-656. [Crossref]

444. Xiaoyan Cai, Zheng Zhao, Jiangnan Dong, Qiang Lv, Bei Yun, Jiangqi Liu, Yan Shen, Jie Kang, Jun Li. 2019. Circular RNA circBACH2 plays a role in papillary thyroid carcinoma by sponging miR-139-5p and regulating LMO4 expression. *Cell Death & Disease* **10**:3. . [Crossref]

445. Lisa M. Lowenstein, Spyridon P. Basourakos, Michelle D. Williams, Patricia Troncoso, Justin R. Gregg, Timothy C. Thompson, Jeri Kim. 2019. Active surveillance for prostate and thyroid cancers: evolution in clinical paradigms and lessons learned. *Nature Reviews Clinical Oncology* **16**:3, 168-184. [Crossref]

446. Sean D. Raj, Rohit Ram, David J. Sabbag, Mark A. Sultenfuss, Rebecca Matejowsky. 2019. Thyroid Fine Needle Aspiration: Successful Prospective Implementation of Strategies to Eliminate Unnecessary Biopsy in the Veteran Population. *Current Problems in Diagnostic Radiology* **48**:2, 127-131. [Crossref]

447. Jennifer H. Kuo, Catherine McManus, Claire E. Graves, Amin Madani, Mamoona T. Khokhar, Bernice Huang, James A. Lee. 2019. Updates in the management of thyroid nodules. *Current Problems in Surgery* **56**:3, 103-127. [Crossref]

Downloaded by Memorial Sloan Kettering from www.liebertpub.com at 08/14/19. For personal use only.

448. Qingjun Wang, Yong Guo, Jing Zhang, Haoyong Ning, Xiliang Zhang, Yuanyuan Lu, Qinglei Shi. 2019. Diagnostic value of high b-value (2000s/mm2) DWI for thyroid micronodules. *Medicine* **98**:10, e14298. [Crossref]

449. Shikha Bose, Wendy Sacks, Ann E. Walts. 2019. Update on Molecular Testing for Cytologically Indeterminate Thyroid Nodules. *Advances In Anatomic Pathology* **26**:2, 114-123. [Crossref]

450. Jeffrey Liaw, Eric Cochran, Meghan N. Wilson. 2019. Primary Papillary Thyroid Cancer of a Thyroglossal Duct Cyst. *Ear, Nose & Throat Journal* **98**:3, 136-138. [Crossref]

451. Megan R Haymart, Mousumi Banerjee, David Reyes-Gastelum, Elaine Caoili, Edward C Norton. 2019. Thyroid Ultrasound and the Increase in Diagnosis of Low-Risk Thyroid Cancer. *The Journal of Clinical Endocrinology & Metabolism* **104**:3, 785-792. [Crossref]

452. Shunji Takahashi, Naomi Kiyota, Tomoko Yamazaki, Naoko Chayahara, Kenji Nakano, Lina Inagaki, Kazuhisa Toda, Tomohiro Enokida, Hironobu Minami, Yoshinori Imamura, Naoki Fukuda, Tatsuya Sasaki, Takuya Suzuki, Hiroki Ikezawa, Corina E Dutcus, Makoto Tahara. 2019. A Phase II study of the safety and efficacy of lenvatinib in patients with advanced thyroid cancer. *Future Oncology* **15**:7, 717-726. [Crossref]

453. MEHMET ZENGIN. 2019. Current approach to thyroid nodules: the Bethesta classification. *Journal of Health Sciences and Medicine* . [Crossref]

454. HyunGoo Kim, Hyungju Kwon, Woosung Lim, Byung-In Moon, Nam Sun Paik. 2019. Quantitative Assessment of the Learning Curve for Robotic Thyroid Surgery. *Journal of Clinical Medicine* **8**:3, 402. [Crossref]

455. Alessandro Semprebene, Anna Mangano, Guido Ventroni, Raffaella Barone, Francesca Piro, Lucio Mango. 2019. Differentiated Thyroid Carcinoma and Late Onset of Lung Distant Metastasis. A Case Report. *Reports* **2**:1, 6. [Crossref]

456. Tian Tian, Ying Kou, Rui Huang, Bin Liu. 2019. PROGNOSIS OF HIGH-RISK PAPILLARY THYROID CANCER PATIENTS WITH PRE-ABLATION STIMULATED TG <1 NG/ML. *Endocrine Practice* **25**:3, 220-225. [Crossref]

457. R. Michael Tuttle, Mona M. Sabra. 2019. ATA HIGH-RISK THYROID CANCER PATIENTS DEMONSTRATING AN EXCELLENT RESPONSE TO THERAPY WITHIN A FEW WEEKS OF INITIAL THERAPY HAVE BETTER THAN EXPECTED CLINICAL OUTCOMES. *Endocrine Practice* **25**:3, 287-289. [Crossref]

458. Jie Liu, Zongmin Zhang, Hui Huang, Siyuan Xu, Yang Liu, Shaoyan Liu, Xiaolei Wang, Zhengang Xu. 2019. Total thyroidectomy versus lobectomy for intermediate-risk papillary thyroid carcinoma: A single-institution matched-pair analysis. *Oral Oncology* **90**, 17-22. [Crossref]

459. Brian Hung-Hin Lang, Yu-Cho Woo, Keith Wan-Hang Chiu. 2019. Role of second high-intensity focused ultrasound (HIFU) treatment for unsatisfactory benign thyroid nodules after first treatment. *European Radiology* **29**:3, 1469-1478. [Crossref]

460. Fernando Jerkovich, María Gabriela García Falcone, Fabián Pitoia. 2019. The experience of an Endocrinology Division on the use of tyrosine multikinase inhibitor therapy in patients with radioiodine-resistant differentiated thyroid cancer. *Endocrine* **91**. . [Crossref]

461. Anery Patel, Valerie Shostrom, Kelly Treude, William Lydiatt, Russell Smith, Whitney Goldner. 2019. Serum Thyroglobulin: Preoperative Levels and Factors Affecting Postoperative Optimal Timing following Total Thyroidectomy. *International Journal of Endocrinology* **2019**, 1-8. [Crossref]

462. Feng-Qing Huang, Jing Li, Lin Jiang, Feng-Xiang Wang, Raphael N. Alolga, Ma-Jie Wang, Wen-Jian Min, Gaoxiang Ma, Yi-Jing Zhao, Shi-Lei Wang, Yuan Yu, Xiang Chen, Danxia Zhu, Jun Zhu, Guangzhou Wang, Tiansong Xia, Jian-Feng Sang, Mao-De Lai, Ping Li, Wei Zhu, Lian-Wen Qi. 2019. Serum-plasma matched metabolomics for comprehensive characterization of benign thyroid nodule and papillary thyroid carcinoma. *International Journal of Cancer* **144**:4, 868-876. [Crossref]

463. Deng-Ke Teng, He-Qun Li, Guo-Qing Sui, Yuan-Qiang Lin, Qiang Luo, Ping Fu, Jia-Rui Du, Chun-Xiang Jin, Hui Wang. 2019. Preliminary report of microwave ablation for the primary papillary thyroid microcarcinoma: a large-cohort of 185 patients feasibility study. *Endocrine* **142**. . [Crossref]

464. Rui Gao, Xi Jia, Yiqian Liang, Kun Fan, Xiaoxiao Wang, Yuanbo Wang, Lulu Yang, Aimin Yang, Guangjian Zhang. 2019. Papillary Thyroid Micro Carcinoma: The Incidence of High-Risk Features and Its Prognostic Implications. *Frontiers in Endocrinology* **10**. . [Crossref]

465. Marilena Celano, Valentina Maggisano, Saverio Massimo Lepore, Marialuisa Sponziello, Valeria Pecce, Antonella Verrienti, Cosimo Durante, Marianna Maranghi, Piernatale Lucia, Stefania Bulotta, Giuseppe Damante, Diego Russo. 2019. Expression of Leptin Receptor and Effects of Leptin on Papillary Thyroid Carcinoma Cells. *International Journal of Endocrinology* **2019**, 1-6. [Crossref]

466. Philippe Thuillier, David Bourhis, Nathalie Roudaut, Geneviève Crouzeix, Zarrin Alavi, Ulrike Schick, Philippe Robin, Véronique Kerlan, Pierre-Yves Salaun, Ronan Abgral. 2019. Diagnostic Value of FDG PET-CT Quantitative Parameters and Deauville-Like 5 Point-Scale in Predicting Malignancy of Focal Thyroid Incidentaloma. *Frontiers in Medicine* **6**. . [Crossref]

Downloaded by Memorial Sloan Kettering from www.liebertpub.com at 08/14/19. For personal use only.

467. 2019. ########. *Nihon Kikan Shokudoka Gakkai Kaiho* **70**:1, 38-40. [Crossref]

468. A. N. DiMarco, M. S. Wong, J. Jayasekara, D. Cole-Clark, A. Aniss, A. R. Glover, L. W. Delbridge, M. S. Sywak, S. B. Sidhu. 2019. Risk of needing completion thyroidectomy for low-risk papillary thyroid cancers treated by lobectomy. *BJS Open* **26**. . [Crossref]

469. J. J. Díez, J. C. Galofré, A. Oleaga, E. Grande, M. Mitjavila, P. Moreno. 2019. Results of a nationwide survey on multidisciplinary teams on thyroid cancer in Spain. *Clinical and Translational Oncology* **145**. . [Crossref]

470. Wang Tracy S.. 2019. Thyroid Lobectomy Versus High-Intensity Focused Ultrasound (HIFU) for the Management of Benign Thyroid Nodules. *Clinical Thyroidology* **31**:2, 61-64. [Citation] [Full Text] [PDF] [PDF Plus]

471. Biermann Martin. 2019. EU-TIRADS Can Decrease Unnecessary Fine-Needle Aspirations of 18F-FDG-Positive Thyroid Nodules. *Clinical Thyroidology* **31**:2, 65-68. [Citation] [Full Text] [PDF] [PDF Plus]

472. Silberstein Edward B. , Guest Associate Editor. 2019. Is It Time to Update the Classification for Radioiodine-Refractory Differentiated Thyroid Cancer?. *Clinical Thyroidology* **31**:2, 69-72. [Citation] [Full Text] [PDF] [PDF Plus]

473. Toft Daniel J.. 2019. I-131 Dosing Based on Stimulated Radioiodine Uptake and Thyroglobulin Is Favorable in Differentiated Thyroid Cancer. *Clinical Thyroidology* **31**:2, 73-75. [Citation] [Full Text] [PDF] [PDF Plus]

474. Hill Katherine A., Yip Linwah, Carty Sally E., McCoy Kelly L.. 2019. Concomitant Thyroid Cancer in Patients with Multiple Endocrine Neoplasia Type 1 Undergoing Surgery for Primary Hyperparathyroidism. *Thyroid* **29**:2, 252-257. [Abstract] [Full Text] [PDF] [PDF Plus]

475. Colombo Carla, Muzza Marina, Proverbio Maria Carla, Tosi Delfina, Soranna Davide, Pesenti Chiara, Rossi Stefania, Cirello Valentina, De Leo Simone, Fusco Nicola, Miozzo Monica, Bulfamante Gaetano, Vicentini Leonardo, Ferrero Stefano, Zambon Antonella, Tabano Silvia, Fugazzola Laura. 2019. Impact of Mutation Density and Heterogeneity on Papillary Thyroid Cancer Clinical Features and Remission Probability. *Thyroid* **29**:2, 237-251. [Abstract] [Full Text] [PDF] [PDF Plus] [Supplementary Material]

476. Kim Mijin, Jeon Min Ji, Han Minkyu, Lee Jeong Hyun, Song Dong Eun, Baek Jung Hwan, Kim Tae Yong, Kim Won Bae, Shong Young Kee, Kim Won Gu. 2019. Tumor Growth Rate Does Not Predict Malignancy in Surgically Resected Thyroid Nodules Classified as Bethesda Category III with Architectural Atypia. *Thyroid* **29**:2, 216-221. [Abstract] [Full Text] [PDF] [PDF Plus] [Supplementary Material]

477. Oh Hye-Seon, Ahn Jong Hwa, Song Eyun, Han Ji Min, Kim Won Gu, Kim Tae Yong, Kim Won Bae, Shong Young Kee, Jeon Min Ji. 2019. Individualized Follow-Up Strategy for Patients with an Indeterminate Response to Initial Therapy for Papillary Thyroid Carcinoma. *Thyroid* **29**:2, 209-215. [Abstract] [Full Text] [PDF] [PDF Plus] [Supplementary Material]

478. Bongiovanni Massimo, Giovanella Luca, Romanelli Francesco, Trimboli Pierpaolo. 2019. Cytological Diagnoses Associated with Noninvasive Follicular Thyroid Neoplasms with Papillary-Like Nuclear Features According to the Bethesda System for Reporting Thyroid Cytopathology: A Systematic Review and Meta-Analysis. *Thyroid* **29**:2, 222-228. [Abstract] [Full Text] [PDF] [PDF Plus] [Supplementary Material]

479. David L. Steward, Sally E. Carty, Rebecca S. Sippel, Samantha Peiling Yang, Julie A. Sosa, Jennifer A. Sipos, James J. Figge, Susan Mandel, Bryan R. Haugen, Kenneth D. Burman, Zubair W. Baloch, Ricardo V. Lloyd, Raja R. Seethala, William E. Gooding, Simion I. Chiosea, Cristiane Gomes-Lima, Robert L. Ferris, Jessica M. Folek, Raheela A. Khawaja, Priya Kundra, Kwok Seng Loh, Carrie B. Marshall, Sarah Mayson, Kelly L. McCoy, Min En Nga, Kee Yuan Ngiam, Marina N. Nikiforova, Jennifer L. Poehls, Matthew D. Ringel, Huaitao Yang, Linwah Yip, Yuri E. Nikiforov. 2019. Performance of a Multigene Genomic Classifier in Thyroid Nodules With Indeterminate Cytology. *JAMA Oncology* **5**:2, 204. [Crossref]

480. Qinghai Peng, Chengcheng Niu, Qianrong Zhang, Meixiang Zhang, Sijie Chen, Qiang Peng. 2019. Mummified Thyroid Nodules: Conventional and Contrast-Enhanced Ultrasound Features. *Journal of Ultrasound in Medicine* **38**:2, 441-452. [Crossref]

481. Dong Sik Bae, Do Hoon Koo. 2019. A Propensity Score-matched Comparison Study of Surgical Outcomes in Patients with Differentiated Thyroid Cancer After Robotic Versus Open Total Thyroidectomy. *World Journal of Surgery* **43**:2, 540-551. [Crossref]

482. Takayuki Ishigaki, Takashi Uruno, Tomoaki Tanaka, Yuna Ogimi, Chie Masaki, Junko Akaishi, Kiyomi Y. Hames, Tomonori Yabuta, Akifumi Suzuki, Chisato Tomoda, Kenichi Matsuzu, Keiko Ohkuwa, Wataru Kitagawa, Mitsuji Nagahama, Kiminori Sugino, Koichi Ito. 2019. Usefulness of Stereotactic Radiotherapy Using the CyberKnife for Patients with Inoperable Locoregional Recurrences of Differentiated Thyroid Cancer. *World Journal of Surgery* **43**:2, 513-518. [Crossref]

483. Sema Ciftci Dogansen, Artur Salmaslioglu, Gulsah Yenidunya Yalin, Seher Tanrikulu, Sema Yarman. 2019. Evaluation of the natural course of thyroid nodules in patients with acromegaly. *Pituitary* **22**:1, 29-36. [Crossref]

Downloaded by Memorial Sloan Kettering from www.liebertpub.com at 08/14/19. For personal use only.

484. Salvatore Gitto, Giorgia Grassi, Chiara De Angelis, Cristian Giuseppe Monaco, Silvana Sdao, Francesco Sardanelli, Luca Maria Sconfienza, Giovanni Mauri. 2019. A computer-aided diagnosis system for the assessment and characterization of low-to-high suspicion thyroid nodules on ultrasound. *La radiologia medica* **124**:2, 118-125. [Crossref]

485. Ken Watanabe, Takao Igarashi, Hirokazu Ashida, Sho Ogiwara, Tomoyuki Ohta, Mayuki Uchiyama, Hiroya Ojiri. 2019. Diagnostic value of ultrasonography and TI-201/Tc-99m dual scintigraphy in differentiating between benign and malignant thyroid nodules. *Endocrine* **63**:2, 301-309. [Crossref]

486. Georgios Boutzios, Gerasimos Tsourouflis, Zoe Garoufalia, Krystallenia Alexandraki, Grigorios Kouraklis. 2019. Long-term sequelae of the less than total thyroidectomy procedures for benign thyroid nodular disease. *Endocrine* **63**:2, 247-251. [Crossref]

487. Marco Raffaelli, Carmela De Crea, Luca Sessa, Serena Elisa Tempera, Amanda Belluzzi, Celestino P. Lombardi, Rocco Bellantone. 2019. Risk factors for local recurrence following lateral neck dissection for papillary thyroid carcinoma. *Endocrine* **63**:2, 310-315. [Crossref]

488. Wei Lan, Zhao Gege, Lv Ningning, Wen Qiang, Bai Lin, Ma Qingjie, Ji Bin. 2019. Negative remnant 99mTc-pertechnetate uptake predicts excellent response to radioactive iodine therapy in low- to intermediate-risk differentiated thyroid cancer patients who have undergone total thyroidectomy. *Annals of Nuclear Medicine* **33**:2, 112-118. [Crossref]

489. E. Macerola, T. Rago, A. Proietti, F. Basolo, P. Vitti. 2019. The mutational analysis in the diagnostic work-up of thyroid nodules: the real impact in a center with large experience in thyroid cytopathology. *Journal of Endocrinological Investigation* **42**:2, 157-166. [Crossref]

490. Y. Luo, Y. Zhao, K. Chen, J. Shen, J. Shi, S. Lu, J. Lei, Z. Li, D. Luo. 2019. Clinical analysis of cervical lymph node metastasis risk factors in patients with papillary thyroid microcarcinoma. *Journal of Endocrinological Investigation* **42**:2, 227-236. [Crossref]

491. Hui Tan, Jun Chen, Yi ling Zhao, Jin huan Liu, Liang Zhang, Chang sheng Liu, Dongjie Huang. 2019. Feasibility of Intravoxel Incoherent Motion for Differentiating Benign and Malignant Thyroid Nodules. *Academic Radiology* **26**:2, 147-153. [Crossref]

492. Véronique Raverot, Françoise Borson-Chazot. 2019. Isolated elevation of thyroglobulin in the follow-up of differentiated thyroid cancer, does it always indicate true persistent disease?. *Annales d'Endocrinologie* **80**:1, 61. [Crossref]

493. Young Min Park, Jeong-Rok Kim, Kyung Ho Oh, Jae-Gu Cho, Seung-Kuk Baek, Soon-Young Kwon, Kwang-Yoon Jung, Jeong-Soo Woo. 2019. Comparison of functional outcomes after total thyroidectomy and completion thyroidectomy: Hypoparathyroidism and postoperative complications. *Auris Nasus Larynx* **46**:1, 101-105. [Crossref]

494. Soh-Ching Ng, Bie-Yu Huang, Sheng-Fong Kuo, Chuen Hsueh, Kun-Chun Chiang, Chih-Hung Chen, Jen-Der Lin. 2019. Diagnostic pitfalls and therapeutic outcomes of the macrofollicular variant of papillary thyroid carcinoma. *Biomedical Journal* **42**:1, 59-65. [Crossref]

495. Manijeh Mohammadi, Carrie Betel, Kirsteen Rennie Burton, Kevin McLughlin Higgins, Zeina Ghorab, Ilana Jaye Halperin. 2019. Retrospective Application of the 2015 American Thyroid Association Guidelines for Ultrasound Classification, Biopsy Indications, and Follow-up Imaging of Thyroid Nodules: Can Improved Reporting Decrease Testing?. *Canadian Association of Radiologists Journal* **70**:1, 68-73. [Crossref]

496. Manijeh Mohammadi, Carrie Betel, Kirsteen Rennie Burton, Kevin McLughlin Higgins, Zeina Ghorab, Ilana Jaye Halperin. 2019. Follow-up of Benign Thyroid Nodules—Can We Do Less?. *Canadian Association of Radiologists Journal* **70**:1, 62-67. [Crossref]

497. K.C.W. Wong, T.Y. Ng, K.S. Yu, J.S.S. Kwok, K.C.A. Chan, J.J.S. Suen, S.F. Leung, A.T.C. Chan. 2019. The Use of Post-ablation Stimulated Thyroglobulin in Predicting Clinical Outcomes in Differentiated Thyroid Carcinoma – What Cut-off Values Should We Use?. *Clinical Oncology* **31**:2, e11-e20. [Crossref]

498. B. Migda, M. Migda, M.S. Migda. 2019. A systematic review and meta-analysis of the Kwak TIRADS for the diagnostic assessment of indeterminate thyroid nodules. *Clinical Radiology* **74**:2, 123-130. [Crossref]

499. Claire Bournaud, Françoise Descotes, Myriam Decaussin-Petrucci, Julien Berthiller, Christelle de la Fouchardière, Anne-Laure Giraudet, Mireille Bertholon-Gregoire, Philip Robinson, Jean-Christophe Lifante, Jonathan Lopez, Françoise Borson-Chazot. 2019. TERT promoter mutations identify a high-risk group in metastasis-free advanced thyroid carcinoma. *European Journal of Cancer* **108**, 41-49. [Crossref]

500. Prakshi Chopra, Chitresh Kumar. 2019. Thyroid lobectomy is not sufficient for T2 papillary thyroid cancers. *Surgery* **165**:2, 486-496. [Crossref]

501. Sarada Khadka, Kavindra Singh, Chitresh Kumar. 2019. Comments on: Cost-effectiveness of immediate biopsy versus surveillance of intermediate-suspicion thyroid nodules. *Surgery* **165**:2, 486-496. [Crossref]

502. Malak Itani, Richard Assaker, Mariam Moshiri, Theodore J. Dubinsky, Manjiri K. Dighe. 2019. Inter-observer Variability in the American College of Radiology Thyroid Imaging Reporting and Data System: In-Depth Analysis and Areas for Improvement. *Ultrasound in Medicine & Biology* **45**:2, 461-470. [Crossref]

Downloaded by Memorial Sloan Kettering from www.liebertpub.com at 08/14/19. For personal use only.

503. Qinghai Peng, Chengcheng Niu, Meixiang Zhang, Qiang Peng, Sijie Chen. 2019. Sonographic Characteristics of Papillary Thyroid Carcinoma with Coexistent Hashimoto's Thyroiditis: Conventional Ultrasound, Acoustic Radiation Force Impulse Imaging and Contrast-Enhanced Ultrasound. *Ultrasound in Medicine & Biology* **45**:2, 471-480. [Crossref]

504. Elias Shaaya, Jared Fridley, Sean M. Barber, Sohail Syed, Jimmy Xia, Michael Galgano, Adetokunbo Oyelese, Albert Telfeian, Ziya Gokaslan. 2019. Posterior Nerve–Sparing Multilevel Cervical Corpectomy and Reconstruction for Metastatic Cervical Spine Tumors: Case Report and Literature Review. *World Neurosurgery* **122**, 298-302. [Crossref]

505. Satoshi Kato, Hideki Murakami, Satoru Demura, Katsuhito Yoshioka, Noriaki Yokogawa, Noritaka Yonezawa, Takaki Shimizu, Norihiro Oku, Ryo Kitagawa, Hiroyuki Tsuchiya. 2019. Kidney and Thyroid Cancer-Specific Treatment Algorithm for Spinal Metastases: A Validation Study. *World Neurosurgery* **122**, e1305-e1311. [Crossref]

506. Bernard Escudier, Francis Worden, Masatoshi Kudo. 2019. Sorafenib: key lessons from over 10 years of experience. *Expert Review of Anticancer Therapy* **19**:2, 177-189. [Crossref]

507. Michael S. Xu, Jennifer Li, Sam M. Wiseman. 2019. Major vessel invasion by thyroid cancer: a comprehensive review. *Expert Review of Anticancer Therapy* **19**:2, 191-203. [Crossref]

508. Pedro W. Rosario, Tiara G. Rocha, Maria R. Calsolari. 2019. Fluorine-18-fluorodeoxyglucose positron emission tomography in thyroid nodules with indeterminate cytology. *Nuclear Medicine Communications* **40**:2, 185-187. [Crossref]

509. Danni Jiang, Yichen Zang, Dandan Jiang, Xiaojuan Zhang, Cheng Zhao. 2019. Value of rapid on-site evaluation for ultrasound-guided thyroid fine needle aspiration. *Journal of International Medical Research* **47**:2, 626-634. [Crossref]

510. Jasmine ME Chua, Jonathan YM Tang, Desmond SW Lim, Nanda Venkatanarasimha, Sivanathan Chandramohan, Chow Wei Too, Sarat K Sanamandra, Parag R Salkade, Bien Soo Tan, Karthikeyan Damodharan. 2019. Should we perform fine needle aspiration cytology of subcentimetre thyroid nodules? A retrospective review of local practice. *Ultrasound* **27**:1, 64-68. [Crossref]

511. Mônica R Gadelha, Leandro Kasuki, Dawn S T Lim, Maria Fleseriu. 2019. Systemic Complications of Acromegaly and the Impact of the Current Treatment Landscape: An Update. *Endocrine Reviews* **40**:1, 268-332. [Crossref]

512. Giulia Sapuppo, Martina Tavarelli, Antonino Belfiore, Riccardo Vigneri, Gabriella Pellegriti. 2019. Time to Separate Persistent From Recurrent Differentiated Thyroid Cancer: Different Conditions With Different Outcomes. *The Journal of Clinical Endocrinology & Metabolism* **104**:2, 258-265. [Crossref]

513. Cristiane J Gomes-Lima, Di Wu, Sarika N Rao, Sree Punukollu, Rama Hritani, Alexander Zeymo, Hala Deeb, Mihriye Mete, Edward F Aulisi, Douglas Van Nostrand, Jacqueline Jonklaas, Leonard Wartofsky, Kenneth D Burman. 2019. Brain Metastases From Differentiated Thyroid Carcinoma: Prevalence, Current Therapies, and Outcomes. *Journal of the Endocrine Society* **3**:2, 359-371. [Crossref]

514. Alexis Deffain, Federica Scipioni, Beatriz De Rienzo, Sana Allal, Marion Castagnet, Jean-Louis Kraimps, Gianluca Donatini. 2019. Preoperative vitamin D levels do not relate with the risk of hypocalcemia following total thyroidectomy. A cohort study. *Minerva Chirurgica* **74**:1. . [Crossref]

515. Livia Lamartina, Teresa Montesano, Rosa Falcone, Marco Biffoni, Giorgio Grani, Marianna Maranghi, Laura Ciotti, Laura Giacomelli, Valeria Ramundo, Cristano Lomonaco, Cira Rosaria Di Gioia, Lucia Piernatale, Giuseppe Ronga, Cosimo Durante. 2019. IS IT WORTH SUPPRESSING TSH IN LOW- AND INTERMEDIATE-RISK PAPILLARY THYROID CANCER PATIENTS BEFORE THE FIRST DISEASE ASSESSMENT?. *Endocrine Practice* **25**:2, 165-169. [Crossref]

516. Ludovico M. Garau, Domenico Rubello, Riccardo Morganti, Giuseppe Boni, Duccio Volterrani, Patrick M. Colletti, Gianpiero Manca. 2019. Sentinel Lymph Node Biopsy in Small Papillary Thyroid Cancer. *Clinical Nuclear Medicine* **44**:2, 107-118. [Crossref]

517. Yasuhiro Ito, Akira Miyauchi. 2019. Active Surveillance as First-Line Management of Papillary Microcarcinoma. *Annual Review of Medicine* **70**:1, 369-379. [Crossref]

518. Katerina Mastrocostas, Kim May Lam, Shereen Ezzat, Sangeet Ghai. Endocrine Gland Imaging 223-262. [Crossref]

519. Fan Yang, Qi Zhong, Zhigang Huang, Meng Lian, Jugao Fang. 2019. Survival in Papillary Thyroid Microcarcinoma: A Comparative Analysis Between the 7th and 8th Versions of the AJCC/UICC Staging System Based on the SEER Database. *Frontiers in Endocrinology* **10**. . [Crossref]

520. Evanthia Giannoula, Ioannis Iakovou, Ioannis Katsikavelas, Panagiotis Antoniou, Vasilios Raftopoulos, Vasiliki Chatzipavlidou, Nikitas Papadopoulos, Susanne Singer, Panagiotis Bamidis. 2019. Development of a mobile application for thyroid cancer patients aiming to enhance their quality of life: Protocol for a pilot study (Preprint). *JMIR Research Protocols* . [Crossref]

521. Luying Gao, Xuehua Xi, Yuxin Jiang, Xiao Yang, Ying Wang, Shenling Zhu, Xingjian Lai, Xiaoyan Zhang, Ruina Zhao, Bo Zhang. 2019. Comparison among TIRADS (ACR TI-RADS and KWAK- TI-RADS) and 2015 ATA Guidelines in the diagnostic efficiency of thyroid nodules. *Endocrine* **126**. . [Crossref]

Downloaded by Memorial Sloan Kettering from www.liebertpub.com at 08/14/19. For personal use only.

522. Andreea Borlea, Laura Cotoi, Ioana Mozos, Dana Stoian. Advanced Ultrasound Techniques in Preoperative Diagnostic of Thyroid Cancers . [Crossref]

523. Min Ji Jeon, Sung Min Chun, Ji-Young Lee, Kyeong Woon Choi, Deokhoon Kim, Tae Yong Kim, Se Jin Jang, Won Bae Kim, Young Kee Shong, Dong Eun Song, Won Gu Kim. 2019. Mutational profile of papillary thyroid microcarcinoma with extensive lymph node metastasis. *Endocrine* **26**. . [Crossref]

524. Feng Cheng, Yanyan Chen, Lei Zhu, Bin Zhou, Yonghong Xu, Yiran Chen, Liping Wen, Shuzheng Chen. 2019. Risk Factors for Cervical Lymph Node Metastasis of Papillary Thyroid Microcarcinoma: A Single-Center Retrospective Study. *International Journal of Endocrinology* **2019**, 1-6. [Crossref]

525. Molnar Călin, Butiurca Vlad Olimpiu, Molnar Varlam Claudiu, Botoncea Marian. Thyroidectomy without Ligatures in Differentiated Thyroid Cancer . [Crossref]

526. Gaetano Achille, Marco Castellana, Sabino Russo, Massimo Montepara, Vito Angelo Giagulli, Vincenzo Triggiani. 2019. Zenker Diverticulum: A Potential Pitfall in Thyroid Ultrasound Evaluation: A Case Report and Systematic Review of Literature. *Endocrine, Metabolic & Immune Disorders - Drug Targets* **19**:1, 95-99. [Crossref]

527. Demet Sengul, Ilker Sengul, Sam Van Slycke. 2019. Risk stratification of the thyroid nodule with Bethesda indeterminate cytology, category III, IV, V on the one surgeon-performed US-guided fine-needle aspiration with 27-gauge needle, verified by histopathology of thyroidectomy: the additional value of one surgeon-performed elastography. *Acta Chirurgica Belgica* **119**:1, 38-46. [Crossref]

528. Angell Trevor E.. 2019. More Hürthle-Cell Aspirations Will Be Identified as Benign by the New Afirma GSC Test. *Clinical Thyroidology* **31**:1, 17-19. [Citation] [Full Text] [PDF] [PDF Plus]

529. Kim Brian W.. 2019. An Increased Relative but Small Absolute Risk of Leukemia Can Be Attributed to I-131 Ablation. *Clinical Thyroidology* **31**:1, 30-32. [Citation] [Full Text] [PDF] [PDF Plus]

530. Luster Markus, Aktolun Cumali, Amendoeira Isabel, Barczyński Marcin, Bible Keith C., Duntas Leonidas H., Elisei Rossella, Handkiewicz-Junak Daria, Hoffmann Martha, Jarząb Barbara, Leenhardt Laurence, Musholt Thomas J., Newbold Kate, Nixon Iain J., Smit Johannes, Sobrinho-Simões Manuel, Sosa Julie Ann, Tuttle R. Michael, Verburg Frederik A., Wartofsky Leonard, Führer Dagmar. 2019. European Perspective on 2015 American Thyroid Association Management Guidelines for Adult Patients with Thyroid Nodules and Differentiated Thyroid Cancer: Proceedings of an Interactive International Symposium. *Thyroid* **29**:1, 7-26. [Abstract] [Full Text] [PDF] [PDF Plus] [Supplementary Material]

531. Li Panli, Zhang Aimi, Liu Ye, Xu Chunyuan, Tang Linglin, Yuan Hong, Liu Qiufang, Wang Xiuying, Feng Dagan, Wang Lisheng, Huang Gang, Song Shaoli. 2019. Radioactive Iodine Therapy in Patients with Differentiated Thyroid Cancer: Study of External Dose Rate Attenuation Law and Individualized Patient Management. *Thyroid* **29**:1, 93-100. [Abstract] [Full Text] [PDF] [PDF Plus] [Supplementary Material]

532. Jin Yuchen, Ruan Maomei, Cheng Lingxiao, Fu Hao, Liu Min, Sheng Shiwei, Chen Libo. 2019. Radioiodine Uptake and Thyroglobulin-Guided Radioiodine Remnant Ablation in Patients with Differentiated Thyroid Cancer: A Prospective, Randomized, Open-Label, Controlled Trial. *Thyroid* **29**:1, 101-110. [Abstract] [Full Text] [PDF] [PDF Plus]

533. Dekker Bernadette L., van der Horst-Schrivers Anouk N.A., Sluiter Wim J., Brouwers Adrienne H., Lentjes Eef G.W.M., Heijboer Annemieke C., Muller Kobold Anneke C., Links Thera P.. 2019. Clinical Applicability of Low Levels of Thyroglobulin Autoantibodies as Cutoff Point for Thyroglobulin Autoantibody Positivity. *Thyroid* **29**:1, 71-78. [Abstract] [Full Text] [PDF] [PDF Plus]

534. Boufraqech Myriem, Patel Dhaval, Nilubol Naris, Powers Astin, King Timothy, Shell Jasmine, Lack Justin, Zhang Lisa, Gara Sudheer Kumar, Gunda Viswanath, Klubo-Gwiezdzinska Joanna, Kumar Suresh, Fagin James, Knauf Jeffrey, Parangi Sareh, Venzon David, Quezado Martha, Kebebew Electron. 2019. Lysyl Oxidase Is a Key Player in BRAF/MAPK Pathway-Driven Thyroid Cancer Aggressiveness. *Thyroid* **29**:1, 79-92. [Abstract] [Full Text] [PDF] [PDF Plus] [Supplementary Material]

535. Sakai Toshihiko, Sugitani Iwao, Ebina Aya, Fukuoka Osamu, Toda Kazuhisa, Mitani Hiroki, Yamada Keiko. 2019. Active Surveillance for T1bN0M0 Papillary Thyroid Carcinoma. *Thyroid* **29**:1, 59-63. [Abstract] [Full Text] [PDF] [PDF Plus]

536. Song Eyun, Han Minkyu, Oh Hye-Seon, Kim Won Woong, Jeon Min Ji, Lee Yu-Mi, Kim Tae Yong, Chung Ki Wook, Kim Won Bae, Shong Young Kee, Hong Suck Joon, Sung Tae-Yon, Kim Won Gu. 2019. Lobectomy Is Feasible for 1–4 cm Papillary Thyroid Carcinomas: A 10-Year Propensity Score Matched-Pair Analysis on Recurrence. *Thyroid* **29**:1, 64-70. [Abstract] [Full Text] [PDF] [PDF Plus] [Supplementary Material]

537. Joanna Klubo-Gwiezdzinska, Sungyoung Auh, Marvin Gershengorn, Brianna Daley, Athanasios Bikas, Kenneth Burman, Leonard Wartofsky, Mark Urken, Eliza Dewey, Robert Smallridge, Ana-Maria Chindris, Electron Kebebew. 2019. Association of Thyrotropin Suppression With Survival Outcomes in Patients With Intermediate- and High-Risk Differentiated Thyroid Cancer. *JAMA Network Open* **2**:2, e187754. [Crossref]

Downloaded by Memorial Sloan Kettering from www.liebertpub.com at 08/14/19. For personal use only.

538. Akira Ohtsuru, Sanae Midorikawa, Tetsuya Ohira, Satoru Suzuki, Hideto Takahashi, Michio Murakami, Hiroki Shimura, Takashi Matsuzuka, Seiji Yasumura, Shin-ichi Suzuki, Susumu Yokoya, Yuko Hashimoto, Akira Sakai, Hitoshi Ohto, Shunichi Yamashita, Koichi Tanigawa, Kenji Kamiya. 2019. Incidence of Thyroid Cancer Among Children and Young Adults in Fukushima, Japan, Screened With 2 Rounds of Ultrasonography Within 5 Years of the 2011 Fukushima Daiichi Nuclear Power Station Accident. *JAMA Otolaryngology–Head & Neck Surgery* **145**:1, 4. [Crossref]

539. Kaitlin E. Sundling, Daniel F. I. Kurtycz. 2019. Standardized terminology systems in cytopathology. *Diagnostic Cytopathology* **47**:1, 53-63. [Crossref]

540. Shorook Na'ara, Kamel Mahameed, Moran Amit, Jacob T. Cohen, Michal Weiler-Sagie, Igor Albitskiy, Ziv Gil, Salem Billan. 2019. Efficacy of posttreatment radioiodine scanning in patients with differentiated thyroid cancer. *Head & Neck* . [Crossref]

541. Carolina Whittle, Marisol García, Eleonora Horvath, Jeannie Slater, Carmen Carrasco. 2019. Thyroid Microcalcifications in the Absence of Identifiable Nodules and Their Association With Thyroid Cancer. *Journal of Ultrasound in Medicine* **38**:1, 97-102. [Crossref]

542. Daniela Pinto, Sílvia Costa Dias. Value-Based Radiology in Pediatric Imaging . [Crossref]

543. Andreas Knopf. Sonography of Major Salivary Glands 235-257. [Crossref]

544. Tomislav Novosel, Peter Jecker. Ultrasound of the Thyroid Gland 259-278. [Crossref]

545. Julian Küstermeyer. Contrast-Enhanced Ultrasonography: Clinical Applications 331-348. [Crossref]

546. Jens E. Meyer. Sonography of Lymph Nodes in the Neck 53-94. [Crossref]

547. Alexander N. Sencha, Yury N. Patrunov, Stanislav V. Pavlovich, Liubov A. Timofeyeva, Munir G. Tukhbatullin, Antonina A. Smetnik. Current State of the Problem of Thyroid Diseases: Principles and Technology of Thyroid Ultrasound 1-38. [Crossref]

548. Antonina A. Smetnik, Alexander N. Sencha, Stanislav V. Pavlovich. Thyroid Disorders and Female Reproductive System Diseases: The Thyroid Gland and Pregnancy 203-213. [Crossref]

549. Yuriy K. Aleksandrov, Yury N. Patrunov, Alexander N. Sencha. Ultrasound-Guided Fine Needle Aspiration Biopsy 231-242. [Crossref]

550. Liubov A. Timofeyeva, Ekaterina A. Sencha, Yuriy K. Aleksandrov, Alexander N. Sencha, Munir G. Tukhbatullin. TIRADS Classification as a Malignancy Risk Stratification System 131-145. [Crossref]

551. Tanaz Vaghaiwalla, Peter Angelos. How Should Well Differentiated Thyroid Cancer with Distant Metastatic Disease Be Managed? 135-140. [Crossref]

552. Alison Roos, Sara A. Byron. Genomics-Enabled Precision Medicine for Cancer 137-169. [Crossref]

553. Frederik A. Verburg. Radioiodine Therapy of Thyroid Cancer 35-42. [Crossref]

554. Stefan K. G. Grebe. Laboratory Testing in Thyroid Disorders 129-159. [Crossref]

555. Enrico Papini, R. Guglielmi, Irene Misischi, Andrea Frasoldati. Ultrasonography of the Thyroid and Cervical Lymph Nodes 161-179. [Crossref]

556. Kerstin Lorenz. Surgery for Benign Goiter 205-216. [Crossref]

557. Gabriela Brenta, José Sgarbi. Subclinical Hyperthyroidism 339-355. [Crossref]

558. Simone De Leo, Lewis E. Braverman. Iodine-Induced Thyroid Dysfunction 435-452. [Crossref]

559. Alan A. Parsa, Hossein Gharib. Thyroid Nodule: Current Evaluation and Management 493-516. [Crossref]

560. Gilberto Paz-Filho, Hans Graf. Nontoxic Multinodular Goiter 517-537. [Crossref]

561. Athanasios Bikas, Kenneth D. Burman. Epidemiology of Thyroid Cancer 541-547. [Crossref]

562. Young Ah Lee, Andrew J. Bauer. Thyroid Cancer in Children and Adolescents 563-582. [Crossref]

563. Brian R. Untch, Dipti Kamani, Gregory W. Randolph. Thyroid Cancer Surgery 583-594. [Crossref]

564. Joanna Klubo-Gwiezdzinska. Staging and Prognosis of Thyroid Cancer 595-610. [Crossref]

565. Jasna Mihailovic, Stanley J. Goldsmith. Radioiodine Therapy in Differentiated Thyroid Carcinoma 611-632. [Crossref]

566. Ulla Feldt-Rasmussen, Luca Giovanella. 655. [Crossref]

567. Rami Alrezk, Joanna Klubo-Gwiezdzinska. The Role of TSH Suppression in the Management of Differentiated Thyroid Cancer 711-720. [Crossref]

568. Moni A. Kuriakose, Swagnik Chakrabarti, Sok Ching Cheong, Luiz P. Kowalski, Tiago Novaes Pinheiro, Camile S. Farah. Head and Neck Tumors 627-762. [Crossref]

569. Paul A. VanderLaan, Jeffrey F. Krane. Head and Neck: Thyroid 159-203. [Crossref]

Downloaded by Memorial Sloan Kettering from www.liebertpub.com at 08/14/19. For personal use only.

570. Serpil Salman. Amiodarone-Induced Thyrotoxicosis in a Patient with Multinodular Goiter 3-7. [Crossref]
571. Bala Başak Öven, Mehmet Tarık Tatoğlu. A Patient Presenting with an Incidentally Found Hypermetabolic Thyroid Nodule on FDG-PET/CT 57-61. [Crossref]
572. Gülşah Yenidünya Yalın, Betül Uğur Altun. Management of a Thyroid Nodule Which Is Hypoactive on Thyroid Scintigraphy and Has Eggshell Calcification on USG 63-67. [Crossref]
573. Mine Adaş, Gökhan Adaş. Should Calcitonin Be Measured in Every Thyroid Nodule? 79-81. [Crossref]
574. Levent Kabasakal, Onur Erdem Şahin. The Role of Thyroid Scintigraphy in the Evaluation of Thyroid Nodules in Patients with Normal TSH 83-86. [Crossref]
575. Meral Mert, Murat Sipahi. Incidentally Detected Thyroid Follicular Adenoma on Myocardial Perfusion Scintigraphy with Tc-99m MIBI 87-90. [Crossref]
576. M. Ümit Uğurlu, Bahadır M. Güllüoğlu. Follicular Neoplasia 91-97. [Crossref]
577. Mehmet Ali Koç, Seher Demirer, Akın Fırat Kocaay. A Gray Zone in Thyroid Fine-Needle Aspiration Cytology: AUS-FLUS 99-103. [Crossref]
578. Semra Günay, Orhan Yalçın. Is Surgery the Treatment of Choice for Every Thyroid Nodule? 105-110. [Crossref]
579. Ali İlker Filiz, Taner Kıvılcım. Follow-Up of Nodular-Multinodular Goiter: When Should the Operation Be Performed? 111-117. [Crossref]
580. Beyza Özçınar, Sibel Özkan Gürdal. Recurrent Nodular Goiter 119-124. [Crossref]
581. Seyfettin Ilgan. Preoperative Cervical USG Mapping in a Patient Undergoing Thyroidectomy for Malignant Cytological Findings 173-181. [Crossref]
582. Ülkem Yararbaş, Zehra Özcan. Papillary Thyroid Carcinoma and Microcarcinoma 183-186. [Crossref]
583. Gülin Uçmak, Burcu Esen Akkaş. Thyrotoxicosis Caused by Functioning Metastases of Differentiated Thyroid Cancer 193-200. [Crossref]
584. Yasemin Giles Şenyürek, İsmail Cem Sormaz. Papillary Thyroid Carcinoma 201-208. [Crossref]
585. Yasemin Giles Şenyürek, İsmail Cem Sormaz. Papillary Thyroid Carcinoma with Central Lymph Node Metastases 209-215. [Crossref]
586. Banu Bilezikçi, Seyfettin Ilgan. A Case of Papillary Carcinoma of the Thyroid with Minimal Extrathyroidal Extension 217-223. [Crossref]
587. Betül Bozkurt. Therapeutic Neck Dissection for Differentiated Thyroid Cancer, to Whom and to What Extent? 225-231. [Crossref]
588. Serap Erel. Prophylactic Unilateral Neck Dissection for Differentiated Thyroid Cancer 233-237. [Crossref]
589. Serdar Özbaş, Seyfettin Ilgan. Completion Thyroidectomy in a Patient with Differentiated Thyroid Cancer 245-251. [Crossref]
590. Gülin Uçmak, B. Büşra Demirel. FDG PET/CT in the Initial Staging of Differentiated Thyroid Cancer 253-258. [Crossref]
591. Betül Uğur Altun, Gülşah Yenidünya Yalın. Toxic Multinodular Goiter in a Patient Who Has Been Followed Up with the Diagnosis of Hashimoto Thyroiditis and Has Normal TSH Values 19-22. [Crossref]
592. Ülkem Yararbaş, Zehra Özcan. A Case of a Papillary Thyroid Cancer with Gross Residual Disease After Surgery 259-262. [Crossref]
593. Gülin Uçmak, Burcu Esen Akkaş. The Effect of Positive Surgical Margins After Thyroidectomy on Patient Prognosis in Cases with Differentiated Thyroid Carcinoma 263-268. [Crossref]
594. Gülin Uçmak, B. Büşra Demirel. Anti-thyroglobulin Antibody Positivity During Follow-Up of a Patient with Differentiated Thyroid Cancer 281-286. [Crossref]
595. Çiğdem Soydal, Elgin Özkan. A Patient with Differentiated Thyroid Cancer with Tg Values Constantly Above Normal but Not Increasing Gradually 287-290. [Crossref]
596. Çiğdem Soydal, Elgin Özkan. A Patient with Papillary Thyroid Carcinoma and Biochemical Incomplete Response with Gradually Increasing Tg Values and Negative Imaging Studies 291-295. [Crossref]
597. Gülin Uçmak, Burcu Esen Akkaş. Rosiglitazone Effect on Radioiodine Uptake in a Case of Dedifferentiated Thyroid Carcinoma 297-303. [Crossref]
598. Seyfettin Ilgan. Management of Recurrent Lymph Nodes in Central and Lateral Neck in the Follow-Up of Differentiated Thyroid Carcinoma 305-311. [Crossref]
599. Elgin Özkan, Çiğdem Soydal. Minimally Invasive Follicular Carcinoma 313-316. [Crossref]
600. Elgin Özkan, Çiğdem Soydal. Follicular Thyroid Cancer and Bone Metastasis 317-321. [Crossref]

Downloaded by Memorial Sloan Kettering from www.liebertpub.com at 08/14/19. For personal use only.

601. Gülin Uçmak, Burcu Esen Akkaş. Differentiated Thyroid Cancer with Brain Metastasis 323-330. [Crossref]
602. Levent Kabasakal, Onur Erdem Şahin. Targeted Systemic Therapy in Patients with Radioiodine-Refractory Differentiated Thyroid Cancer 341-346. [Crossref]
603. Tevfik Fikret Çermik, Nurhan Ergül. Thyroid Follicular Carcinoma with Iodine-Avid Bone Metastases Showing Mild Uptake on Both 18F-FDG and 68Ga-DOTATOC PET/CT 347-352. [Crossref]
604. Levent Kabasakal, Onur Erdem Şahin. Somatostatin Receptor Imaging in Differentiated Thyroid Cancer 353-357. [Crossref]
605. Gülin Uçmak, B. Büşra Demirel. The Clinical Management of a Patient with Insular Thyroid Carcinoma 365-370. [Crossref]
606. Neslihan Kurtulmuş. Concurrent Papillary Thyroid Cancer and Medullary Thyroid Cancer 387-392. [Crossref]
607. Elgin Özkan, Çiğdem Soydal. Hurthle Cell Carcinoma 399-402. [Crossref]
608. Hakan Demir. Radioiodine Therapy During Breastfeeding 409-413. [Crossref]
609. Belma Koçer. Surgery in Graves' Disease 35-43. [Crossref]
610. Türkay Kırdak. Surgery in Hyperthyroidism: Toxic Adenoma and/or Multinodular Goiter 45-49. [Crossref]
611. Filiz Özülker, Tamer Özülker. A Case of Sarcoidosis, Differentiated Thyroid Carcinoma, and Graves' Disease in the Thyroid Gland 51-56. [Crossref]
612. Juan C. Hernandez-Prera, Bruce M. Wenig. Predictive Markers and Targeted Therapies in Thyroid Cancer and Selected Endocrine Tumors 493-500. [Crossref]
613. Mark S. Sneider, Peter S. Dahlberg. Robotic Thyroidectomy 311-316. [Crossref]
614. Michiya Nishino. 249. [Crossref]
615. Lukasz Czerwonka. Goiter 431-433. [Crossref]
616. Melissa Boltz. Thyroid Nodule 435-437. [Crossref]
617. Malini Soundarrajan, Peter A. Kopp. Thyroid Hormone Biosynthesis and Physiology 1-17. [Crossref]
618. Vishnu Vardhan Garla, Licy L. Yanes Cardozo, Lillian Frances Lien. Hypothyroidism 19-43. [Crossref]
619. Sarah E. Mayson, Linda A. Barbour. Thyroid Nodules and Cancer in Pregnancy 137-156. [Crossref]
620. Yasuhiro Ito, Akira Miyauchi, Hitomi Oda. Management of Papillary Microcarcinoma of the Thyroid with A Short Column (Management of Tumors Diagnosed as Follicular Neoplasm on Cytology) 83-90. [Crossref]
621. Kennichi Kakudo, S. Satoh, Y. Okamoto. How to Follow Fine-Needle Aspiration Biopsy-Confirmed Benign Thyroid Nodules 91-93. [Crossref]
622. Sanae Midorikawa, Akira Ohtsuru. How to Be Considerate to Patients with Thyroid Nodules: Lessons from the Pediatric Thyroid Cancer Screening Program in Fukushima After the Nuclear Plant Accident 95-99. [Crossref]
623. Pichet Sampatanukul, Andrey Bychkov. Specimen Adequacy and Non-diagnostic Thyroid Nodules 113-123. [Crossref]
624. Kennichi Kakudo, Marc Pusztaszeri, Massimo Bongiovanni. Factors Impacting Thyroid Fine Needle Aspiration Cytology and Algorithm for Cytological Diagnosis in the Japanese System for Reporting FNA Cytology 19-26. [Crossref]
625. Kennichi Kakudo, Zhiyan Liu, Yubo Ren, Tomoko Wakasa. Diagnostic Criteria for AUS/FLUS in the Second Edition Bethesda System for Reporting Thyroid Cytopathology 187-193. [Crossref]
626. Andrey Bychkov, Chan Kwon Jung. Hobnail Variant of Papillary Thyroid Carcinoma 241-248. [Crossref]
627. Sule Canberk. Aggressive/Non-aggressive Oncocytic/Non-oncocytic Variants of Papıllary Thyroid Carcınoma 255-265. [Crossref]
628. Giovanni Tallini, Dario de Biase, Andrea Repaci, Michela Visani. What's New in Thyroid Tumor Classification, the 2017 World Health Organization Classification of Tumours of Endocrine Organs 37-47. [Crossref]
629. Jay Wasman. Hürthle Cell Neoplasms in Papanicolaou- and Romanowsky-Stained Specimens 355-364. [Crossref]
630. Massimo Bongiovanni, Esther Diana Rossi. Experience in Molecular Testing Using FNA Cytology in EU Countries 443-449. [Crossref]
631. Chan Kwon Jung. Core Needle Biopsy for the Diagnosis of Thyroid Nodules: Pathologic Aspects 491-504. [Crossref]
632. Akira Ohtsuru, Sanae Midorikawa, Satoru Suzuki, Hiroki Shimura, Takashi Matsuzuka, Shunichi Yamashita. Thyroid Cancer Screening Program for Young People in Fukushima After the Nuclear Plant Accident 519-523. [Crossref]
633. Marc Pusztaszeri. Introduction to the Second Edition of the Bethesda System for Reporting Thyroid Cytopathology 59-68. [Crossref]
634. Priyanthi Kumarasinghe. Australian System for Reporting Thyroid Cytology 69-76. [Crossref]

Downloaded by Memorial Sloan Kettering from www.liebertpub.com at 08/14/19. For personal use only.

635. Rui Huang, Rong Tian, Zhaowei Meng. Na+/I– Symporter Target for Thyroid Disease Imaging and Treatment 235-255. [Crossref]

636. Su Min Ha, Jung Hwan Baek, Young Jun Choi, Sae Rom Chung, Tae Yon Sung, Tae Yong Kim, Jeong Hyun Lee. 2019. Malignancy risk of initially benign thyroid nodules: validation with various Thyroid Imaging Reporting and Data System guidelines. *European Radiology* **29**:1, 133-140. [Crossref]

637. Brian H. H. Lang, Yu-Cho Woo, Keith Wan-Hang Chiu. 2019. Two-year efficacy of single-session high-intensity focused ultrasound (HIFU) ablation of benign thyroid nodules. *European Radiology* **29**:1, 93-101. [Crossref]

638. Marc Monachese, Gautam Mankaney, Rocio Lopez, Margaret O'Malley, Lisa Laguardia, Matthew F. Kalady, James Church, Joyce Shin, Carol A. Burke. 2019. Outcome of thyroid ultrasound screening in FAP patients with a normal baseline exam. *Familial Cancer* **18**:1, 75-82. [Crossref]

639. Domenico Albano, Maria Beatrice Panarotto, Rexhep Durmo, Carlo Rodella, Francesco Bertagna, Raffaele Giubbini. 2019. Clinical and prognostic role of detection timing of distant metastases in patients with differentiated thyroid cancer. *Endocrine* **63**:1, 79-86. [Crossref]

640. C. Sparano, G. Parenti, A. Cilotti, L. Bencini, M. Calistri, E. Mannucci, C. Biagini, V. Vezzosi, M. Mannelli, G. Forti, L. Petrone. 2019. Clinical impact of the new SIAPEC-IAP classification on the indeterminate category of thyroid nodules. *Journal of Endocrinological Investigation* **42**:1, 1-6. [Crossref]

641. M. G. Castagna, C. Marzocchi, T. Pilli, R. Forleo, F. Pacini, S. Cantara. 2019. MicroRNA expression profile of thyroid nodules in fine-needle aspiration cytology: a confirmatory series. *Journal of Endocrinological Investigation* **42**:1, 97-100. [Crossref]

642. M. Borowczyk, A. Janicki, G. Dworacki, E. Szczepanek-Parulska, M. Danieluk, J. Barnett, M. Antonik, M. Kałużna, B. Bromińska, R. Czepczyński, M. Bączyk, K. Ziemnicka, M. Ruchała. 2019. Decreased staging of differentiated thyroid cancer in patients with chronic lymphocytic thyroiditis. *Journal of Endocrinological Investigation* **42**:1, 45-52. [Crossref]

643. G. Grani, L. Lamartina, T. Montesano, G. Ronga, V. Maggisano, R. Falcone, V. Ramundo, L. Giacomelli, C. Durante, D. Russo, M. Maranghi. 2019. Lack of association between obesity and aggressiveness of differentiated thyroid cancer. *Journal of Endocrinological Investigation* **42**:1, 85-90. [Crossref]

644. Ligia J. Dominguez, Mario Barbagallo. Thyroid Disorders in Old Age . [Crossref]

645. Luca Giovanella, Giorgio Treglia, Pierpaolo Trimboli. Thyroid Imaging 545-564. [Crossref]

646. Ari J. Wassner. Thyroid Tumors in Children 327-334. [Crossref]

647. Amita Mahajan, Sana A. Ghaznavi, Kirstie Lithgow, Ralf Paschke. Toxic Multinodular Goiter 730-736. [Crossref]

648. Ralf Schmidmaier, Felix Röpcke. Endokrinologie 47-131. [Crossref]

649. Hakim-Moulay Dehbi, Ujjal Mallick, Jonathan Wadsley, Kate Newbold, Clive Harmer, Allan Hackshaw. 2019. Recurrence after low-dose radioiodine ablation and recombinant human thyroid-stimulating hormone for differentiated thyroid cancer (HiLo): long-term results of an open-label, non-inferiority randomised controlled trial. *The Lancet Diabetes & Endocrinology* **7**:1, 44-51. [Crossref]

650. R Michael Tuttle. 2019. Distinguishing remnant ablation from adjuvant treatment in differentiated thyroid cancer. *The Lancet Diabetes & Endocrinology* **7**:1, 7-8. [Crossref]

651. Fábio Muradás Girardi, Laura Mezzomo da Silva, Cecilia Dias Flores. 2019. A predictive model to distinguish malignant and benign thyroid nodules based on age, gender and ultrasonographic features. *Brazilian Journal of Otorhinolaryngology* **85**:1, 24-31. [Crossref]

652. Isabela de Oliveira Amui, José Vicente Tagliarini, Emanuel C. Castilho, Mariângela de Alencar Marques, Yoshio Kiy, José Eduardo Corrente, Gláucia M.F.S. Mazeto. 2019. The first postoperative-stimulated serum thyroglobulin is a prognostic factor for thyroid microcarcinomas. *Brazilian Journal of Otorhinolaryngology* **85**:1, 37-42. [Crossref]

653. Julia Isabelle Staubitz, Arno Schad, Erik Springer, Krishnaraj Rajalingam, Hauke Lang, Wilfried Roth, Nils Hartmann, Thomas Johannes Musholt. 2019. Novel rearrangements involving the RET gene in papillary thyroid carcinoma. *Cancer Genetics* **230**, 13-20. [Crossref]

654. Antonin Prochazka, Sumeet Gulati, Stepan Holinka, Daniel Smutek. 2019. Patch-based classification of thyroid nodules in ultrasound images using direction independent features extracted by two-threshold binary decomposition. *Computerized Medical Imaging and Graphics* **71**, 9-18. [Crossref]

655. Ke Zhang, Jianqiu Liu, Cuilin Li, Xiaowei Peng, Hui Li, Zhi Li. 2019. Identification and validation of potential target genes in papillary thyroid cancer. *European Journal of Pharmacology* **843**, 217-225. [Crossref]

Downloaded by Memorial Sloan Kettering from www.liebertpub.com at 08/14/19. For personal use only.

656. Zhiyu Pang, Myles Margolis, Ravi J. Menezes, Hassaan Maan, Sangeet Ghai. 2019. Diagnostic performance of 2015 American Thyroid Association guidelines and inter-observer variability in assigning risk category. *European Journal of Radiology Open* **6**, 122-127. [Crossref]

657. Andrea Cruz Ferraz de Oliveira, Camila Destefani, Louise De Brot, Débora Lacerda, Flavio Alexandre Moreira, Clovis Pinto, Demian Travesso, Mauricio Amoedo, Luiz Paulo Kowalski, Ricardo Pastorello, Mauro Ajaj Saieg. 2019. The usefulness of fine-needle aspirates for detection of recurrent carcinoma in the thyroid bed. *Journal of the American Society of Cytopathology* **8**:1, 34-38. [Crossref]

658. Michiya Nishino. 2019. How is noninvasive follicular thyroid neoplasm with papillary-like nuclear features (NIFTP) shaping the way we interpret thyroid cytology?. *Journal of the American Society of Cytopathology* **8**:1, 1-4. [Crossref]

659. Hanung Adi Nugroho, Zulfanahri, Eka Legya Frannita, Igi Ardiyanto, Lina Choridah. 2019. Computer aided diagnosis for thyroid cancer system based on internal and external characteristics. *Journal of King Saud University - Computer and Information Sciences* . [Crossref]

660. Syarifah N. Al-Yahya, Rohaizak Muhammad, Shahrun N.A. Suhaimi, Mawaddah Azman, Abdullah S. Mohamed, Marina M. Baki. 2019. Selective Laryngeal Examination: Sensitivity of Endocrine Surgeons in Screening Voice Abnormality. *Journal of Voice* . [Crossref]

661. Teck K. Khoo. 2019. Ethanol Ablation of Cystic Thyroid Nodules. *Mayo Clinic Proceedings* **94**:1, 171. [Crossref]

662. Katherine D. Gray, Sahar Bannani, Cécile Caillard, Sonia Amanat, Timothy M. Ullmann, Pavel Romanov, Laurent Brunaud, Toni Beninato, Thomas J. Fahey, Eric Mirallie, Rasa Zarnegar. 2019. High-dose radioactive iodine therapy is associated with decreased risk of recurrence in high-risk papillary thyroid cancer. *Surgery* **165**:1, 37-43. [Crossref]

663. Veljko Strajina, Benzon M. Dy, Travis J. McKenzie, Zahraa Al-Hilli, Robert A. Lee, Mabel Ryder, David R. Farley, Geoffrey B. Thompson, Melanie L. Lyden. 2019. Treatment of lateral neck papillary thyroid carcinoma recurrence after selective lateral neck dissection. *Surgery* **165**:1, 31-36. [Crossref]

664. Beatriz de Rienzo-Madero, John P Sabra, Elise Gand, Gianluca Donatini, Jean-Louis Kraimps. 2019. Unilateral benign multinodular versus solitary goiter: Long-term contralateral reoperation rates after lobectomy. *Surgery* **165**:1, 75-79. [Crossref]

665. Nathalie Chereau, Tristan Greilsamer, Eric Mirallié, Samira M. Sadowski, Marc Pusztaszeri, Frederic Triponez, Grégory Baud, Francois Pattou, Niki Christou, Muriel Mathonnet, Laurent Brunaud, Nicolas Santucci, Pierre Goudet, Carole Guérin, Frédéric Sebag, Gianluca Donatini, Jean-Louis Kraimps, Frédérique Tissier, Charlotte Lussey-Lepoutre, Laurence Leenhardt, Fabrice Menegaux. 2019. NIFT-P: Are they indolent tumors? Results of a multi-institutional study. *Surgery* **165**:1, 12-16. [Crossref]

666. Danilea M Carmona Matos, Samuel Jang, Baraa Hijaz, Alex W Chang, Ricardo V Lloyd, Herbert Chen, Renata Jaskula-Sztul. 2019. Characterization of somatostatin receptors (SSTRs) expression and antiproliferative effect of somatostatin analogues in aggressive thyroid cancers. *Surgery* **165**:1, 64-68. [Crossref]

667. Brian H.H. Lang, Carlos K.H. Wong, Estella P.M. Ma, Yu-Cho Woo, Keith Wan-Hang Chiu. 2019. A propensity-matched analysis of clinical outcomes between open thyroid lobectomy and high-intensity focused ultrasound (HIFU) ablation of benign thyroid nodules. *Surgery* **165**:1, 85-91. [Crossref]

668. Akira Miyauchi, Takumi Kudo, Yasuhiro Ito, Hitomi Oda, Masatoshi Yamamoto, Hisanori Sasai, Takuya Higashiyama, Hiroo Masuoka, Mitsuhiro Fukushima, Minoru Kihara, Akihiro Miya. 2019. Natural history of papillary thyroid microcarcinoma: Kinetic analyses on tumor volume during active surveillance and before presentation. *Surgery* **165**:1, 25-30. [Crossref]

669. Yi-Hsuan Lin, Yuan-Chun Tsai, Kun Ju Lin, Jen- Der Lin, Chih-Ching Wang, Szu-Tah Chen. 2019. Computer-Aided Diagnostic Technique in 2-Deoxy-2-[18F]fluoro-D-glucose-Positive Thyroid Nodule: Clinical Experience of 74 Non-thyroid Cancer Patients. *Ultrasound in Medicine & Biology* **45**:1, 108-121. [Crossref]

670. Enrico Papini, Claudio Maurizio Pacella, Luigi Alessandro Solbiati, Gaetano Achille, Daniele Barbaro, Stella Bernardi, Vito Cantisani, Roberto Cesareo, Arturo Chiti, Luca Cozzaglio, Anna Crescenzi, Francesco De Cobelli, Maurilio Deandrea, Laura Fugazzola, Giovanni Gambelunghe, Roberto Garberoglio, Gioacchino Giugliano, Livio Luzi, Roberto Negro, Luca Persani, Bruno Raggiunti, Francesco Sardanelli, Ettore Seregni, Martina Sollini, Stefano Spiezia, Fulvio Stacul, Dominique Van Doorne, Luca Maria Sconfienza, Giovanni Mauri. 2019. Minimally-invasive treatments for benign thyroid nodules: a Delphi-based consensus statement from the Italian minimally-invasive treatments of the thyroid (MITT) group. *International Journal of Hyperthermia* **36**:1, 376-382. [Crossref]

671. Jianming Li, Yujiang Liu, Jibin Liu, Peipei Yang, Xiangdong Hu, Linxue Qian. 2019. A comparative study of short-term efficacy and safety for thyroid micropapillary carcinoma patients after microwave ablation or surgery. *International Journal of Hyperthermia* **36**:1, 640-646. [Crossref]

Downloaded by Memorial Sloan Kettering from www.liebertpub.com at 08/14/19. For personal use only.

672. Daniel N Johnson, Allison B Cavallo, Imran Uraizee, Kevin Tanager, Ricardo R Lastra, Tatjana Antic, Nicole A Cipriani. 2019. A Proposal for Separation of Nuclear Atypia and Architectural Atypia in Bethesda Category III (AUS/FLUS) Based on Differing Rates of Thyroid Malignancy. *American Journal of Clinical Pathology* **151**:1, 86-94. [Crossref]

673. Robert J. Amdur, Roi Dagan. 2019. The University of Florida Department of Radiation Oncology Guidelines for Treatment of Differentiated Thyroid Cancer With I-131 or External-beam Radiotherapy. *American Journal of Clinical Oncology* **42**:1, 92-98. [Crossref]

674. Yan Shen, Miao Liu, Jie He, Shu Wu, Yong-Lin Wan, Jun Ding, Xiao-Yan Cai, Xiao-Hong Fu. 2019. Differences in treatment outcomes between ultrasound-guided percutaneous microwave ablation and endoscopic thyroidectomy for patients with papillary thyroid microcarcinoma. *Medicine* **98**:1, e13953. [Crossref]

675. Jian-Biao Wang, Ya-Yu Sun, Liu-Hong Shi, Lei Xie. 2019. Predictive factors for non-small-volume central lymph node metastases (more than 5 or ≥ 2mm) in clinically node-negative papillary thyroid carcinoma. *Medicine* **98**:1, e14028. [Crossref]

676. Shu Liu, Yanru Zhao, Miaojing Li, Jieying Xi, Bingyin Shi, Huachao Zhu. 2019. Simultaneous Hodgkin lymphoma and BRAFV600E-positive papillary thyroid carcinoma. *Medicine* **98**:3, e14180. [Crossref]

677. Guohua Shen, Ying Kou, Bin Liu, Rui Huang, Anren Kuang. 2019. The BRAFV600E mutation in papillary thyroid microcarcinoma with intermediate-risk to high-risk features. *Nuclear Medicine Communications* **40**:1, 8-13. [Crossref]

678. Zeming Liu, Wen Zeng, Yusufu Maimaiti, Jie Ming, Yawen Guo, Yan Liu, Chunping Liu, Tao Huang. 2019. High Expression of Yes-activated Protein-1 in Papillary Thyroid Carcinoma Correlates With Poor Prognosis. *Applied Immunohistochemistry & Molecular Morphology* **27**:1, 59-64. [Crossref]

679. Anca M. Avram, Natalja Rosculet, Nazanene H. Esfandiari, Paul G. Gauger, Barbra S. Miller, Mark Cohen, David T. Hughes. 2019. Differentiated Thyroid Cancer Outcomes After Surgery and Activity-Adjusted 131I Theragnostics. *Clinical Nuclear Medicine* **44**:1, 11-20. [Crossref]

680. Youjin Lee, Byung-Ho Yoon, Seeyoun Lee, Youn Kyung Chung, Young-Kyun Lee. 2019. Risk of Osteoporotic Fractures after Thyroid-stimulating Hormone Suppression Therapy in Patients with Thyroid Cancer. *Journal of Bone Metabolism* **26**:1, 45. [Crossref]

681. Ki-Wook Chung, Dong Eun Song. 2019. Borderline Thyroid Tumors: a Surgeon's Perspectives. *International Journal of Thyroidology* **12**:1, 15. [Crossref]

682. Ohjoon Kwon, Sohee Lee, Ja Seong Bae. 2019. The Prognostic Value of Central Lymph Node Yield and Ratio in Papillary Thyroid Carcinoma Patients Who Underwent Thyroidectomy with Prophylactic Central Compartment Neck Dissection. *International Journal of Thyroidology* **12**:1, 19. [Crossref]

683. Won Sang Yoo, Hoon Sung Choi. 2019. Ultrasonographic Characteristics of the Hyperfunctioning Thyroid Nodule and Predictive Factors for Thyroid Stimulating Hormone Suppression. *International Journal of Thyroidology* **12**:1, 35. [Crossref]

684. Hyeung Kyoo Kim, Euy Young Soh. 2019. Molecular Testing of Thyroid Indeterminate Nodules for Clinical Management Decision. *International Journal of Thyroidology* **12**:1, 9. [Crossref]

685. Ana Creo, Fares Alahdab, Alaa Al Nofal, Kristen Thomas, Amy Kolbe, Siobhan Pittock. 2019. Diagnostic accuracy of the McGill thyroid nodule score in paediatric patients. *Clinical Endocrinology* **90**:1, 200-207. [Crossref]

686. B. Bode-Lesniewska, B. Cochand-Priollet, P. Straccia, G. Fadda, M. Bongiovanni. 2019. Management of thyroid cytological material, preanalytical procedures and bio-banking. *Cytopathology* **30**:1, 7-16. [Crossref]

687. George H. Sakorafas, Andreas Koureas, Iliana Mpampali, Dimitrios Balalis, Dimitrios Nasikas, Sotirios Ganztzoulas. 2019. Patterns of Lymph Node Metastasis in Differentiated Thyroid Cancer; Clinical Implications with Particular Emphasis on the Emerging Role of Compartment-Oriented Lymph Node Dissection. *Oncology Research and Treatment* **42**:3, 143-147. [Crossref]

688. Craig A. Bollig, Jeffrey B. Jorgensen, Robert P. Zitsch, Laura M. Dooley. 2019. Utility of Intraoperative Frozen Section in Large Thyroid Nodules. *Otolaryngology–Head and Neck Surgery* **160**:1, 49-56. [Crossref]

689. Antonin Prochazka, Sumeet Gulati, Stepan Holinka, Daniel Smutek. 2019. Classification of Thyroid Nodules in Ultrasound Images Using Direction-Independent Features Extracted by Two-Threshold Binary Decomposition. *Technology in Cancer Research & Treatment* **18**, 153303381983074. [Crossref]

690. Tongtong Liu, Shichong Zhou, Jinhua Yu, Yi Guo, Yuanyuan Wang, Jin Zhou, Cai Chang. 2019. Prediction of Lymph Node Metastasis in Patients With Papillary Thyroid Carcinoma: A Radiomics Method Based on Preoperative Ultrasound Images. *Technology in Cancer Research & Treatment* **18**, 153303381983171. [Crossref]

691. Maureen Hatch, Alina V Brenner, Elizabeth K Cahoon, Vladimir Drozdovitch, Mark P Little, Tatiana Bogdanova, Victor Shpak, Elena Bolshova, Galyna Zamotayeva, Galyna Terekhova, Evgeniy Shelkovoy, Viktoria Klochkova, Kiyohiko Mabuchi, Mykola

Downloaded by Memorial Sloan Kettering from www.liebertpub.com at 08/14/19. For personal use only.

Tronko. 2019. Thyroid Cancer and Benign Nodules After Exposure In Utero to Fallout From Chernobyl. *The Journal of Clinical Endocrinology & Metabolism* **104**:1, 41-48. [Crossref]

692. Ali S Alzahrani, Meshael Alswailem, Yosra Moria, Reem Almutairi, Metib Alotaibi, Avaniyapuram Kannan Murugan, Ebtesam Qasem, Balgees Alghamdi, Hindi Al-Hindi. 2019. Lung Metastasis in Pediatric Thyroid Cancer: Radiological Pattern, Molecular Genetics, Response to Therapy, and Outcome. *The Journal of Clinical Endocrinology & Metabolism* **104**:1, 103-110. [Crossref]
693. Mariano Martín, Romina Celeste Geysels, Victoria Peyret, Carlos Eduardo Bernal Barquero, Ana María Masini-Repiso, Juan Pablo Nicola. 2019. Implications of Na+/I- Symporter Transport to the Plasma Membrane for Thyroid Hormonogenesis and Radioiodide Therapy. *Journal of the Endocrine Society* **3**:1, 222-234. [Crossref]
694. Brenessa M. Lindeman, Matthew A. Nehs, Trevor E. Angell, Erik K. Alexander, Atul A. Gawande, Francis D. Moore, Gerard M. Doherty, Nancy L. Cho. 2019. Effect of Noninvasive Follicular Thyroid Neoplasm with Papillary-Like Nuclear Features (NIFTP) on Malignancy Rates in Thyroid Nodules: How to Counsel Patients on Extent of Surgery. *Annals of Surgical Oncology* **26**:1, 93-97. [Crossref]
695. Federica Liotti, Nella Prevete, Giancarlo Vecchio, Rosa Marina Melillo. 2019. Recent advances in understanding immune phenotypes of thyroid carcinomas: prognostication and emerging therapies. *F1000Research* **8**, 227. [Crossref]
696. Seyfullah Kan, Muhammed Kizilgul, Bulent Celik, Selvihan Beysel, Mustafa Caliskan, Mahmut Apaydin, Bekir Ucan, Erman Cakal. 2019. The effect of disease activity on thyroid nodules in patients with acromegaly. *Endocrine Journal* **66**:4, 301-307. [Crossref]
697. Bruno Heidi Nozima, Thais Biude Mendes, Gustavo José da Silva Pereira, Rodrigo Pinheiro Araldi, Edna Sadayo Miazato Iwamura, Soraya Soubhi Smaili, Gianna Maria Griz Carvalheira, Janete Maria Cerutti. 2019. FAM129A regulates autophagy in thyroid carcinomas in an oncogene-dependent manner. *Endocrine-Related Cancer* **8**, 227-238. [Crossref]
698. Shin Dol Jo, Joon-Hyop Lee, Suk Ha Kang, Yun Yeong Kim, Yong Soon Chun, Heung Kyu Park, Sang Tae Choi, Jin Mo Kang, Yoo Seung Chung. 2019. Risk Factors for Distant Metastasis in Follicular Thyroid Carcinoma in Korea. *Journal of Endocrine Surgery* **19**:1, 1. [Crossref]
699. Jin-Woo Park, Ok-Jun Lee, Seung-Myoung Son, Chang-Gok Woo. 2019. Impact of Minimal Extrathyroidal Extension on Recurrence in Papillary Thyroid Carcinoma Measuring 4 cm or Less without Clinical Lymph Node Metastasis. *Journal of Endocrine Surgery* **19**:1, 11. [Crossref]
700. Carla Fernanda Nava, André B. Zanella, Rafael Selbach Scheffel, Ana Luiza Maia, Jose Miguel Dora. 2019. Impact of the updated TNM staging criteria on prediction of persistent disease in a differentiated thyroid carcinoma cohort. *Archives of Endocrinology and Metabolism* **63**:1, 5. [Crossref]
701. Ana Rafaela Lopes Reis Lima, Karoline Matias Morais de Medeiros, Conceição de Maria Ribeiro Veiga Parente, Adriana de Sá Caldas, Manuel dos Santos Faria, Marcelo Magalhães, Carla Souza Pereira Sobral. 2019. Does the Bethesda category predict aggressive features in differentiated thyroid cancer?. *Archives of Endocrinology and Metabolism* **63**:1, 12. [Crossref]
702. Denise Momesso. 2019. Clinical risk predictors for differentiated thyroid cancer management: what is new?. *Archives of Endocrinology and Metabolism* **63**:1, 2. [Crossref]
703. William D. Middleton, Sharlene A. Teefey. 2019. Reply to "Multiple Observers Are Needed for Guidelines Classification Comparison". *American Journal of Roentgenology* **212**:1, W24-W24. [Crossref]
704. Shui-Boon Soh, Tar-Choon Aw. 2019. Laboratory Testing in Thyroid Conditions - Pitfalls and Clinical Utility. *Annals of Laboratory Medicine* **39**:1, 3. [Crossref]
705. Sae Rom Chung, Jung Hwan Baek, Young Jun Choi, Tae-Yon Sung, Dong Eun Song, Tae Yong Kim, Jeong Hyun Lee. 2019. The Role of Core Needle Biopsy for the Evaluation of Thyroid Nodules with Suspicious Ultrasound Features. *Korean Journal of Radiology* **20**:1, 158. [Crossref]
706. Soo Yeon Hahn, Jung Hee Shin, Dong Gyu Na, Eun Joo Ha, Hye Shin Ahn, Hyun Kyung Lim, Jeong Hyun Lee, Jeong Seon Park, Ji-hoon Kim, Jin Yong Sung, Joon Hyung Lee, Jung Hwan Baek, Jung Hyun Yoon, Jung Suk Sim, Kwang Hwi Lee, Seon Mi Baek, So Lyung Jung, Yeo Koon Kim, Yoon Jung Choi. 2019. Ethanol Ablation of the Thyroid Nodules: 2018 Consensus Statement by the Korean Society of Thyroid Radiology. *Korean Journal of Radiology* **20**:4, 609. [Crossref]
707. Yossi Geron, Carlos Benbassat, Miriam Shteinshneider, Shlomit Koren, Keren Or, Efrat Markus, Dania Hirsch, Limor Muallem Kalmovich. 2019. Long-Term Outcome after Hemithyroidectomy for Papillary Thyroid Cancer: A Comparative Study and Review of the Literature. *Cancers* **11**:1, 26. [Crossref]
708. Luca Giovanella, Gaetano Paone, Teresa Ruberto, Luca Ceriani, Pierpaolo Trimboli. 2019. 99m Tc-Pertechnetate Scintigraphy Predicts Successful Postoperative Ablation in Differentiated Thyroid Carcinoma Patients Treated with Low Radioiodine Activities. *Endocrinology and Metabolism* **34**:1, 63. [Crossref]

Downloaded by Memorial Sloan Kettering from www.liebertpub.com at 08/14/19. For personal use only.

709. Jung Suk Sim, Jung Hwan Baek. 2019. Long-Term Outcomes Following Thermal Ablation of Benign Thyroid Nodules as an Alternative to Surgery: The Importance of Controlling Regrowth. *Endocrinology and Metabolism* **34**:2, 117. [Crossref]

710. Jae Hoon Moon, Steven R. Steinhubl. 2019. Digital Medicine in Thyroidology: A New Era of Managing Thyroid Disease. *Endocrinology and Metabolism* **34**:2, 124. [Crossref]

711. Myung-Chul Lee, Min Joo Kim, Hoon Sung Choi, Sun Wook Cho, Guk Haeng Lee, Young Joo Park, Do Joon Park. 2019. Postoperative Thyroid-Stimulating Hormone Levels Did Not Affect Recurrence after Thyroid Lobectomy in Patients with Papillary Thyroid Cancer. *Endocrinology and Metabolism* **34**:2, 150. [Crossref]

712. Kwan Ho Lee, Eun Young Seok, Eun Young Kim, Ji Sup Yun, Yong Lai Park, Chan Heun Park. 2019. Different prognostic values of individual hematologic parameters in papillary thyroid cancer due to age-related changes in immunity. *Annals of Surgical Treatment and Research* **96**:2, 70. [Crossref]

713. O. Mulla, K. Seejore, G.E. Gerrard, V.M. Gill, R.D. Murray. 2019. When Can We Discharge Differentiated Thyroid Cancer Patients Who Present With High-Risk Disease and Subsequently Have an Excellent Response to Treatment?. *Clinical Oncology* . [Crossref]

714. Kevin J. Kovatch, David Reyes-Gastelum, David T. Hughes, Ann S. Hamilton, Kevin C. Ward, Megan R. Haymart. 2019. Assessment of Voice Outcomes Following Surgery for Thyroid Cancer. *JAMA Otolaryngology–Head & Neck Surgery* . [Crossref]

715. Pablo Valderrabano, Julie E. Hallanger-Johnson, Ram Thapa, Xuefeng Wang, Bryan McIver. 2019. Comparison of Postmarketing Findings vs the Initial Clinical Validation Findings of a Thyroid Nodule Gene Expression Classifier. *JAMA Otolaryngology–Head & Neck Surgery* . [Crossref]

716. Alan A Parsa, Hossein Gharib. 2019. Update on Thyroid Nodule Management. *US Endocrinology* **15**:1, 32. [Crossref]

717. ShigaRappai Chirayath, PraveenV Pavithran, Nithya Abraham, Vasantha Nair, Nisha Bhavani, Harish Kumar, UshaV Menon, ArunS Menon. 2019. Prospective study of bethesda categories III and IV thyroid nodules: Outcomes and predictive value of BRAF V600E mutation. *Indian Journal of Endocrinology and Metabolism* **23**:3, 278. [Crossref]

718. Chae Moon Hong, Ju Hye Jeong, Seung Hyun Son, Chang-Hee Lee, Shin Young Jeong, Sang-Woo Lee, Jaetae Lee, Byeong-Cheol Ahn. 2019. Serum thyroglobulin elevation after needle aspiration of the lymph nodes. *Medicine* **98**:31, e16461. [Crossref]

719. Min Joo Kim, Seok-Mo Kim, Eun Kyung Lee, Yul Hwangbo, You Jin Lee, Sun Wook Cho, Do Joon Park, Yumi Lee, Young Joo Park. 2019. Tumor doubling time predicts response to sorafenib in radioactive iodine-refractory differentiated thyroid cancer. *Endocrine Journal* **66**:7, 597-604. [Crossref]

720. Petra Kühn. Palliative Chirurgie maligner Schilddrüsentumoren 275-293. [Crossref]

721. Stefano Gay, Eleonora Monti, Chiara Trambaiolo Antonelli, Marco Mora, Bruno Spina, Gianluca Ansaldo, Marsida Teliti, Martina Comina, Lucia Conte, Michele Minuto, Elisabetta Varaldo, Simonetta Zupo, Barbara Massa, Silvia Morbelli, Massimo Giusti. 2019. Case report: lenvatinib in neoadjuvant setting in a patient affected by invasive poorly differentiated thyroid carcinoma. *Future Oncology* . [Crossref]

722. Wan-Jun Zhao, Lin-Ru Fu, Zhi-Mian Huang, Jing-Qiang Zhu, Bu-Yun Ma. 2019. Effectiveness evaluation of computer-aided diagnosis system for the diagnosis of thyroid nodules on ultrasound. *Medicine* **98**:32, e16379. [Crossref]

723. Samuel J. Zolin, Talia Burneikis, Anatoliy V. Rudin, Rachel B. Shirley, Allan Siperstein. 2019. Analysis of a thyroid nodule care pathway: Opportunity to improve compliance and value of care. *Surgery* . [Crossref]

724. Federica Orsini, Federica Guidoccio, Giuliano Mariani. Radiopharmaceuticals for Therapy 99-116. [Crossref]

725. Federica Guidoccio, Gayane Aghakhanyan, Mariano Grosso. Hybrid Imaging and Radionuclide Therapy for Thyroid Disorders 707-747. [Crossref]

726. Jirat Chenbhanich, Amporn Atsawarungruangkit, Sira Korpaisarn, Tanit Phupitakphol, Soravis Osataphan, Prasit Phowthongkum. 2019. Prevalence of thyroid diseases in familial adenomatous polyposis: a systematic review and meta-analysis. *Familial Cancer* **18**:1, 53-62. [Crossref]

727. Stella Bernardi, Chiara Dobrinja, Anna Carere, Fabiola Giudici, Veronica Calabrò, Fabrizio Zanconati, Nicolò de Manzini, Bruno Fabris, Fulvio Stacul. 2018. Patient satisfaction after thyroid RFA versus surgery for benign thyroid nodules: a telephone survey. *International Journal of Hyperthermia* **35**:1, 150-158. [Crossref]

728. Brian H. H. Lang, Yu-Cho Woo, Keith Wan-Hang Chiu. 2018. Changes in serum thyroglobulin and antithyroglobulin shortly following high-intensity focused ablation of benign thyroid nodules in patients with positive antithyroglobulin status. *International Journal of Hyperthermia* **35**:1, 637-643. [Crossref]

729. Olga S. Serdyukova, Sergei E. Titov, Ekaterina S. Malakhina, Oksana D. Rymar. 2018. MicroRNAs – promising molecular markers for detecting cancer in thyroid nodules. *Clinical and experimental thyroidology* **14**:3, 140-148. [Crossref]

Downloaded by Memorial Sloan Kettering from www.liebertpub.com at 08/14/19. For personal use only.

730. Vera A. Kachko, Galina V. Semkina, Nadezhda M. Platonova, Vladimir E. Vanushko, Aleksandr Yu. Abrosimov. 2018. Diagnosis of thyroid neoplasms: state of the art on 2018. *Endocrine Surgery* **12**:3, 109-127. [Crossref]

731. Chen Wang, Hongcui Diao, Ping Ren, Xufu Wang, Yangang Wang, Wenjuan Zhao. 2018. Efficacy and Affecting Factors of 131I Thyroid Remnant Ablation After Surgical Treatment of Differentiated Thyroid Carcinoma. *Frontiers in Oncology* **8**. . [Crossref]

732. Brian Hh Lang, Yu-Cho Woo, Keith Wan-Hang Chiu. 2018. High intensity focused ultrasound (HIFU) ablation of benign thyroid nodule is safe and efficacious in patients who continue taking an anti-coagulation or anti-platelet agent in the treatment period. *International Journal of Hyperthermia* **33**, 1-5. [Crossref]

733. Alexander J. Lin, Pamela Samson, Todd DeWees, Lauren Henke, Thomas Baranski, Julie Schwarz, John Pfeifer, Perry Grigsby, Stephanie Markovina. 2018. A molecular approach combined with American Thyroid Association classification better stratifies recurrence risk of classic histology papillary thyroid cancer. *Cancer Medicine* **18**. . [Crossref]

734. Shuai Xue, Peisong Wang, Zachary A. Hurst, Yi Seok Chang, Guang Chen. 2018. Active Surveillance for Papillary Thyroid Microcarcinoma: Challenges and Prospects. *Frontiers in Endocrinology* **9**. . [Crossref]

735. Gilda Pontieri, Francesca Urselli, Livia Peschi, Alessia Liccardi, Anna Rita Ruggiero, Emilia Vergara, Claudio Bellevicine, Giancarlo Troncone, Maurizio De Palma, Bernadette Biondi. 2018. Is the Isthmus Location an Additional Risk Factor for Indeterminate Thyroid Nodules? Case Report and Review of the Literature. *Frontiers in Endocrinology* **9**. . [Crossref]

736. Ruijian Liu, Guihuang Jiang, Peng Gao, Guoming Li, Linghui Nie, Jianhao Yan, Min Jiang, Renpeng Duan, Yue Zhao, Jinxian Luo, Yi Yin, Cheng Li. 2018. Non-invasive Amide Proton Transfer Imaging and ZOOM Diffusion-Weighted Imaging in Differentiating Benign and Malignant Thyroid Micronodules. *Frontiers in Endocrinology* **9**. . [Crossref]

737. Jung Bum Choi, Seul Gi Lee, Min Jhi Kim, Tae Hyung Kim, Eun Jeong Ban, Cho Rok Lee, Jandee Lee, Sang-Wook Kang, Jong Ju Jeong, Kee-Hyun Nam, Woong Youn Chung, Cheong Soo Park. 2018. Oncologic outcomes in patients with 1-cm to 4-cm differentiated thyroid carcinoma according to extent of thyroidectomy. *Head & Neck* **21**. . [Crossref]

738. Susan J. Frank, Se Jin Ahn, Martin I. Surks. 2018. Virtual evaluation of selected cervical lymph nodes with three-dimensional ultrasound in thyroid cancer patients after thyroidectomy. *Head & Neck* **2**. . [Crossref]

739. Kennichi Kakudo, Andrey Bychkov, Yanhua Bai, Yaqiong Li, Zhiyan Liu, Chan Kwon Jung. 2018. The new 4th edition World Health Organization classification for thyroid tumors, Asian perspectives. *Pathology International* **39**. . [Crossref]

740. Yan Zhang, Ming-bo Zhang, Yu-kun Luo, Jie Li, Zhi-li Wang, Jie Tang. 2018. The Value of Peripheral Enhancement Pattern for Diagnosing Thyroid Cancer Using Contrast-Enhanced Ultrasound. *International Journal of Endocrinology* **2018**, 1-7. [Crossref]

741. Emerson Charles H.. 2018. Comprehensive Modeling of the Medical Literature Demonstrates Superior Cost Effectiveness and Quality of Life Using the 2015 Compared to the 2009 American Thyroid Association Guidelines for Managing Thyroid Nodules and Differentiated Thyroid Cancer. *Clinical Thyroidology* **30**:12, 546-550. [Citation] [Full Text] [PDF] [PDF Plus]

742. Livhits Masha J., Yeh Michael W.. 2018. Papillary Thyroid Cancer Recurrence in the Lateral Neck Can Be Treated with Surgery or Ethanol Ablation. *Clinical Thyroidology* **30**:12, 557-559. [Citation] [Full Text] [PDF] [PDF Plus]

743. Biermann Martin, Haugland Hans Kristian. 2018. Zirconium-89–Labeled Anti-Galectin-3 Antibodies Show Thyroid Cancer–Specific Uptake in Three Thyroid Cancer Cell Lines in an Orthotopic Mouse Model. *Clinical Thyroidology* **30**:12, 574-577. [Citation] [Full Text] [PDF] [PDF Plus]

744. Evranos Berna, Faki Sevgul, Polat Sefika Burcak, Bestepe Nagihan, Ersoy Reyhan, Cakir Bekir. 2018. Effects of Radioactive Iodine Therapy on Ovarian Reserve: A Prospective Pilot Study. *Thyroid* **28**:12, 1702-1707. [Abstract] [Full Text] [PDF] [PDF Plus]

745. Cipriani Nicole A., White Michael G., Angelos Peter, Grogan Raymon H.. 2018. Large Cytologically Benign Thyroid Nodules Do Not Have High Rates of Malignancy or False-Negative Rates and Clinical Observation Should be Considered: A Meta-Analysis. *Thyroid* **28**:12, 1595-1608. [Abstract] [Full Text] [PDF] [PDF Plus] [Supplementary Material]

746. Yu Chi Yun, Saeed Omar, Goldberg Alyse S., Farooq Shafaq, Fazelzad Rouhi, Goldstein David P., Tsang Richard W., Brierley James D., Ezzat Shereen, Thabane Lehana, Goldsmith Charlie H., Sawka Anna M.. 2018. A Systematic Review and Meta-Analysis of Subsequent Malignant Neoplasm Risk After Radioactive Iodine Treatment of Thyroid Cancer. *Thyroid* **28**:12, 1662-1673. [Abstract] [Full Text] [PDF] [PDF Plus] [Supplementary Material]

747. Santos Marcos Tadeu dos, Buzolin Ana Lígia, Gama Ricardo Ribeiro, Silva Eduardo Caetano Albino da, Dufloth Rozany Mucha, Figueiredo David Livingstone Alves, Carvalho André Lopes. 2018. Molecular Classification of Thyroid Nodules with Indeterminate Cytology: Development and Validation of a Highly Sensitive and Specific New miRNA-Based Classifier Test Using Fine-Needle Aspiration Smear Slides. *Thyroid* **28**:12, 1618-1626. [Abstract] [Full Text] [PDF] [PDF Plus] [Supplementary Material]

748. Oh Hye-Seon, Ha Jeonghoon, Kim Hye In, Kim Tae Hyuk, Kim Won Gu, Lim Dong-Jun, Kim Tae Yong, Kim Sun Wook, Kim Won Bae, Shong Young Kee, Chung Jae Hoon, Baek Jung Hwan. 2018. Active Surveillance of Low-Risk Papillary Thyroid Microcarcinoma: A Multi-Center Cohort Study in Korea. *Thyroid* **28**:12, 1587-1594. [Abstract] [Full Text] [PDF] [PDF Plus]

Downloaded by Memorial Sloan Kettering from www.liebertpub.com at 08/14/19. For personal use only.

749. Hedman Christel, Djärv Therese, Strang Peter, Lundgren Catharina Ihre. 2018. Fear of Recurrence and View of Life Affect Health-Related Quality of Life in Patients with Differentiated Thyroid Carcinoma: A Prospective Swedish Population-Based Study. *Thyroid* **28**:12, 1609-1617. [Abstract] [Full Text] [PDF] [PDF Plus]

750. Stang Michael T., Yip Linwah, Wharry Laura, Bartlett David L., McCoy Kelly L., Carty Sally E.. 2018. Gasless Transaxillary Endoscopic Thyroidectomy with Robotic Assistance: A High-Volume Experience in North America. *Thyroid* **28**:12, 1655-1661. [Abstract] [Full Text] [PDF] [PDF Plus] [Supplementary Material]

751. Vosler Peter S., Blumberg Jeffrey, Busato Gian M., Freeman Jeremy L.. 2018. Two Approaches to Conservative Neck Dissection: Anterior and Posterior Approaches to Level V. *VideoEndocrinology* **5**:4. . [Abstract] [Full Text] [PDF] [PDF Plus]

752. Tuttle R. Michael. 2018. Risk Stratification in Differentiated Thyroid Cancer: Importance and Clinical Implications of Preoperative Risk Stratification. *VideoEndocrinology* **5**:4. . [Abstract] [Full Text] [PDF] [PDF Plus]

753. Matthew L. Hung, James X. Wu, Ning Li, Masha J. Livhits, Michael W. Yeh. 2018. Association of Radioactive Iodine Administration After Reoperation With Outcomes Among Patients With Recurrent or Persistent Papillary Thyroid Cancer. *JAMA Surgery* **153**:12, 1098. [Crossref]

754. Martina Lombardi, Massimo Tonacchera, Enrico Macchia. 2018. A new case of Marine-Lenhart syndrome with a papillary thyroid carcinoma. *Clinical Case Reports* **6**:12, 2299-2302. [Crossref]

755. N. Möckelmann, A. Münscher. 2018. Neue Aspekte in der Therapie von Schilddrüsenkarzinomen. *HNO* **66**:12, 896-900. [Crossref]

756. Rui Qu, Jinyi Li, Jingge Yang, Peng Sun, Jian Gong, Cunchuan Wang. 2018. Treatment of differentiated thyroid cancer: can endoscopic thyroidectomy via a chest-breast approach achieve similar therapeutic effects as open surgery?. *Surgical Endoscopy* **32**:12, 4749-4756. [Crossref]

757. Roberto Vita, Antonio Ieni, Giovanni Tuccari, Salvatore Benvenga. 2018. The increasing prevalence of chronic lymphocytic thyroiditis in papillary microcarcinoma. *Reviews in Endocrine and Metabolic Disorders* **19**:4, 301-309. [Crossref]

758. Mark T. Macmillan, Michelle C. Williams. 2018. Incidental Non-cardiac Findings in Cardiovascular Imaging. *Current Treatment Options in Cardiovascular Medicine* **20**:12. . [Crossref]

759. Yingqiang Zhang, Chen Wang, Xin Zhang, Hui Li, Xin Li, Yansong Lin. 2018. 30mCi radioactive iodine achieving comparative excellent response in intermediate/high-risk nonmetastatic papillary thyroid cancer: a propensity score matching study. *Endocrine* **62**:3, 655-662. [Crossref]

760. Xiaotun Zhang, Joshua M. Howell, Yajue Huang. 2018. Cervical Lymph Node Fine-Needle Aspiration and Needle-Wash Thyroglobulin Reflex Test for Papillary Thyroid Carcinoma. *Endocrine Pathology* **29**:4, 346-350. [Crossref]

761. Reeree Lee, Young So, Yoo Sung Song, Won Woo Lee. 2018. Evaluation of Hot Nodules of Thyroid Gland Using Tc-99m Pertechnetate: a Novel Approach Using Quantitative Single-Photon Emission Computed Tomography/Computed Tomography. *Nuclear Medicine and Molecular Imaging* **52**:6, 468-472. [Crossref]

762. S. Mazzeo, R. Cervelli, R. Elisei, G. Tarantini, C. Cappelli, E. Molinaro, D. Galleri, L. De Napoli, C. Comite, R. Cioni, P. Vitti, D. Caramella. 2018. mRECIST criteria to assess recurrent thyroid carcinoma treatment response after radiofrequency ablation: a prospective study. *Journal of Endocrinological Investigation* **41**:12, 1389-1399. [Crossref]

763. T. Rago, V. Cantisani, F. Ianni, L. Chiovato, R. Garberoglio, C. Durante, A. Frasoldati, S. Spiezia, R. Farina, G. Vallone, A. Pontecorvi, P. Vitti. 2018. Thyroid ultrasonography reporting: consensus of Italian Thyroid Association (AIT), Italian Society of Endocrinology (SIE), Italian Society of Ultrasonography in Medicine and Biology (SIUMB) and Ultrasound Chapter of Italian Society of Medical Radiology (SIRM). *Journal of Endocrinological Investigation* **41**:12, 1435-1443. [Crossref]

764. M. C. Zatelli, L. Lamartina, D. Meringolo, E. Arvat, L. Damiani, G. Grani, A. Nervo, C. Durante, L. Giacomelli. 2018. Thyroid nodule recurrence following lobo-isthmectomy: incidence, patient's characteristics, and risk factors. *Journal of Endocrinological Investigation* **41**:12, 1469-1475. [Crossref]

765. Petros Perros. 2018. A decade of thyroidology. *Hormones* **17**:4, 491-495. [Crossref]

766. Xiangchun Li, Sheng Zhang, Qiang Zhang, Xi Wei, Yi Pan, Jing Zhao, Xiaojie Xin, Chunxin Qin, Xiaoqing Wang, Jianxin Li, Fan Yang, Yanhui Zhao, Meng Yang, Qinghua Wang, Zhiming Zheng, Xiangqian Zheng, Xiangming Yang, Christopher T Whitlow, Metin Nafi Gurcan, Lun Zhang, Xudong Wang, Boris C Pasche, Ming Gao, Wei Zhang, Kexin Chen. 2018. Diagnosis of thyroid cancer using deep convolutional neural network models applied to sonographic images: a retrospective, multicohort, diagnostic study. *The Lancet Oncology* . [Crossref]

767. Bernard Corvilain, Antoine Hamy, Laurent Brunaud, Françoise Borson-Chazot, Jacques Orgiazzi, Leila Bensalem Hachmi, Mourad Semrouni, Patrice Rodien, Charlotte Lussey-Lepoutre. 2018. Treatment of adult Graves' disease. *Annales d'Endocrinologie* **79**:6, 618-635. [Crossref]

Downloaded by Memorial Sloan Kettering from www.liebertpub.com at 08/14/19. For personal use only.

768. M. Doga, A.M. Formenti, S. Frara, M. Memo, A. Giustina, G. Mazziotti. 2018. Subclinical thyrotoxicosis and bone. *Current Opinion in Endocrine and Metabolic Research* **3**, 25-30. [Crossref]

769. Luis García Pascual, Maria Lluïsa Surralles, Xavier Morlius, Laia Garcia Cano, Clarisa González Mínguez. 2018. Prevalence and associated malignancy of Bethesda category III cytologies of thyroid nodules assigned to the "cytological atypia" or "architectural atypia" groups. *Endocrinología, Diabetes y Nutrición (English ed.)* **65**:10, 577-583. [Crossref]

770. Luis García Pascual, Maria Lluïsa Surralles, Xavier Morlius, Laia Garcia Cano, Clarisa González Mínguez. 2018. Prevalencia y malignidad asociada de las citologías de categoría Bethesda III de nódulos tiroideos según el grupo «atipia citológica» o «atipia arquitectónica». *Endocrinología, Diabetes y Nutrición* **65**:10, 577-583. [Crossref]

771. Sule Canberk, Diana Montezuma, Ebru Taştekin, Diana Grangeia, Mehmet Polat Demirhas, Meryem Akbas, Fatma Tokat, Umit Ince, Paula Soares, Fernando Schmitt. 2018. "The other side of the coin": understanding noninvasive follicular tumor with papillary-like nuclear features in Unifocal and multifocal settings. *Human Pathology* . [Crossref]

772. Salvatore Arena, Salvatore Benvenga. 2018. Gender-specific correlation of intranodular chronic lymphocytic thyroiditis with thyroid nodule size, echogenicity, and histologically-verified cytological class of malignancy risk. *Journal of Clinical & Translational Endocrinology* **14**, 39-45. [Crossref]

773. Yuqing Zong, Kai Li, Kuiran Dong, Wei Yao, Gongbao Liu, Xianmin Xiao. 2018. The surgical choice for unilateral thyroid carcinoma in pediatrics: Lobectomy or total thyroidectomy?. *Journal of Pediatric Surgery* **53**:12, 2449-2453. [Crossref]

774. Mijin Kim, Hye In Kim, Min Ji Jeon, Hee Kyung Kim, Eun Heui Kim, Hyon-Seung Yi, Eun Sook Kim, Hosu Kim, Bo Hyun Kim, Tae Yong Kim, Sun Wook Kim, Ho-Cheol Kang, Won Bae Kim, Jae Hoon Chung, Young Kee Shong, Tae Hyuk Kim, Won Gu Kim. 2018. Eighth edition of tumor-node-metastasis staging system improve survival predictability for papillary, but not follicular thyroid carcinoma: A multicenter cohort study. *Oral Oncology* **87**, 97-103. [Crossref]

775. Ho-Ryun Won, Jae Won Chang, Yea Eun Kang, Jae Yoon Kang, Bon Seok Koo. 2018. Optimal extent of lateral neck dissection for well-differentiated thyroid carcinoma with metastatic lateral neck lymph nodes: A systematic review and meta-analysis. *Oral Oncology* **87**, 117-125. [Crossref]

776. Yungang Sun, Jian Gong, Bin Guo, Jingjie Shang, Yong Cheng, Hao Xu. 2018. Association of adjuvant radioactive iodine therapy with survival in node-positive papillary thyroid cancer. *Oral Oncology* **87**, 152-157. [Crossref]

777. Sung Hoon Nam, Mi Rye Bae, Jong-Lyel Roh, Gyungyup Gong, Kyung-Ja Cho, Seung-Ho Choi, Soon Yuhl Nam, Sang Yoon Kim. 2018. A comparison of the 7th and 8th editions of the AJCC staging system in terms of predicting recurrence and survival in patients with papillary thyroid carcinoma. *Oral Oncology* **87**, 158-164. [Crossref]

778. Eric J. Kuo, James X. Wu, Kyle A. Zanocco. 2018. Cost effectiveness of immediate biopsy versus surveillance of intermediate-suspicion thyroid nodules. *Surgery* **164**:6, 1330-1335. [Crossref]

779. M. Shreyamsa, V. Sasi Mouli, Kul Ranjan Singh, Pooja Ramakant, Anand Kumar Mishra. 2018. Re: Cost effectiveness of immediate biopsy versus surveillance of intermediate-suspicion thyroid nodules. *Surgery* . [Crossref]

780. Rui Gao, Guang-Jian Zhang, Yuan-Bo Wang, Yan Liu, Fan Wang, Xi Jia, Yi-Qian Liang, Ai-Min Yang. 2018. Clinical Value of 99mTc-3PRGD2 SPECT/CT in Differentiated Thyroid Carcinoma with Negative 131I Whole-Body Scan and Elevated Thyroglobulin Level. *Scientific Reports* **8**:1. . [Crossref]

781. Min Liu, Lingxiao Cheng, Yuchen Jin, Maomei Ruan, Shiwei Sheng, Libo Chen. 2018. Predicting 131I-avidity of metastases from differentiated thyroid cancer using 18F-FDG PET/CT in postoperative patients with elevated thyroglobulin. *Scientific Reports* **8**:1. . [Crossref]

782. You-Bin Lee, Ji-Ye Kim, Haeyon Cho, Soo Yeon Hahn, Jung Hee Shin, Seung-Eun Lee, Ji Eun Jun, Sun Wook Kim, Jae Hoon Chung, Tae Hyuk Kim, Young Lyun Oh. 2018. Modified Bethesda system informing cytopathologic adequacy improves malignancy risk stratification in nodules considered benign or atypia(follicular lesion) of undetermined significance. *Scientific Reports* **8**:1. . [Crossref]

783. Shan Jin, Wuyuntu Bao, Yun-Tian Yang, Tala Bai, Yinbao Bai. 2018. Establishing a prediction model for lateral neck lymph node metastasis in patients with papillary thyroid carcinoma. *Scientific Reports* **8**:1. . [Crossref]

784. Felipe Albornoz-Castañeda, Gloria Díaz-Londoño, Marcia García-Arencibia, Gianina Sirandoni-Riquelme. 2018. Estimation of blood and bone marrow doses of thyroid carcinoma patients treated with 131 I through gamma spectrometry. *Journal of Radiological Protection* **38**:4, 1359-1370. [Crossref]

785. Krzysztof Kaliszewski, Dorota Diakowska, Marcin Ziętek, Bartłomiej Knychalski, Michał Aporowicz, Krzysztof Sutkowski, Beata Wojtczak. 2018. Thyroid incidentaloma as a "PAIN" phenomenon— does it always require surgery?. *Medicine* **97**:49, e13339. [Crossref]

786. Young Jae Ryu, Shin Jae Kang, Jin Seong Cho, Jung Han Yoon, Min Ho Park. 2018. Identifying risk factors of lateral lymph node recurrence in clinically node-negative papillary thyroid cancer. *Medicine* **97**:51, e13435. [Crossref]

Downloaded by Memorial Sloan Kettering from www.liebertpub.com at 08/14/19. For personal use only.

787. Brandon Spencer Jackson. 2018. Controversy regarding when clinically suspicious thyroid nodules should be subjected to surgery. *Medicine* **97**:50, e13634. [Crossref]

788. Luying Gao, Xuehua Xi, Juanjuan Wang, Xiao Yang, Ying Wang, Shenling Zhu, Xingjian Lai, Xiaoyan Zhang, Ruina Zhao, Bo Zhang. 2018. Ultrasound risk evaluation of thyroid nodules that are "unspecified" in the 2015 American Thyroid Association management guidelines. *Medicine* **97**:52, e13914. [Crossref]

789. Sen Wang, Chao Liang, Li Zhao, Zhaowei Meng, Chunmei Zhang, Qiang Jia, Jian Tan, Hui Yang, Xiangxiang Liu, Xiaoran Wang. 2018. Influence of radioactive iodine therapy on liver function in patients with differentiated thyroid cancer. *Nuclear Medicine Communications* **39**:12, 1113-1120. [Crossref]

790. Maria F. Villani, Armando Grossi, Bartolomeo Cassano, Milena Pizzoferro, Graziamaria Ubertini, Mariaconcetta Longo, Maria C. Garganese. 2018. Usefulness of iodine-123 whole-body scan in planning iodine-131 treatment of the differentiated thyroid carcinoma in children and adolescence. *Nuclear Medicine Communications* **39**:12, 1121-1128. [Crossref]

791. Yi-Ju Wu, Shun-Yu Chi, Ahmed Elsarawy, Yi-Chia Chan, Fong-Fu Chou, Yu-Cheng Lin, Sin-Yong Wee, Cheng-Chung Pan, Ben-Chung Cheng, Chih-Che Lin. 2018. What is the Appropriate Nodular Diameter in Thyroid Cancer for Extraction by Transoral Endoscopic Thyroidectomy Vestibular Approach Without Breaking the Specimens? A Surgicopathologic Study. *Surgical Laparoscopy, Endoscopy & Percutaneous Techniques* **28**:6, 390-393. [Crossref]

792. Rui Qu, Jianxue Wang, Jinyi Li, Zhiyong Dong, Jingge Yang, Daosheng Liu, Cunchuan Wang. 2018. The Learning Curve for Surgeons Regarding Endoscopic Thyroidectomy via the Oral-vestibular Approach. *Surgical Laparoscopy, Endoscopy & Percutaneous Techniques* **28**:6, 380-384. [Crossref]

793. Hong Kyu Kim, Hoon Yub Kim, Young Jun Chai, Gianlorenzo Dionigi, Eren Berber, Ralph P. Tufano. 2018. Transoral Robotic Thyroidectomy. *Surgical Laparoscopy, Endoscopy & Percutaneous Techniques* **28**:6, 404-409. [Crossref]

794. Sabri Özden, Sadettin Er, Mesut Tez. 2018. Clinical approach for molecular testing on thyroid fine needle aspirates. *Cytopathology* **29**:6, 598-598. [Crossref]

795. Ke Jiang, Junyi Zhou, Jianyong Lei, Ying Liu, Jinnan Li, Xueying Su, Zhihui Li, Tao Wei, Yong Jiang, Jingqiang Zhu. 2018. Cell block is a valuable adjunct to conventional smear for thyroid fine needle aspiration: 2395 cases with histological correlation. *Cytopathology* **29**:6, 525-530. [Crossref]

796. Ha Kyoung Park, Dong Wook Kim, Tae Kwun Ha, Young Jin Heo, Jin Wook Baek, Yoo Jin Lee, Young Jun Cho, Dong Kun Lee, Do Hun Kim, Soo Jin Jung, Ki Jung Ahn, Hye Shin Ahn, Hye Jin Baek. 2018. Utility of routine ultrasonography follow-up after total thyroidectomy in patients with papillary thyroid carcinoma: a single-center study. *BMC Medical Imaging* **18**:1. . [Crossref]

797. Brooke Nickel, Juan P. Brito, Ray Moynihan, Alexandra Barratt, Susan Jordan, Kirsten McCaffery. 2018. Patients' experiences of diagnosis and management of papillary thyroid microcarcinoma: a qualitative study. *BMC Cancer* **18**:1. . [Crossref]

798. Lei Jianyong, Li Zhihui, Gong Rixiang, Zhu Jingqiang. 2018. Using a nomogram based on preoperative serum fibrinogen levels to predict recurrence of papillary thyroid carcinoma. *BMC Cancer* **18**:1. . [Crossref]

799. Soo Young Kim, Seok-Mo Kim, Ho-Jin Chang, Bup-Woo Kim, Yong Sang Lee, Cheong Soo Park, Ki Cheong Park, Hang-Seok Chang. 2018. SoLAT (Sorafenib Lenvatinib alternating treatment): a new treatment protocol with alternating Sorafenib and Lenvatinib for refractory thyroid Cancer. *BMC Cancer* **18**:1. . [Crossref]

800. Wanying Chang, Lei Tang, Caiwei Lu, Min Wu, Man Chen. 2018. Shear wave elastography in the evaluation of level VI lymph nodes in papillary thyroid carcinoma: combined with gray-scale ultrasound ex vivo. *BMC Cancer* **18**:1. . [Crossref]

801. Jia Liu, Dongmei Zheng, Qiang Li, Xulei Tang, Zuojie Luo, Zhongshang Yuan, Ling Gao, Jiajun Zhao. 2018. A predictive model of thyroid malignancy using clinical, biochemical and sonographic parameters for patients in a multi-center setting. *BMC Endocrine Disorders* **18**:1. . [Crossref]

802. Ruihua Wang, Liu Yang, Shui Jin, Xingmin Han, Baoping Liu. 2018. Thyroid stimulating hormone suppression time on cardiac function of patients with differentiated thyroid carcinoma. *Cancer Cell International* **18**:1. . [Crossref]

803. George E. Naoum, Michael Morkos, Brian Kim, Waleed Arafat. 2018. Novel targeted therapies and immunotherapy for advanced thyroid cancers. *Molecular Cancer* **17**:1. . [Crossref]

804. Hiroshi Urakawa, Kenichi Nakanishi, Eisuke Arai, Kunihiro Ikuta, Shunsuke Hamada, Takehiro Ota, Naoki Ishiguro, Yoshihiro Nishida. 2018. Single metastasis of myxoid liposarcoma from the thigh to thyroid gland: a case report. *World Journal of Surgical Oncology* **16**:1. . [Crossref]

805. Young Jae Ryu, Jin Seong Cho, Jung Han Yoon, Min Ho Park. 2018. Identifying risk factors for recurrence of papillary thyroid cancer in patients who underwent modified radical neck dissection. *World Journal of Surgical Oncology* **16**:1. . [Crossref]

806. Jianlu Song, Shouxin Wu, Xiaotian Xia, Yu Wang, Youben Fan, Zhili Yang. 2018. Cell adhesion-related gene somatic mutations are enriched in aggressive papillary thyroid microcarcinomas. *Journal of Translational Medicine* **16**:1. . [Crossref]

Downloaded by Memorial Sloan Kettering from www.liebertpub.com at 08/14/19. For personal use only.

807. Christina Tugendsam, Veronika Petz, Wolfgang Buchinger, Brigitta Schmoll-Hauer, Iris Pia Schenk, Karin Rudolph, Michael Krebs, Georg Zettinig. 2018. Ultrasound criteria for risk stratification of thyroid nodules in the previously iodine deficient area of Austria - a single centre, retrospective analysis. *Thyroid Research* **11**:1. . [Crossref]

808. Eiman Alseddeeqi, Raqwana Baharoon, Rawia Mohamed, Jenan Ghaith, Abeer Al-Helali, Luai A. Ahmed. 2018. Thyroid malignancy among patients with thyroid nodules in the United Arab Emirates: a five-year retrospective tertiary Centre analysis. *Thyroid Research* **11**:1. . [Crossref]

809. Silvia Oddo, Margherita Balestra, Lara Vera, Massimo Giusti. 2018. Benign thyroid nodule unresponsive to radiofrequency ablation treated with laser ablation: a case report. *Journal of Medical Case Reports* **12**:1. . [Crossref]

810. Renaud Ciappuccini, Cédric Desmonts, Idlir Licaj, Cécile Blanc-Fournier, Stéphane Bardet, Nicolas Aide. 2018. Optimization of a dedicated protocol using a small-voxel PSF reconstruction for head-and-neck 18FDG PET/CT imaging in differentiated thyroid cancer. *EJNMMI Research* **8**:1. . [Crossref]

811. Priyanka C. Iyer, Ramona Dadu, Maria Gule-Monroe, Naifa L. Busaidy, Renata Ferrarotto, Mouhammed Amir Habra, Mark Zafereo, Michelle D. Williams, G. Brandon Gunn, Horiana Grosu, Heath D. Skinner, Erich M. Sturgis, Neil Gross, Maria E. Cabanillas. 2018. Salvage pembrolizumab added to kinase inhibitor therapy for the treatment of anaplastic thyroid carcinoma. *Journal for ImmunoTherapy of Cancer* **6**:1. . [Crossref]

812. D. S. Chan, K. Gong, M. G. Roskies, V. I. Forest, M. P. Hier, R. J. Payne. 2018. Re-visiting the ATA 2015 sonographic guidelines - who are we missing?: A retrospective review. *Journal of Otolaryngology - Head & Neck Surgery* **47**:1. . [Crossref]

813. Vincent L. Biron, Ashlee Matkin, Morris Kostiuk, Jordana Williams, David W. Cote, Jeffrey Harris, Hadi Seikaly, Daniel A. O'Connell. 2018. Analytic and clinical validity of thyroid nodule mutational profiling using droplet digital polymerase chain reaction. *Journal of Otolaryngology - Head & Neck Surgery* **47**:1. . [Crossref]

814. Oleksandr Butskiy, Brent A. Chang, Kimberly Luu, Robert M. McKenzie, Donald W. Anderson. 2018. A systematic approach to the recurrent laryngeal nerve dissection at the cricothyroid junction. *Journal of Otolaryngology - Head & Neck Surgery* **47**:1. . [Crossref]

815. Laurent Fradet, Rabia Temmar, Frédéric Couture, Mathieu Belzile, Pierre-Hugues Fortier, Robert Day. 2018. Evaluation of PACE4 isoforms as biomarkers in thyroid cancer. *Journal of Otolaryngology - Head & Neck Surgery* **47**:1. . [Crossref]

816. Bich-May Nguyen, Kenneth W. Lin, Ranit Mishori. 2018. Public health implications of overscreening for carotid artery stenosis, prediabetes, and thyroid cancer. *Public Health Reviews* **39**:1. . [Crossref]

817. Xieyi Zhang, Tetsuya Higuchi, Arifudin Achmad, Anu Bhattarai, Hiroyasu Tomonaga, Huong Nguyen Thu, Aiko Yamaguchi, Hiromi Hirasawa, Ayako Taketomi-Takahashi, Yoshito Tsushima. 2018. Can 18F-fluorodeoxyglucose positron emission tomography predict the response to radioactive iodine therapy in metastatic differentiated thyroid carcinoma?. *European Journal of Hybrid Imaging* **2**:1. . [Crossref]

818. Moran Amit, Mongkol Boonsripitayanon, Mark E. Zafereo. 2018. ASO Author Reflections: Strap Muscle Invasion Does Not Influence Recurrence and Survival in Patients with Differentiated Thyroid Cancer. *Annals of Surgical Oncology* **25**:S3, 892-893. [Crossref]

819. Naseem Eisa, Ahsan Khan, Mutaal Akhter, Molly Fensterwald, Saba Saleem, Ghaneh Fananapazir, Michael J. Campbell. 2018. Both Ultrasound Features and Nuclear Atypia are Associated with Malignancy in Thyroid Nodules with Atypia of Undetermined Significance. *Annals of Surgical Oncology* **25**:13, 3913-3918. [Crossref]

820. Huy Gia Vuong, Nguyen Phuoc Long, Nguyen Hoang Anh, Tran Diem Nghi, Mai Van Hieu, Le Phi Hung, Tadao Nakazawa, Ryohei Katoh, Tetsuo Kondo. 2018. Papillary thyroid carcinoma with tall cell features is as aggressive as tall cell variant: a meta-analysis. *Endocrine Connections* **12**, R286-R293. [Crossref]

821. Erika Urbano Lima, Ileana G S Rubio, Joaquim Custodio Da Silva, Ana Luiza Galrão, Danielle Pêssoa, Taise Cerqueira Oliveira, Fabiane Carrijo, Igor Silva Campos, Luciano Fonseca Espinheira, Luiz Jose Sampaio, Claudio Rogerio Lima, Janete Maria Cerutti, Helton Estrela Ramos. 2018. HOPX homeobox methylation in differentiated thyroid cancer and its clinical relevance. *Endocrine Connections* **23**, 1333-1342. [Crossref]

822. Iuri Martin Goemann, Vicente Rodrigues Marczyk, Mirian Romitti, Simone Magagnin Wajner, Ana Luiza Maia. 2018. Current concepts and challenges to unravel the role of iodothyronine deiodinases in human neoplasias. *Endocrine-Related Cancer* **25**:12, R625-R645. [Crossref]

823. William D. Middleton, Sharlene A. Teefey. 2018. Reply to "Nonclassifiable Nodules in Korean Society of Thyroid Radiology TIRADS and Size Threshold of Fine-Needle Aspiration". *American Journal of Roentgenology* **211**:6, W304-W304. [Crossref]

824. X. Chen, Q. Zhou, F. Wang, F. Zhang, H. Du, Q. Zhang, W. Wu, X. Gong. 2018. Value of BRAF V600E in High-Risk Thyroid Nodules with Benign Cytology Results. *American Journal of Neuroradiology* **39**:12, 2360-2365. [Crossref]

Downloaded by Memorial Sloan Kettering from www.liebertpub.com at 08/14/19. For personal use only.

825. Kyuryung Kim, Sora Jeon, Tae-Min Kim, Chan Kwon Jung. 2018. Immune Gene Signature Delineates a Subclass of Papillary Thyroid Cancer with Unfavorable Clinical Outcomes. *Cancers* **10**:12, 494. [Crossref]

826. Veronica Vella, Roberta Malaguarnera. 2018. The Emerging Role of Insulin Receptor Isoforms in Thyroid Cancer: Clinical Implications and New Perspectives. *International Journal of Molecular Sciences* **19**:12, 3814. [Crossref]

827. Xin Wu, Binglu Li, Chaoji Zheng, Xiaodong He. 2018. RISK FACTORS FOR CENTRAL LYMPH NODE METASTASES IN PATIENTS WITH PAPILLARY THYROID MICROCARCINOMA. *Endocrine Practice* **24**:12, 1057-1062. [Crossref]

828. Konstantinos Segkos, Kyle Porter, Leigha Senter, Matthew D. Ringel, Fadi A. Nabhan. 2018. Neck Ultrasound in Patients with Follicular Thyroid Carcinoma. *Hormones and Cancer* **9**:6, 433-439. [Crossref]

829. Renaud Ciappuccini, Corinne Jeanne, Stéphane Bardet. 2018. Incidental focal thyroid uptake on 18F-Choline PET-CT: need to rule out thyroid cancer. *Endocrine* **62**:3, 729-730. [Crossref]

830. Dengke Teng, Lei Ding, Yu Wang, Caimei Liu, Yongxu Xia, Hui Wang. 2018. Safety and efficiency of ultrasound-guided low power microwave ablation in the treatment of cervical metastatic lymph node from papillary thyroid carcinoma: a mean of 32 months follow-up study. *Endocrine* **62**:3, 648-654. [Crossref]

831. François-Marie Moussallieh, Miora Koloina Ranaivosoa, Sarah Romain, Nathalie Reix. 2018. Analytical validation of two second generation thyroglobulin immunoassays (Roche and Thermo Fisher). *Clinical Chemistry and Laboratory Medicine (CCLM)* **56**:12, e302-e305. [Crossref]

832. 2018. ##########. *Nippon Jibiinkoka Gakkai Kaiho* **121**:11, 1336-1344. [Crossref]

833. Haruhiko Yamazaki, Takeshi Kishida, Go Noguchi, Hiroyuki Iwasaki, Nobuyasu Suganuma, Katsuhiko Masudo, Hirotaka Nakayama, Toshinari Yamashita, Takashi Yamanaka, Yuko Sugawara, Yuka Matsubara, Kaori Kohagura, Yasushi Rino, Munetaka Masuda. 2018. Nephrectomy for Metastatic Kidney Tumor in Patients with Differentiated Thyroid Cancer: A Report of Two Cases. *Case Reports in Endocrinology* **2018**, 1-5. [Crossref]

834. M. M. Uygur, T. Yoldemir, D. G. Yavuz. 2018. Thyroid disease in the perimenopause and postmenopause period. *Climacteric* **21**:6, 542-548. [Crossref]

835. Biermann Martin. 2018. Low-Dose Radioiodine Ablation Is Equally Effective as High-Dose Ablation in Patients with Low-Risk Thyroid Cancer on Long-Term Follow-up. *Clinical Thyroidology* **30**:11, 511-515. [Citation] [Full Text] [PDF] [PDF Plus]

836. Carr Azadeh A., Yen Tina W.F., Ortiz Diana I., Hunt Bryan C., Fareau Gilbert, Massey Becky L., Campbell Bruce H., Doffek Kara L., Evans Douglas B., Wang Tracy S.. 2018. Patients with Oncocytic Variant Papillary Thyroid Carcinoma Have a Similar Prognosis to Matched Classical Papillary Thyroid Carcinoma Controls. *Thyroid* **28**:11, 1462-1467. [Abstract] [Full Text] [PDF] [PDF Plus]

837. Wu Che-Wei, Chiang Feng-Yu, Randolph Gregory W., Dionigi Gianlorenzo, Kim Hoon Yub, Lin Yi-Chu, Huang Tzu-Yen, Lin Chiao-I, Hun Pao-Chu, Kamani Dipti, Chang Pi-Ying, Lu I-Cheng. 2018. Transcutaneous Recording During Intraoperative Neuromonitoring in Thyroid Surgery. *Thyroid* **28**:11, 1500-1507. [Abstract] [Full Text] [PDF] [PDF Plus]

838. Wu Che-Wei, Chiang Feng-Yu, Randolph Gregory W., Dionigi Gianlorenzo, Kim Hoon Yub, Lin Yi-Chu, Chen Hui-Chun, Chen Hsiu-Ya, Kamani Dipti, Tsai Tsung-Yi, Lu I-Cheng, Chang Pi-Ying. 2018. Feasibility of Intraoperative Neuromonitoring During Thyroid Surgery Using Transcartilage Surface Recording Electrodes. *Thyroid* **28**:11, 1508-1516. [Abstract] [Full Text] [PDF] [PDF Plus]

839. Ha Eun Ju, Na Dong Gyu, Moon Won-Jin, Lee Young Hen, Choi Nami. 2018. Diagnostic Performance of Ultrasound-Based Risk-Stratification Systems for Thyroid Nodules: Comparison of the 2015 American Thyroid Association Guidelines with the 2016 Korean Thyroid Association/Korean Society of Thyroid Radiology and 2017 American College of Radiology Guidelines. *Thyroid* **28**:11, 1532-1537. [Abstract] [Full Text] [PDF] [PDF Plus] [Supplementary Material]

840. Kim Taek Min, Kim Ji-hoon, Yoo Roh-Eul, Kim Soo Chin, Chung Eun-Jae, Hong Eun Kyoung, Jo Sangwon, Kang Koung Mi, Choi Seung Hong, Sohn Chul-Ho, Rhim Jung Hyo, Park Sun-Won, Park Young Joo. 2018. Persistent/Recurrent Differentiated Thyroid Cancer: Clinical and Radiological Characteristics of Persistent Disease and Clinical Recurrence Based on Computed Tomography Analysis. *Thyroid* **28**:11, 1490-1499. [Abstract] [Full Text] [PDF] [PDF Plus]

841. Xin You, Yixin Zhao, Jing Sui, Xianbiao Shi, Yulu Sun, Jiahan Xu, Geyu Liang, Qingxiang Xu, Yongzhong Yao. 2018. Integrated analysis of long noncoding RNA interactions reveals the potential role in progression of human papillary thyroid cancer. *Cancer Medicine* **7**:11, 5394-5410. [Crossref]

842. Genpeng Li, Jianyong Lei, Linlin Song, Ke Jiang, Tao Wei, Zhihui Li, Rixiang Gong, Jingqiang Zhu. 2018. Radioiodine refractoriness score: A multivariable prediction model for postoperative radioiodine-refractory differentiated thyroid carcinomas. *Cancer Medicine* **7**:11, 5448-5456. [Crossref]

843. John S. Abele. 2018. Private practice outpatient fine needle aspiration clinic: A 2018 update. *Cancer Cytopathology* **126**:11, 902-923. [Crossref]

Downloaded by Memorial Sloan Kettering from www.liebertpub.com at 08/14/19. For personal use only.

844. Esther Diana Rossi, William C. Faquin. 2018. NIFTP revised: Chronicle of a change foretold. *Cancer Cytopathology* **126**:11, 897-901. [Crossref]

845. Ho Jin Son, Jeong Kyu Kim, Young Do Jung, Gyu Ho Jang, Youn Tae Seo, Deok Su Kim, Sung Hwan Park, Young Ju Jeong. 2018. Comparison of outcomes between hemithyroidectomy alone and hemithyroidectomy with elective unilateral central neck dissection in patients with papillary thyroid microcarcinoma. *Head & Neck* **40**:11, 2449-2454. [Crossref]

846. Ali Abbasian Ardakani, Reza Reiazi, Afshin Mohammadi. 2018. A Clinical Decision Support System Using Ultrasound Textures and Radiologic Features to Distinguish Metastasis From Tumor-Free Cervical Lymph Nodes in Patients With Papillary Thyroid Carcinoma. *Journal of Ultrasound in Medicine* **37**:11, 2527-2535. [Crossref]

847. Hye Shin Ahn, Mirinae Seo, Su Min Ha, Hee Sung Kim. 2018. Comparison of the Diagnostic Efficacy of Ultrasound-Guided Core Needle Biopsy With 18- Versus 20-Gauge Needles for Thyroid Nodules. *Journal of Ultrasound in Medicine* **37**:11, 2565-2574. [Crossref]

848. Elham Beheshtian, Sadaf Sahraian, David M. Yousem, Majid K. Khan. 2018. Incidental findings on cervical spine computed tomography scans: overlooked and unimportant?. *Neuroradiology* **60**:11, 1175-1180. [Crossref]

849. Sae Rom Chung, Chong Hyun Suh, Jung Hwan Baek, Young Jun Choi, Jeong Hyun Lee. 2018. The role of core needle biopsy in the diagnosis of initially detected thyroid nodules: a systematic review and meta-analysis. *European Radiology* **28**:11, 4909-4918. [Crossref]

850. Young Chan Lee, Ah Ra Jung, Yu-Mee Sohn, Eui-Jong Kim, Young-Gyu Eun. 2018. Ultrasonographic features associated with false-negative and false-positive results of extrathyroidal extensions in papillary thyroid microcarcinoma. *European Archives of Oto-Rhino-Laryngology* **275**:11, 2817-2822. [Crossref]

851. Karen Or, Carlos Benbassat, Shlomit Koren, Miriam Shteinshneider, Ronit Koren, Dror Cantrell, Esther Kummer, Limor Muallem Kalmovich. 2018. Adherence to ATA 2015 guidelines in the management of unifocal non-invasive papillary thyroid cancer: a clinical survey among endocrinologists and surgeons. *European Archives of Oto-Rhino-Laryngology* **275**:11, 2851-2859. [Crossref]

852. Marialuisa Sponziello, Gabriella Silvestri, Antonella Verrienti, Alessia Perna, Francesca Rosignolo, Chiara Brunelli, Valeria Pecce, Esther Diana Rossi, Celestino Pio Lombardi, Cosimo Durante, Sebastiano Filetti, Guido Fadda. 2018. A novel nonsense EIF1AX mutation identified in a thyroid nodule histologically diagnosed as oncocytic carcinoma. *Endocrine* **62**:2, 492-495. [Crossref]

853. Lei Zhang, Mingchun Wang. 2018. Growth Inhibitory Effect of Mangiferin on Thyroid Cancer Cell Line TPC1. *Biotechnology and Bioprocess Engineering* **23**:6, 649-654. [Crossref]

854. A. Campennì, R. M. Ruggeri, M. Siracusa, S. A. Pignata, F. Di Mauro, A. Vento, F. Trimarchi, S. Baldari. 2018. Combined BRAFV600E analysis and 99mTc-MIBI scintigraphy can be a useful diagnostic tool in differentiated thyroid cancer patients with incomplete bio-chemical response to first radioiodine therapy (RAIT): a pilot investigation. *Journal of Endocrinological Investigation* **41**:11, 1283-1288. [Crossref]

855. G. Sapuppo, M. Tavarelli, M. Russo, P. Malandrino, A. Belfiore, R. Vigneri, G. Pellegriti. 2018. Lymph node location is a risk factor for papillary thyroid cancer-related death. *Journal of Endocrinological Investigation* **41**:11, 1349-1353. [Crossref]

856. Adriana Gregory, Mahdi Bayat, Viksit Kumar, Max Denis, Bae Hyung Kim, Jeremy Webb, Duane D. Meixner, Mabel Ryder, John M. Knudsen, Shigao Chen, Mostafa Fatemi, Azra Alizad. 2018. Differentiation of Benign and Malignant Thyroid Nodules by Using Comb-push Ultrasound Shear Elastography. *Academic Radiology* **25**:11, 1388-1397. [Crossref]

857. Wuping Zheng, Jingtai Li, Pengfei Lv, Zhilin Chen, Pingming Fan. 2018. Treatment efficacy between total thyroidectomy and lobectomy for patients with papillary thyroid microcarcinoma: A systemic review and meta-analysis. *European Journal of Surgical Oncology* **44**:11, 1679-1684. [Crossref]

858. João Gonçalves Filho, Mark E. Zafereo, Faisal I. Ahmad, Iain J. Nixon, Ashok R. Shaha, Vincent Vander Poorten, Alvaro Sanabria, Avi Khafif Hefetz, K. Thomas Robbins, Dipti Kamani, Gregory W. Randolph, Andres Coca-Pelaz, Ricard Simo, Alessandra Rinaldo, Peter Angelos, Alfio Ferlito, Luiz P. Kowalski. 2018. Decision making for the central compartment in differentiated thyroid cancer. *European Journal of Surgical Oncology* **44**:11, 1671-1678. [Crossref]

859. Jianming Li, Jibin Liu, Xiaomeng Yu, Xiaoli Bao, Linxue Qian. 2018. BRAFv600e mutation combined with thyroglobulin and fine-needle aspiration in diagnosis of lymph node metastasis of papillary thyroid carcinoma. *Pathology - Research and Practice* **214**:11, 1892-1897. [Crossref]

860. Jie Chen, Xiao-Long Li, Chong-Ke Zhao, Dan Wang, Qiao Wang, Ming-Xu Li, Qing Wei, Guo Ji, Hui-Xiong Xu. 2018. Conventional Ultrasound, Immunohistochemical Factors and BRAFV600E Mutation in Predicting Central Cervical Lymph Node Metastasis of Papillary Thyroid Carcinoma. *Ultrasound in Medicine & Biology* **44**:11, 2296-2306. [Crossref]

861. Tracy S. Wang, Julie Ann Sosa. 2018. Thyroid surgery for differentiated thyroid cancer — recent advances and future directions. *Nature Reviews Endocrinology* **14**:11, 670-683. [Crossref]

Downloaded by Memorial Sloan Kettering from www.liebertpub.com at 08/14/19. For personal use only.

862. Konrad Patyra, Holger Jaeschke, Christoffer Löf, Meeri Jännäri, Suvi T. Ruohonen, Henriette Undeutsch, Moosa Khalil, Andreina Kero, Matti Poutanen, Jorma Toppari, Min Chen, Lee S. Weinstein, Ralf Paschke, Jukka Kero. 2018. Partial thyrocyte-specific Gα s deficiency leads to rapid-onset hypothyroidism, hyperplasia, and papillary thyroid carcinoma–like lesions in mice. *The FASEB Journal* **32**:11, 6239-6251. [Crossref]

863. Pedro W. Rosario, Tiara G. Rocha, Gabriela F. Mourão, Maria R. Calsolari. 2018. Is radioiodine scintigraphy still of value in thyroid nodules with indeterminate cytology?. *Nuclear Medicine Communications* **39**:11, 1059-1060. [Crossref]

864. Earl Abraham, Bryan Tran, David Roshan, Susannah Graham, Christopher Lehane, James Wykes, Peter Campbell, Ardalan Ebrahimi. 2018. Microscopic positive margins in papillary thyroid cancer do not impact disease recurrence. *ANZ Journal of Surgery* **88**:11, 1193-1197. [Crossref]

865. Dane Cole-Clark, Philip J. Townend, Anton Engelsman, Man-Shun Wong, Mark Sywak, Anthony Glover, Stan B. Sidhu. 2018. Impact of the American Thyroid Association guidelines on the Australian surgical management of papillary thyroid cancer. *ANZ Journal of Surgery* **88**:11, 1102-1103. [Crossref]

866. Pierpaolo Trimboli, Gaetano Paone, Giorgio Treglia, Camilla Virili, Teresa Ruberto, Luca Ceriani, Arnoldo Piccardo, Luca Giovanella. 2018. Fine-needle aspiration in all thyroid incidentalomas at 18 F-FDG PET/CT: Can EU-TIRADS revise the dogma?. *Clinical Endocrinology* **89**:5, 642-648. [Crossref]

867. Luis-Mauricio Hurtado-López, Alejandro Ordoñez-Rueda, Felipe-Rafael Zaldivar-Ramírez, Erich Basurto-Kuba. 2018. Regional Node Distribution in Papillary Thyroid Cancer with Microscopic Metastasis. *Journal of Thyroid Research* **2018**, 1-5. [Crossref]

868. CL Chng, HC Tan, CW Too, WY Lim, PPS Chiam, L Zhu, NV Nadkarni, AYY Lim. 2018. Diagnostic performance of ATA, BTA and TIRADS sonographic patterns in the prediction of malignancy in histologically proven thyroid nodules. *Singapore Medical Journal* 578-583. [Crossref]

869. Selvihan Beysel, Nilnur Eyerci, Ferda Alparslan Pinarli, Mahmut Apaydin, Muhammed Kizilgul, Mustafa Caliskan, Ozgur Ozcelik, Seyfullah Kan, Erman Cakal. 2018. VDR gene FokI polymorphism as a poor prognostic factor for papillary thyroid cancer. *Tumor Biology* **40**:11, 101042831881176. [Crossref]

870. Thomas E Pennington, May Thwin, Mark Sywak, Leigh Delbridge, Stan Sidhu. 2018. Sonographic Volumetric Assessment Is a More Accurate Measure Than Maximum Diameter Alone in Papillary Thyroid Cancer. *Journal of the Endocrine Society* **2**:11, 1284-1292. [Crossref]

871. Partha S Choudhury, Manoj Gupta. 2018. Differentiated thyroid cancer theranostics: radioiodine and beyond. *The British Journal of Radiology* **91**:1091, 20180136. [Crossref]

872. J Harvey Turner. 2018. An introduction to the clinical practice of theranostics in oncology. *The British Journal of Radiology* **91**:1091, 20180440. [Crossref]

873. Sora Jeon, Yourha Kim, Young Jeong, Ja Bae, Chan Jung. 2018. CCND1 Splice Variant as A Novel Diagnostic and Predictive Biomarker for Thyroid Cancer. *Cancers* **10**:11, 437. [Crossref]

874. Kwanhoon Jo, Dong-Jun Lim. 2018. Clinical implications of anti-thyroglobulin antibody measurement before surgery in thyroid cancer. *The Korean Journal of Internal Medicine* **33**:6, 1050-1057. [Crossref]

875. Christopher R. Kieliszak, Dustin J. Jones, Richard T. Klapchar, Ryan M. Collar, David L. Steward. 2018. Fine-Needle Aspiration Utilization for Malignant Thyroid Neoplasms in the Community Hospital Setting: A Quality Improvement Study. *The Journal of the American Osteopathic Association* **118**:11, 713. [Crossref]

876. Ludovico Maria Garau, Domenico Rubello, Alice Ferretti, Giuseppe Boni, Duccio Volterrani, Gianpiero Manca. 2018. Sentinel lymph node biopsy in small papillary thyroid cancer. A review on novel surgical techniques. *Endocrine* **62**:2, 340-350. [Crossref]

877. Anish Jacob Cherian, Siddhartha Chakravarthy, Noamaan Muhammed, Suchitra Chinadurai, Mahasampath Gowri, M. J. Paul, Deepak Thomas Abraham. 2018. Thyroidectomy Audit: Effects of Specialised, High Volume Work on Key Performance Indicators. *Indian Journal of Surgery* **115**. . [Crossref]

878. Rui Gao, Xi Jia, Ting Ji, Jinteng Feng, Aimin Yang, Guangjian Zhang. 2018. Management and Prognostic Factors for Thyroid Carcinoma Showing Thymus-Like Elements (CASTLE): A Case Series Study. *Frontiers in Oncology* **8**. . [Crossref]

879. Paolo Marzullo, Alessandro Minocci, Chiara Mele, Rezene Fessehatsion, Mariantonella Tagliaferri, Loredana Pagano, Massimo Scacchi, Gianluca Aimaretti, Alessandro Sartorio. 2018. The relationship between resting energy expenditure and thyroid hormones in response to short-term weight loss in severe obesity. *PLOS ONE* **13**:10, e0205293. [Crossref]

880. Yang Liu, Lin Li, Jie Yu, Yu-Xia Fan, Xiu-Bo Lu. 2018. Carbon nanoparticle lymph node tracer improves the outcomes of surgical treatment in papillary thyroid cancer. *Cancer Biomarkers* **23**:2, 227-233. [Crossref]

Downloaded by Memorial Sloan Kettering from www.liebertpub.com at 08/14/19. For personal use only.

881. Bo Hyun Kim, Seong Jang Kim, Mijin Kim, Sang-Woo Lee, Shin Young Jeong, Kyoungjune Pak, Keunyoung Kim, In Joo Kim. 2018. Diagnostic performance of HMGA2 gene expression for differentiation of malignant thyroid nodules: A systematic review and meta-analysis. *Clinical Endocrinology* **31**. . [Crossref]

882. David Viola, Laura Agate, Eleonora Molinaro, Valeria Bottici, Loredana Lorusso, Francesco Latrofa, Liborio Torregrossa, Laura Boldrini, Teresa Ramone, Paolo Vitti, Rossella Elisei. 2018. Lung Recurrence of Papillary Thyroid Cancer Diagnosed With Antithyroglobulin Antibodies After 10 Years From Initial Treatment. *Frontiers in Endocrinology* **9**. . [Crossref]

883. Hung-Chun Chen, Yu-Cheng Pei, Tuan-Jen Fang. 2018. Risk factors for thyroid surgery-related unilateral vocal fold paralysis. *The Laryngoscope* **8**. . [Crossref]

884. Kim Brian W.. 2018. Radioactive Iodine Therapy Is Associated with Clonal Hematopoiesis, a Precursor for Hematologic Malignancies. *Clinical Thyroidology* **30**:10, 443-446. [Citation] [Full Text] [PDF] [PDF Plus]

885. Fish Stephanie A.. 2018. Benign Nodules Show Little Change in Sonographic Appearance over Time. *Clinical Thyroidology* **30**:10, 476-479. [Citation] [Full Text] [PDF] [PDF Plus]

886. Orgiazzi Jacques. 2018. Thyroid Cancers with Nodules of Indeterminate Cytology Have a Specific Distribution of Histologic Types. *Clinical Thyroidology* **30**:10, 480-484. [Citation] [Full Text] [PDF] [PDF Plus]

887. Rago Teresa, Scutari Maria, Loiacono Valeria, Tonacchera Massimo, Scuotri Giuditta, Romani Rossana, Proietti Agnese, Piaggi Paolo, Elisei Rossella, Basolo Fulvio, Latrofa Francesco, Vitti Paolo. 2018. Patients with Indeterminate Thyroid Nodules at Cytology and Cancer at Histology Have a More Favorable Outcome Compared with Patients with Suspicious or Malignant Cytology. *Thyroid* **28**:10, 1318-1324. [Abstract] [Full Text] [PDF] [PDF Plus]

888. Llamas-Olier Augusto Enrique, Cuéllar Diana Isabel, Buitrago Giancarlo. 2018. Intermediate-Risk Papillary Thyroid Cancer: Risk Factors for Early Recurrence in Patients with Excellent Response to Initial Therapy. *Thyroid* **28**:10, 1311-1317. [Abstract] [Full Text] [PDF] [PDF Plus]

889. Brito Juan P., Moon Jae Hoon, Zeuren Rebecca, Kong Sung Hye, Kim Yeo Goon, Iñiguez-Ariza Nicole M., Choi June Young, Lee Kyu Eun, Kim Ji-hoon, Hargraves Ian, Bernet Victor, Montori Victor M., Park Young Joo, Tuttle R. Michael. 2018. Thyroid Cancer Treatment Choice: A Pilot Study of a Tool to Facilitate Conversations with Patients with Papillary Microcarcinomas Considering Treatment Options. *Thyroid* **28**:10, 1325-1331. [Abstract] [Full Text] [PDF] [PDF Plus] [Supplementary Material]

890. Ghaznavi Sana A., Ganly Ian, Shaha Ashok R., English Crystal, Wills Jonathan, Tuttle R. Michael. 2018. Using the American Thyroid Association Risk-Stratification System to Refine and Individualize the American Joint Committee on Cancer Eighth Edition Disease-Specific Survival Estimates in Differentiated Thyroid Cancer. *Thyroid* **28**:10, 1293-1300. [Abstract] [Full Text] [PDF] [PDF Plus]

891. Daniels Gilbert H.. 2018. Follicular Thyroid Carcinoma: A Perspective. *Thyroid* **28**:10, 1229-1242. [Citation] [Full Text] [PDF] [PDF Plus]

892. Brooke Nickel, Alexandra Barratt, Kevin McGeechan, Juan P. Brito, Ray Moynihan, Kirsten Howard, Kirsten McCaffery. 2018. Effect of a Change in Papillary Thyroid Cancer Terminology on Anxiety Levels and Treatment Preferences. *JAMA Otolaryngology–Head & Neck Surgery* **144**:10, 867. [Crossref]

893. Brooke Nickel, Kirsten Howard, Juan P. Brito, Alexandra Barratt, Ray Moynihan, Kirsten McCaffery. 2018. Association of Preferences for Papillary Thyroid Cancer Treatment With Disease Terminology. *JAMA Otolaryngology–Head & Neck Surgery* **144**:10, 887. [Crossref]

894. Ricardo G. Pastorello, Camila Destefani, Pedro H. Pinto, Caroline H. Credidio, Rafael X. Reis, Thiago de A. Rodrigues, Maryane C. de Toledo, Louise De Brot, Felipe de A. Costa, Antonio G. Nascimento, Clóvis A. L. Pinto, Mauro A. Saieg. 2018. The impact of rapid on-site evaluation on thyroid fine-needle aspiration biopsy: A 2-year cancer center institutional experience. *Cancer Cytopathology* **126**:10, 846-852. [Crossref]

895. Younghen Lee, Ji-hoon Kim, Jung Hwan Baek, So Lyung Jung, Sun-Won Park, Jinna Kim, Tae Jin Yun, Eun Ju Ha, Kyu Eun Lee, Soon Young Kwon, Kyung-Sook Yang, Dong Gyu Na. 2018. Value of CT added to ultrasonography for the diagnosis of lymph node metastasis in patients with thyroid cancer. *Head & Neck* **40**:10, 2137-2148. [Crossref]

896. Jin Soo A. Song, Nico Moolman, Steven Burrell, Murali Rajaraman, Martin Joseph Bullock, Jonathan Trites, S. Mark Taylor, Matthew H. Rigby, Robert D. Hart. 2018. Use of radioiodine-131 scan to measure influence of surgical discipline, practice, and volume on residual thyroid tissue after total thyroidectomy for differentiated thyroid carcinoma. *Head & Neck* **40**:10, 2129-2136. [Crossref]

897. Xiabin Lan, Jun Cao, Jiajie Xu, Chao Chen, Chuanming Zheng, Jiafeng Wang, Xuhang Zhu, Xin Zhu, Minghua Ge. 2018. Decreased expression of hsa_circ_0137287 predicts aggressive clinicopathologic characteristics in papillary thyroid carcinoma. *Journal of Clinical Laboratory Analysis* **32**:8, e22573. [Crossref]

Downloaded by Memorial Sloan Kettering from www.liebertpub.com at 08/14/19. For personal use only.

898. Samantha Epstein, Rachel McEachern, Rachita Khot, Shetal Padia, James T. Patrie, Jason N. Itri. 2018. Papillary Thyroid Carcinoma Recurrence: Low Yield of Neck Ultrasound With an Undetectable Serum Thyroglobulin Level. *Journal of Ultrasound in Medicine* **37**:10, 2325-2331. [Crossref]

899. Sarah Ogle, Alexa Merz, Ralitza Parina, Mahmoud Alsayed, Mira Milas. 2018. Ultrasound and the Evaluation of Pediatric Thyroid Malignancy: Current Recommendations for Diagnosis and Follow-up. *Journal of Ultrasound in Medicine* **37**:10, 2311-2324. [Crossref]

900. Emad Kandil, Khuzema Mohsin, Mohammad A. Murcy, Gregory W. Randolph. 2018. Continuous vagal monitoring value in prevention of vocal cord paralysis following thyroid surgery. *The Laryngoscope* **128**:10, 2429-2432. [Crossref]

901. Rick Schneider, Gregory W. Randolph, Gianlorenzo Dionigi, Che-Wei Wu, Marcin Barczynski, Feng-Yu Chiang, Zaid Al-Quaryshi, Peter Angelos, Katrin Brauckhoff, Claudio R. Cernea, John Chaplin, Jonathan Cheetham, Louise Davies, Peter E. Goretzki, Dana Hartl, Dipti Kamani, Emad Kandil, Natalia Kyriazidis, Whitney Liddy, Lisa Orloff, Joseph Scharpf, Jonathan Serpell, Jennifer J. Shin, Catherine F. Sinclair, Michael C. Singer, Samuel K. Snyder, Neil S. Tolley, Sam Van Slycke, Erivelto Volpi, Ian Witterick, Richard J. Wong, Gayle Woodson, Mark Zafereo, Henning Dralle. 2018. International neural monitoring study group guideline 2018 part I: Staging bilateral thyroid surgery with monitoring loss of signal. *The Laryngoscope* **128**, S1-S17. [Crossref]

902. Che-Wei Wu, Gianlorenzo Dionigi, Marcin Barczynski, Feng-Yu Chiang, Henning Dralle, Rick Schneider, Zaid Al-Quaryshi, Peter Angelos, Katrin Brauckhoff, Jennifer A. Brooks, Claudio R. Cernea, John Chaplin, Amy Y. Chen, Louise Davies, Gill R. Diercks, Quan Yang Duh, Christopher Fundakowski, Peter E. Goretzki, Nathan W. Hales, Dana Hartl, Dipti Kamani, Emad Kandil, Natalia Kyriazidis, Whitney Liddy, Akira Miyauchi, Lisa Orloff, Jeff C. Rastatter, Joseph Scharpf, Jonathan Serpell, Jennifer J. Shin, Catherine F. Sinclair, Brendan C. Stack, Neil S. Tolley, Sam Van Slycke, Samuel K. Snyder, Mark L. Urken, Erivelto Volpi, Ian Witterick, Richard J. Wong, Gayle Woodson, Mark Zafereo, Gregory W. Randolph. 2018. International neuromonitoring study group guidelines 2018: Part II: Optimal recurrent laryngeal nerve management for invasive thyroid cancer-incorporation of surgical, laryngeal, and neural electrophysiologic data. *The Laryngoscope* **128**, S18-S27. [Crossref]

903. Poupak Fallahi, Silvia Martina Ferrari, Gabriele Materazzi, Francesca Ragusa, Ilaria Ruffilli, Armando Patrizio, Paolo Miccoli, Alessandro Antonelli. 2018. Oral L-thyroxine liquid versus tablet in patients submitted to total thyroidectomy for thyroid cancer (without malabsorption): A prospective study. *Laryngoscope Investigative Otolaryngology* **3**:5, 405-408. [Crossref]

904. Jonathon O. Russell, Christopher R. Razavi, Mai G. Al Khadem, Michael Lopez, Sejal Saraf, Jason D. Prescott, Heather M. Starmer, Jeremy D. Richmon, Ralph P. Tufano. 2018. Anterior cervical incision-sparing thyroidectomy: Comparing retroauricular and transoral approaches. *Laryngoscope Investigative Otolaryngology* **3**:5, 409-414. [Crossref]

905. Tongtong Liu, Xifeng Ge, Jinhua Yu, Yi Guo, Yuanyuan Wang, Wenping Wang, Ligang Cui. 2018. Comparison of the application of B-mode and strain elastography ultrasound in the estimation of lymph node metastasis of papillary thyroid carcinoma based on a radiomics approach. *International Journal of Computer Assisted Radiology and Surgery* **13**:10, 1617-1627. [Crossref]

906. Maria Grazia Chiofalo, Raffaella D'Anna, Francesca Di Gennaro, Sergio Venanzio Setola, Vincenzo Marotta. 2018. Great veins invasion in follicular thyroid cancer: single-centre study assessing prevalence and clinical outcome. *Endocrine* **62**:1, 71-75. [Crossref]

907. Di Wu, Dorina Ylli, Cristiane J. Gomes Lima, Wen Lee, Kenneth D. Burman, Leonard Wartofsky, Douglas Van Nostrand. 2018. Use of 99mTc-sestamibi SPECT/CT when conventional imaging studies are negative for localizing suspected recurrence in differentiated thyroid cancer: a method and a lesson for clinical management. *Endocrine* **62**:1, 57-63. [Crossref]

908. María Luisa De Mingo Dominguez, Sonsoles Guadalix Iglesias, Cristina Martin-Arriscado Arroba, Begoña López Alvarez, Guillermo Martínez Diaz-Guerra, Jose Ignacio Martinez-Pueyo, Eduardo Ferrero Herrero, Federico Hawkins Carranza. 2018. Low trabecular bone score in postmenopausal women with differentiated thyroid carcinoma after long-term TSH suppressive therapy. *Endocrine* **62**:1, 166-173. [Crossref]

909. Jessica L. Gray, Gautam Singh, Lesley Uttley, Saba P. Balasubramanian. 2018. Routine thyroglobulin, neck ultrasound and physical examination in the routine follow up of patients with differentiated thyroid cancer—Where is the evidence?. *Endocrine* **62**:1, 26-33. [Crossref]

910. Sanjay Kalra, A. K. Das, Sarita Bajaj, Banshi Saboo, Deepak Khandelwal, Mangesh Tiwaskar, Navneet Agarwal, Pritam Gupta, Rakesh Sahay, Sameer Aggarwal, Sujoy Ghosh, Vijay Negalur, A. G. Unnikrishnan, Ganapathi Bantwal, Rashmi Aggarwal, Harshal Chaudhari, Nitin Mulgaonkar. 2018. Diagnosis and Management of Hypothyroidism: Addressing the Knowledge–Action Gaps. *Advances in Therapy* **35**:10, 1519-1534. [Crossref]

911. Jihyun Kim, Hyunjong Lee, Hwanhee Lee, Ji-In Bang, Yeon-koo Kang, Sungwoo Bae, Yoo Sung Song, Won Woo Lee. 2018. Quantitative Single-Photon Emission Computed Tomography/Computed Tomography for Evaluation of Salivary Gland Dysfunction in Sjögren's Syndrome Patients. *Nuclear Medicine and Molecular Imaging* **52**:5, 368-376. [Crossref]

Downloaded by Memorial Sloan Kettering from www.liebertpub.com at 08/14/19. For personal use only.

912. Alfredo Campennì, Salvatore Antonio Pignata, Sergio Baldari. 2018. Post-operative radioiodine therapy (RaIT) as adjuvant therapy in low–intermediate risk differentiated thyroid cancer. *Clinical and Translational Imaging* **6**:5, 347-355. [Crossref]

913. L. Conte, E. Monti, S. Gay, P. Marroni, A. Adorno, M. Mittica, M. Mussap, M. Giusti. 2018. Evaluation of adequacy of levo-thyroxine dosage in patients with differentiated thyroid carcinoma: correlation between morning and afternoon TSH determination. *Journal of Endocrinological Investigation* **41**:10, 1193-1197. [Crossref]

914. Natalia Malara, Nadia Innaro, Chiara Mignogna, Ivan Presta, Krizia Caterina Pirrone, Annalidia Donato, Vincenzo Gangemi, Rosario Sacco, Vincenzo Mollace, Giuseppe Donato. 2018. La biopsia liquida nella diagnosi del carcinoma tiroideo indifferenziato. *L'Endocrinologo* **19**:5, 270-272. [Crossref]

915. Antonio Calvo Cebrián, Alberto López García-Franco, Jorge Short Apellaniz. 2018. Modelo Point-of-Care Ultrasound en Atención Primaria: ¿herramienta de alta resolución?. *Atención Primaria* **50**:8, 500-508. [Crossref]

916. Aglaia Kyrilli, Maria Lytrivi, Pierre Bel Lassen, Bernard Corvilain. 2018. Treatment options of subclinical hyperthyroidism and cardiovascular risk. *Current Opinion in Endocrine and Metabolic Research* **2**, 38-45. [Crossref]

917. Kevin C. Choong, Amer Khiyami, Stephen W. Tamarkin, Christopher R. McHenry. 2018. Fine-needle aspiration biopsy of thyroid nodules: Is routine ultrasound-guidance necessary?. *Surgery* **164**:4, 789-794. [Crossref]

918. Xingjian Lai, Yan Jiang, Bo Zhang, Zhiyong Liang, Yuxin Jiang, Jianchu Li, Ruina Zhao, Xiao Yang, Xiaoyan Zhang. 2018. Preoperative sonographic features of follicular thyroid carcinoma predict biological behavior. *Medicine* **97**:41, e12814. [Crossref]

919. Luba Rakhlin, Stephanie Fish. 2018. Pregnancy as a risk factor for thyroid cancer progression. *Current Opinion in Endocrinology & Diabetes and Obesity* **25**:5, 326-329. [Crossref]

920. Allen S. Ho, Irene Chen, Michelle Melany, Wendy L. Sacks. 2018. Evolving management considerations in active surveillance for micropapillary thyroid carcinoma. *Current Opinion in Endocrinology & Diabetes and Obesity* **25**:5, 353-359. [Crossref]

921. Wolfgang Roll, Burkhard Riemann, Michael Schäfers, Lars Stegger, Alexis Vrachimis. 2018. 177Lu-DOTATATE Therapy in Radioiodine-refractory Differentiated Thyroid Cancer. *Clinical Nuclear Medicine* **43**:10, e346-e351. [Crossref]

922. Daqi Zhang, Qingfeng Fu, Gianlorenzo Dionigi, Tie Wang, Jingwei Xin, Jiao Zhang, Gaofeng Xue, Hongbo Li, Hui Sun. 2018. Intraoperative Neural Monitoring in Endoscopic Thyroidectomy Via Bilateral Areola Approach. *Surgical Laparoscopy, Endoscopy & Percutaneous Techniques* **28**:5, 303-308. [Crossref]

923. Daqi Zhang, Che-Wei Wu, Davide Inversini, Hoon Yub Kim, Angkoon Anuwong, Alessandro Bacuzzi, Gianlorenzo Dionigi. 2018. Lessons Learned From a Faulty Transoral Endoscopic Thyroidectomy Vestibular Approach. *Surgical Laparoscopy, Endoscopy & Percutaneous Techniques* **28**:5, e94-e99. [Crossref]

924. Miao-yun Long, Fei-yu Diao, Li-na Peng, Lang-ping Tan, Yue Zhu, Kai Huang, Hong-hao Li. 2018. Effect of neurological monitoring in postoperative 5-15 days residual thyroidectomy after primary thyroid cancer surgery. *Asia-Pacific Journal of Clinical Oncology* **14**:5, e332-e335. [Crossref]

925. I.J. Nixon, R.S. Simo, D. Kim. 2018. Refining definitions within low-risk differentiated thyroid cancers. *Clinical Otolaryngology* **43**:5, 1195-1200. [Crossref]

926. Steven C. Eberhardt, Marta E. Heilbrun. 2018. Radiology Report Value Equation. *RadioGraphics* **38**:6, 1888-1896. [Crossref]

927. Christopher R. Razavi, Elya Vasiliou, Ralph P. Tufano, Jonathon O. Russell. 2018. Learning Curve for Transoral Endoscopic Thyroid Lobectomy. *Otolaryngology–Head and Neck Surgery* **159**:4, 625-629. [Crossref]

928. Tania Jaber, Steven G Waguespack, Maria E Cabanillas, Mohamed Elbanan, Thinh Vu, Ramona Dadu, Steven I Sherman, Moran Amit, Elmer B Santos, Mark Zafereo, Naifa L Busaidy. 2018. Targeted Therapy in Advanced Thyroid Cancer to Resensitize Tumors to Radioactive Iodine. *The Journal of Clinical Endocrinology & Metabolism* **103**:10, 3698-3705. [Crossref]

929. Sarika N Rao, Maria E Cabanillas. 2018. Navigating Systemic Therapy in Advanced Thyroid Carcinoma: From Standard of Care to Personalized Therapy and Beyond. *Journal of the Endocrine Society* **2**:10, 1109-1130. [Crossref]

930. Christopher R. McHenry. 2018. Is Prophylactic Central Compartment Neck Dissection Indicated for Clinically Node-Negative Papillary Thyroid Cancer: The Answer is Dependent on How the Data are Interpreted and the Weight Given to the Risks and Benefits. *Annals of Surgical Oncology* **25**:11, 3123-3124. [Crossref]

931. Shu-Fu Lin, Jen-Der Lin, Chuen Hsueh, Ting-Chao Chou, Richard J Wong. 2018. Potent effects of roniciclib alone and with sorafenib against well-differentiated thyroid cancer. *Endocrine-Related Cancer* **25**:10, 853-864. [Crossref]

932. Ethem Turgay Cerit, Mehmet Muhittin Yalçin, Çiğdem Özkan, Müjde Aktürk, Alev Eroğlu Altinova, Ümit Özgür Akdemir, Murat Akin, Emre Arslan, Ayhan Karakoç, Ali Riza Çimen, Nuri Çakir. 2018. Guided intraoperative scintigraphic tumor targeting of metastatic cervical lymph nodes in patients with differentiated thyroid cancer: a single-center report. *Archives of Endocrinology and Metabolism* **62**:5, 495-500. [Crossref]

Downloaded by Memorial Sloan Kettering from www.liebertpub.com at 08/14/19. For personal use only.

933. Moran Amit, Mongkol Boonsripitayanon, Ryan P. Goepfert, Samantha Tam, Naifa L. Busaidy, Maria E. Cabanillas, Ramona Dadu, Jeena Varghese, Steven G. Waguespack, Neil D. Gross, Paul Graham, Michelle D. Williams, Erich M. Sturgis, Mark E. Zafereo. 2018. Extrathyroidal Extension: Does Strap Muscle Invasion Alone Influence Recurrence and Survival in Patients with Differentiated Thyroid Cancer?. *Annals of Surgical Oncology* **25**:11, 3380-3388. [Crossref]

934. Anca M. Avram, Yuni K. Dewaraja. 2018. Thyroid cancer radiotheragnostics: the case for activity adjusted 131I therapy. *Clinical and Translational Imaging* **6**:5, 335-346. [Crossref]

935. Oya Topaloğlu, Hüsniye Başer, Ayşegül Aksoy Altınboğa, Serap Ulusoy, Reyhan Ersoy, Bekir Çakır. 2018. The Evaluation of Clinicopathologic Features of Differentiated Thyroid Cancers. *Ankara Medical Journal* . [Crossref]

936. Magdalena Mileva, Bojana Stoilovska, Anamarija Jovanovska, Ana Ugrinska, Gordana Petrushevska, Slavica Kostadinova-Kunovska, Daniela Miladinova, Venjamin Majstorov. 2018. Thyroid cancer detection rate and associated risk factors in patients with thyroid nodules classified as Bethesda category III. *Radiology and Oncology* **52**:4, 370-376. [Crossref]

937. Renato Tozzoli, Nicola Bizzaro. 2018. Harmonization in autoimmune thyroid disease diagnostics. *Clinical Chemistry and Laboratory Medicine (CCLM)* **56**:10, 1778-1782. [Crossref]

938. Yong Bae Ji. 2018. Molecular Diagnosis of Thyroid Nodule. *Korean Journal of Otorhinolaryngology-Head and Neck Surgery* **61**:9, 445-452. [Crossref]

939. Fei Wang, Shihua Zhao, Xiaopei Shen, Guangwu Zhu, Rengyun Liu, David Viola, Rossella Elisei, Efisio Puxeddu, Laura Fugazzola, Carla Colombo, Barbara Jarzab, Agnieszka Czarniecka, Alfred K. Lam, Caterina Mian, Federica Vianello, Linwah Yip, Garcilaso Riesco-Eizaguirre, Pilar Santisteban, Christine J. O'Neill, Mark S. Sywak, Roderick Clifton-Bligh, Bela Bendlova, Vlasta Sýkorová, Yangang Wang, Mingzhao Xing. 2018. BRAF V600E Confers Male Sex Disease-Specific Mortality Risk in Patients With Papillary Thyroid Cancer. *Journal of Clinical Oncology* **36**:27, 2787-2795. [Crossref]

940. Claudio Casella, Silvia Ministrini, Alessandro Galani, Francesco Mastriale, Carlo Cappelli, Nazario Portolani. 2018. The New TNM Staging System for Thyroid Cancer and the Risk of Disease Downstaging. *Frontiers in Endocrinology* **9**. . [Crossref]

941. Nurdan Gül, Ayşe Kubat Üzüm, Özlem Soyluk Selçukbiricik, Gülçin Yegen, Refik Tanakol, Ferihan Aral. 2018. Prevalence of papillary thyroid cancer in subacute thyroiditis patients may be higher than it is presumed: retrospective analysis of 137 patients. *Radiology and Oncology* **52**:3, 257-262. [Crossref]

942. Yanhong Luo, Hua Zhu, Tao Tan, Jianfeng He. 2018. Current Standards and Recent Advances in Biomarkers of Major Endocrine Tumors. *Frontiers in Pharmacology* **9**. . [Crossref]

943. Sami P. Moubayed, Rosalie Machado, R. Michael Tuttle, Lisa A. Orloff, Gregory Randolph, Juan C. Hernandez-Prera, Martha J. Griffin, Mark L. Urken. 2018. Enhanced interdisciplinary communication: development of an interactive thyroid nodule/cancer disease map. *The Laryngoscope* **26**. . [Crossref]

944. Jan Krátký, Jana Ježková, Mikuláš Kosák, Hana Vítková, Jana Bartáková, Miloš Mráz, Jindřich Lukáš, Zdenka Límanová, Jan Jiskra. 2018. Positive Antithyroid Antibodies and Nonsuppressed TSH Are Associated with Thyroid Cancer: A Retrospective Cross-Sectional Study. *International Journal of Endocrinology* **2018**, 1-6. [Crossref]

945. Hye Jeong Kim, In Ho Choi, So-Young Jin, Hyeong Kyu Park, Dong Won Byun, Kyoil Suh, Myung Hi Yoo. 2018. Efficacy of Shear-Wave Elastography for Detecting Postoperative Cervical Lymph Node Metastasis in Papillary Thyroid Carcinoma. *International Journal of Endocrinology* **2018**, 1-6. [Crossref]

946. Jason Tasoulas, Gerasimos Tsourouflis, Stamatios Theocharis. 2018. Neovascularization: an attractive but tricky target in thyroid cancer. *Expert Opinion on Therapeutic Targets* **22**:9, 799-810. [Crossref]

947. Biermann Martin. 2018. Needle Biopsy of Thyroid Nodules Is Best Performed Using Capillary Action Techniques Rather than Suction. *Clinical Thyroidology* **30**:9, 418-421. [Citation] [Full Text] [PDF] [PDF Plus]

948. Kim Brian W.. 2018. Integrating AJCC-TNM, ATA-IRS, and Patient Age Improves Survival Predictions for Thyroid Cancer. *Clinical Thyroidology* **30**:9, 422-425. [Citation] [Full Text] [PDF] [PDF Plus]

949. Livhits Masha J., Yeh Michael W.. 2018. The American Thyroid Association Sonographic Classification System Can Stratify the Risk of Malignancy for Indeterminate Thyroid Nodules. *Clinical Thyroidology* **30**:9, 426-428. [Citation] [Full Text] [PDF] [PDF Plus]

950. Semrad Thomas J., Keegan Theresa H.M., Semrad Alison, Brunson Ann, Farwell D. Gregory. 2018. Predictors of Neck Reoperation and Mortality After Initial Total Thyroidectomy for Differentiated Thyroid Cancer. *Thyroid* **28**:9, 1143-1152. [Abstract] [Full Text] [PDF] [PDF Plus] [Supplementary Material]

951. Ma Ben, Wei Wenjun, Xu Weibo, Wang Yu, Guan Haixia, Fan Jingbin, Zhao Zhihong, Wen Duo, Yang Shuwen, Wang Yulong, Chang Bin, Ji Qinghai. 2018. Surgical Confirmation of Incomplete Treatment for Primary Papillary Thyroid Carcinoma by Percutaneous Thermal Ablation: A Retrospective Case Review and Literature Review. *Thyroid* **28**:9, 1134-1142. [Abstract] [Full Text] [PDF] [PDF Plus] [Supplementary Material]

Downloaded by Memorial Sloan Kettering from www.liebertpub.com at 08/14/19. For personal use only.

952. Van Nostrand Douglas. 2018. Radioiodine Refractory Differentiated Thyroid Cancer: Time to Update the Classifications. *Thyroid* **28**:9, 1083-1093. [Abstract] [Full Text] [PDF] [PDF Plus] [Supplementary Material]

953. Jeon Min Ji, Kim Hee Kyung, Kim Eun Heui, Kim Eun Sook, Yi Hyon-Seung, Kim Tae Yong, Kang Ho-Cheol, Shong Young Kee, Kim Won Bae, Kim Bo Hyun, Kim Won Gu, on Behalf of the Korean Thyroid Cancer Study Group. 2018. Decreasing Disease-Specific Mortality of Differentiated Thyroid Cancer in Korea: A Multicenter Cohort Study. *Thyroid* **28**:9, 1121-1127. [Abstract] [Full Text] [PDF] [PDF Plus] [Supplementary Material]

954. Grani Giorgio, Lamartina Livia, Biffoni Marco, Giacomelli Laura, Maranghi Marianna, Falcone Rosa, Ramundo Valeria, Cantisani Vito, Filetti Sebastiano, Durante Cosimo. 2018. Sonographically Estimated Risks of Malignancy for Thyroid Nodules Computed with Five Standard Classification Systems: Changes over Time and Their Relation to Malignancy. *Thyroid* **28**:9, 1190-1197. [Abstract] [Full Text] [PDF] [PDF Plus] [Supplementary Material]

955. Pablo Valderrabano, Laila Khazai, Zachary J. Thompson, Kristen J. Otto, Julie E. Hallanger-Johnson, Christine H. Chung, Barbara A. Centeno, Bryan McIver. 2018. Association of Tumor Size With Histologic and Clinical Outcomes Among Patients With Cytologically Indeterminate Thyroid Nodules. *JAMA Otolaryngology–Head & Neck Surgery* **144**:9, 788. [Crossref]

956. Hunter J. Underwood, Kepal N. Patel. 2018. Revisiting the 2015 American Thyroid Association Guidelines With Respect to Indeterminate Thyroid Nodules in the Era of Noninvasive Follicular Thyroid Neoplasm With Papillary-like Nuclear Features. *JAMA Otolaryngology–Head & Neck Surgery* **144**:9, 795. [Crossref]

957. Kepal N. Patel, Trevor E. Angell, Joshua Babiarz, Neil M. Barth, Thomas Blevins, Quan-Yang Duh, Ronald A. Ghossein, R. Mack Harrell, Jing Huang, Giulia C. Kennedy, Su Yeon Kim, Richard T. Kloos, Virginia A. LiVolsi, Gregory W. Randolph, Peter M. Sadow, Michael H. Shanik, Julie A. Sosa, S. Thomas Traweek, P. Sean Walsh, Duncan Whitney, Michael W. Yeh, Paul W. Ladenson. 2018. Performance of a Genomic Sequencing Classifier for the Preoperative Diagnosis of Cytologically Indeterminate Thyroid Nodules. *JAMA Surgery* **153**:9, 817. [Crossref]

958. Robert L. Ferris, Yuri Nikiforov, Davis Terris, Raja R. Seethala, J. Andrew Ridge, Peter Angelos, Quan-Yang Duh, Richard Wong, Mona M. Sabra, James A. Fagin, Bryan McIver, Victor J. Bernet, R. Mack Harrell, Naifa Busaidy, Edmund S. Cibas, William C. Faquin, Peter Sadow, Zubair Baloch, Maisie Shindo, Lisa Orloff, Louise Davies, Gregory W. Randolph. 2018. AHNS Series: Do you know your guidelines? AHNS Endocrine Section Consensus Statement: State-of-the-art thyroid surgical recommendations in the era of noninvasive follicular thyroid neoplasm with papillary-like nuclear features. *Head & Neck* **40**:9, 1881-1888. [Crossref]

959. Young Jun Choi, Jung Hwan Baek, Jung Hee Shin, Woo Hyun Shim, Seon-Ok Kim, Won-Hong Lee, Dong Eun Song, Tae Yong Kim, Ki-Wook Chung, Jeong Hyun Lee. 2018. Web-based thyroid imaging reporting and data system: Malignancy risk of atypia of undetermined significance or follicular lesion of undetermined significance thyroid nodules calculated by a combination of ultrasonography features and biopsy results. *Head & Neck* **40**:9, 1917-1925. [Crossref]

960. Hyungju Kwon, Joon-Hyop Lee, Joohyun Woo, Woosung Lim, Byung-In Moon, Nam Sun Paik. 2018. Efficacy of a clinical pathway for patients with thyroid cancer. *Head & Neck* **40**:9, 1909-1916. [Crossref]

961. Vivian Youngjean Park, Hye Sun Lee, Eun-Kyung Kim, Jin Young Kwak, Jung Hyun Yoon, Hee Jung Moon. 2018. Frequencies and malignancy rates of 6-tiered Bethesda categories of thyroid nodules according to ultrasound assessment and nodule size. *Head & Neck* **40**:9, 1947-1954. [Crossref]

962. Iain J. Nixon, Peter Angelos, Ashok R. Shaha, Alessandra Rinaldo, Michelle D. Williams, Alfio Ferlito. 2018. Image-guided chemical and thermal ablations for thyroid disease: Review of efficacy and complications. *Head & Neck* **40**:9, 2103-2115. [Crossref]

963. Yu-Mi Lee, Jae Won Cho, Suck Joon Hong, Jong Ho Yoon. 2018. Dynamic risk stratification in papillary thyroid carcinoma measuring 1 to 4 cm. *Journal of Surgical Oncology* **118**:4, 636-643. [Crossref]

964. Marco Russo, Pasqualino Malandrino, Mariacarla Moleti, Francesco Vermiglio, Antonio D'Angelo, Giuliana La Rosa, Giulia Sapuppo, Francesca Calaciura, Concetto Regalbuto, Antonino Belfiore, Riccardo Vigneri, Gabriella Pellegriti. 2018. Differentiated thyroid cancer in children: Heterogeneity of predictive risk factors. *Pediatric Blood & Cancer* **65**:9, e27226. [Crossref]

965. Wu Bo, Karen E. Schoedel, Sally E. Carty, Lisa A. Radkay, N. Paul Ohori, Yuri E. Nikiforov, Marina N. Nikiforova, Linwah Yip. 2018. Incidental Diagnosis of Parathyroid Lesions by Preoperative Use of Next-Generation Molecular Testing. *World Journal of Surgery* **42**:9, 2840-2845. [Crossref]

966. Chien-Ling Hung, Chih-Ching Yeh, Pi-Shan Sung, Chung-Jye Hung, Chih-Hsin Muo, Fung-Chang Sung, I-Ming Jou, Kuen-Jer Tsai. 2018. Is Partial or Total Thyroidectomy Associated with Risk of Long-Term Osteoporosis: A Nationwide Population-Based Study. *World Journal of Surgery* **42**:9, 2864-2871. [Crossref]

967. Eun Ju Ha, Chong Hyun Suh, Jung Hwan Baek. 2018. Complications following ultrasound-guided core needle biopsy of thyroid nodules: a systematic review and meta-analysis. *European Radiology* **28**:9, 3848-3860. [Crossref]

Downloaded by Memorial Sloan Kettering from www.liebertpub.com at 08/14/19. For personal use only.

968. Naykky Singh Ospina, Ana Castaneda-Guarderas, Russell Ward, Juan P. Brito, Spyridoula Maraka, Claudia Zeballos Palacios, Kathleen J. Yost, Diana S. Dean, Victor M. Montori. 2018. Patients' knowledge about the outcomes of thyroid biopsy: a patient survey. *Endocrine* **61**:3, 482-488. [Crossref]

969. Gustavo C. Penna, Ana Pestana, José Manuel Cameselle, Denise Momesso, Fernanda Accioly de Andrade, Ana Paula Aguiar Vidal, Mario Lucio Araujo Junior, Miguel Melo, Priscila Valverde Fernandes, Rossana Corbo, Mario Vaisman, Manuel Sobrinho-Simões, Paula Soares, Fernanda Vaisman. 2018. TERTp mutation is associated with a shorter progression free survival in patients with aggressive histology subtypes of follicular-cell derived thyroid carcinoma. *Endocrine* **61**:3, 489-498. [Crossref]

970. Rushad Patell, Alexandra Mikhael, Michael Tabet, James Bena, Eren Berber, Christian Nasr. 2018. Assessing the utility of preoperative serum thyroglobulin in differentiated thyroid cancer: a retrospective cohort study. *Endocrine* **61**:3, 506-510. [Crossref]

971. Jianhua Feng, Fei Shen, Wensong Cai, Xiaoxiong Gan, Xingyan Deng, Bo Xu. 2018. Survival of aggressive variants of papillary thyroid carcinoma in patients under 55 years old: a SEER population-based retrospective analysis. *Endocrine* **61**:3, 499-505. [Crossref]

972. Pedro Weslley Rosario, Grabriela Franco Mourão. 2018. Noninvasive follicular thyroid neoplasm with papillary-like nuclear features (NIFTP) in children and adolescents. *Endocrine* **61**:3, 542-544. [Crossref]

973. Maria José Carregosa Pinheiro dos Santos, André Uchimura Bastos, Vitor Rodrigues da Costa, Rosana Delcelo, Susan Chow Lindsey, Gabriel Avelar Colozza-Gama, Hongzhuang Peng, Frank J. Rauscher, Gisele Oler, Janete Maria Cerutti. 2018. LIMD2 Is Overexpressed in BRAF V600E-Positive Papillary Thyroid Carcinomas and Matched Lymph Node Metastases. *Endocrine Pathology* **29**:3, 222-230. [Crossref]

974. Rita Abi-Raad, Manju Prasad, Rebecca Baldassari, Kevin Schofield, Glenda G. Callender, David Chhieng, Adebowale J. Adeniran. 2018. The Value of Negative Diagnosis in Thyroid Fine-Needle Aspiration: a Retrospective Study with Histologic Follow-Up. *Endocrine Pathology* **29**:3, 269-275. [Crossref]

975. M. G. Castagna, R. Forleo, F. Maino, N. Fralassi, F. Barbato, P. Palmitesta, T. Pilli, M. Capezzone, L. Brilli, C. Ciuoli, S. Cantara, C. Formichi, F. Pacini. 2018. Small papillary thyroid carcinoma with minimal extrathyroidal extension should be managed as ATA low-risk tumor. *Journal of Endocrinological Investigation* **41**:9, 1029-1035. [Crossref]

976. Georg Zettinig, Wolfgang Buchinger, Michael Krebs. 2018. So wird die Feinnadelpunktion der Schilddrüse in Österreich durchgeführt – die Ergebnisse einer landesweiten Umfrage. *Journal für Klinische Endokrinologie und Stoffwechsel* **11**:3, 94-100. [Crossref]

977. Martha Hoffmann. 2018. Abklärung des FDG-PET-positiven Schilddrüsenknotens. *Journal für Klinische Endokrinologie und Stoffwechsel* **11**:3, 91-93. [Crossref]

978. Eun Cho, Eun-Kyung Kim, Hee Jung Moon, Jung Hyun Yoon, Vivian Y. Park, Jin Young Kwak. 2018. High suspicion US pattern on the ATA guidelines, not cytologic diagnosis, may be a predicting marker of lymph node metastasis in patients with classical papillary thyroid carcinoma. *The American Journal of Surgery* **216**:3, 562-566. [Crossref]

979. Jaume Capdevila, Kate Newbold, Lisa Licitra, Aron Popovtzer, Francesc Moreso, José Zamorano, Michael Kreissl, Javier Aller, Enrique Grande. 2018. Optimisation of treatment with lenvatinib in radioactive iodine-refractory differentiated thyroid cancer. *Cancer Treatment Reviews* **69**, 164-176. [Crossref]

980. Marta Gawin, Anna Wojakowska, Monika Pietrowska, Łukasz Marczak, Mykola Chekan, Karol Jelonek, Dariusz Lange, Roman Jaksik, Aleksandra Gruca, Piotr Widłak. 2018. Proteome profiles of different types of thyroid cancers. *Molecular and Cellular Endocrinology* **472**, 68-79. [Crossref]

981. So Young Park, Hye In Kim, Joon Young Choi, Jun-Ho Choe, Jung-Han Kim, Jee Soo Kim, Young Lyun Oh, Soo Yeon Hahn, Jung Hee Shin, Soo Hyun Ahn, Kyunga Kim, Jong Gill Jeong, Sun Wook Kim, Jae Hoon Chung, Tae Hyuk Kim. 2018. Low versus high activity radioiodine remnant ablation for differentiated thyroid carcinoma with gross extrathyroidal extension invading only strap muscles. *Oral Oncology* **84**, 41-45. [Crossref]

982. Michiya Nishino, Jeffrey F. Krane. 2018. Updates in Thyroid Cytology. *Surgical Pathology Clinics* **11**:3, 467-487. [Crossref]

983. Shih-Ping Cheng, Ming-Nan Chien, Tao-Yeuan Wang, Jie-Jen Lee, Chun-Chuan Lee, Chien-Liang Liu. 2018. Reconsideration of tumor size threshold for total thyroidectomy in differentiated thyroid cancer. *Surgery* **164**:3, 504-510. [Crossref]

984. Shanshan Wang, Juekun Wu, Jianwei Ren, Alexander C. Vlantis, Ming-yue Li, Shirley Y.W. Liu, Enders K.W. Ng, Amy B.W. Chan, Ding-Cun Luo, Zhimin Liu, Wei Guo, Lingbin Xue, Siu Kwan Ng, C. Andrew van Hasselt, Michael C.F. Tong, George G. Chen. 2018. MicroRNA-125b Interacts with Foxp3 to Induce Autophagy in Thyroid Cancer. *Molecular Therapy* **26**:9, 2295-2303. [Crossref]

985. Darlene Metter, William T. Phillips, Ronald C. Walker, Ralph Blumhardt. 2018. To Use or Not to Use 131I in Thyroid Cancer. *Clinical Nuclear Medicine* **43**:9, 670-671. [Crossref]

Downloaded by Memorial Sloan Kettering from www.liebertpub.com at 08/14/19. For personal use only.

986. Daqi Zhang, Tie Wang, Gianlorenzo Dionigi, Jiao Zhang, Gaofeng Xue, Hui Sun. 2018. Central Lymph Node Dissection by Endoscopic Bilateral Areola Versus Open Thyroidectomy. *Surgical Laparoscopy, Endoscopy & Percutaneous Techniques* 1. [Crossref]

987. Melissa Henry, Yu Chang, Saul Frenkiel, Gabrielle Chartier, Richard Payne, Christina MacDonald, Carmen Loiselle, Martin Black, Alex Mlynarek, Antoinette Ehrler, Zeev Rosberger, Michael Tamilia, Michael Hier. 2018. Feelings of Disenfranchisement and Support Needs Among Patients With Thyroid Cancer. *Oncology Nursing Forum* **45**:5, 639-652. [Crossref]

988. Amit Pandya, Elaine M Caoili, Farah Jawad-Makki, Ashish P Wasnik, Prasad R Shankar, Ron Bude, Megan R Haymart, Matthew S Davenport. 2018. Limitations of the 2015 ATA Guidelines for Prediction of Thyroid Cancer: A Review of 1947 Consecutive Aspirations. *The Journal of Clinical Endocrinology & Metabolism* **103**:9, 3496-3502. [Crossref]

989. Christine E Cherella, Henry A Feldman, Monica Hollowell, Danielle M Richman, Edmund S Cibas, Jessica R Smith, Trevor E Angell, Zhihong Wang, Erik K Alexander, Ari J Wassner. 2018. Natural History and Outcomes of Cytologically Benign Thyroid Nodules in Children. *The Journal of Clinical Endocrinology & Metabolism* **103**:9, 3557-3565. [Crossref]

990. Joanna Klubo-Gwiezdzinska, Leonard Wartofsky. 2018. The Role of Molecular Diagnostics in the Management of Indeterminate Thyroid Nodules. *The Journal of Clinical Endocrinology & Metabolism* **103**:9, 3507-3510. [Crossref]

991. David T. Hughes, Jennifer E. Rosen, Douglas B. Evans, Elizabeth Grubbs, Tracy S. Wang, Carmen C. Solórzano. 2018. Prophylactic Central Compartment Neck Dissection in Papillary Thyroid Cancer and Effect on Locoregional Recurrence. *Annals of Surgical Oncology* **25**:9, 2526-2534. [Crossref]

992. Rajshri M. Gartland, Carrie C. Lubitz. 2018. Impact of Extent of Surgery on Tumor Recurrence and Survival for Papillary Thyroid Cancer Patients. *Annals of Surgical Oncology* **25**:9, 2520-2525. [Crossref]

993. Eyun Song, Min Ji Jeon, Hye-Seon Oh, Minkyu Han, Yu-Mi Lee, Tae Yong Kim, Ki-Wook Chung, Won Bae Kim, Young Kee Shong, Dong Eun Song, Won Gu Kim. 2018. Do aggressive variants of papillary thyroid carcinoma have worse clinical outcome than classic papillary thyroid carcinoma?. *European Journal of Endocrinology* **179**:3, 135-142. [Crossref]

994. Domenico Albano, Francesco Bertagna, Mattia Bonacina, Rexhep Durmo, Elisabetta Cerudelli, Maria Gazzilli, Maria Beatrice Panarotto, Anna Maria Formenti, Gherardo Mazziotti, Andrea Giustina, Raffaele Giubbini. 2018. Possible delayed diagnosis and treatment of metastatic differentiated thyroid cancer by adopting the 2015 ATA guidelines. *European Journal of Endocrinology* **179**:3, 143-151. [Crossref]

995. Dagmara Rusinek, Aleksandra Pfeifer, Jolanta Krajewska, Malgorzata Oczko-Wojciechowska, Daria Handkiewicz-Junak, Agnieszka Pawlaczek, Jadwiga Zebracka-Gala, Malgorzata Kowalska, Renata Cyplinska, Ewa Zembala-Nozynska, Mykola Chekan, Ewa Chmielik, Aleksandra Kropinska, Roman Lamch, Beata Jurecka-Lubieniecka, Barbara Jarzab, Agnieszka Czarniecka. 2018. Coexistence of TERT Promoter Mutations and the BRAF V600E Alteration and Its Impact on Histopathological Features of Papillary Thyroid Carcinoma in a Selected Series of Polish Patients. *International Journal of Molecular Sciences* **19**:9, 2647. [Crossref]

996. Christine L. Twining, Mark A. Lupo, R. Michael Tuttle. 2018. IMPLEMENTING KEY CHANGES IN THE AMERICAN THYROID ASSOCIATION 2015 THYROID NODULES/DIFFERENTIATED THYROID CANCER GUIDELINES ACROSS PRACTICE TYPES. *Endocrine Practice* **24**:9, 833-840. [Crossref]

997. Ana Marcella Rivas, Aziza Nassar, Jun Zhang, John D. Casler, Ana Maria Chindris, Robert Smallridge, Victor Bernet. 2018. THYROSEQ ® V2.0 MOLECULAR TESTING: A COST-EFFECTIVE APPROACH FOR THE EVALUATION OF INDETERMINATE THYROID NODULES. *Endocrine Practice* **24**:9, 780-788. [Crossref]

998. Meng-Meng Xiang, Jiang-Yue Qin, Yong-Chun Shen, Yong Jiang, Fu-Qiang Wen. 2018. Lung Metastasis of Thyroid Cancer Appearing Diffuse and Disseminated on Imaging. *Chinese Medical Journal* **131**:17, 2132. [Crossref]

999. Livia Lamartina, Giorgio Grani, Cosimo Durante, Isabelle Borget, Sebastiano Filetti, Martin Schlumberger. 2018. Follow-up of differentiated thyroid cancer – what should (and what should not) be done. *Nature Reviews Endocrinology* **14**:9, 538-551. [Crossref]

1000. Chang-Hee Lee, Ji-hoon Jung, Seung Hyun Son, Chae Moon Hong, Ju Hye Jeong, Shin Young Jeong, Sang-Woo Lee, Jaetae Lee, Byeong-Cheol Ahn. 2018. Risk factors for radioactive iodine-avid metastatic lymph nodes on post I-131 ablation SPECT/CT in low- or intermediate-risk groups of papillary thyroid cancer. *PLOS ONE* **13**:8, e0202644. [Crossref]

1001. Da Som Kim, Dong Wook Kim, Young Jin Heo, Jin Wook Baek, Yoo Jin Lee, Hye Jung Choo, Young Mi Park, Ha Kyoung Park, Tae Kwun Ha, Do Hun Kim, Soo Jin Jung, Ji Sun Park, Ki Jung Ahn, Hye Jin Baek, Taewoo Kang. 2018. Utility of including BRAF mutation analysis with ultrasonographic and cytological diagnoses in ultrasonography-guided fine-needle aspiration of thyroid nodules. *PLOS ONE* **13**:8, e0202687. [Crossref]

1002. Jae Hyun Park, Yu-mi Lee, Yi Ho Lee, Suck Joon Hong, Jong Ho Yoon. 2018. The prognostic value of serum thyroid-stimulating hormone level post-lobectomy in low- and intermediate-risk papillary thyroid carcinoma. *Journal of Surgical Oncology* **26**. . [Crossref]

Downloaded by Memorial Sloan Kettering from www.liebertpub.com at 08/14/19. For personal use only.

1003. Brendan C. Stack, Neil S. Tolley, Twyla B. Bartel, John P. Bilezikian, Donald Bodenner, Pauline Camacho, Jeremy P. D. T. Cox, Henning Dralle, James E. Jackson, John C. Morris, Lisa Ann Orloff, Fausto Palazzo, John A. Ridge, David Scott-Coombes, David Steward, David J. Terris, Geoffrey Thompson, Gregory W. Randolph. 2018. AHNS Series: Do you know your guidelines? Optimizing outcomes in reoperative parathyroid surgery: Definitive multidisciplinary joint consensus guidelines of the American Head and Neck Society and the British Association of Endocrine and Thyroid Surgeons. *Head & Neck* **150**. . [Crossref]

1004. Fish Stephanie. 2018. The 2015 ATA Guidelines for the Prediction of Thyroid Cancer Based on Ultrasonography Overestimate the Incidence of Thyroid Cancer. *Clinical Thyroidology* **30**:8, 364-367. [Citation] [Full Text] [PDF] [PDF Plus]

1005. Tam Samantha, Amit Moran, Boonsripitayanon Mongkol, Busaidy Naifa L., Cabanillas Maria E., Waguespack Steven G., Gross Neil D., Grubbs Elizabeth G., Williams Michelle D., Lai Stephen Y., Sturgis Erich M., Zafereo Mark E.. 2018. Effect of Tumor Size and Minimal Extrathyroidal Extension in Patients with Differentiated Thyroid Cancer. *Thyroid* **28**:8, 982-990. [Abstract] [Full Text] [PDF] [PDF Plus] [Supplementary Material]

1006. Liang Jinyu, Huang Xiaowen, Hu Hangtong, Liu Yihao, Zhou Qian, Cao Qinghua, Wang Wei, Liu Baoxian, Zheng Yanling, Li Xin, Xie Xiaoyan, Lu Mingde, Peng Sui, Liu Longzhong, Xiao Haipeng. 2018. Predicting Malignancy in Thyroid Nodules: Radiomics Score Versus 2017 American College of Radiology Thyroid Imaging, Reporting and Data System. *Thyroid* **28**:8, 1024-1033. [Abstract] [Full Text] [PDF] [PDF Plus] [Supplementary Material]

1007. Tran Bryan, Roshan David, Abraham Earl, Wang Laura, Garibotto Natalia, Wykes James, Campbell Peter, Ebrahimi Ardalan. 2018. The Prognostic Impact of Tumor Size in Papillary Thyroid Carcinoma is Modified by Age. *Thyroid* **28**:8, 991-996. [Abstract] [Full Text] [PDF] [PDF Plus]

1008. Park Suyeon, Jeon Min Ji, Oh Hye-Seon, Lee Yu-Mi, Sung Tae-Yon, Han Minkyu, Han Ji Min, Kim Tae Yong, Chung Ki-Wook, Kim Won Bae, Shong Young Kee, Kim Won Gu. 2018. Changes in Serum Thyroglobulin Levels After Lobectomy in Patients with Low-Risk Papillary Thyroid Cancer. *Thyroid* **28**:8, 997-1003. [Abstract] [Full Text] [PDF] [PDF Plus]

1009. van Velsen Evert F.S., Stegenga Merel T., van Kemenade Folkert J., Kam Boen L.R., van Ginhoven Tessa M., Visser W. Edward, Peeters Robin P.. 2018. Comparing the Prognostic Value of the Eighth Edition of the American Joint Committee on Cancer/Tumor Node Metastasis Staging System Between Papillary and Follicular Thyroid Cancer. *Thyroid* **28**:8, 976-981. [Abstract] [Full Text] [PDF] [PDF Plus] [Supplementary Material]

1010. Valderrabano Pablo, McGettigan Melissa J., Lam Cesar A., Khazai Laila, Thompson Zachary J., Chung Christine H., Centeno Barbara A., McIver Bryan. 2018. Thyroid Nodules with Indeterminate Cytology: Utility of the American Thyroid Association Sonographic Patterns for Cancer Risk Stratification. *Thyroid* **28**:8, 1004-1012. [Abstract] [Full Text] [PDF] [PDF Plus] [Supplementary Material]

1011. S. Y. Park, H. I. Kim, J.-H. Kim, J. S. Kim, Y. L. Oh, S. W. Kim, J. H. Chung, H. W. Jang, T. H. Kim. 2018. Prognostic significance of gross extrathyroidal extension invading only strap muscles in differentiated thyroid carcinoma. *British Journal of Surgery* **105**:9, 1155-1162. [Crossref]

1012. Esther Diana Rossi, Luigi Maria Larocca, Liron Pantanowitz. 2018. Ancillary molecular testing of indeterminate thyroid nodules. *Cancer Cytopathology* **126**, 654-671. [Crossref]

1013. Vivian L. Weiss, Rochelle F. Andreotti, Kim A. Ely. 2018. Use of the thyroid imaging, reporting, and data system (TI-RADS) scoring system for the evaluation of subcentimeter thyroid nodules. *Cancer Cytopathology* **126**:8, 518-524. [Crossref]

1014. Yasuhiro Ito, Akira Miyauchi, Hiroo Masuoka, Mitsuhiro Fukushima, Minoru Kihara, Akihiro Miya. 2018. Excellent Prognosis of Central Lymph Node Recurrence-Free Survival for cN0M0 Papillary Thyroid Carcinoma Patients Who Underwent Routine Prophylactic Central Node Dissection. *World Journal of Surgery* **42**:8, 2462-2468. [Crossref]

1015. Brian H. H. Lang, Yu-Cho Woo, Keith Wan-Hang Chiu. 2018. Sequential high intensity focused ultrasound (HIFU) ablation in the treatment of benign multinodular goitre: an observational retrospective study. *European Radiology* **28**:8, 3237-3244. [Crossref]

1016. Xueyang Yang, Yifang Hu, He Shi, Chengzhou Zhang, Zhixiao Wang, Xiaoyun Liu, Huanhuan Chen, Lijuan Zhang, Dai Cui. 2018. The diagnostic value of TROP-2, SLP-2 and CD56 expression in papillary thyroid carcinoma. *European Archives of Oto-Rhino-Laryngology* **275**:8, 2127-2134. [Crossref]

1017. Nikola Slijepcevic, Vladan Zivaljevic, Aleksandar Diklic, Milan Jovanovic, Branislav Oluic, Ivan Paunovic. 2018. Risk factors associated with intrathyroid extension of thyroid microcarcinomas. *Langenbeck's Archives of Surgery* **403**:5, 615-622. [Crossref]

1018. Carlos K. H. Wong, Edmond P. H. Choi, Y. C. Woo, Brian H. H. Lang. 2018. Measurement properties of ThyPRO short-form (ThyPRO-39) for use in Chinese patients with benign thyroid diseases. *Quality of Life Research* **27**:8, 2177-2187. [Crossref]

1019. Hazel B. Nichols, Chelsea Anderson, Kathryn J. Ruddy, Kristin Z. Black, Barbara Luke, Stephanie M. Engel, Jennifer E. Mersereau. 2018. Childbirth after adolescent and young adult cancer: a population-based study. *Journal of Cancer Survivorship* **12**:4, 592-600. [Crossref]

Downloaded by Memorial Sloan Kettering from www.liebertpub.com at 08/14/19. For personal use only.

1020. Hengqiang Zhao, Hehe Li, Tao Huang. 2018. High Urinary Iodine, Thyroid Autoantibodies, and Thyroid-Stimulating Hormone for Papillary Thyroid Cancer Risk. *Biological Trace Element Research* **184**:2, 317-324. [Crossref]

1021. Gabin Yun, Yeo Koon Kim, Sang Il Choi, Ji-hoon Kim. 2018. Medullary thyroid carcinoma: Application of Thyroid Imaging Reporting and Data System (TI-RADS) Classification. *Endocrine* **61**:2, 285-292. [Crossref]

1022. Eduardo Bardou Yunes Filho, Rafael Vaz Machry, Rodrigo Mesquita, Rafael Selbach Scheffel, Ana Luiza Maia. 2018. The timing of parathyroid hormone measurement defines the cut-off values to accurately predict postoperative hypocalcemia: a prospective study. *Endocrine* **61**:2, 224-231. [Crossref]

1023. Ninni Mu, C. Christofer Juhlin, Edneia Tani, Anastasios Sofiadis, Eva Reihnér, Jan Zedenius, Catharina Larsson, Inga-Lena Nilsson. 2018. High Ki-67 index in fine needle aspiration cytology of follicular thyroid tumors is associated with increased risk of carcinoma. *Endocrine* **61**:2, 293-302. [Crossref]

1024. Christopher John Symonds, Paula Seal, Sana Ghaznavi, Winson Y. Cheung, Ralf Paschke. 2018. Thyroid nodule ultrasound reports in routine clinical practice provide insufficient information to estimate risk of malignancy. *Endocrine* **61**:2, 303-307. [Crossref]

1025. Kristine Zøylner Swan, Viveque Egsgaard Nielsen, Christian Godballe, Jens Faunø Thrane, Marie Riis Mortensen, Sten Schytte, Henrik Baymler Pedersen, Peer Christiansen, Steen Joop Bonnema. 2018. Is serum TSH a biomarker of thyroid carcinoma in patients residing in a mildly iodine-deficient area?. *Endocrine* **61**:2, 308-316. [Crossref]

1026. Chae Moon Hong, Byeong-Cheol Ahn. 2018. Factors Associated with Dose Determination of Radioactive Iodine Therapy for Differentiated Thyroid Cancer. *Nuclear Medicine and Molecular Imaging* **52**:4, 247-253. [Crossref]

1027. Minchul Song, Subin Jeon, Sae-Ryung Kang, Zeenat Jabin, Su Woong Yoo, Jung-Joon Min, Hee-Seung Bom, Sang-Geon Cho, Jahae Kim, Ho-Chun Song, Seong Young Kwon. 2018. Response Prediction of Altered Thyroglobulin Levels After Radioactive Iodine Therapy Aided by Recombinant Human Thyrotropin in Patients with Differentiated Thyroid Cancer. *Nuclear Medicine and Molecular Imaging* **52**:4, 287-292. [Crossref]

1028. Maria Grazia Castagna, Francesco Trimarchi. 2018. La risposta al trattamento iniziale del carcinoma differenziato della tiroide ne guida la gestione clinica nel tempo. *L'Endocrinologo* **19**:4, 213-214. [Crossref]

1029. T. Rago, S. Manfrini, A. Palermo. 2018. ATA vs EU-TIRADS vs AACE/ACE/AME: criteri ecografici tiroidei a confronto. *L'Endocrinologo* **19**:4, 210-212. [Crossref]

1030. Monica Finessi, Daniele Giovanni Nicolotti, Nicola Ferraro, Marilena Bellò, Alessandro Piovesan, Gianni Bisi, Désirée Deandreis. 2018. Lezioni dal riscontro incidentale di captazione tiroidea alla 18F-FDG PET/CT. *L'Endocrinologo* **19**:4, 218-219. [Crossref]

1031. Irene López Rojo, Adela Gómez Valdazo, Joaquín Gómez Ramirez. 2018. Current Use of Molecular Profiling for Indeterminate Thyroid Nodules. *Cirugía Española (English Edition)* **96**:7, 395-400. [Crossref]

1032. Irene López Rojo, Adela Gómez Valdazo, Joaquín Gómez Ramirez. 2018. Utilidad del estudio molecular de nódulos tiroideos con citología indeterminada. *Cirugía Española* **96**:7, 395-400. [Crossref]

1033. Manuel Penin. 2018. Reply to letters to the editor on the thyroid fine needle aspiration biopsy learning curve. *Endocrinología, Diabetes y Nutrición (English ed.)* **65**:7, 423-424. [Crossref]

1034. Manuel Penin. 2018. Respuesta a cartas al editor sobre la curva de aprendizaje de punción-aspiración con aguja fina de tiroides. *Endocrinología, Diabetes y Nutrición* **65**:7, 423-424. [Crossref]

1035. Chad M. Hall, Donald C. LaSeur, Samuel K. Snyder, Terry C. Lairmore. 2018. Reoperative central lymph node dissection for incidental papillary thyroid cancer can be performed safely: A retrospective review. *International Journal of Surgery* **56**, 102-107. [Crossref]

1036. Meghan Garstka, Khuzema Mohsin, Daniah Bu Ali, Hosam Shalaby, Kareem Ibraheem, Mahmoud Farag, Sang-Wook Kang, Emad Kandil. 2018. Well-differentiated thyroid cancer and robotic transaxillary surgery at a North American institution. *Journal of Surgical Research* **228**, 170-178. [Crossref]

1037. Oksana Hamidi, Matthew R. Callstrom, Robert A. Lee, Diana Dean, M. Regina Castro, John C. Morris, Marius N. Stan. 2018. Outcomes of Radiofrequency Ablation Therapy for Large Benign Thyroid Nodules: A Mayo Clinic Case Series. *Mayo Clinic Proceedings* **93**:8, 1018-1025. [Crossref]

1038. Nicole M. Iñiguez-Ariza, Robert A. Lee, Naykky M. Singh-Ospina, Marius N. Stan, M. Regina Castro. 2018. Ethanol Ablation for the Treatment of Cystic and Predominantly Cystic Thyroid Nodules. *Mayo Clinic Proceedings* **93**:8, 1009-1017. [Crossref]

1039. Giuseppe Barbesino. 2018. Percutaneous Treatment of Benign Thyroid Nodules: Time to Bring It to the United States?. *Mayo Clinic Proceedings* **93**:8, 970-972. [Crossref]

1040. John Benjamin McIntire, Susan McCammon, Eric R. Mong. 2018. Endocrine Surgery in the Geriatric Population. *Otolaryngologic Clinics of North America* **51**:4, 753-758. [Crossref]

Downloaded by Memorial Sloan Kettering from www.liebertpub.com at 08/14/19. For personal use only.

1041. Jung Hyun Yoon, Eun-Kyung Kim, Jin Young Kwak, Vivian Youngjean Park, Hee Jung Moon. 2018. Application of Various Additional Imaging Techniques for Thyroid Ultrasound: Direct Comparison of Combined Various Elastography and Doppler Parameters to Gray-Scale Ultrasound in Differential Diagnosis of Thyroid Nodules. *Ultrasound in Medicine & Biology* **44**:8, 1679-1686. [Crossref]

1042. N Bourcigaux, C Rubino, I Berthaud, M E Toubert, B Donadille, L Leenhardt, I Petrot-Keller, S Brailly-Tabard, J Fromigué, F de Vathaire, T Simon, J P Siffroi, M Schlumberger, P Bouchard, S Christin-Maitre. 2018. Impact on testicular function of a single ablative activity of 3.7 GBq radioactive iodine for differentiated thyroid carcinoma. *Human Reproduction* **33**:8, 1408-1416. [Crossref]

1043. Bin Wang, An-Ping Su, Teng-Fei Xing, Han Luo, Wan-Jun Zhao, Jing-Qiang Zhu. 2018. The function of carbon nanoparticles to improve lymph node dissection and identification of parathyroid glands during thyroid reoperation for carcinoma. *Medicine* **97**:32, e11778. [Crossref]

1044. Zeming Liu, Qiuyang Zhao, Chunping Liu, Wen Zeng, Jie Ming, Chen Chen, Shuntao Wang, Yiquan Xiong, Chao Zhang, Tianwen Chen, Tao Huang, Liang Guo. 2018. Is biopsy enough for papillary thyroid microcarcinoma?. *Medicine* **97**:31, e11791. [Crossref]

1045. Xuan Wang, Jian Tan, Wei Zheng, Ning Li. 2018. A retrospective study of the clinical features in papillary thyroid microcarcinoma depending on age. *Nuclear Medicine Communications* **39**:8, 713-719. [Crossref]

1046. Sara E. Higgins, Justine A. Barletta. 2018. Applications of Immunohistochemistry to Endocrine Pathology. *Advances In Anatomic Pathology* 1. [Crossref]

1047. Arnoldo Piccardo, Luca Giovanella. 2018. Re. *Clinical Nuclear Medicine* **43**:8, 631-632. [Crossref]

1048. Minjung Seo, Yon Seon Kim, Jong Cheol Lee, Myung Woul Han, Eun Sook Kim, Kyung Bin Kim, Seol Hoon Park. 2018. Low-Dose Radioactive Iodine Ablation Is Sufficient in Patients With Small Papillary Thyroid Cancer Having Minor Extrathyroidal Extension and Central Lymph Node Metastasis (T3 N1a). *Clinical Nuclear Medicine* **43**:8, 635-636. [Crossref]

1049. Minjung Seo, Yon Seon Kim, Jong Cheol Lee, Myung Woul Han, Eun Sook Kim, Kyung Bin Kim, Seol Hoon Park. 2018. Low-Dose Radioactive Iodine Ablation Is Sufficient in Patients With Small Papillary Thyroid Cancer Having Minor Extrathyroidal Extension and Central Lymph Node Metastasis (T3 N1a). *Clinical Nuclear Medicine* **43**:8, 633-634. [Crossref]

1050. Luca Giovanella, Arnoldo Piccardo, Cinzia Pezzoli, Fabiano Bini, Riccardo Ricci, Teresa Ruberto, Pierpaolo Trimboli. 2018. Comparison of high intensity focused ultrasound and radioiodine for treating toxic thyroid nodules. *Clinical Endocrinology* **89**:2, 219-225. [Crossref]

1051. Kelsi E. Deaver, Bryan R. Haugen, Nikita Pozdeyev, Carrie B. Marshall. 2018. Outcomes of Bethesda categories III and IV thyroid nodules over 5 years and performance of the Afirma gene expression classifier: A single-institution study. *Clinical Endocrinology* **89**:2, 226-232. [Crossref]

1052. H.-J. Jiang, C.-W. Wu, F.-Y. Chiang, H.-Y.C. Chiou, I.-J. Chen, P.-J. Hsiao. 2018. Reliable sonographic features for nodal thyroglobulin to diagnose recurrent lymph node metastasis from papillary thyroid carcinoma. *Clinical Otolaryngology* **43**:4, 1065-1072. [Crossref]

1053. Danielle M. Richman, Carol B. Benson, Peter M. Doubilet, Hope E. Peters, Stephen A. Huang, Elizabeth Asch, Ari J. Wassner, Jessica R. Smith, Christine E. Cherella, Mary C. Frates. 2018. Thyroid Nodules in Pediatric Patients: Sonographic Characteristics and Likelihood of Cancer. *Radiology* **288**:2, 591-599. [Crossref]

1054. Jooae Choe, Jung Hwan Baek, Hye Sun Park, Young Jun Choi, Jeong Hyun Lee. 2018. Core needle biopsy of thyroid nodules: outcomes and safety from a large single-center single-operator study. *Acta Radiologica* **59**:8, 924-931. [Crossref]

1055. Jieun Koh, Soo-Yeon Kim, Hye Sun Lee, Eun-Kyung Kim, Jin Young Kwak, Hee Jung Moon, Jung Hyun Yoon. 2018. Diagnostic performances and interobserver agreement according to observer experience: a comparison study using three guidelines for management of thyroid nodules. *Acta Radiologica* **59**:8, 917-923. [Crossref]

1056. Rosa Falcone, Valeria Ramundo, Livia Lamartina, Valeria Ascoli, Daniela Bosco, Cira Di Gioia, Teresa Montesano, Marco Biffoni, Marco Bononi, Laura Giacomelli, Antonio Minni, Maria Segni, Marianna Maranghi, Vito Cantisani, Cosimo Durante, Giorgio Grani. 2018. Sonographic Presentation of Metastases to the Thyroid Gland: A Case Series. *Journal of the Endocrine Society* **2**:8, 855-859. [Crossref]

1057. Xiao Shi, Nai-Si Huang, Bo-Wen Lei, Ke-Han Song, Rong-Liang Shi, Wen-Jun Wei, Wei-Ping Hu, Fan Dong, Yu Wang, Yu-Long Wang, Qing-Hai Ji. 2018. Central Lymph Node Status has Significant Prognostic Value in the Clinically Node-Negative Tall-Cell Variant of Papillary Thyroid Cancer Regardless of T-Staging and Radioactive Iodine Administration: First Evidence From a Population-Based Study. *Annals of Surgical Oncology* **25**:8, 2316-2322. [Crossref]

Downloaded by Memorial Sloan Kettering from www.liebertpub.com at 08/14/19. For personal use only.

1058. Filiz Eksi Haydardedeoglu, Gulay Simsek Bagir, Nese Torun, Emrah Kocer, Mehmet Reyhan, Melek Eda Ertorer. 2018. Hounsfield unit value has null effect on thyroid nodules at 18F-FDG PET/CT scans. *Archives of Endocrinology and Metabolism* **62**:4, 460-465. [Crossref]

1059. Immacolata Nettore, Annamaria Colao, Paolo Macchia. 2018. Nutritional and Environmental Factors in Thyroid Carcinogenesis. *International Journal of Environmental Research and Public Health* **15**:8, 1735. [Crossref]

1060. Raj K. Gopal, Kirsten Kübler, Sarah E. Calvo, Paz Polak, Dimitri Livitz, Daniel Rosebrock, Peter M. Sadow, Braidie Campbell, Samuel E. Donovan, Salma Amin, Benjamin J. Gigliotti, Zenon Grabarek, Julian M. Hess, Chip Stewart, Lior Z. Braunstein, Peter F. Arndt, Scott Mordecai, Angela R. Shih, Frances Chaves, Tiannan Zhan, Carrie C. Lubitz, Jiwoong Kim, A. John Iafrate, Lori Wirth, Sareh Parangi, Ignaty Leshchiner, Gilbert H. Daniels, Vamsi K. Mootha, Dora Dias-Santagata, Gad Getz, David G. McFadden. 2018. Widespread Chromosomal Losses and Mitochondrial DNA Alterations as Genetic Drivers in Hürthle Cell Carcinoma. *Cancer Cell* **34**:2, 242-255.e5. [Crossref]

1061. So-hyeon Hong, Hyejin Lee, Min-Sun Cho, Jee Eun Lee, Yeon-Ah Sung, Young Sun Hong. 2018. Malignancy Risk and Related Factors of Atypia of Undetermined Significance/Follicular Lesion of Undetermined Significance in Thyroid Fine Needle Aspiration. *International Journal of Endocrinology* **2018**, 1-7. [Crossref]

1062. H. Gilbert Welch, Gerard M. Doherty. 2018. Saving Thyroids — Overtreatment of Small Papillary Cancers. *New England Journal of Medicine* **379**:4, 310-312. [Crossref]

1063. Qingjun Wang, Yong Guo, Jing Zhang, Lijing Shi, Haoyong Ning, Xiliang Zhang, Yuanyuan Lu. 2018. Utility of high b-value (2000 sec/mm2) DWI with RESOLVE in differentiating papillary thyroid carcinomas and papillary thyroid microcarcinomas from benign thyroid nodules. *PLOS ONE* **13**:7, e0200270. [Crossref]

1064. Chan Yong Seong, Young Jun Chai, Sang Mok Lee, Su-jin Kim, June Young Choi, Kyu Eun Lee, Ki-Tae Hwang, Sun-Won Park, Ka Hee Yi. 2018. Significance of distance between tumor and thyroid capsule as an indicator for central lymph node metastasis in clinically node negative papillary thyroid carcinoma patients. *PLOS ONE* **13**:7, e0200166. [Crossref]

1065. Muhammed Kizilgul, Meltem Mermer, Bekir Ucan. Medical Nutrition Therapy for Special Groups with Diabetes Mellitus . [Crossref]

1066. Stefano Valabrega, Giuliano Santolamazza, Francesco Romanelli, Giorgia Scapicchio, Francesco D'Angelo, Carlo Bellotti, Paolo Aurello, Luciano Izzo, Maria R. Giovagnoli, Pierpaolo Trimboli. 2018. Cancer Rate of the Indeterminate Lesions at Low or High Risk According to Italian System for Reporting of Thyroid FNA. *Frontiers in Endocrinology* **9**. . [Crossref]

1067. Dilidaer Muhanhali, Tianyu Zhai, Jingjing Jiang, Zhilong Ai, Wei Zhu, Yan Ling. 2018. Long Non-coding Antisense RNA TNRC6C-AS1 Is Activated in Papillary Thyroid Cancer and Promotes Cancer Progression by Suppressing TNRC6C Expression. *Frontiers in Endocrinology* **9**. . [Crossref]

1068. Bernard Peene, Annick Van den Bruel, Carolien Moyson, Brigitte Decallonne. 2018. Evolution in the management of thyroid cancer: an observational study in two referral centres in Belgium. *Acta Clinica Belgica* **73**:4, 287-291. [Crossref]

1069. Ramesh K. Pandey, Eliza Sharma, Sasmit Roy, Saroj Kandel, Sumit Dahal, Muhammad Rajib Hossain, Marie F. Schmidt, Zewge Shiferaw-Deribe. 2018. Hot and malignant – a case of invasive papillary carcinoma in hyperthyroid patient with hot nodules. *Journal of Community Hospital Internal Medicine Perspectives* **8**:4, 220-222. [Crossref]

1070. Erik Kouba, Andrew Ford, Charmaine G Brown, Chen Yeh, Gene P Siegal, Upender Manne, Isam-Eldin Eltoum. 2018. Detection of BRAF V600E Mutations With Next-Generation Sequencing in Infarcted Thyroid Carcinomas After Fine-Needle Aspiration. *American Journal of Clinical Pathology* **150**:2, 177-185. [Crossref]

1071. Hershman Jerome M.. 2018. Analysis of Clinical Factors 1 Year After Surgery for Thyroid Cancer Enables Prediction of Treatment-free Survival. *Clinical Thyroidology* **30**:7, 309-311. [Citation] [Full Text] [PDF] [PDF Plus]

1072. Livhits Masha J., Yeh Michael W.. 2018. Thyroglobulin Levels Do Not Predict Recurrence After Lobectomy for Low-Risk Papillary Thyroid Cancer. *Clinical Thyroidology* **30**:7, 312-314. [Citation] [Full Text] [PDF] [PDF Plus]

1073. Emerson Charles H.. 2018. Recent Molecular Profiling Studies in Papillary and Follicular Thyroid Carcinoma Provide Clinical and Basic Insights. *Clinical Thyroidology* **30**:7, 319-323. [Citation] [Full Text] [PDF] [PDF Plus]

1074. Wang Tracy S.. 2018. Residual Lymph Node Metastases after Initial Surgery—What Are the Implications for the Approach to Initial Surgery and Postoperative Therapy?. *Clinical Thyroidology* **30**:7, 324-327. [Citation] [Full Text] [PDF] [PDF Plus]

1075. Biermann Martin, Reisæter Lars R.. 2018. Automated Analysis of Gray-Scale Ultrasound Images of Thyroid Nodules ("Radiomics") May Outperform Image Interpretation by Less Experienced Thyroid Radiologists. *Clinical Thyroidology* **30**:7, 332-336. [Citation] [Full Text] [PDF] [PDF Plus]

1076. Chu Karen P., Baker Sarah, Zenke Julianna, Morad Ahmed, Ghosh Sunita, Morrish Don W., McEwan A.J.B. Sandy, Williams David C., Severin Diane, McMullen Todd P.W.. 2018. Low-Activity Radioactive Iodine Therapy for Thyroid Carcinomas

Downloaded by Memorial Sloan Kettering from www.liebertpub.com at 08/14/19. For personal use only.

Exhibiting Nodal Metastases and Extrathyroidal Extension May Lead to Early Disease Recurrence. *Thyroid* **28**:7, 902-912. [Abstract] [Full Text] [PDF] [PDF Plus]

1077. Cho Yoon Young, Kang Min Jin, Kim Soo Kyoung, Jung Jung Hwa, Hahm Jong Ryeal, Kim Tae Hyuk, Nam Joo Young, Lee Byung-Wan, Lee Yong-ho, Chung Jae Hoon, Song Sun Ok, Kim Sun Wook. 2018. Protective Effect of Metformin Against Thyroid Cancer Development: A Population-Based Study in Korea. *Thyroid* **28**:7, 864-870. [Abstract] [Full Text] [PDF] [PDF Plus] [Supplementary Material]

1078. Matrone Antonio, Latrofa Francesco, Torregrossa Liborio, Piaggi Paolo, Gambale Carla, Faranda Alessio, Ricci Debora, Agate Laura, Molinaro Eleonora, Basolo Fulvio, Vitti Paolo, Elisei Rossella. 2018. Changing Trend of Thyroglobulin Antibodies in Patients With Differentiated Thyroid Cancer Treated With Total Thyroidectomy Without 131I Ablation. *Thyroid* **28**:7, 871-879. [Abstract] [Full Text] [PDF] [PDF Plus]

1079. Chen Chun-Rong, McLachlan Sandra M., Hubbard Paul A., McNally Randall, Murali Ramachandran, Rapoport Basil. 2018. Structure of a Thyrotropin Receptor Monoclonal Antibody Variable Region Provides Insight into Potential Mechanisms for its Inverse Agonist Activity. *Thyroid* **28**:7, 933-940. [Abstract] [Full Text] [PDF] [PDF Plus]

1080. Rachel C. Jug, Michael B. Datto, Xiaoyin "Sara" Jiang. 2018. Molecular testing for indeterminate thyroid nodules: Performance of the Afirma gene expression classifier and ThyroSeq panel. *Cancer Cytopathology* **126**:7, 471-480. [Crossref]

1081. Antonio Rabal Fueyo, Magdalena Vilanova Serra, Enrique Lerma Puertas, Enrique Montserrat Esplugas, José Ignacio Pérez García, Eugenia Mato Matute, Alberto De Leiva Hidalgo, Antonio Moral Duarte. 2018. Diagnostic accuracy of ultrasound and fine-needle aspiration in the study of thyroid nodule and multinodular goitre. *Endocrinology, Diabetes & Metabolism* **1**:3, e00024. [Crossref]

1082. Ayaka J. Iwata, Arti Bhan, Sharon Lahiri, Amy M. Williams, Andrew R. Taylor, Steven S. Chang, Michael C. Singer. 2018. Comparison of incidental versus palpable thyroid nodules presenting for fine-needle aspiration biopsy. *Head & Neck* **40**:7, 1508-1514. [Crossref]

1083. Chong-Ke Zhao, Shi-Gao Chen, Azra Alizad, Ya-Ping He, Qiao Wang, Dan Wang, Wen-Wen Yue, Kun Zhang, Shen Qu, Qing Wei, Hui-Xiong Xu. 2018. Three-Dimensional Shear Wave Elastography for Differentiating Benign From Malignant Thyroid Nodules. *Journal of Ultrasound in Medicine* **37**:7, 1777-1788. [Crossref]

1084. Arnoldo Piccardo, Matteo Puntoni, Giulia Ferrarazzo, Luca Foppiani, Gianluca Bottoni, Vania Altrinetti, Giorgio Treglia, Mehrdad Naseri, Bassam Dib, Manlio Cabria, Pierpaolo Trimboli, Michela Massollo, Luca Giovanella. 2018. Could short thyroid hormone withdrawal be an effective strategy for radioiodine remnant ablation in differentiated thyroid cancer patients?. *European Journal of Nuclear Medicine and Molecular Imaging* **45**:7, 1218-1223. [Crossref]

1085. Pedro Weslley Rosário. 2018. Noninvasive Follicular Thyroid Neoplasm with Papillary-like Nuclear Features (NIFTP): Did We Trade Six for a Half a Dozen?. *World Journal of Surgery* **42**:7, 2277-2278. [Crossref]

1086. Irakoze Laurent, Siying Tang, Manirakiza Astère, Kan Ran Wang, Shuhua Deng, Ling Xiao, Qi Fu Li. 2018. Liquid L-thyroxine versus tablet L-thyroxine in patients on L- thyroxine replacement or suppressive therapy: a meta-analysis. *Endocrine* **61**:1, 28-35. [Crossref]

1087. Maria Grazia Chiofalo, Simona Signoriello, Franco Fulciniti, Nicola Avenia, Serenella Ristagno, Celestino Pio Lombardi, Angelo Nicolosi, Maria Rosa Pelizzo, Giuliano Perigli, Andrea Polistena, Vincenzo Panebianco, Rocco Bellantone, Pietro Giorgio Calò, Isabella Merante Boschin, Benedetta Badii, Massimo Di Maio, Ciro Gallo, Francesco Perrone, Luciano Pezzullo. 2018. Predictivity of clinical, laboratory and imaging findings in diagnostic definition of palpable thyroid nodules. A multicenter prospective study. *Endocrine* **61**:1, 43-50. [Crossref]

1088. Shouyi Yan, Wenxin Zhao, Bo Wang, Liyong Zhang. 2018. Standardization of simple auxiliary method beneficial to total endoscopic thyroidectomy on patients with PTC, based on retrospective study of 356 cases. *Endocrine* **61**:1, 51-57. [Crossref]

1089. Shinji Ito, Shingo Iwano, Katsuhiko Kato, Shinji Naganawa. 2018. Predictive factors for the outcomes of initial I-131 low-dose ablation therapy to Japanese patients with differentiated thyroid cancer. *Annals of Nuclear Medicine* **32**:6, 418-424. [Crossref]

1090. F. Pacini, F. Basolo, R. Bellantone, G. Boni, M. A. Cannizzaro, M. De Palma, C. Durante, R. Elisei, G. Fadda, A. Frasoldati, L. Fugazzola, R. Guglielmi, C. P. Lombardi, P. Miccoli, E. Papini, G. Pellegriti, L. Pezzullo, A. Pontecorvi, M. Salvatori, E. Seregni, P. Vitti. 2018. Italian consensus on diagnosis and treatment of differentiated thyroid cancer: joint statements of six Italian societies. *Journal of Endocrinological Investigation* **41**:7, 849-876. [Crossref]

1091. Tetyana Maniuk, Ania Z. Kielar, Joseph P. O'Sullivan, Mohamed El-Khodary, Heather Lochnan, Bibianna Purgina, Michael J. Odell. 2018. Effect of Implementing Community of Practice Modified Thyroid Imaging Reporting and Data System on Reporting Adherence and Number of Thyroid Biopsies. *Academic Radiology* **25**:7, 915-924. [Crossref]

1092. Theodore Karatzas, Ioannis Vasileiadis. 2018. Authors' reply to the Letter to Editor "Thyroglobulin antibodies may serve as predictive marker for papillary thyroid carcinoma in indeterminate cytology: Acceptable or not?". *The American Journal of Surgery* **216**:1, 178-179. [Crossref]

Downloaded by Memorial Sloan Kettering from www.liebertpub.com at 08/14/19. For personal use only.

1093. Ioannis Vasileiadis, Georgios Boutzios, Maria Karalaki, Evangelos Misiakos, Theodore Karatzas. 2018. Papillary thyroid carcinoma of the isthmus: Total thyroidectomy or isthmusectomy?. *The American Journal of Surgery* **216**:1, 135-139. [Crossref]

1094. Tian Lv, Zhenglun Zhu, Xiaochun Fei, Jiqi Yan. 2018. Letter to the editor on "Vasovagal reflex emergency caused by Riedel's thyroiditis: A case report and review of the literature". Lymphocytic thyroiditis with multifocal non-tumor-associated psammoma bodies. *Asian Journal of Surgery* **41**:4, 399-400. [Crossref]

1095. Marina Carvalho S. Côrtes, Pedro Weslley Rosario, Gabriela Franco Mourão, Maria Regina Calsolari. 2018. Influence of chronic lymphocytic thyroiditis on the risk of persistent and recurrent disease in patients with papillary thyroid carcinoma and elevated antithyroglobulin antibodies after initial therapy. *Brazilian Journal of Otorhinolaryngology* **84**:4, 448-452. [Crossref]

1096. Luca Tagliaferri, Carlo Gobitti, Giuseppe Ferdinando Colloca, Luca Boldrini, Eleonora Farina, Carlo Furlan, Fabiola Paiar, Federica Vianello, Michela Basso, Lorenzo Cerizza, Fabio Monari, Gabriele Simontacchi, Maria Antonietta Gambacorta, Jacopo Lenkowicz, Nicola Dinapoli, Vito Lanzotti, Renzo Mazzarotto, Elvio Russi, Monica Mangoni. 2018. A new standardized data collection system for interdisciplinary thyroid cancer management: Thyroid COBRA. *European Journal of Internal Medicine* **53**, 73-78. [Crossref]

1097. Yunjun Wang, Qing Guan, Jun Xiang. 2018. Nomogram for predicting central lymph node metastasis in papillary thyroid microcarcinoma: A retrospective cohort study of 8668 patients. *International Journal of Surgery* **55**, 98-102. [Crossref]

1098. Sylvia L. Asa, Shereen Ezzat. 2018. The epigenetic landscape of differentiated thyroid cancer. *Molecular and Cellular Endocrinology* **469**, 3-10. [Crossref]

1099. Khaled Y. Ajarma, Ashraf F. Al-Faouri, Maysoon K. Al Ruhaibeh, Feras A. Almbaidien, Rima T. Nserat, Abdallah O. Al-Shawabkeh, Khaldon K. Al-Sarihin, Yousef A. Al-Harazi, Haitham S. Rbihat, Mohammad E. Aljbour. 2018. The risk of thyroid carcinoma in multinodular goiter compared to solitary thyroid nodules: A retrospective analysis of 600 patients. *Medical Journal Armed Forces India* . [Crossref]

1100. Haitham Mirghani, Krystle A. Lang Kuhs, Tim Waterboer. 2018. Biomarkers for early identification of recurrences in HPV-driven oropharyngeal cancer. *Oral Oncology* **82**, 108-114. [Crossref]

1101. Carmen Franco. 2018. Citopatología de tiroides. Punción por aguja fina. *Revista Médica Clínica Las Condes* **29**:4, 435-439. [Crossref]

1102. Anping Su, Yanping Gong, Wenshuang Wu, Rixiang Gong, Zhihui Li, Jingqiang Zhu. 2018. Does the number of parathyroid glands autotransplanted affect the incidence of hypoparathyroidism and recovery of parathyroid function?. *Surgery* **164**:1, 124-129. [Crossref]

1103. Flor Marina Medina Chamorro, José Abella Calle, Juliana Escobar Stein, Lina Merchancano, Andrés Mauricio Mendoza Briñez, Andrés Arturo Pulido Wilches. 2018. Experience of the Implementation of Rapid On-Site Evaluation in Ultrasound-Guided Fine-Needle Aspiration Biopsy of Thyroid Nodules. *Current Problems in Diagnostic Radiology* **47**:4, 220-224. [Crossref]

1104. Roshan M. Patel, Egor Parkhomenko, Kamaljot S. Kaler, Zhamshid Okhunov, Ralph V. Clayman, Jaime Landman. 2018. Renal mass biopsy. *Current Opinion in Urology* **28**:4, 360-363. [Crossref]

1105. Zhenying Guo, Minghua Ge, Ying-Hsia Chu, Sofia Asioli, Ricardo V. Lloyd. 2018. Recent Advances in the Classification of Low-grade Papillary-like Thyroid Neoplasms and Aggressive Papillary Thyroid Carcinomas. *Advances In Anatomic Pathology* **25**:4, 263-272. [Crossref]

1106. Kenichi Nakanishi, Toyone Kikumori, Noriyuki Miyajima, Yuko Takano, Sumiyo Noda, Dai Takeuchi, Shingo Iwano, Yasuhiro Kodera. 2018. Impact of Patient Age and Histological Type on Radioactive Iodine Avidity of Recurrent Lesions of Differentiated Thyroid Carcinoma. *Clinical Nuclear Medicine* **43**:7, 482-485. [Crossref]

1107. Guohua Shen, Ying Kou, Bin Liu, Rui Huang, Anren Kuang. 2018. BRAFV600E Mutation Does Not Significantly Affect the Efficacy of Radioiodine Therapy in Patients With Papillary Thyroid Carcinoma Without Known Distant Metastases. *Clinical Nuclear Medicine* **43**:7, e215-e219. [Crossref]

1108. Jae Won Cho, Yu-mi Lee, Yi Ho Lee, Suck Joon Hong, Jong Ho Yoon. 2018. Dynamic risk stratification system in post-lobectomy low-risk and intermediate-risk papillary thyroid carcinoma patients. *Clinical Endocrinology* **89**:1, 100-109. [Crossref]

1109. Dong Won Lee, Chang Myeon Song, Yong Bae Ji, Ji Young Kim, Yun Young Choi, Ji Young Lee, Kyung Tae. 2018. Efficacy of 18 F-fluorodeoxyglucose PET/CT for Detecting Lymph Node Metastasis in Papillary Thyroid Carcinoma. *OTO Open* **2**:3, 2473974X1878854. [Crossref]

1110. Mousumi Banerjee, David Reyes-Gastelum, Megan R Haymart. 2018. Treatment-Free Survival in Patients With Differentiated Thyroid Cancer. *The Journal of Clinical Endocrinology & Metabolism* **103**:7, 2720-2727. [Crossref]

1111. Howard B A Baum. 2018. Clinical Excellence in Endocrinology. *The Journal of Clinical Endocrinology & Metabolism* **103**:7, 2430-2435. [Crossref]

Downloaded by Memorial Sloan Kettering from www.liebertpub.com at 08/14/19. For personal use only.

1112. Min Ji Hong, Dong Gyu Na, Soo Jin Kim, Dae Sik Kim. 2018. Role of core needle biopsy as a first-line diagnostic tool for thyroid nodules: a retrospective cohort study. *Ultrasonography* **37**:3, 244-253. [Crossref]

1113. E Chaigneau, G Russ, B Royer, C Bigorgne, M Bienvenu-Perrard, A Rouxel, L Leenhardt, L Belin, C Buffet. 2018. TIRADS score is of limited clinical value for risk stratification of indeterminate cytological results. *European Journal of Endocrinology* **179**:1, 13-20. [Crossref]

1114. Christopher Perdoni, Clara Olcott, David C. Lieb, Daniel W. Karakla. 2018. DEVELOPMENT OF UPPER AERODIGESTIVE TRACT COMPLICATIONS IN PATIENTS WITH STAGE IV THYROID CANCER RECEIVING TYROSINE KINASE INHIBITORS. *AACE Clinical Case Reports* **4**:4, e270-e274. [Crossref]

1115. Jules Aljammal, Konstantinos Segkos, Abigail I. Wald, Yuri E. Nikiforov. 2018. POSITIVE PIK3CA (P.H1047R) MUTATION IN A BENIGN THYROID NODULE OF A PATIENT WITH MEN-1 SYNDROME. *AACE Clinical Case Reports* **4**:4, e320-e323. [Crossref]

1116. Rosemary Wong, Stephen G Farrell, Mathis Grossmann. 2018. Thyroid nodules: diagnosis and management. *Medical Journal of Australia* **209**:2, 92-98. [Crossref]

1117. Joon Ho Jang, So Hyun Park, Kyung soon Cho, Won Kyung Cho, Young Jin Suh, Byung Kyu Suh, Dae Kyun Koh. 2018. Cancer in thyroid nodules with fine-needle aspiration in Korean pediatric populations. *Annals of Pediatric Endocrinology & Metabolism* **23**:2, 94-98. [Crossref]

1118. Mayumi Endo, Jessica B. Liu, Marcelle Dougan, Jennifer S. Lee. 2018. Incidence of Second Malignancy in Patients with Papillary Thyroid Cancer from Surveillance, Epidemiology, and End Results 13 Dataset. *Journal of Thyroid Research* **2018**, 1-11. [Crossref]

1119. Narin Nasıroğlu İmga, Hakan Ataş, Dilek Berker, Gül Dağlar. 2018. Papiller tiroid mikrokarsinom ve makrokarsinomu olan hastalarda klinik, laboratuvar ve tümör özelliklerinin karşılaştırılması ve risk faktörlerinin değerlendirilmesi. *TURKISH JOURNAL of CLINICS and LABORATORY* . [Crossref]

1120. Mario Rotondi, Francesca Coperchini, Francesco Latrofa, Luca Chiovato. 2018. Role of Chemokines in Thyroid Cancer Microenvironment: Is CXCL8 the Main Player?. *Frontiers in Endocrinology* **9**. . [Crossref]

1121. Remco J. Molenaar, Surbhi Sidana, Tomas Radivoyevitch, Anjali S. Advani, Aaron T. Gerds, Hetty E. Carraway, Dana Angelini, Matt Kalaycio, Aziz Nazha, David J. Adelstein, Christian Nasr, Jaroslaw P. Maciejewski, Navneet S. Majhail, Mikkael A. Sekeres, Sudipto Mukherjee. 2018. Risk of Hematologic Malignancies After Radioiodine Treatment of Well-Differentiated Thyroid Cancer. *Journal of Clinical Oncology* **36**:18, 1831-1839. [Crossref]

1122. John Buscombe. 2018. Radioiodine and Its Relationship to Hematologic Malignancy: The Confounding Role of Supraphysiologic Thyroxine. *Journal of Clinical Oncology* **36**:18, 1884-1885. [Crossref]

1123. Michael C. Kreissl, Enrique Grande. 2018. Inconclusive Analysis of the Connection Between Secondary Hematologic Malignancies and Radioiodine Treatment. *Journal of Clinical Oncology* **36**:18, 1882-1883. [Crossref]

1124. Martina Sollini, Arturo Chiti. 2018. Concerns About the Risk of Myeloid Malignancies After Radioiodine Therapy in Thyroid Cancer. *Journal of Clinical Oncology* **36**:18, 1885-1886. [Crossref]

1125. Remco J. Molenaar, Surbhi Sidana, Tomas Radivoyevitch, Aaron T. Gerds, Hetty E. Carraway, Matt Kalaycio, Aziz Nazha, David J. Adelstein, Christian Nasr, Jaroslaw P. Maciejewski, Navneed S. Majhail, Mikkael A. Sekeres, Sudipto Mukherjee. 2018. Reply to A. Piccardo et al, E. Hindié et al, M.C. Kreissl et al, M. Doss, J. Buscombe, R. Fisher, M. Sollini et al, M. Lichtenstein, and M. Tulchinsky et al. *Journal of Clinical Oncology* **36**:18, 1889-1892. [Crossref]

1126. Mark Tulchinsky, Richard P. Baum, K.G. Bennet, Leonard M. Freeman, Ian Jong, Kalevi Kairemo, Carol S. Marcus, Renee M. Moadel, Paritosh Suman. 2018. Well-Founded Recommendations for Radioactive Iodine Treatment of Differentiated Thyroid Cancer Require Balanced Study of Benefits and Harms. *Journal of Clinical Oncology* **36**:18, 1887-1888. [Crossref]

1127. Bennett S. Greenspan. 2018. Radioiodine Treatment of Well-Differentiated Thyroid Cancer: Balancing Risks and Benefits. *Journal of Clinical Oncology* **36**:18, 1785-1787. [Crossref]

1128. Biermann Martin. 2018. Thyroid Ultrasound Classification System Accurately Predicts Risk of Malignancy in Subcentimeter Nodules. *Clinical Thyroidology* **30**:6, 273-276. [Citation] [Full Text] [PDF] [PDF Plus]

1129. Wang Tracy S.. 2018. Risk of Malignancy of Indeterminate Thyroid Nodules Needs Stratification by Subclassification of the Bethesda System for Reporting Thyroid Cytopathology. *Clinical Thyroidology* **30**:6, 277-279. [Citation] [Full Text] [PDF] [PDF Plus]

1130. Hershman Jerome M.. 2018. Giving RAI Within 3 Months After Thyroidectomy Results in Better Responses Than Delaying RAI Beyond 3 Months After Surgery. *Clinical Thyroidology* **30**:6, 284-286. [Citation] [Full Text] [PDF] [PDF Plus]

Downloaded by Memorial Sloan Kettering from www.liebertpub.com at 08/14/19. For personal use only.

1131. Verburg Frederik A., Mäder Uwe, Giovanella Luca, Luster Markus, Reiners Christoph. 2018. Low or Undetectable Basal Thyroglobulin Levels Obviate the Need for Neck Ultrasound in Differentiated Thyroid Cancer Patients After Total Thyroidectomy and 131I Ablation. *Thyroid* **28**:6, 722-728. [Abstract] [Full Text] [PDF] [PDF Plus]

1132. Chung Sae Rom, Choi Young Jun, Suh Chong Hyun, Kim Hwa Jung, Lee Jong Jin, Kim Won Gu, Sung Tae Yon, Lee Yu-mi, Song Dong Eun, Lee Jeong Hyun, Baek Jung Hwan. 2018. Thyroid Incidentalomas Detected on 18F-Fluorodeoxyglucose Positron Emission Tomography with Computed Tomography: Malignant Risk Stratification and Management Plan. *Thyroid* **28**:6, 762-768. [Abstract] [Full Text] [PDF] [PDF Plus] [Supplementary Material]

1133. Sawka Anna M., Carty Sally E., Haugen Bryan R., Hennessey James V., Kopp Peter A., Pearce Elizabeth N., Sosa Julie A., Tufano Ralph P., Jonklaas Jacqueline. 2018. American Thyroid Association Guidelines and Statements: Past, Present, and Future. *Thyroid* **28**:6, 692-706. [Abstract] [Full Text] [PDF] [PDF Plus]

1134. Davies Louise, Sugino Kiminori, Sugitani Iwao, Tomoda Chisato. 2018. Re: "High Thyroid Cancer Mortality Rate in Japan: A Result of Nonaggressive Treatment Strategy, or Just an Aging Population?" By Magner (Thyroid 2018;28:818–819). *Thyroid* **28**:6, 820-822. [Citation] [Full Text] [PDF] [PDF Plus]

1135. Amber L. Smith, Michelle D. Williams, John Stewart, Wei-Lien Wang, Savitri Krishnamurthy, Maria E. Cabanillas, Sinchita Roy-Chowdhuri. 2018. Utility of the BRAF p.V600E immunoperoxidase stain in FNA direct smears and cell block preparations from patients with thyroid carcinoma. *Cancer Cytopathology* **126**:6, 406-413. [Crossref]

1136. Bekir Kuru, Mehmet Kefeli. 2018. Risk factors associated with malignancy and with triage to surgery in thyroid nodules classified as Bethesda category IV (FN/SFN). *Diagnostic Cytopathology* **46**:6, 489-494. [Crossref]

1137. Samskruthi P. Murthy, Deepak Balasubramanian, Narayana Subramaniam, Gopalakrishnan Nair, Misha J. C. Babu, Priyank V. Rathod, Krishnakumar Thankappan, Subramania Iyer, Smitha Nalumackal Vijayan, Chaya Prasad, Vasantha Nair. 2018. Prevalence of adverse pathological features in 1 to 4 cm low-risk differentiated thyroid carcinoma. *Head & Neck* **40**:6, 1214-1218. [Crossref]

1138. Debora Lucia Seguro Danilovic, Evandro Sobroza de Mello, Eliana Salgado Turri Frazzato, Alda Wakamatsu, Alexander Augusto de Lima Jorge, Ana Oliveira Hoff, Suemi Marui. 2018. Oncogenic mutations in KEAP1 disturbing inhibitory Nrf2-Keap1 interaction: Activation of antioxidative pathway in papillary thyroid carcinoma. *Head & Neck* **40**:6, 1271-1278. [Crossref]

1139. Dong Wook Shin, Beomseok Suh, Hyunsun Lim, Jae Moon Yun, Sun Ok Song, Youngmin Park. 2018. J-Shaped Association Between Postoperative Levothyroxine Dosage and Fracture Risk in Thyroid Cancer Patients: A Retrospective Cohort Study. *Journal of Bone and Mineral Research* **33**:6, 1037-1043. [Crossref]

1140. YiJie Dong, MinJing Mao, WeiWei Zhan, JianQiao Zhou, Wei Zhou, JieJie Yao, YunYun Hu, Yan Wang, TingJun Ye. 2018. Size and Ultrasound Features Affecting Results of Ultrasound-Guided Fine-Needle Aspiration of Thyroid Nodules. *Journal of Ultrasound in Medicine* **37**:6, 1367-1377. [Crossref]

1141. Craig A. Bollig, David Lesko, David Gilley, Laura M. Dooley. 2018. The futility of intraoperative frozen section in the evaluation of follicular thyroid lesions. *The Laryngoscope* **128**:6, 1501-1505. [Crossref]

1142. T. Weber, S. Peth, R. Hummel. 2018. Chirurgie papillärer Mikrokarzinome der Schilddrüse. *Der Chirurg* **89**:6, 415-421. [Crossref]

1143. Wen-Jun Wei, Zhong-Wu Lu, Duo Wen, Tian Liao, Duan-Shu Li, Yu Wang, Yong-Xue Zhu, Zhuo-Ying Wang, Yi Wu, Yu-Long Wang, Qing-Hai Ji. 2018. The Positive Lymph Node Number and Postoperative N-Staging Used to Estimate Survival in Patients with Differentiated Thyroid Cancer: Results from the Surveillance, Epidemiology, and End Results Dataset (1988–2008). *World Journal of Surgery* **42**:6, 1762-1771. [Crossref]

1144. Brian H. H. Lang, Yu-Cho Woo, Keith Wan-Hang Chiu. 2018. Evaluation of pain during high-intensity focused ultrasound ablation of benign thyroid nodules. *European Radiology* **28**:6, 2620-2627. [Crossref]

1145. Brian H.H. Lang, Yu-Cho Woo, Keith Wan-Hang Chiu. 2018. Significance of hyperechoic marks observed during high-intensity focused ultrasound (HIFU) ablation of benign thyroid nodules. *European Radiology* **28**:6, 2675-2681. [Crossref]

1146. Bartosz Migda, Michal Migda, Marian S. Migda, Rafal Z. Slapa. 2018. Use of the Kwak Thyroid Image Reporting and Data System (K-TIRADS) in differential diagnosis of thyroid nodules: systematic review and meta-analysis. *European Radiology* **28**:6, 2380-2388. [Crossref]

1147. Anil K. D'Cruz, Richa Vaish, Abhishek Vaidya, Iain J. Nixon, Michelle D. Williams, Vincent Vander Poorten, Fernando López, Peter Angelos, Ashok R. Shaha, Avi Khafif, Alena Skalova, Alessandra Rinaldo, Jennifer L. Hunt, Alfio Ferlito. 2018. Molecular markers in well-differentiated thyroid cancer. *European Archives of Oto-Rhino-Laryngology* **275**:6, 1375-1384. [Crossref]

1148. Massimo Giusti, Miranda Mittica, Paola Comite, Claudia Campana, Stefano Gay, Michele Mussap. 2018. Anti-Müllerian hormone in pre-menopausal females after ablative radioiodine treatment for differentiated thyroid cancer. *Endocrine* **60**:3, 516-523. [Crossref]

Downloaded by Memorial Sloan Kettering from www.liebertpub.com at 08/14/19. For personal use only.

1149. A. Ernaga-Lorea, M. C. Hernández-Morhain, E. Anda-Apiñániz, J. J. Pineda-Arribas, I. Migueliz-Bermejo, N. Eguílaz-Esparza, A. Irigaray-Echarri. 2018. Prognostic value of change in anti-thyroglobulin antibodies after thyroidectomy in patients with papillary thyroid carcinoma. *Clinical and Translational Oncology* **20**:6, 740-744. [Crossref]

1150. S. H. Kim, J. G. Kang, C. S. Kim, S.-H. Ihm, M. G. Choi, H. J. Yoo, S. J. Lee. 2018. Gemigliptin, a novel dipeptidyl peptidase-IV inhibitor, exerts a synergistic cytotoxicity with the histone deacetylase inhibitor PXD101 in thyroid carcinoma cells. *Journal of Endocrinological Investigation* **41**:6, 677-689. [Crossref]

1151. Francesca Delle Cese, Pietro Locantore, Rocco Bellantone, Alfredo Pontecorvi. 2018. Indicazioni all'agoaspirato tiroideo. Cosa è cambiato. *L'Endocrinologo* **19**:3, 158-159. [Crossref]

1152. Giorgio Grani, Livia Lamartina, Cosimo Durante, Sebastiano Filetti, David S Cooper. 2018. Follicular thyroid cancer and Hürthle cell carcinoma: challenges in diagnosis, treatment, and clinical management. *The Lancet Diabetes & Endocrinology* **6**:6, 500-514. [Crossref]

1153. Ismael Mora-Guzmán, José Luis Muñoz de Nova, Cristina Marín-Campos, José Antonio Jiménez-Heffernan, Juan Julián Cuesta Pérez, Marcos Lahera Vargas, Emma Torres Mínguez, Elena Martín-Pérez. 2018. Efficiency of the Bethesda System for Thyroid Cytopathology. *Cirugía Española (English Edition)* **96**:6, 363-368. [Crossref]

1154. Ismael Mora-Guzmán, José Luis Muñoz de Nova, Cristina Marín-Campos, José Antonio Jiménez-Heffernan, Juan Julián Cuesta Pérez, Marcos Lahera Vargas, Emma Torres Mínguez, Elena Martín-Pérez. 2018. Rendimiento del sistema Bethesda en el diagnóstico citopatológico del nódulo tiroideo. *Cirugía Española* **96**:6, 363-368. [Crossref]

1155. M.-r. Kwon, J.H. Shin, S.Y. Hahn, Y.L. Oh, J.Y. Kwak, E. Lee, Y. Lim. 2018. Histogram analysis of greyscale sonograms to differentiate between the subtypes of follicular variant of papillary thyroid cancer. *Clinical Radiology* **73**:6, 591.e1-591.e7. [Crossref]

1156. Mikhail Fridman, Olga Krasko, Alfred King-yin Lam. 2018. Optimizing treatment for children and adolescents with papillary thyroid carcinoma in post-Chernobyl exposed region: The roles of lymph node dissections in the central and lateral neck compartments. *European Journal of Surgical Oncology* **44**:6, 733-743. [Crossref]

1157. Tong Tang, Jia Li, Lu Zheng, Lei Zhang, Jianing Shi. 2018. Risk factors of central lymph node metastasis in papillary thyroid carcinoma: A retrospective cohort study. *International Journal of Surgery* **54**, 129-132. [Crossref]

1158. Neeta J. Erinjeri, Norman G. Nicolson, Christine Deyholos, Reju Korah, Tobias Carling. 2018. Whole-Exome Sequencing Identifies Two Discrete Druggable Signaling Pathways in Follicular Thyroid Cancer. *Journal of the American College of Surgeons* **226**:6, 950-959.e5. [Crossref]

1159. Anastasios Maniakas, Louise Davies, Mark E. Zafereo. 2018. Thyroid Disease Around the World. *Otolaryngologic Clinics of North America* **51**:3, 631-642. [Crossref]

1160. Ashok R. Shaha, R. Michael Tuttle. 2018. Reply: Active Surveillance in Micropapillary Carcinoma. *Surgery* **163**:6, 1325-1329. [Crossref]

1161. Xiaoli Liu, Daqi Zhang, Guang Zhang, Lina Zhao, Le Zhou, Yantao Fu, Shijie Li, Yishen Zhao, Changlin Li, Che-Wei Wu, Feng-Yu Chiang, Gianlorenzo Dionigi, Hui Sun. 2018. Laryngeal nerve morbidity in 1.273 central node dissections for thyroid cancer. *Surgical Oncology* **27**:2, A21-A25. [Crossref]

1162. Xue-Pei Huang, Tian-Tian Ye, Li Zhang, Rui-Feng Liu, Xing-Jian Lai, Liang Wang, Meng Yang, Bo Zhang, Xiao-Yi Li, Zi-Wen Liu, Yu Xia, Yu-Xin Jiang. 2018. Sonographic features of papillary thyroid microcarcinoma predicting high-volume central neck lymph node metastasis. *Surgical Oncology* **27**:2, 172-176. [Crossref]

1163. Bin Song, Hao Wang, Yongqi Chen, Weiyan Liu, Ran Wei, Zedong Dai, Wenjuan Hu, Yi Ding, Lanyun Wang. 2018. Magnetic resonance imaging in the prediction of aggressive histological features in papillary thyroid carcinoma. *Medicine* **97**:26, e11279. [Crossref]

1164. Jiayi Xing, Jian Wang, Shanshan You, Jianchu Li. 2018. Ultrasound Identifies Broken Drainage Tube Postthyroidectomy. *Ultrasound Quarterly* **34**:2, 94-98. [Crossref]

1165. Yi Zheng, Shangyan Xu, Huili Kang, Weiwei Zhan. 2018. A Single-Center Retrospective Validation Study of the American College of Radiology Thyroid Imaging Reporting and Data System. *Ultrasound Quarterly* **34**:2, 77-83. [Crossref]

1166. Cansu G. Genç, Anneke P. Jilesen, Stefano Partelli, Massimo Falconi, Francesca Muffatti, Folkert J. van Kemenade, Susanne van Eeden, Joanne Verheij, Susan van Dieren, Casper H. J. van Eijck, Elisabeth J. M. Nieveen van Dijkum. 2018. A New Scoring System to Predict Recurrent Disease in Grade 1 and 2 Nonfunctional Pancreatic Neuroendocrine Tumors. *Annals of Surgery* **267**:6, 1148-1154. [Crossref]

1167. Mijin Kim, Minkyu Han, Jeong Hyun Lee, Dong Eun Song, Kyunggon Kim, Jung Hwan Baek, Young Kee Shong, Won Gu Kim. 2018. Tumour growth rate of follicular thyroid carcinoma is not different from that of follicular adenoma. *Clinical Endocrinology* **88**:6, 936-942. [Crossref]

Downloaded by Memorial Sloan Kettering from www.liebertpub.com at 08/14/19. For personal use only.

1168. Frederik A. Verburg, Uwe Mäder, Markus Luster, Christoph Reiners. 2018. The effects of the Union for International Cancer Control/American Joint Committee on Cancer Tumour, Node, Metastasis system version 8 on staging of differentiated thyroid cancer: a comparison to version 7. *Clinical Endocrinology* **88**:6, 950-956. [Crossref]

1169. Luca Giovanella, Mauro Imperiali, Arnoldo Piccardo, Monica Taborelli, Frederik Anton Verburg, Federica Daurizio, Pierpaolo Trimboli. 2018. Procalcitonin measurement to screen medullary thyroid carcinoma: A prospective evaluation in a series of 2705 patients with thyroid nodules. *European Journal of Clinical Investigation* **48**:6, e12934. [Crossref]

1170. Eun Ju Ha, Dong Gyu Na, Jung Hwan Baek, Jin Yong Sung, Ji-hoon Kim, So Young Kang. 2018. US Fine-Needle Aspiration Biopsy for Thyroid Malignancy: Diagnostic Performance of Seven Society Guidelines Applied to 2000 Thyroid Nodules. *Radiology* **287**:3, 893-900. [Crossref]

1171. Adnan Darr, Navid Hakim, Sangha Mitra Mummadi, Christopher Hobbs. 2018. Neck lumps. *InnovAiT: Education and inspiration for general practice* **11**:6, 322-329. [Crossref]

1172. Sait Sager, Esra Hatipoglu, Burcak Gunes, Sertac Asa, Lebriz Uslu, Kerim Sönmezoğlu. 2018. Comparison of day 3 and day 5 thyroglobulin results after thyrogen injection in differentiated thyroid cancer patients. *Therapeutic Advances in Endocrinology and Metabolism* **9**:6, 177-183. [Crossref]

1173. Bryan Tran, David Roshan, Earl Abraham, Laura Wang, Natalia Garibotto, James Wykes, Peter Campbell, Ardalan Ebrahimi. 2018. An Analysis of The American Joint Committee on Cancer 8th Edition T Staging System for Papillary Thyroid Carcinoma. *The Journal of Clinical Endocrinology & Metabolism* **103**:6, 2199-2206. [Crossref]

1174. Masha J Livhits, Eric J Kuo, Angela M Leung, Jianyu Rao, Mary Levin, Michael L Douek, Katrina R Beckett, Kyle A Zanocco, Dianne S Cheung, Yaroslav A Gofnung, Stephanie Smooke-Praw, Michael W Yeh. 2018. Gene Expression Classifier vs Targeted Next-Generation Sequencing in the Management of Indeterminate Thyroid Nodules. *The Journal of Clinical Endocrinology & Metabolism* **103**:6, 2261-2268. [Crossref]

1175. Talia Diker-Cohen, Dania Hirsch, Ilan Shimon, Gideon Bachar, Amit Akirov, Hadar Duskin-Bitan, Eyal Robenshtok. 2018. Impact of Minimal Extrathyroid Extension in Differentiated Thyroid Cancer: Systematic Review and Meta-Analysis. *The Journal of Clinical Endocrinology & Metabolism* **103**:6, 2100-2106. [Crossref]

1176. Fabio Maino, Raffaella Forleo, Martina Martinelli, Noemi Fralassi, Filomena Barbato, Tania Pilli, Marco Capezzone, Lucia Brilli, Cristina Ciuoli, Giovanni Di Cairano, Laura Nigi, Furio Pacini, Maria Grazia Castagna. 2018. Prospective Validation of ATA and ETA Sonographic Pattern Risk of Thyroid Nodules Selected for FNAC. *The Journal of Clinical Endocrinology & Metabolism* **103**:6, 2362-2368. [Crossref]

1177. A Lauria Pantano, E Maddaloni, S I Briganti, G Beretta Anguissola, E Perrella, C Taffon, A Palermo, P Pozzilli, S Manfrini, A Crescenzi. 2018. Differences between ATA, AACE/ACE/AME and ACR TI-RADS ultrasound classifications performance in identifying cytological high-risk thyroid nodules. *European Journal of Endocrinology* **178**:6, 595-603. [Crossref]

1178. Seong-Jang Kim, Sang-Woo Lee, Kyoungjune Pak, Sung-Ryul Shim. 2018. Diagnostic performance of PET in thyroid cancer with elevated anti-Tg Ab. *Endocrine-Related Cancer* **25**:6, 643-652. [Crossref]

1179. Flavio Carneiro Hojaij. 2018. How deep is our anxiety during treatment of thyroid cancer?. *Archives of Endocrinology and Metabolism* **62**:3, 273-274. [Crossref]

1180. Aysenur Ozderya, Kadriye Aydin, Naile Gokkaya, Sule Temizkan. 2018. PERCUTANEOUS ETHANOL INJECTION FOR BENIGN CYSTIC AND MIXED THYROID NODULES. *Endocrine Practice* **24**:6, 548-555. [Crossref]

1181. Shimei Ding, Wei Qu, Yang Jiao, Jing Zhang, Chunhong Zhang, Shuangsuo Dang. 2018. LncRNA SNHG12 promotes the proliferation and metastasis of papillary thyroid carcinoma cells through regulating wnt/β-catenin signaling pathway. *Cancer Biomarkers* **22**:2, 217-226. [Crossref]

1182. Tommaso Porcelli, Francesca Sessa, Angela Caputo, Christian Catalini, Domenico Salvatore. 2018. Teriparatide Replacement Therapy for Hypoparathyroidism During Treatment With Lenvatinib for Advanced Thyroid Cancer: A Case Report. *Frontiers in Endocrinology* **9**. . [Crossref]

1183. Miguel Melo, Adriana Gaspar da Rocha, Gustavo Cancela e Penna, Manuel Sobrinho-Simões, Paula Soares. 2018. Age-Associated Mortality Risk in Papillary Thyroid Cancer: Does BRAF Make a Real Difference?. *Journal of Clinical Oncology* **36**:14, 1455-1456. [Crossref]

1184. Hye Jin Baek, Dong Wook Kim, Gi Won Shin, Young Jin Heo, Jin Wook Baek, Yoo Jin Lee, Young Jun Cho, Ha Kyoung Park, Tae Kwun Ha, Do Hun Kim, Soo Jin Jung, Ji Sun Park, Ki Jung Ahn. 2018. Ultrasonographic Features of Papillary Thyroid Carcinomas According to Their Subtypes. *Frontiers in Endocrinology* **9**. . [Crossref]

1185. Jose Higino Steck, Elaine Stabenow, Gustavo Baldove Bettoni, Samuel Steck, Claudio Roberto Cernea. 2018. Accuracy of sentinel lymph node mapping in detecting occult neck metastasis in papillary thyroid carcinoma. *Archives of Endocrinology and Metabolism* . [Crossref]

Downloaded by Memorial Sloan Kettering from www.liebertpub.com at 08/14/19. For personal use only.

1186. Shih-Yi Lin, Cheng-Li Lin, Hsien-Te Chen, Chia-Hung Kao. 2018. Risk of osteoporosis in thyroid cancer patients using levothyroxine: a population-based study. *Current Medical Research and Opinion* **34**:5, 805-812. [Crossref]

1187. Amanda Doubleday, Rebecca S. Sippel. 2018. Surgical options for thyroid cancer and post-surgical management. *Expert Review of Endocrinology & Metabolism* **13**:3, 137-148. [Crossref]

1188. Fish Stephanie A.. 2018. Using the American College of Radiology Thyroid Imaging Reporting and Data System Will Decrease the Number of Thyroid Nodule Biopsies While Improving Diagnostic Accuracy. *Clinical Thyroidology* **30**:5, 206-209. [Citation] [Full Text] [PDF] [PDF Plus]

1189. Livhits Masha J., Yeh Michael W.. 2018. Minimal Extrathyroidal Extension Carries a Modest Increase for Recurrence but Not Mortality in Differentiated Thyroid Cancer. *Clinical Thyroidology* **30**:5, 210-212. [Citation] [Full Text] [PDF] [PDF Plus]

1190. Leung Angela M.. 2018. Radioactive Iodine Ablation Decreases Serum Anti-Müllerian Hormone Concentrations (as a Marker of Ovarian Reserve) in Women with Thyroid Cancer. *Clinical Thyroidology* **30**:5, 223-225. [Citation] [Full Text] [PDF] [PDF Plus]

1191. Buj Raquel, Mallona Izaskun, Díez-Villanueva Anna, Zafon Carles, Mate José L., Roca Mireia, Puig-Domingo Manel, Reverter Jordi L., Mauricio Dídac, Peinado Miguel A., Jordà Mireia. 2018. Kallikreins Stepwise Scoring Reveals Three Subtypes of Papillary Thyroid Cancer with Prognostic Implications. *Thyroid* **28**:5, 601-612. [Abstract] [Full Text] [PDF] [PDF Plus] [Supplementary Material]

1192. Bongiovanni Massimo, Papadakis Georgios E., Rouiller Nathalie, Marino Laura, Lamine Faiza, Bisig Bettina, Ziadi Sonia, Sykiotis Gerasimos P.. 2018. The Bethesda System for Reporting Thyroid Cytopathology Explained for Practitioners: Frequently Asked Questions. *Thyroid* **28**:5, 556-565. [Abstract] [Full Text] [PDF] [PDF Plus]

1193. Athena L. Chen, Andrew A. Renshaw, William C. Faquin, Erik K. Alexander, Howard T. Heller, Edmund S. Cibas. 2018. Thyroid FNA biopsies comprised of abundant, mature squamous cells can be reported as benign: A cytologic study of 18 patients with clinical correlation. *Cancer Cytopathology* **126**:5, 336-341. [Crossref]

1194. Pedro Weslley Rosario. 2018. Glucose uptake evaluated by 18F-fluorodeoxyglucose positron emission tomography in noninvasive follicular thyroid neoplasm with papillary-like nuclear features. *Diagnostic Cytopathology* **46**:5, 456-457. [Crossref]

1195. Sann Y. Mon, Gregory Riedlinger, Collette E. Abbott, Raja Seethala, N. Paul Ohori, Marina N. Nikiforova, Yuri E. Nikiforov, Steven P. Hodak. 2018. Cancer risk and clinicopathological characteristics of thyroid nodules harboring thyroid-stimulating hormone receptor gene mutations. *Diagnostic Cytopathology* **46**:5, 369-377. [Crossref]

1196. Reese W. Randle, Maria F. Bates, David F. Schneider, Rebecca S. Sippel, Susan C. Pitt. 2018. Survival in patients with medullary thyroid cancer after less than the recommended initial operation. *Journal of Surgical Oncology* **117**:6, 1211-1216. [Crossref]

1197. Pingyan Jin, Huijuan Feng, Wei Ouyang, Juqing Wu, Pan Chen, Jing Wang, Yungang Sun, Jialang Xian, Liuhua Huang. 2018. Radiation dose rates of differentiated thyroid cancer patients after 131I therapy. *Radiation and Environmental Biophysics* **57**:2, 169-177. [Crossref]

1198. Nathalie Chereau, Etienne Dauzier, Gaëlle Godiris–Petit, Séverine Noullet, Isabelle Brocheriou, Laurence Leenhardt, Camille Buffet, Fabrice Menegaux. 2018. Risk of recurrence in a homogeneously managed pT3-differentiated thyroid carcinoma population. *Langenbeck's Archives of Surgery* **403**:3, 325-332. [Crossref]

1199. Adam Stangierski, Kosma Wolinski, Marek Ruchala. 2018. Shear wave elastography in the diagnostics of parathyroid adenomas–new application of the method. *Endocrine* **60**:2, 240-245. [Crossref]

1200. Jean L. Oosthuizen, Blair Walker, Emilija Todorovic, Hamid Masoudi, Sam M. Wiseman. 2018. The presence of papillary features in thyroid nodules diagnosed as atypia of undetermined significance or follicular lesion of undetermined significance increases cancer risk and should influence treatment. *The American Journal of Surgery* **215**:5, 819-823. [Crossref]

1201. Maite Domínguez Ayala, Amaia Expósito Rodríguez, Amaia Bilbao González, Pablo Mínguez Gabiña, Teresa Gutiérrez Rodríguez, Emilia Rodeño Ortiz de Zarate, Maitane García Carrillo, Borja Barrios Treviño. 2018. BRAF V600E Mutation in Papillary Thyroid Cancer and Its Effect on Postoperative Radioiodine (131 I) Therapy: Should We Modify Our Therapeutic Strategy?. *Cirugía Española (English Edition)* **96**:5, 276-282. [Crossref]

1202. Maite Domínguez Ayala, Amaia Expósito Rodríguez, Amaia Bilbao González, Pablo Mínguez Gabiña, Teresa Gutiérrez Rodríguez, Emilia Rodeño Ortiz de Zarate, Maitane García Carrillo, Borja Barrios Treviño. 2018. Mutación del gen BRAF V600E en el cáncer papilar de tiroides y su efecto en la terapia con yodo radiactivo (131 I) posquirúrgica: ¿deberíamos modificar nuestra estrategia terapéutica?. *Cirugía Española* **96**:5, 276-282. [Crossref]

1203. Marko Barjaktarović, Milica M. Janković, Marija Jeremić, Milovan Matović. 2018. Hybrid Vision-Fusion system for whole-body scintigraphy. *Computers in Biology and Medicine* **96**, 69-78. [Crossref]

1204. Yuchen Jin, Douglas Van Nostrand, Lingxiao Cheng, Min Liu, Libo Chen. 2018. Radioiodine refractory differentiated thyroid cancer. *Critical Reviews in Oncology/Hematology* **125**, 111-120. [Crossref]

Downloaded by Memorial Sloan Kettering from www.liebertpub.com at 08/14/19. For personal use only.

1205. Ignacio Bernabeu, Javier Aller, Cristina Álvarez-Escolá, Carmen Fajardo-Montañana, Ángeles Gálvez-Moreno, Cristina Guillín-Amarelle, Gemma Sesmilo. 2018. Criteria for diagnosis and postoperative control of acromegaly, and screening and management of its comorbidities: Expert consensus. *Endocrinología, Diabetes y Nutrición (English ed.)* **65**:5, 297-305. [Crossref]

1206. Ignacio Bernabeu, Javier Aller, Cristina Álvarez-Escolá, Carmen Fajardo-Montañana, Ángeles Gálvez-Moreno, Cristina Guillín-Amarelle, Gemma Sesmilo. 2018. Criterios para el diagnóstico y el control poscirugía de la acromegalia, y el cribado y el manejo de sus comorbilidades: recomendaciones de expertos. *Endocrinología, Diabetes y Nutrición* **65**:5, 297-305. [Crossref]

1207. McKayla J. Riggs, Joseph K. Kluesner, Caela R. Miller. 2018. Management of highly differentiated thyroid follicular carcinoma of ovarian origin with a minimally invasive approach. *Gynecologic Oncology Reports* **24**, 87-89. [Crossref]

1208. Andrew S. Griffin, Jason Mitsky, Upma Rawal, Abraham J. Bronner, Franklin N. Tessler, Jenny K. Hoang. 2018. Improved Quality of Thyroid Ultrasound Reports After Implementation of the ACR Thyroid Imaging Reporting and Data System Nodule Lexicon and Risk Stratification System. *Journal of the American College of Radiology* **15**:5, 743-748. [Crossref]

1209. Kowsalya Vellingiri, Ki-Hyun Kim, Anastasia Pournara, Akash Deep. 2018. Towards high-efficiency sorptive capture of radionuclides in solution and gas. *Progress in Materials Science* **94**, 1-67. [Crossref]

1210. Samer R. Rajjoub, Huan Yan, Natalie A. Calcatera, Kristine Kuchta, Chi-Hsiung E. Wang, Waseem Lutfi, Tricia A. Moo-Young, David J. Winchester, Richard A. Prinz. 2018. Thyroid lobectomy is not sufficient for T2 papillary thyroid cancers. *Surgery* **163**:5, 1134-1143. [Crossref]

1211. YanFang Wang, Fang Nie, Ting Liu, Dan Yang, Qi Li, Jing Li, AiLing Song. 2018. Revised Value of Contrast-Enhanced Ultrasound for Solid Hypo-Echoic Thyroid Nodules Graded with the Thyroid Imaging Reporting and Data System. *Ultrasound in Medicine & Biology* **44**:5, 930-940. [Crossref]

1212. Mahdi Haghighatafshar, Mehrnaz Ghaedian, Zahra Etemadi, Seyed M. Entezarmahdi, Tahereh Ghaedian. 2018. Pilocarpine effect on dose rate of salivary gland in differentiated thyroid carcinoma patients treated with radioiodine. *Nuclear Medicine Communications* **39**:5, 430-434. [Crossref]

1213. Yajing Zhang, Wenjuan Hua, Xiao Zhang, Jun Peng, Jiaqian Liang, Zairong Gao. 2018. The predictive value for excellent response to initial therapy in differentiated thyroid cancer. *Nuclear Medicine Communications* **39**:5, 405-410. [Crossref]

1214. Carolyn R. Chew, Tracey Lam, Steven T. F. Chan, Laura Chin-Lenn. 2018. Systematic differences between ultrasound and pathological evaluation of thyroid nodules: a method comparison study. *ANZ Journal of Surgery* **88**:5, 464-467. [Crossref]

1215. Anthony W Gannon, Jill E Langer, Richard Bellah, Sarah Ratcliffe, Jennifer Pizza, Sogol Mostoufi-Moab, Anne R Cappola, Andrew J Bauer. 2018. Diagnostic Accuracy of Ultrasound With Color Flow Doppler in Children With Thyroid Nodules. *The Journal of Clinical Endocrinology & Metabolism* **103**:5, 1958-1965. [Crossref]

1216. Di Wu, Haixia Guan. 2018. Letter to the Editor: "Decreasing Use of Radioactive Iodine for Low-Risk Thyroid Cancer in California, 1999 to 2015". *The Journal of Clinical Endocrinology & Metabolism* **103**:5, 2071-2072. [Crossref]

1217. Trevor E. Angell, Chirag M. Vyas, Justine A. Barletta, Edmund S. Cibas, Nancy L. Cho, Gerard M. Doherty, Atul A. Gawande, Brooke E. Howitt, Jeffrey F. Krane, Ellen Marqusee, Kyle C. Strickland, Erik K. Alexander, Francis D. Moore, Matthew A. Nehs. 2018. Reasons Associated with Total Thyroidectomy as Initial Surgical Management of an Indeterminate Thyroid Nodule. *Annals of Surgical Oncology* **25**:5, 1410-1417. [Crossref]

1218. Kwon Joong Na, Hongyoon Choi. 2018. Immune landscape of papillary thyroid cancer and immunotherapeutic implications. *Endocrine-Related Cancer* **25**:5, 523-531. [Crossref]

1219. Min Joon Park, Young Sik Choi, Hee Sung Song, Beom Su Kim. 2018. The Relationship between Ultrasonographic Features and Clinical Characteristics of Medullary Thyroid Carcinoma. *Clinical Ultrasound* **3**:1, 8-14. [Crossref]

1220. William D. Middleton, Sharlene A. Teefey, Carl C. Reading, Jill E. Langer, Michael D. Beland, Margaret M. Szabunio, Terry S. Desser. 2018. Comparison of Performance Characteristics of American College of Radiology TI-RADS, Korean Society of Thyroid Radiology TIRADS, and American Thyroid Association Guidelines. *American Journal of Roentgenology* **210**:5, 1148-1154. [Crossref]

1221. Mark Lupo, Richard Guttler, Zsofia Geck, Theresa R. Tonozzi, Anja Kammesheidt, Glenn D. Braunstein. 2018. IS MEASUREMENT OF CIRCULATING TUMOR DNA OF DIAGNOSTIC USE IN PATIENTS WITH THYROID NODULES?. *Endocrine Practice* **24**:5, 453-459. [Crossref]

1222. Zeinab Kordestani, Mojgan Sanjari, Moeinadin Safavi, Mahdieh Mashrouteh, Gholamreza Asadikaram, Maryam Fekri Soofi Abadi, Ali Mirzazadeh. 2018. ENHANCED BETA-CATENIN EXPRESSION IS ASSOCIATED WITH RECURRENCE OF PAPILLARY THYROID CARCINOMA. *Endocrine Practice* **24**:5, 411-418. [Crossref]

1223. Zeyad T. Sahli, Philip W. Smith, Christopher B. Umbricht, Martha A. Zeiger. 2018. Preoperative Molecular Markers in Thyroid Nodules. *Frontiers in Endocrinology* **9**. . [Crossref]

Downloaded by Memorial Sloan Kettering from www.liebertpub.com at 08/14/19. For personal use only.

1224. Sevil Tatlıdil, Ayşegül Akgün. 2018. FDG PET/BT görüntülemede tiroid bezinde rastlantısal saptanan fokal artmış FDG tutulumunun klinik önemi. *Ege Tıp Dergisi* . [Crossref]

1225. Marina N. Nikiforova, Stephanie Mercurio, Abigail I. Wald, Michelle Barbi de Moura, Keith Callenberg, Lucas Santana-Santos, William E. Gooding, Linwah Yip, Robert L. Ferris, Yuri E. Nikiforov. 2018. Analytical performance of the ThyroSeq v3 genomic classifier for cancer diagnosis in thyroid nodules. *Cancer* **124**:8, 1682-1690. [Crossref]

1226. Chang Hwan Ryu, Boram Park, Junsun Ryu, Youn Mi Ryu, Seong Ae Jo, You Jin Lee, Eun-Kyung Lee, Yul Hwangbo, Jungnam Joo, Yuh-Seog Jung. 2018. Development and Evaluation of a Korean Version of a Thyroid-Specific Quality-of-Life Questionnaire Scale in Thyroid Cancer Patients. *Cancer Research and Treatment* **50**:2, 405-415. [Crossref]

1227. Ji Hye Won, Ji Ye Lee, Hyun Sook Hong, Sun Hye Jeong. 2018. Thyroid nodules and cancer in children and adolescents affected by hashimoto's thyroiditis. *The British Journal of Radiology* **104**, 20180014. [Crossref]

1228. Pablo Valderrabano, Laila Khazai, Zachary J. Thompson, Marino E. Leon, Kristen J. Otto, Julie E. Hallanger-Johnson, J. Trad Wadsworth, Christine H. Chung, Barbara A. Centeno, Bryan McIver. 2018. Impact of oncogene panel results on surgical management of cytologically indeterminate thyroid nodules. *Head & Neck* **25**. . [Crossref]

1229. Hyun Kyung Lim, Dong Wook Kim, Jung Hwan Baek, Jung Yin Huh, Ji Hwa Ryu, Jin Yong Sung, Sung Hee Park. 2018. Factors influencing the outcome from ultrasonography-guided fine-needle aspiration of benign thyroid cysts and partially cystic thyroid nodules: A multicenter study. *Endocrine Research* **43**:2, 65-72. [Crossref]

1230. Thaís Gomes De Melo, Aglecio Luiz Souza, Elizabeth Ficher, Arlete Maria Fernandes, Ligia Vera Montali Da Assumpção, Sarah Monte Alegre, Denise Engelbrecht Zantut-Wittmann. 2018. Reduced insulin sensitivity in differentiated thyroid cancer patients with suppressed TSH. *Endocrine Research* **43**:2, 73-79. [Crossref]

1231. Hershman Jerome M.. 2018. During Active Surveillance of Papillary Thyroid Microcarcinomas Higher Serum TSH Is Associated with Nodule Growth. *Clinical Thyroidology* **30**:4, 156-158. [Citation] [Full Text] [PDF] [PDF Plus]

1232. Wang Tracy S.. 2018. Extent of Initial Surgery May Impact Overall Survival, Even for Low-Risk Papillary Thyroid Cancers. *Clinical Thyroidology* **30**:4, 162-164. [Citation] [Full Text] [PDF] [PDF Plus]

1233. Biermann Martin. 2018. Punctate Echogenic Foci with Comet-Tail Artifacts May Be Associated with Malignancy When Occurring in Solid Portions of a Thyroid Nodule. *Clinical Thyroidology* **30**:4, 171-174. [Citation] [Full Text] [PDF] [PDF Plus]

1234. Lim Joel Xue Yi, Nga Min En, Chan Dedrick Kok Hong, Tan Wee Boon, Parameswaran Rajeev, Ngiam Kee Yuan. 2018. Subclassification of Bethesda Atypical and Follicular Neoplasm Categories According to Nuclear and Architectural Atypia Improves Discrimination of Thyroid Malignancy Risk. *Thyroid* **28**:4, 511-521. [Abstract] [Full Text] [PDF] [PDF Plus]

1235. Yaish Iris, Azem Foad, Gutfeld Orit, Silman Zmira, Serebro Merav, Sharon Orli, Shefer Gabi, Limor Rona, Stern Naftali, Tordjman Karen M.. 2018. A Single Radioactive Iodine Treatment Has a Deleterious Effect on Ovarian Reserve in Women with Thyroid Cancer: Results of a Prospective Pilot Study. *Thyroid* **28**:4, 522-527. [Abstract] [Full Text] [PDF] [PDF Plus] [Supplementary Material]

1236. Ito Yasuhiro, Miyauchi Akira, Kudo Takumi, Oda Hitomi, Yamamoto Masatoshi, Sasai Hisanori, Masuoka Hiroo, Fukushima Mitsuhiro, Higashiyama Takuya, Kihara Minoru, Miya Akihiro. 2018. Trends in the Implementation of Active Surveillance for Low-Risk Papillary Thyroid Microcarcinomas at Kuma Hospital: Gradual Increase and Heterogeneity in the Acceptance of This New Management Option. *Thyroid* **28**:4, 488-495. [Abstract] [Full Text] [PDF] [PDF Plus]

1237. Kim Mijin, Jeon Min Ji, Oh Hye-Seon, Park Suyeon, Song Dong Eun, Sung Tae-Yon, Kim Tae Yong, Chung Ki-Wook, Kim Won Bae, Shong Young Kee, Lee Yu-Mi, Kim Won Gu. 2018. Prognostic Implication of N1b Classification in the Eighth Edition of the Tumor-Node-Metastasis Staging System of Differentiated Thyroid Cancer. *Thyroid* **28**:4, 496-503. [Abstract] [Full Text] [PDF] [PDF Plus] [Supplementary Material]

1238. Rosario Pedro Weslley. 2018. Re: "A Follow-Up Strategy for Patients with Excellent Response to Initial Therapy for Differentiated Thyroid Carcinoma" by Jeon et al. (Thyroid 2018;28:187–192). *Thyroid* **28**:4, 547-548. [Citation] [Full Text] [PDF] [PDF Plus]

1239. Wang Zhihong, Vyas Chirag M., Van Benschoten Olivia, Nehs Matt A., Moore Francis D. Jr., Marqusee Ellen, Krane Jeffrey F., Kim Matthew I., Heller Howard T., Gawande Atul A., Frates Mary C., Doubilet Peter M., Doherty Gerard M., Cho Nancy L., Cibas Edmund S., Benson Carol B., Barletta Justine A., Zavacki Ann Marie, Larsen P. Reed, Alexander Erik K., Angell Trevor E.. 2018. Quantitative Analysis of the Benefits and Risk of Thyroid Nodule Evaluation in Patients ≥70 Years Old. *Thyroid* **28**:4, 465-471. [Abstract] [Full Text] [PDF] [PDF Plus]

1240. Li-ou Han, Xin-yu Li, Ming-ming Cao, Yan Cao, Li-hong Zhou. 2018. Development and validation of an individualized diagnostic signature in thyroid cancer. *Cancer Medicine* **7**:4, 1135-1140. [Crossref]

1241. Jin Soo A. Song, Adam A. Dmytriw, Eugene Yu, Reza Forghani, Lorne Rotstein, David Goldstein, Colin S. Poon. 2018. Investigation of thyroid nodules: A practical algorithm and review of guidelines. *Head & Neck* **11**. . [Crossref]

Downloaded by Memorial Sloan Kettering from www.liebertpub.com at 08/14/19. For personal use only.

1242. Bo Ra Yang, Eun-Kyung Kim, Hee Jung Moon, Jung Hyun Yoon, Vivian Y. Park, Jin Young Kwak. 2018. Qualitative and Semiquantitative Elastography for the Diagnosis of Intermediate Suspicious Thyroid Nodules Based on the 2015 American Thyroid Association Guidelines. *Journal of Ultrasound in Medicine* **37**:4, 1007-1014. [Crossref]

1243. Dengke Teng, Guoqing Sui, Caimei Liu, Yu Wang, Yongxu Xia, Hui Wang. 2018. Long-term efficacy of ultrasound-guided low power microwave ablation for the treatment of primary papillary thyroid microcarcinoma: a 3-year follow-up study. *Journal of Cancer Research and Clinical Oncology* **144**:4, 771-779. [Crossref]

1244. Joon Ho Choi, Byung Hyun Byun, Ilhan Lim, Hansol Moon, Jihyun Park, Kyoung Jin Chang, Byung Il Kim, Chang Woon Choi, Sang Moo Lim. 2018. The Predictive Values of Lesion Size, F-18 FDG Avidity and I-131 Avidity for the Clinical Outcome of I-131 Treatment in Patients with Metastatic Differentiated Thyroid Carcinoma Only in the Lung. *Nuclear Medicine and Molecular Imaging* **52**:2, 135-143. [Crossref]

1245. Martina Tavarelli, Giulia Sapuppo, Dario Tumino, Romilda Masucci, Marco Russo, Sebastiano Squatrito, Maria Concetta Fornito, Gabriella Pellegriti. 2018. Ruolo della 18FDG PET nel follow-up del carcinoma differenziato della tiroide (CDT) in presenza di valori di Tireoglobulina (Tg) indosabili, AAT elevati e TBS post-131-I negativo: esperienza clinica in una paziente. *L'Endocrinologo* **19**:2, 105-106. [Crossref]

1246. Zhuoran Liu, Tian Lv, Cong Xie, Zhongmin Di. 2018. BRAF V600E gene mutation is associated with bilateral malignancy of papillary thyroid cancer. *The American Journal of the Medical Sciences* . [Crossref]

1247. Trina M. Sheedy. 2018. Evaluation and Management of Adult Neck Masses. *Physician Assistant Clinics* **3**:2, 271-284. [Crossref]

1248. Sean M. Siebert, R. Brooke Jeffrey, Adam J. Gomez, Aya Kamaya. 2018. Central echogenic areas in thyroid nodules: Diagnostic performance in prediction of papillary cancer. *European Journal of Radiology* **101**, 45-49. [Crossref]

1249. Jianhua Feng, Xiaoxiong Gan, Fei Shen, Wensong Cai, Bo Xu. 2018. The role of two tumor foci for predicting central lymph node metastasis in papillary thyroid carcinoma: A meta-analysis. *International Journal of Surgery* **52**, 166-170. [Crossref]

1250. K.P. Rooney, A.B. Miah, S.A. Bhide, M.T. Guerrero-Urbano, M.T. Sharabiani, K.L. Newbold, L. Grove, K.J. Harrington, C.M. Nutting. 2018. Intensity modulated radiotherapy in locally advanced thyroid cancer: Outcomes of a sequential phase I dose-escalation study. *Radiotherapy and Oncology* **127**:1, 43-48. [Crossref]

1251. Frédéric Borel, Niki Christou, Olivier Marret, Muriel Mathonnet, Cécile Caillard, Sahar Bannani, Delphine Drui, Florent Espitalier, Claire Blanchard, Eric Mirallié. 2018. Long-term voice quality outcomes after total thyroidectomy: a prospective multicenter study. *Surgery* **163**:4, 796-800. [Crossref]

1252. Electron Kebebew. 2018. Thyroid Cancer: Is It All in the Genes?. *JNCI: Journal of the National Cancer Institute* **110**:4, 327-328. [Crossref]

1253. Catherine E. Mercado, Peter A. Drew, Christopher G. Morris, Peter T. Dziegielewski, William M. Mendenhall, Robert J. Amdur. 2018. Positive Surgical Margins in Favorable-Stage Differentiated Thyroid Cancer. *American Journal of Clinical Oncology* 1. [Crossref]

1254. Soo Chin Kim, Ji-hoon Kim, Jae-Kyung Won, Eun Jae Chung. 2018. Asymptomatic intrathyroidal pyriform sinus fistula mimicking thyroid cancer. *Medicine* **97**:16, e0488. [Crossref]

1255. Wolfgang Roll, Matthias Weckesser, Monika Pöppelmann, Manfred Schiborr, Michael Schäfers, Kambiz Rahbar. 2018. 99mTc-MDP SPECT-CT and Ultrasound in the Diagnosis and Staging of Thyroid Metastasis From Osteosarcoma. *Clinical Nuclear Medicine* **43**:4, e109-e110. [Crossref]

1256. Rong Zhang, Qiufang Liu, Hui Cui, Xiuying Wang, Shaoli Song, Gang Huang, Dagan Feng. Thyroid classification via new multi-channel feature association and learning from multi-modality MRI images 277-280. [Crossref]

1257. M. A. Saieg, B. Barbosa, J. Nishi, A. Ferrari, F. Costa. 2018. The impact of repeat FNA in non-diagnostic and indeterminate thyroid nodules: A 5-year single-centre experience. *Cytopathology* **29**:2, 196-200. [Crossref]

1258. I. Paajanen, S. Metso, P. Jaatinen, I. Kholová. 2018. Thyroid FNA diagnostics in a real-life setting: Experiences of the implementation of the Bethesda system in Finland. *Cytopathology* **29**:2, 189-195. [Crossref]

1259. Franklin N. Tessler, William D. Middleton, Edward G. Grant. 2018. Thyroid Imaging Reporting and Data System (TI-RADS): A User's Guide. *Radiology* **287**:1, 29-36. [Crossref]

1260. Jenny K. Hoang, William D. Middleton, Alfredo E. Farjat, Jill E. Langer, Carl C. Reading, Sharlene A. Teefey, Nicole Abinanti, Fernando J. Boschini, Abraham J. Bronner, Nirvikar Dahiya, Barbara S. Hertzberg, Justin R. Newman, Daniel Scanga, Robert C. Vogler, Franklin N. Tessler. 2018. Reduction in Thyroid Nodule Biopsies and Improved Accuracy with American College of Radiology Thyroid Imaging Reporting and Data System. *Radiology* **287**:1, 185-193. [Crossref]

Downloaded by Memorial Sloan Kettering from www.liebertpub.com at 08/14/19. For personal use only.

1261. Elizabeth J de Koster, Lioe-Fee de Geus-Oei, Olaf M Dekkers, Ilse van Engen-van Grunsven, Jaap Hamming, Eleonora P M Corssmit, Hans Morreau, Abbey Schepers, Jan Smit, Wim J G Oyen, Dennis Vriens. 2018. Diagnostic Utility of Molecular and Imaging Biomarkers in Cytological Indeterminate Thyroid Nodules. *Endocrine Reviews* **39**:2, 154-191. [Crossref]

1262. Agnese Persichetti, Enrico Di Stasio, Rinaldo Guglielmi, Giancarlo Bizzarri, Silvia Taccogna, Irene Misischi, Filomena Graziano, Lucilla Petrucci, Antonio Bianchini, Enrico Papini. 2018. Predictive Value of Malignancy of Thyroid Nodule Ultrasound Classification Systems: A Prospective Study. *The Journal of Clinical Endocrinology & Metabolism* **103**:4, 1359-1368. [Crossref]

1263. Stephanie L Samuels, Lea F Surrey, Colin P Hawkes, Madeline Amberge, Sogol Mostoufi-Moab, Jill E Langer, N Scott Adzick, Ken Kazahaya, Tricia Bhatti, Zubair Baloch, Virginia A LiVolsi, Andrew J Bauer. 2018. Characteristics of Follicular Variant Papillary Thyroid Carcinoma in a Pediatric Cohort. *The Journal of Clinical Endocrinology & Metabolism* **103**:4, 1639-1648. [Crossref]

1264. Kyle Zanocco, David J. Kaltman, James X. Wu, Abbey Fingeret, Keith S. Heller, James A. Lee, Michael W. Yeh, Julie Ann Sosa, Cord Sturgeon. 2018. Cost Effectiveness of Routine Laryngoscopy in the Surgical Treatment of Differentiated Thyroid Cancer. *Annals of Surgical Oncology* **25**:4, 949-956. [Crossref]

1265. Grace C. H. Yang, Karen O. Fried. 2018. Pathologic basis of the sonographic differences between thyroid cancer and noninvasive follicular thyroid neoplasm with papillary-like nuclear features. *Ultrasonography* **37**:2, 157-163. [Crossref]

1266. Brian H. Lang, Arnold L. H. Wu. 2018. The efficacy and safety of high-intensity focused ultrasound ablation of benign thyroid nodules. *Ultrasonography* **37**:2, 89-97. [Crossref]

1267. Amandine Berdelou, Livia Lamartina, Michele Klain, Sophie Leboulleux, Martin Schlumberger, _ _. 2018. Treatment of refractory thyroid cancer. *Endocrine-Related Cancer* **25**:4, R209-R223. [Crossref]

1268. Mario Vaisman. 2018. Improving care of patients with low-risk differentiated thyroid carcinoma. *Archives of Endocrinology and Metabolism* **62**:2, 129-130. [Crossref]

1269. Sean M. Siebert, Adam J. Gomez, Tie Liang, Ali M. Tahvildari, Terry S. Desser, R. Brooke Jeffrey, Aya Kamaya. 2018. Diagnostic Performance of Margin Features in Thyroid Nodules in Prediction of Malignancy. *American Journal of Roentgenology* **210**:4, 860-865. [Crossref]

1270. N.U. Patel, K.E. Lind, K. McKinney, T.J. Clark, S.S. Pokharel, J.M. Meier, E.R. Stamm, K. Garg, B. Haugen. 2018. Clinical Validation of a Predictive Model for the Presence of Cervical Lymph Node Metastasis in Papillary Thyroid Cancer. *American Journal of Neuroradiology* **39**:4, 756-761. [Crossref]

1271. Dong Wook Kim, Gi Won Shin, Yoo Jin Lee, Soo Jin Jung, Hye Jin Baek, Taewoo Kang. 2018. SONOGRAPHIC FEATURES OF MULTIFOCAL PAPILLARY THYROID CARCINOMAS. *Endocrine Practice* **24**:4, 351-360. [Crossref]

1272. Michiya Nishino, Marina Nikiforova. 2018. Update on Molecular Testing for Cytologically Indeterminate Thyroid Nodules. *Archives of Pathology & Laboratory Medicine* **142**:4, 446-457. [Crossref]

1273. Yueye Huang, Shen Qu, Guangwu Zhu, Fei Wang, Rengyun Liu, Xiaopei Shen, David Viola, Rossella Elisei, Efisio Puxeddu, Laura Fugazzola, Carla Colombo, Barbara Jarzab, Agnieszka Czarniecka, Alfred K Lam, Caterina Mian, Federica Vianello, Linwah Yip, Garcilaso Riesco-Eizaguirre, Pilar Santisteban, Christine J O'Neill, Mark S Sywak, Roderick Clifton-Bligh, Bela Bendlova, Vlasta Sýkorová, Mingzhao Xing. 2018. BRAF V600E Mutation-Assisted Risk Stratification of Solitary Intrathyroidal Papillary Thyroid Cancer for Precision Treatment. *JNCI: Journal of the National Cancer Institute* **110**:4, 362-370. [Crossref]

1274. Vladimir A. Solodkiy, Dmitry K. Fomin, Dmitry A. Galushko, Hayk G. Asmaryan. 2018. The predictors of "hidden" central neck lymph node metastasis in patients with differentiated thyroid cancer. *Clinical and experimental thyroidology* **14**:1, 19-24. [Crossref]

1275. Marina E. Boriskova, Ulyana V. Farafonova, Polina A. Pankova, Mikhail A. Bikov, Elmira A. Ramazanova. 2018. Surgical tactics optimization for treatment of BRAF positive papillary thyroid cancer. *Clinical and experimental thyroidology* **14**:1, 25-33. [Crossref]

1276. Fausto Fama, Alessandro Sindoni, Marco Cicciu, Francesca Polito, Arnaud Piquard, Olivier Saint-Marc, Maria Gioffre′-Florio, Salvatore Benvenga. 2018. Preoperatively undiagnosed papillary thyroid carcinoma in patients thyroidectomized for benign multinodular goiter. *Archives of Endocrinology and Metabolism* . [Crossref]

1277. Bruno Mussoi de Macedo, Rogério F. Izquierdo, Lenara Golbert, Erika L. Souza Meyer. 2018. Reliability of Thyroid Imaging Reporting and Data System (TI-RADS), and ultrasonographic classification of the American Thyroid Association (ATA) in differentiating benign from malignant thyroid nodules. *Archives of Endocrinology and Metabolism* . [Crossref]

1278. Fabián Pitoia, Fernando Jerkovich, Carolina Urciuoli, Florencia Falcón, Andrea Páes de Lima. 2018. Impact of historic histopathologic sample review on the risk of recurrence in patients with differentiated thyroid cancer. *Archives of Endocrinology and Metabolism* . [Crossref]

1279. Shirlei Kugler Aiçar Súss, Cleo Otaviano Mesa, Gisah Amaral de Carvalho, Fabíola Yukiko Miasaki, Carolina Perez Chaves, Dominique Cochat Fuser, Rossana Corbo, Denise Momesso, Daniel A. Bulzico, Hans Graf, Fernanda Vaisman. 2018. Clinical

Downloaded by Memorial Sloan Kettering from www.liebertpub.com at 08/14/19. For personal use only.

outcomes of low and intermediate risk differentiated thyroid cancer patients treated with 30mCi for ablation or without radioactive iodine therapy. *Archives of Endocrinology and Metabolism* . [Crossref]

1280. Fernando A. Batista, Marjory A. Marcello, Mariana B. Martins, Karina C. Peres, Ulieme O. Cardoso, Aline C. D. N. Silva, Natassia E. Bufalo, Fernando A. Soares, Márcio J. da Silva, Lígia V. Assumpção, Laura S. Ward. 2018. Diagnostic utility of DREAM gene mRNA levels in thyroid tumours. *Archives of Endocrinology and Metabolism* . [Crossref]

1281. Chien-Liang Liu, Po-Sheng Yang, Ming-Nan Chien, Yuan-Ching Chang, Chi-Hsin Lin, Shih-Ping Cheng. 2018. Expression of serine peptidase inhibitor Kunitz type 1 in differentiated thyroid cancer. *Histochemistry and Cell Biology* **159**. . [Crossref]

1282. Biermann Martin, Brauckhoff Katrin. 2018. Most "Recurrences" of Thyroid Cancer Represent Persistent Rather Than Recurrent Disease. *Clinical Thyroidology* **30**:3, 108-111. [Citation] [Full Text] [PDF] [PDF Plus]

1283. Wang Tracy S.. 2018. Preoperative Ultrasonography Guides the Extent of Thyroidectomy for Papillary Thyroid Cancer. *Clinical Thyroidology* **30**:3, 119-121. [Citation] [Full Text] [PDF] [PDF Plus]

1284. Hershman Jerome M.. 2018. Highly Sensitive Thyroglobulin Assays Are Reliable Indicators of Persistent Disease in Thyroid Cancer Patients with Thyroglobulin Antibody. *Clinical Thyroidology* **30**:3, 122-125. [Citation] [Full Text] [PDF] [PDF Plus]

1285. Fish Stephanie A.. 2018. Tumor Size and Nodal Stage Predict Recurrence and Timing of Ultrasonography in Papillary Thyroid Carcinoma Patients. *Clinical Thyroidology* **30**:3, 126-128. [Citation] [Full Text] [PDF] [PDF Plus]

1286. Latrofa Francesco, Ricci Debora, Bottai Sara, Brozzi Federica, Chiovato Luca, Piaggi Paolo, Marinò Michele, Vitti Paolo. 2018. Effect of Thyroglobulin Autoantibodies on the Metabolic Clearance of Serum Thyroglobulin. *Thyroid* **28**:3, 288-294. [Abstract] [Full Text] [PDF] [PDF Plus]

1287. Lubitz Carrie C., Zhan Tiannan, Gunda Viswanath, Amin Salma, Gigliotti Benjamin J., Fingeret Abbey L., Holm Tammy M., Wachtel Heather, Sadow Peter M., Wirth Lori J., Sullivan Ryan J., Panka David J., Parangi Sareh. 2018. Circulating BRAFV600E Levels Correlate with Treatment in Patients with Thyroid Carcinoma. *Thyroid* **28**:3, 328-339. [Abstract] [Full Text] [PDF] [PDF Plus]

1288. Kim Mijin, Kim Tae Hyuk, Shin Dong Yeob, Lim Dong Jun, Kim Eui Young, Kim Won Bae, Chung Jae Hoon, Shong Young Kee, Kim Bo Hyun, Kim Won Gu, on behalf of Korean Thyroid Cancer Study Group (KTCSG). 2018. Tertiary Care Experience of Sorafenib in the Treatment of Progressive Radioiodine-Refractory Differentiated Thyroid Carcinoma: A Korean Multicenter Study. *Thyroid* **28**:3, 340-348. [Abstract] [Full Text] [PDF] [PDF Plus] [Supplementary Material]

1289. Jianyong Lei, Jinjing Zhong, Zhihui Li, Tao Wei, Rixiang Gong, Jingqiang Zhu. 2018. A Nomogram Based on the Characteristics of Metastatic Lymph Nodes to Predict Papillary Thyroid Carcinoma Recurrence. *Thyroid* **28**:3, 301-310. [Abstract] [Full Text] [PDF] [PDF Plus]

1290. Aghajani Marra, Graham Susannah, McCafferty Charles, Shaheed Christina Abdel, Roberts Tara, DeSouza Paul, Yang Tao, Niles Navin. 2018. Clinicopathologic and Prognostic Significance of Programmed Cell Death Ligand 1 Expression in Patients with Non-Medullary Thyroid Cancer: A Systematic Review and Meta-Analysis. *Thyroid* **28**:3, 349-361. [Abstract] [Full Text] [PDF] [PDF Plus]

1291. Nguyen Xuan V., Roy Choudhury Kingshuk, Tessler Franklin N., Hoang Jenny K.. 2018. Effect of Tumor Size on Risk of Metastatic Disease and Survival for Thyroid Cancer: Implications for Biopsy Guidelines. *Thyroid* **28**:3, 295-300. [Abstract] [Full Text] [PDF] [PDF Plus]

1292. J. Vidal Fortuny, S. M. Sadowski, V. Belfontali, S. Guigard, A. Poncet, F. Ris, W. Karenovics, F. Triponez. 2018. Randomized clinical trial of intraoperative parathyroid gland angiography with indocyanine green fluorescence predicting parathyroid function after thyroid surgery. *British Journal of Surgery* **105**:4, 350-357. [Crossref]

1293. Mara Y. Roth, Robert L. Witt, David L. Steward. 2018. Molecular testing for thyroid nodules: Review and current state. *Cancer* **124**:5, 888-898. [Crossref]

1294. Mary C. Frates, Carol B. Benson, David M. Dorfman, Edmund S. Cibas, Stephen A. Huang. 2018. Ectopic Intrathyroidal Thymic Tissue Mimicking Thyroid Nodules in Children. *Journal of Ultrasound in Medicine* **37**:3, 783-791. [Crossref]

1295. Soh-Ching Ng, Sheng-Fong Kuo, Chung-Ching Hua, Bie-Yu Huang, Kun-Chun Chiang, Yin-Yi Chu, Chuen Hsueh, Jen-Der Lin. 2018. Differentiation of the Follicular Variant of Papillary Thyroid Carcinoma From Classic Papillary Thyroid Carcinoma: An Ultrasound Analysis and Complement to Fine-Needle Aspiration Cytology. *Journal of Ultrasound in Medicine* **37**:3, 667-674. [Crossref]

1296. Feng Mao, Hui-Xiong Xu, Hang Zhou, Xiao-Wan Bo, Xiao-Long Li, Dan-Dan Li, Bo-Ji Liu, Yi-Feng Zhang, Jun-Mei Xu, Shen Qu. 2018. Assessment of Virtual Touch Tissue Imaging Quantification and the Ultrasound Thyroid Imaging Reporting and Data System in Patients With Thyroid Nodules Referred for Biopsy. *Journal of Ultrasound in Medicine* **37**:3, 725-736. [Crossref]

Downloaded by Memorial Sloan Kettering from www.liebertpub.com at 08/14/19. For personal use only.

1297. Chelsea Tan, Ilona Lavender, Amanda Naismith, Qui Nguyen, Ronnie Ptasznik, Dee Nandurkar, Jennifer Wong, Beena Kumar, Peter J. Fuller, Peter R. Coombs, Michael Mond. 2018. Evaluation of a dedicated ultrasound fine needle aspiration service for thyroid nodules. *Sonography* **5**:1, 3-11. [Crossref]

1298. Stephanie Allelein, K. Lorenz, Matthias Schott. 2018. Metastasiertes Schilddrüsenkarzinom. *best practice onkologie* **13**:2, 62-72. [Crossref]

1299. Ghobad Azizi, James M. Keller, Michelle L. Mayo, Kelé Piper, David Puett, Karly M. Earp, Carl D. Malchoff. 2018. Shear wave elastography and Afirma™ gene expression classifier in thyroid nodules with indeterminate cytology: a comparison study. *Endocrine* **59**:3, 573-584. [Crossref]

1300. Yuan Qin, Wei Sun, Hao Zhang, Ping Zhang, Zhihong Wang, Wenwu Dong, Liang He, Ting Zhang, Liang Shao, Wenqian Zhang, Changhao Wu. 2018. LncRNA GAS8-AS1 inhibits cell proliferation through ATG5-mediated autophagy in papillary thyroid cancer. *Endocrine* **59**:3, 555-564. [Crossref]

1301. Kyle C. Strickland, Markus Eszlinger, Ralf Paschke, Trevor E. Angell, Erik K. Alexander, Ellen Marqusee, Matthew A. Nehs, Vickie Y. Jo, Alarice Lowe, Marina Vivero, Monica Hollowell, Xiaohua Qian, Tad Wieczorek, Christopher A. French, Lisa A. Teot, Edmund S. Cibas, Neal I. Lindeman, Jeffrey F. Krane, Justine A. Barletta. 2018. Molecular Testing of Nodules with a Suspicious or Malignant Cytologic Diagnosis in the Setting of Non-Invasive Follicular Thyroid Neoplasm with Papillary-Like Nuclear Features (NIFTP). *Endocrine Pathology* **29**:1, 68-74. [Crossref]

1302. Pierpaolo Trimboli, Franco Fulciniti, Elisabetta Merlo, Jessica Barizzi, Luca Mazzucchelli, Luca Giovanella. 2018. Histologic Outcome of Indeterminate Thyroid Nodules Classified at Low or High Risk. *Endocrine Pathology* **29**:1, 75-79. [Crossref]

1303. Misbah Khan, Aamir Ali Syed, Amina Iqbal Khan, Syed Raza Hussain, Namra Urooj. 2018. Association of tumor size and focality with recurrence/persistence in papillary thyroid cancer patients treated with total thyroidectomy along with radioactive-iodine ablation and TSH suppression. *Updates in Surgery* **70**:1, 121-127. [Crossref]

1304. M. Leo, E. Sabini, I. Ionni, A. Sframeli, B. Mazzi, F. Menconi, E. Molinaro, F. Bianchi, F. Brozzi, P. Santini, R. Elisei, M. Nardi, P. Vitti, C. Marcocci, M. Marinò. 2018. Use of low-dose radioiodine ablation for Graves' orbitopathy: results of a pilot, perspective study in a small series of patients. *Journal of Endocrinological Investigation* **41**:3, 357-361. [Crossref]

1305. E. Petnehazy, G. Reicht, J. Hebenstreit, R. Stacher, S. Lax, P. Mazal, W. Buchinger. 2018. Individualisierte Abklärung und Therapie von Schilddrüsenmalignomen im Sinne einer personalisierten Medizin. *Journal für Klinische Endokrinologie und Stoffwechsel* **11**:1, 19-22. [Crossref]

1306. Coriolan Lebreton, Abir Al Ghuzlan, Anne Floquet, Michèle Kind, Sophie Leboulleux, Yann Godbert. 2018. Cancer thyroïdien sur struma ovarii : généralités et principes de prise en charge. *Bulletin du Cancer* **105**:3, 281-289. [Crossref]

1307. Jaime Jacqueline Jayapalan, Cheng-Siang Lee, Ching Chin Lee, Khoon Leong Ng, Sarni Mat Junit, Onn Haji Hashim. 2018. iTRAQ analysis of urinary proteins: Potential use of gelsolin and osteopontin to distinguish benign thyroid goiter from papillary thyroid carcinoma. *Clinical Biochemistry* **53**, 127-131. [Crossref]

1308. Christelle de la Fouchardière, Myriam Decaussin-Petrucci, Julien Berthiller, Françoise Descotes, Jonathan Lopez, Jean-Christophe Lifante, Jean-Louis Peix, Anne-Laure Giraudet, Armelle Delahaye, Sandrine Masson, Claire Bournaud-Salinas, Françoise Borson Chazot. 2018. Predictive factors of outcome in poorly differentiated thyroid carcinomas. *European Journal of Cancer* **92**, 40-47. [Crossref]

1309. P. Asimakopoulos, I.J. Nixon. 2018. Surgical management of primary thyroid tumours. *European Journal of Surgical Oncology* **44**:3, 321-326. [Crossref]

1310. P. Angelos, D.M. Hartl, J.P. Shah, I.J. Nixon, R.P. Owen, A. Rinaldo, J.P. Rodrigo, A.R. Shaha, C.E. Silver, C. Suárez, A. Ferlito. 2018. Ethical issues in non-intervention trials for thyroid cancer. *European Journal of Surgical Oncology* **44**:3, 316-320. [Crossref]

1311. Y. Ito, A. Miyauchi, H. Oda. 2018. Low-risk papillary microcarcinoma of the thyroid: A review of active surveillance trials. *European Journal of Surgical Oncology* **44**:3, 307-315. [Crossref]

1312. K.J. Kovatch, C.W. Hoban, A.G. Shuman. 2018. Thyroid cancer surgery guidelines in an era of de-escalation. *European Journal of Surgical Oncology* **44**:3, 297-306. [Crossref]

1313. J.L. Marti, L.G.T. Morris, A.S. Ho. 2018. Selective use of radioactive iodine (RAI) in thyroid cancer: No longer "one size fits all". *European Journal of Surgical Oncology* **44**:3, 348-356. [Crossref]

1314. B. Xu, R. Ghossein. 2018. Evolution of the histologic classification of thyroid neoplasms and its impact on clinical management. *European Journal of Surgical Oncology* **44**:3, 338-347. [Crossref]

1315. J.R. Cracchiolo, R.J. Wong. 2018. Management of the lateral neck in well differentiated thyroid cancer. *European Journal of Surgical Oncology* **44**:3, 332-337. [Crossref]

Downloaded by Memorial Sloan Kettering from www.liebertpub.com at 08/14/19. For personal use only.

1316. L.Y. Wang, I. Ganly. 2018. Post-treatment surveillance of thyroid cancer. *European Journal of Surgical Oncology* **44**:3, 357-366. [Crossref]

1317. Ryan P. Goepfert, Gary L. Clayman. 2018. Management of the central compartment in differentiated thyroid carcinoma. *European Journal of Surgical Oncology* **44**:3, 327-331. [Crossref]

1318. Noor Janjua, Volkert B. Wreesmann. 2018. Aggressive differentiated thyroid cancer. *European Journal of Surgical Oncology* **44**:3, 367-377. [Crossref]

1319. Hani O. Nasef, Iain J. Nixon, Volkert B. Wreesmann. 2018. Optimization of the risk-benefit ratio of differentiated thyroid cancer treatment. *European Journal of Surgical Oncology* **44**:3, 276-285. [Crossref]

1320. Xiabin Lan, Wei Sun, Wenwu Dong, Zhihong Wang, Ting Zhang, Liang He, Hao Zhang. 2018. Downregulation of long noncoding RNA H19 contributes to the proliferation and migration of papillary thyroid carcinoma. *Gene* **646**, 98-105. [Crossref]

1321. Na Lae Eun, Eun Ju Son, Jeong-Ah Kim, Hye Mi Gweon, Jung-Hyun Kang, Ji Hyun Youk. 2018. Comparison of the diagnostic performances of ultrasonography, CT and fine needle aspiration cytology for the prediction of lymph node metastasis in patients with lymph node dissection of papillary thyroid carcinoma: A retrospective cohort study. *International Journal of Surgery* **51**, 145-150. [Crossref]

1322. Nancy A. Young, Kay Khine Win, Lauren Pomo, Catherine Anastasopoulou, Corrado Minimo, Jane Mayrin. 2018. An academic community hospital experience using commercially available molecular testing in the management of indeterminate thyroid nodules. *Journal of the American Society of Cytopathology* **7**:2, 92-98. [Crossref]

1323. Ritu Nayar, Güliz A. Barkan, Cynthia Benedict, Christine Booth, David C. Chhieng, Dina Mody, Momin T. Siddiqui, Laura Z. Tabatabai, Rebecca Johnson. 2018. Laboratory management curriculum for cytopathology subspecialty training. *Journal of the American Society of Cytopathology* **7**:2, 61-78. [Crossref]

1324. Ricardo R. Lastra, George Birdsong, David H. Hwang, Merce Jorda, Darcy A. Kerr, Cindy McGrath, Shelley Odronic, Rema Rao, Paul A. VanderLaan, Joe W. Walker, Tatjana Antic. 2018. Preoperative cytologic interpretation of noninvasive follicular thyroid neoplasm with papillary-like nuclear features: a 1-year multi-institutional experience. *Journal of the American Society of Cytopathology* **7**:2, 79-85. [Crossref]

1325. Theodosios S. Papavramidis, Anna Zisi, Sofia-Eleni Tzorakoleftheraki, Triantafyllia Koletsa, Ioannis Pliakos, Stavros Panidis, George Kotsovolis, Christina Manani, Marina Kita, Antonis Michalopoulos. 2018. Papillary carcinoma arising from the pyramidal lobe of the thyroid gland – Two case reports. *Journal of Clinical and Translational Endocrinology: Case Reports* **7**, 1-4. [Crossref]

1326. Mehtap Doğan, Kasım Durmuş, Zekiye Hasbek, Emine Elif Altuntaş. 2018. Does the use of recombinant TSH in preparation for I-131 scintigraphy scan affect hearing function?. *Journal of Otology* **13**:1, 20-24. [Crossref]

1327. Toni Beninato, Wouter P. Kluijfhout, Frederick Thurston Drake, Elham Khanafshar, Jessica E. Gosnell, Wen T. Shen, Quan-Yang Duh, Insoo Suh. 2018. Squamous differentiation in papillary thyroid carcinoma: a rare feature of aggressive disease. *Journal of Surgical Research* **223**, 39-45. [Crossref]

1328. Michael Wagner, Melinda Wuest, Ingrit Hamann, Ana Lopez-Campistrous, Todd P.W. McMullen, Frank Wuest. 2018. Molecular imaging of platelet-derived growth factor receptor-alpha (PDGFRα) in papillary thyroid cancer using immuno-PET. *Nuclear Medicine and Biology* **58**, 51-58. [Crossref]

1329. Hye In Kim, Kyunga Kim, So Young Park, Jun-Ho Choe, Jung-Han Kim, Jee Soo Kim, Young Lyun Oh, Soo Yeon Hahn, Jung Hee Shin, Hyeon Seon Ahn, Sun Wook Kim, Tae Hyuk Kim, Jae Hoon Chung. 2018. Refining the eighth edition AJCC TNM classification and prognostic groups for papillary thyroid cancer with lateral nodal metastasis. *Oral Oncology* **78**, 80-86. [Crossref]

1330. Vaninder K. Dhillon, Ralph P. Tufano. 2018. Removal of thyroid remnant for cancer in the previously operated central neck. *Operative Techniques in Otolaryngology-Head and Neck Surgery* **29**:1, 19-23. [Crossref]

1331. Gian-Marco Busato, Jeremy Freeman. 2018. Revision central neck dissection. *Operative Techniques in Otolaryngology-Head and Neck Surgery* **29**:1, 24-29. [Crossref]

1332. Joseph Scharpf. 2018. Thyroid cancer invading the upper aerodigestive tract. *Operative Techniques in Otolaryngology-Head and Neck Surgery* **29**:1, 35-41. [Crossref]

1333. W.L. Craig, L. Smart, S. Fielding, C. Ramsay, Z.H. Krukowski. 2018. Long term outcomes of simple clinical risk stratification in management of differentiated thyroid cancer. *The Surgeon* . [Crossref]

1334. Frederik A. Verburg, Markus Luster. 2018. Balancing benefit and risk in TSH management of DTC. *Nature Reviews Endocrinology* **14**:3, 136-137. [Crossref]

1335. Isabelle Moneke, Jussuf T Kaifi, Raphael Kloeser, Patrick Samson, Benedikt Haager, Sebastian Wiesemann, Sven Diederichs, Bernward Passlick. 2018. Pulmonary metastasectomy for thyroid cancer as salvage therapy for radioactive iodine-refractory metastases†. *European Journal of Cardio-Thoracic Surgery* **53**:3, 625-630. [Crossref]

Downloaded by Memorial Sloan Kettering from www.liebertpub.com at 08/14/19. For personal use only.

1336. Yong Sang Lee, Soo Young Kim, Soon Won Hong, Seok-Mo Kim, Bup-Woo Kim, Hang-Seok Chang, Cheong Soo Park. 2018. Ultrasonographic features and clinicopathologic characteristics of macrofollicular variant papillary thyroid carcinoma. *Medicine* **97**:9, e8105. [Crossref]

1337. Roh-Eul Yoo, Ji-hoon Kim, Jin Chul Paeng, Young Joo Park. 2018. Radiofrequency ablation for treatment of locally recurrent thyroid cancer presenting as a metastatic lymph node with dense macrocalcification. *Medicine* **97**:9, e0003. [Crossref]

1338. Hou-Yang Hu, Jun Liang, Teng Zhang, Teng Zhao, Yan-Song Lin. 2018. Suppressed thyroglobulin performs better than stimulated thyroglobulin in defining an excellent response in patients with differentiated thyroid cancer. *Nuclear Medicine Communications* **39**:3, 247-251. [Crossref]

1339. Tae Hyuk Kim, Minju Lee, Ah-Young Kwon, Jun-Ho Choe, Jung-Han Kim, Jee Soo Kim, Soo Yeon Hahn, Jung Hee Shin, Man Ki Chung, Young Ik Son, Chang-Seok Ki, Hyun Sook Yim, Yoo-Li Kim, Jae Hoon Chung, Sun Wook Kim, Young Lyun Oh. 2018. Molecular genotyping of the non-invasive encapsulated follicular variant of papillary thyroid carcinoma. *Histopathology* **72**:4, 648-661. [Crossref]

1340. Jung Hyun Yoon, Eun-Kyung Kim, Jin Young Kwak, Hee Jung Moon. 2018. Non-diagnostic thyroid nodules after application of the Bethesda system: a study evaluating the interval for repeat aspiration for non-diagnostic results. *Acta Radiologica* **59**:3, 305-312. [Crossref]

1341. Sergio Vargas-Salas, José R Martínez, Soledad Urra, José Miguel Domínguez, Natalia Mena, Thomas Uslar, Marcela Lagos, Marcela Henríquez, Hernán E González. 2018. Genetic testing for indeterminate thyroid cytology: review and meta-analysis. *Endocrine-Related Cancer* **25**:3, R163-R177. [Crossref]

1342. Yeun-Yoon Kim, Kyunghwa Han, Eun-Kyung Kim, Hee Jung Moon, Jung Hyun Yoon, Vivian Y. Park, Jin Young Kwak. 2018. Validation of the 2015 American Thyroid Association Management Guidelines for Thyroid Nodules With Benign Cytologic Findings in the Era of the Bethesda System. *American Journal of Roentgenology* **210**:3, 629-634. [Crossref]

1343. Maria E. Cabanillas, Steven P. Weitzman, Ramona Dadu, Ted Gansler, Mark Zafereo. Thyroid Cancer 519-531. [Crossref]

1344. Agnese Barnabei, Lidia Strigari, Agnese Persichetti, Roberto Baldelli, Laura Rizza, Claudia Annoscia, Rosa Lauretta, Giovanni Cigliana, Maddalena Barba, Aurora De Leo, Marialuisa Appetecchia, Francesco Torino. 2018. Indirect Basal Metabolism Estimation in Tailoring Recombinant Human TSH Administration in Patients Affected by Differentiated Thyroid Cancer: A Hypothesis-Generating Study. *Frontiers in Endocrinology* **9**. . [Crossref]

1345. Mehmet Çelik, Buket Yılmaz Bülbül, Semra Aytürk, Ahmet Küçükarda, Ebru Taştekin, Nuray Can, Funda Üstün, Yavuz Atakan Sezer, Sibel Güldiken. 2018. Synchronous and antecedent malignancies in patients with papillary thyroid carcinoma. *The European Research Journal* . [Crossref]

1346. Xiaopei Shen, Guangwu Zhu, Rengyun Liu, David Viola, Rossella Elisei, Efisio Puxeddu, Laura Fugazzola, Carla Colombo, Barbara Jarzab, Agnieszka Czarniecka, Alfred K. Lam, Caterina Mian, Federica Vianello, Linwah Yip, Garcilaso Riesco-Eizaguirre, Pilar Santisteban, Christine J. O'Neill, Mark S. Sywak, Roderick Clifton-Bligh, Bela Bendlova, Vlasta Sýkorová, Mingzhao Xing. 2018. Patient Age–Associated Mortality Risk Is Differentiated by BRAF V600E Status in Papillary Thyroid Cancer. *Journal of Clinical Oncology* **36**:5, 438-445. [Crossref]

1347. Megan R. Haymart. 2018. Is BRAF V600E Mutation the Explanation for Age-Associated Mortality Risk in Patients With Papillary Thyroid Cancer?. *Journal of Clinical Oncology* **36**:5, 433-434. [Crossref]

1348. Wang Tracy S.. 2018. Current ATA Thyroid Cancer Guidelines Are Poor Predictors of the Extent of Thyroidectomy. *Clinical Thyroidology* **30**:2, 56-58. [Citation] [Full Text] [PDF] [PDF Plus]

1349. Fish Stephanie A.. 2018. Surgeon-Performed Ultrasound Is Important in the Preoperative Nodal Assessment of Patients with Potential Thyroid Malignancy. *Clinical Thyroidology* **30**:2, 77-79. [Citation] [Full Text] [PDF] [PDF Plus]

1350. Biermann Martin. 2018. Ultrasound Shear Wave Elastography May Help Reduce Frequency of Fine-Needle Biopsy in Low-Risk Thyroid Nodules. *Clinical Thyroidology* **30**:2, 80-84. [Citation] [Full Text] [PDF] [PDF Plus]

1351. Hershman Jerome M.. 2018. RAI Ablation Has Decreased for Low-Risk Thyroid Cancers in California. *Clinical Thyroidology* **30**:2, 85-87. [Citation] [Full Text] [PDF] [PDF Plus]

1352. Jeon Min Ji, Kim Mijin, Park Suyeon, Oh Hye-Seon, Kim Tae Yong, Kim Won Bae, Shong Young Kee, Kim Won Gu. 2018. A Follow-Up Strategy for Patients with an Excellent Response to Initial Therapy for Differentiated Thyroid Carcinoma: Less Is Better. *Thyroid* **28**:2, 187-192. [Abstract] [Full Text] [PDF] [PDF Plus] [Supplementary Material]

1353. Jeon Min Ji, Kim Young Nam, Sung Tae-Yong, Hong Suck Joon, Cho Yoon Young, Kim Tae Yong, Shong Young Kee, Kim Won Bae, Kim Sun Wook, Chung Jae Hoon, Kim Tae Hyuk, Kim Won Gu. 2018. Practical Initial Risk Stratification Based on Lymph Node Metastases in Pediatric and Adolescent Differentiated Thyroid Cancer. *Thyroid* **28**:2, 193-200. [Abstract] [Full Text] [PDF] [PDF Plus] [Supplementary Material]

Downloaded by Memorial Sloan Kettering from www.liebertpub.com at 08/14/19. For personal use only.

1354. Shteinshnaider Miriam, Muallem Kalmovich Limor, Koren Shlomit, Or Karen, Cantrell Dror, Benbassat Carlos. 2018. Reassessment of Differentiated Thyroid Cancer Patients Using the Eighth TNM/AJCC Classification System: A Comparative Study. *Thyroid* **28**:2, 201-209. [Abstract] [Full Text] [PDF] [PDF Plus]

1355. Côrtes Marina Carvalho Souza, Rosario Pedro Weslley, Oliveira Luís Fernando Faria, Calsolari Maria Regina. 2018. Clinical Impact of Detectable Antithyroglobulin Antibodies Below the Reference Limit (Borderline) in Patients with Papillary Thyroid Carcinoma with Undetectable Serum Thyroglobulin and Normal Neck Ultrasonography After Ablation: A Prospective Study. *Thyroid* **28**:2, 229-235. [Abstract] [Full Text] [PDF] [PDF Plus]

1356. Valderrabano Pablo, Khazai Laila, Thompson Zachary J., Sharpe Susan C., Tarasova Valentina D., Otto Kristen J., Hallanger-Johnson Julie E., Wadsworth J. Trad, Wenig Bruce M., Chung Christine H., Centeno Barbara A., McIver Bryan. 2018. Cancer Risk Associated with Nuclear Atypia in Cytologically Indeterminate Thyroid Nodules: A Systematic Review and Meta-Analysis. *Thyroid* **28**:2, 210-219. [Abstract] [Full Text] [PDF] [PDF Plus] [Supplementary Material]

1357. Moran Amit, Samantha Tam, Mongkol Boonsripitayanon, Maria E. Cabanillas, Naifa L. Busaidy, Elizabeth Gardner Grubbs, Stephen Y. Lai, Neil D. Gross, Erich M. Sturgis, Mark E. Zafereo. 2018. Association of Lymph Node Density With Survival of Patients With Papillary Thyroid Cancer. *JAMA Otolaryngology–Head & Neck Surgery* **144**:2, 108. [Crossref]

1358. H. I. Kim, T. H. Kim, J.-H. Choe, J.-H. Kim, J. S. Kim, Y. N. Kim, H. Kim, S. W. Kim, J. H. Chung. 2018. Surgeon volume and prognosis of patients with advanced papillary thyroid cancer and lateral nodal metastasis. *British Journal of Surgery* **105**:3, 270-278. [Crossref]

1359. Tamar C. Brandler, Joseph Yee, Fang Zhou, Margaret Cho, Joan Cangiarella, Xiao-Jun Wei, Melissa Yee-Chang, Wei Sun. 2018. Does noninvasive follicular thyroid neoplasm with papillary-like nuclear features have distinctive features on sonography?. *Diagnostic Cytopathology* **46**:2, 139-147. [Crossref]

1360. Davide Lombardi, Alberto Paderno, Davide Giordano, Diego Barbieri, Stefano Taboni, Cesare Piazza, Carlo Cappelli, Francesco Bertagna, Verter Barbieri, Simonetta Piana, Salvatore Bellafiore, Giuseppe Spriano, Giuseppe Mercante, Piero Nicolai. 2018. Therapeutic lateral neck dissection in well-differentiated thyroid cancer: Analysis on factors predicting distribution of positive nodes and prognosis. *Head & Neck* **40**:2, 242-250. [Crossref]

1361. Robert L. Witt. 2018. In reference to Does mutational analysis influence the management of differentiated thyroid cancers?. *The Laryngoscope* **128**:2, E84-E84. [Crossref]

1362. Marcin Barczyński, Aleksander Konturek, Alicja Hubalewska-Dydejczyk, Filip Gołkowski, Wojciech Nowak. 2018. Ten-Year Follow-Up of a Randomized Clinical Trial of Total Thyroidectomy Versus Dunhill Operation Versus Bilateral Subtotal Thyroidectomy for Multinodular Non-toxic Goiter. *World Journal of Surgery* **42**:2, 384-392. [Crossref]

1363. Maureen D. Moore, Emily Postma, Katherine D. Gray, Timothy M. Ullmann, James R. Hurley, Stanley Goldsmith, Vivian R. Sobel, Aaron Schulman, Theresa Scognamiglio, Paul J. Christos, Erin Hassett, Jessica Luick, Dana Whitehall, Rasa Zarnegar, Thomas J. Fahey. 2018. Less is More: The Impact of Multidisciplinary Thyroid Conference on the Treatment of Well-Differentiated Thyroid Carcinoma. *World Journal of Surgery* **42**:2, 343-349. [Crossref]

1364. Linwah Yip, Sally E. Carty. 2018. An Evolving Understanding of the Clinical Implications of NIFTP. *World Journal of Surgery* **42**:2, 327-328. [Crossref]

1365. Rocco Bellantone, Marco Raffaelli, Carmela De Crea, Luca Sessa, Emanuela Traini, Pietro Princi, Celestino Pio Lombardi. 2018. Video-Assisted Thyroidectomy for Papillary Thyroid Carcinoma: Oncologic Outcome in Patients with Follow-Up ≥ 10 Years. *World Journal of Surgery* **42**:2, 402-408. [Crossref]

1366. Stephanie Allelein, K. Lorenz, Matthias Schott. 2018. Metastasiertes Schilddrüsenkarzinom. *Der Onkologe* **24**:2, 107-117. [Crossref]

1367. Jingtai Zhi, Jingzhu Zhao, Ming Gao, Yi Pan, Jianghua Wu, Yigong Li, Dapeng Li, Yang Yu, Xiangqian Zheng. 2018. Impact of major different variants of papillary thyroid microcarcinoma on the clinicopathological characteristics: the study of 1041 cases. *International Journal of Clinical Oncology* **23**:1, 59-65. [Crossref]

1368. M. Molina-Vega, J. García-Alemán, A. Sebastián-Ochoa, I. Mancha-Doblas, J. M. Trigo-Pérez, F. Tinahones-Madueño. 2018. Tyrosine kinase inhibitors in iodine-refractory differentiated thyroid cancer: experience in clinical practice. *Endocrine* **59**:2, 395-401. [Crossref]

1369. Luca Giovanella. 2018. Tomografia a emissione di positroni con 18F-fluorodesossiglucosio nel carcinoma tiroideo radioiodio-refrattario. *L'Endocrinologo* **19**:1, 15-20. [Crossref]

1370. Carlos Miguel Oliveira, Rui Alves Costa, Miguel Patrício, Amélia Estêvão, Bruno Graça, Filipe Caseiro-Alves. 2018. Sonographic Criteria Predictive of Malignant Thyroid Nodules. *Academic Radiology* **25**:2, 213-218. [Crossref]

Downloaded by Memorial Sloan Kettering from www.liebertpub.com at 08/14/19. For personal use only.

1371. Yan-Rong Li, Ching-Ping Tseng, Hsueh-Ling Hsu, Hung-Chih Lin, Yi-An Chen, Szu-Tah Chen, Miaw-Jene Liou, Jen-Der Lin. 2018. Circulating epithelial cells as potential biomarkers for detection of recurrence in patients of papillary thyroid carcinoma with positive serum anti-thyroglobulin antibody. *Clinica Chimica Acta* **477**, 74-80. [Crossref]

1372. Mariana Bonjiorno Martins, Marjory Alana Marcello, Fernando de Assis Batista, Karina Colombera Peres, Murilo Meneghetti, Mirela Andrea Latham Ward, Elba Cristina Sá de Camargo Etchebehere, Ligia Vera Montali da Assumpção, Laura Sterian Ward. 2018. Serum interleukin measurement may help identify thyroid cancer patients with active disease. *Clinical Biochemistry* **52**, 1-7. [Crossref]

1373. S.C. Clement, L.C.M. Kremer, F.A. Verburg, J.H. Simmons, M. Goldfarb, R.P. Peeters, E.K. Alexander, E. Bardi, E. Brignardello, L.S. Constine, C.A. Dinauer, V.M. Drozd, F. Felicetti, E. Frey, A. Heinzel, M.M. van den Heuvel-Eibrink, S.A. Huang, T.P. Links, K. Lorenz, R.L. Mulder, S.J. Neggers, E.J.M. Nieveen van Dijkum, K.C. Oeffinger, R.R. van Rijn, S.A. Rivkees, C.M. Ronckers, A.B. Schneider, R. Skinner, J.D. Wasserman, T. Wynn, M.M. Hudson, P.C. Nathan, H.M. van Santen. 2018. Balancing the benefits and harms of thyroid cancer surveillance in survivors of Childhood, adolescent and young adult cancer: Recommendations from the international Late Effects of Childhood Cancer Guideline Harmonization Group in collaboration with the PanCareSurFup Consortium. *Cancer Treatment Reviews* **63**, 28-39. [Crossref]

1374. Ali Abbasian Ardakani, Ali Mohammadzadeh, Nahid Yaghoubi, Zahra Ghaemmaghami, Reza Reiazi, Amir Homayoun Jafari, Sepideh Hekmat, Ahmad Bitarafan-Rajabi, Mohammad Bagher Shiran. 2018. Predictive Quantitative Sonographic Features on Classification of Hot and Cold Thyroid Nodules. *European Journal of Radiology* . [Crossref]

1375. Yoon Kyoung So, Min-Ji Kim, Seonwoo Kim, Young-Ik Son. 2018. Lateral lymph node metastasis in papillary thyroid carcinoma: A systematic review and meta-analysis for prevalence, risk factors, and location. *International Journal of Surgery* **50**, 94-103. [Crossref]

1376. Kang-Lung Lee, Tzeng-Ji Chen, Ging-Shing Won, Yi-Hong Chou, Hong-Jen Chiou, Hsin-Kai Wang, Yi-Chen Lai, Yung-Hui Lin, Jane Wang. 2018. The use of fine needle aspiration and trends in incidence of thyroid cancer in Taiwan. *Journal of the Chinese Medical Association* **81**:2, 164-169. [Crossref]

1377. Samuel J. Galgano, Ryan V. Marshall, Erik H. Middlebrooks, Jonathan E. McConathy, Pradeep Bhambhvani. 2018. PET/MR Imaging in Head and Neck Cancer. *Magnetic Resonance Imaging Clinics of North America* **26**:1, 167-178. [Crossref]

1378. Yong Sang Lee, Seok-Mo Kim, Bup-Woo Kim, Ho Jin Chang, Soo Young Kim, Cheong Soo Park, Ki Cheong Park, Hang-Seok Chang. 2018. Anti-cancer Effects of HNHA and Lenvatinib by the Suppression of EMT-Mediated Drug Resistance in Cancer Stem Cells. *Neoplasia* **20**:2, 197-206. [Crossref]

1379. Wei-Jun Wei, Guo-Qiang Zhang, Quan-Yong Luo. 2018. Postsurgical Management of Differentiated Thyroid Cancer in China. *Trends in Endocrinology & Metabolism* **29**:2, 71-73. [Crossref]

1380. Alessandro Antonelli, Silvia Martina Ferrari, Poupak Fallahi. 2018. Current and future immunotherapies for thyroid cancer. *Expert Review of Anticancer Therapy* **18**:2, 149-159. [Crossref]

1381. Georgi I. Popivanov, Pavel Bochev, Radka Hristoskova, Ventsislav M. Mutafchiyski, Mihail Tabakov, Anthony Philipov, Roberto Cirocchi. 2018. Synchronous papillary thyroid cancer and non-Hodgkin lymphoma. *Medicine* **97**:6, e9831. [Crossref]

1382. Nihat Yumusak, Murat Sadic, Gozde Yucel, Hasan I. Atilgan, Gokhan Koca, Meliha Korkmaz. 2018. Apoptosis and cell proliferation in short-term and long-term effects of radioiodine-131-induced kidney damage. *Nuclear Medicine Communications* **39**:2, 131-139. [Crossref]

1383. P. Trimboli, M. Imperiali, A. Piccardo, A. CampennÌ, I. Giordani, R. M. Ruggeri, S. Baldari, F. Orlandi, L. Giovanella. 2018. Multicentre clinical evaluation of the new highly sensitive Elecsys® thyroglobulin II assay in patients with differentiated thyroid carcinoma. *Clinical Endocrinology* **88**:2, 295-302. [Crossref]

1384. Seo Young Sohn, Hye In Kim, Young Nam Kim, Tae Hyuk Kim, Sun Wook Kim, Jae Hoon Chung. 2018. Prognostic indicators of outcomes in patients with lung metastases from differentiated thyroid carcinoma during long-term follow-up. *Clinical Endocrinology* **88**:2, 318-326. [Crossref]

1385. Tian Lv, Changbin Zhu, Zhongmin Di. 2018. Risk factors stratifying malignancy of nodules in contralateral thyroid lobe in patients with pre-operative ultrasound indicated unilateral papillary thyroid carcinoma: A retrospective analysis from single centre. *Clinical Endocrinology* **88**:2, 279-284. [Crossref]

1386. Nelli Pajamäki, Saara Metso, Tommi Hakala, Tapani Ebeling, Heini Huhtala, Essi Ryödi, Juhani Sand, Arja Jukkola-Vuorinen, Pirkko-Liisa Kellokumpu-Lehtinen, Pia Jaatinen. 2018. Long-term cardiovascular morbidity and mortality in patients treated for differentiated thyroid cancer. *Clinical Endocrinology* **88**:2, 303-310. [Crossref]

1387. O. Cohen, T. Raz Yarkoni, Y. Lahav, O. Azoulay, D. Halperin, M. Yehuda. 2018. Surgeon-performed thyroid ultrasound-proving utility and credibility in selecting patients for fine needle aspiration according to the American thyroid association guidelines. A retrospective study of 500 patients. *Clinical Otolaryngology* **43**:1, 267-273. [Crossref]

Downloaded by Memorial Sloan Kettering from www.liebertpub.com at 08/14/19. For personal use only.

1388. Craig A. Bollig, David Gilley, David Lesko, Jeffrey B. Jorgensen, Tabitha L. Galloway, Robert P. Zitsch, Laura M. Dooley. 2018. Economic Impact of Frozen Section for Thyroid Nodules with "Suspicious for Malignancy" Cytology. *Otolaryngology–Head and Neck Surgery* **158**:2, 257-264. [Crossref]

1389. Inseon Ryoo, Dong Wook Kim, Chang Yoon Lee, Jung Yin Huh, Song Lee, Hye Shin Ahn, Jin Yong Sung. 2018. Analysis of postoperative ultrasonography surveillance after total thyroidectomy in patients with papillary thyroid carcinoma: a multicenter study. *Acta Radiologica* **59**:2, 196-203. [Crossref]

1390. Amit Ritter, Gideon Bachar, Dania Hirsch, Carlos Benbassat, Orna Katz, Nadav Kochen, Talia Diker-Cohen, Amit Akirov, Ilan Shimon, Eyal Robenshtok. 2018. Natural History of Contralateral Nodules After Lobectomy in Patients With Papillary Thyroid Carcinoma. *The Journal of Clinical Endocrinology & Metabolism* **103**:2, 407-414. [Crossref]

1391. Dania Hirsch, Alexander Gorshtein, Eyal Robenshtok, Hiba Masri-Iraqi, Amit Akirov, Hadar Duskin Bitan, Ilan Shimon, Carlos Benbassat. 2018. Second Radioiodine Treatment: Limited Benefit for Differentiated Thyroid Cancer With Locoregional Persistent Disease. *The Journal of Clinical Endocrinology & Metabolism* **103**:2, 469-476. [Crossref]

1392. Sona Shah, Laura Boucai. 2018. Effect of Age on Response to Therapy and Mortality in Patients With Thyroid Cancer at High Risk of Recurrence. *The Journal of Clinical Endocrinology & Metabolism* **103**:2, 689-697. [Crossref]

1393. Chae Jung Park, Eun-Kyung Kim, Hee Jung Moon, Jung Hyun Yoon, Vivian Youngjean Park, Jin Young Kwak. 2018. Thyroid Nodules With Nondiagnostic Cytologic Results: Follow-Up Management Using Ultrasound Patterns Based on the 2015 American Thyroid Association Guidelines. *American Journal of Roentgenology* **210**:2, 412-417. [Crossref]

1394. Sara Donato, Rita Santos, Helder Simões, Valeriano Leite. 2018. Novel therapies against aggressive differentiated thyroid carcinomas. *International Journal of Endocrine Oncology* **5**:1, IJE05. [Crossref]

1395. Maren Y. Fuller, Dina Mody, April Hull, Kristi Pepper, Heather Hendrickson, Randall Olsen. 2018. Next-Generation Sequencing Identifies Gene Mutations That Are Predictive of Malignancy in Residual Needle Rinses Collected From Fine-Needle Aspirations of Thyroid Nodules. *Archives of Pathology & Laboratory Medicine* **142**:2, 178-183. [Crossref]

1396. Thomas J. Giordano. 2018. Genomic Hallmarks of Thyroid Neoplasia. *Annual Review of Pathology: Mechanisms of Disease* **13**:1, 141-162. [Crossref]

1397. Vikram Singh Shekhawat, Anil Bhansali. 2018. Bony swellings: an enigma. *BMJ Case Reports* **174**, bcr-2017-222084. [Crossref]

1398. Michele Podetta, Marc Pusztaszeri, Christian Toso, Michel Procopiou, Frédéric Triponez, Samira Mercedes Sadowski. 2018. Oncocytic Adrenocortical Neoplasm with Concomitant Papillary Thyroid Cancer. *Frontiers in Endocrinology* **8**. . [Crossref]

1399. Hongxun Wu, Bingjie Zhang, Jie Li, Qianyun Liu, Tingting Zhao. 2018. Echogenic foci with comet-tail artifact in resected thyroid nodules: Not an absolute predictor of benign disease. *PLOS ONE* **13**:1, e0191505. [Crossref]

1400. Jeongin Yoo, Hye Shin Ahn, Soo Jin Kim, Sung Hee Park, Mirinae Seo, Semin Chong. 2018. Evaluation of Diagnostic Performance of Screening Thyroid Ultrasonography and Imaging Findings of Screening-Detected Thyroid Cancer. *Cancer Research and Treatment* **50**:1, 11-18. [Crossref]

1401. Xiao Yue Cai, Niranjan Vijayaratnam, Alexander J. B. McEwan, Rebecca Reif, Donald W. Morrish. 2018. Comparison of 30 mCi and 50 mCi I-131 doses for ablation of thyroid remnant in papillary thyroid cancer patients. *Endocrine Research* **43**:1, 11-14. [Crossref]

1402. Murat Ö. Kılıç, Serdar G. Terzioğlu, Serap Y. Gülçek, Engin Sarı. 2018. The Role of Ultrasonography in the Assessment of Vocal Cord Functions After Thyroidectomy. *Journal of Investigative Surgery* **31**:1, 24-28. [Crossref]

1403. Biermann Martin. 2018. Selenium Supplementation May Help Protect Salivary Glands After Iodine-131 Therapy for Differentiated Thyroid Cancer. *Clinical Thyroidology* **30**:1, 21-24. [Citation] [Full Text] [PDF] [PDF Plus]

1404. Emerson Charles H.. 2018. A Consensus Has Not Been Reached for Pathology Reporting of Tall-Cell Variant of Papillary Thyroid Carcinoma. *Clinical Thyroidology* **30**:1, 25-29. [Citation] [Full Text] [PDF] [PDF Plus]

1405. Mostoufi-Moab Sogol, Labourier Emmanuel, Sullivan Lisa, LiVolsi Virginia, Li Yimei, Xiao Rui, Beaudenon-Huibregtse Sylvie, Kazahaya Ken, Adzick N. Scott, Baloch Zubair, Bauer Andrew J.. 2018. Molecular Testing for Oncogenic Gene Alterations in Pediatric Thyroid Lesions. *Thyroid* **28**:1, 60-67. [Abstract] [Full Text] [PDF] [PDF Plus] [Supplementary Material]

1406. Berdelou Amandine, Borget Isabelle, Godbert Yann, Nguyen Thierry, Garcia Marie-Eve, Chougnet Cécile N., Ferru Aurélie, Buffet Camille, Chabre Olivier, Huillard Olivier, Leboulleux Sophie, Schlumberger Martin. 2018. Lenvatinib for the Treatment of Radioiodine-Refractory Thyroid Cancer in Real-Life Practice. *Thyroid* **28**:1, 72-78. [Abstract] [Full Text] [PDF] [PDF Plus]

1407. Miyauchi Akira, Ito Yasuhiro, Oda Hitomi. 2018. Insights into the Management of Papillary Microcarcinoma of the Thyroid. *Thyroid* **28**:1, 23-31. [Abstract] [Full Text] [PDF] [PDF Plus]

1408. Watutantrige-Fernando Sara, Vianello Federica, Barollo Susi, Bertazza Loris, Galuppini Francesca, Cavedon Elisabetta, Censi Simona, Benna Clara, Ide Eric Casal, Parisi Alessandro, Nacamulli Davide, Iacobone Maurizio, Pennelli Gianmaria, Mian Caterina.

Downloaded by Memorial Sloan Kettering from www.liebertpub.com at 08/14/19. For personal use only.

2018. The Hobnail Variant of Papillary Thyroid Carcinoma: Clinical/Molecular Characteristics of a Large Monocentric Series and Comparison with Conventional Histotypes. *Thyroid* **28**:1, 96-103. [Abstract] [Full Text] [PDF] [PDF Plus]

1409. Yamashita Shunichi, Suzuki Shinichi, Suzuki Satoru, Shimura Hiroki, Saenko Vladimir. 2018. Lessons from Fukushima: Latest Findings of Thyroid Cancer After the Fukushima Nuclear Power Plant Accident. *Thyroid* **28**:1, 11-22. [Abstract] [Full Text] [PDF] [PDF Plus]

1410. Nam Sung Hoon, Roh Jong-Lyel, Gong Gyungyup, Cho Kyung-Ja, Choi Seung-Ho, Nam Soon Yuhl, Kim Sang Yoon. 2018. Nodal Factors Predictive of Recurrence After Thyroidectomy and Neck Dissection for Papillary Thyroid Carcinoma. *Thyroid* **28**:1, 88-95. [Abstract] [Full Text] [PDF] [PDF Plus] [Supplementary Material]

1411. Murata Yoshiharu, Yamada Masanobu. 2018. Thyroid-Related Research in Japan A Spotlight on Recent Important Contributions. *Thyroid* **28**:1, 1-3. [Citation] [Full Text] [PDF] [PDF Plus]

1412. Natalya V. Guseva, Omar Jaber, Aaron A. Stence, Krishnaveni Sompallae, Amani Bashir, Ramakrishna Sompallae, Aaron D. Bossler, Chris S. Jensen, Deqin Ma. 2018. Simultaneous detection of single-nucleotide variant, deletion/insertion, and fusion in lung and thyroid carcinoma using cytology specimen and an RNA-based next-generation sequencing assay. *Cancer Cytopathology* **126**:3, 158. [Crossref]

1413. Kristen L. Partyka, Melissa L. Randolph, Karen A. Lawrence, Harvey Cramer, Howard H. Wu. 2018. Utilization of direct smears of thyroid fine-needle aspirates for ancillary molecular testing: A comparison of two proprietary testing platforms. *Diagnostic Cytopathology* **46**:4, 320. [Crossref]

1414. Christopher E. Fundakowski, Nathan W. Hales, Nishant Agrawal, Marcin Barczyński, Pauline M. Camacho, Dana M. Hartl, Emad Kandil, Whitney E. Liddy, Travis J. McKenzie, John C. Morris, John A. Ridge, Rick Schneider, Jonathan Serpell, Catherine F. Sinclair, Samuel K. Snyder, David J. Terris, R. Michael Tuttle, Che-Wei Wu, Richard J. Wong, Mark Zafereo, Gregory W. Randolph. 2018. Surgical management of the recurrent laryngeal nerve in thyroidectomy: American Head and Neck Society Consensus Statement. *Head & Neck* **40**:4, 663. [Crossref]

1415. Daniel J. Lee, Christopher J. Chin, Chris J. Hong, Stefan Perera, Ian J. Witterick. 2018. Outpatient versus inpatient thyroidectomy: A systematic review and meta-analysis. *Head & Neck* **40**:1, 192-202. [Crossref]

1416. Ji-Hun Kang, Da-Woon Jung, Kyoung-June Pak, In-Ju Kim, Hak-Jin Kim, Jae-Keun Cho, Sung-Chan Shin, Soo-Geun Wang, Byung-Joo Lee. 2018. Prognostic implication of fluorine-18 fluorodeoxyglucose positron emission tomography/computed tomography in patients with recurrent papillary thyroid cancer. *Head & Neck* **40**:1, 94-102. [Crossref]

1417. Pierpaolo Trimboli, Maurilio Deandrea, Alberto Mormile, Luca Ceriani, Francesca Garino, Paolo P. Limone, Luca Giovanella. 2018. American Thyroid Association ultrasound system for the initial assessment of thyroid nodules: Use in stratifying the risk of malignancy of indeterminate lesions. *Head & Neck* **40**:4, 722. [Crossref]

1418. Luying Gao, Ruyu Liu, Yuxin Jiang, Wenfeng Song, Ying Wang, Jia Liu, Juanjuan Wang, Dongqian Wu, Shuai Li, Aimin Hao, Bo Zhang. 2018. Computer-aided system for diagnosing thyroid nodules on ultrasound: A comparison with radiologist-based clinical assessments. *Head & Neck* **40**:4, 778. [Crossref]

1419. June Young Choi, Hyeong Won Yu, In Eui Bae, Jong-kyu Kim, Chan Yong Seong, Jin Wook Yi, Young Jun Chai, Su-jin Kim, Kyu Eun Lee. 2018. Novel method to save the parathyroid gland during thyroidectomy: Subcapsular saline injection. *Head & Neck* **40**:4, 801. [Crossref]

1420. Shishi Zhang, Wei Wang, Haijian Zhao, Falin He, Kun Zhong, Shuai Yuan, Zhiguo Wang. 2018. Status of internal quality control for thyroid hormones immunoassays from 2011 to 2016 in China. *Journal of Clinical Laboratory Analysis* **32**:1, e22154. [Crossref]

1421. Hyung Jin Lee, Dae Young Yoon, Young Lan Seo, Jin Ho Kim, Sora Baek, Kyoung Ja Lim, Young Kwon Cho, Eun Joo Yun. 2018. Intraobserver and Interobserver Variability in Ultrasound Measurements of Thyroid Nodules. *Journal of Ultrasound in Medicine* **37**:1, 173-178. [Crossref]

1422. Ameya Asarkar, Manish Shaha, Ashok Shaha, Cherie-Ann O. Nathan. 2018. Does mutational analysis influence the management of differentiated thyroid cancers?. *The Laryngoscope* **128**:1, 1-2. [Crossref]

1423. Jamie Segel Grubey, Yazdan Raji, William S. Duke, David J. Terris. 2018. Outpatient thyroidectomy is safe in the elderly and super-elderly. *The Laryngoscope* **128**:1, 290-294. [Crossref]

1424. Thomas A. D'Agostino, Elyse Shuk, Erin K. Maloney, Rebecca Zeuren, R. Michael Tuttle, Carma L. Bylund. 2018. Treatment decision making in early-stage papillary thyroid cancer. *Psycho-Oncology* **27**:1, 61-68. [Crossref]

1425. Melissa Henry, Saul Frenkiel, Gabrielle Chartier, Christina MacDonald, Richard J. Payne, Martin J. Black, Alex M. Mlynarek, Anthony Zeitouni, Karen Kost, Carmen Loiselle, Antoinette Ehrler, Zeev Rosberger, Michael Tamilia, Yu Xin Chang, Cecilia de la Mora, Camille Arbaud, Michael P. Hier. 2018. Thyroid cancer patients receiving an interdisciplinary team-based care approach (ITCA-ThyCa) appear to display better outcomes: Program evaluation results indicating a need for further integrated care and support. *Psycho-Oncology* **27**:3, 937. [Crossref]

Downloaded by Memorial Sloan Kettering from www.liebertpub.com at 08/14/19. For personal use only.

1426. Moni A. Kuriakose, Swagnik Chakrabarti, Sok Ching Cheong, Luiz P. Kowalski, Tiago Novaes Pinheiro, Camile S. Farah. Head and Neck Tumors 1-136. [Crossref]

1427. Sebastiano Filetti, Steven I. Sherman. New (Medical) Treatment for Thyroid Carcinoma 1-26. [Crossref]

1428. Giovanni Ceccarini, Ferruccio Santini, Paolo Vitti. Tests of Thyroid Function 33-55. [Crossref]

1429. Furio Pacini, Maria Grazia Castagna, Martin Schlumberger. Differentiated Thyroid Carcinoma of Follicular Origin 563-588. [Crossref]

1430. Sebastiano Filetti, Steven I. Sherman. New (Medical) Treatment for Thyroid Carcinoma 645-670. [Crossref]

1431. E. Papini, R. Guglielmi, G. Bizzarri, A. Frasoldati. Nonisotopic Thyroid Imaging 89-123. [Crossref]

1432. Steen Joop Bonnema, Laszlo Hegedüs. Nontoxic Goiter 127-163. [Crossref]

1433. Markus Eszlinger, Laszlo Hegedüs, Ralf Paschke. Thyroid Nodule 165-201. [Crossref]

1434. Andrew T. Day, David W. Eisele. Radioiodine Sialadenitis 87-92. [Crossref]

1435. Sina Jasim, Hossein Gharib. Multinodular Goiter 135-152. [Crossref]

1436. Danae A. Delivanis, M. Regina Castro. Thyroid Incidentalomas 153-167. [Crossref]

1437. Randall P. Scheri, Julie Ann Sosa. Surgery for Thyroid Nodules 169-192. [Crossref]

1438. Enrico Papini, Rinaldo Guglielmi, Antonio Bianchini, Giancarlo Bizzarri. Minimally Invasive Treatments for Thyroid Nodules 193-206. [Crossref]

1439. Siobhan Pittock. Thyroid Nodules in Children 207-231. [Crossref]

1440. Alan A. Parsa, Hossein Gharib. Laboratory Evaluation for Thyroid Nodules 19-33. [Crossref]

1441. Jolanta M. Durski, Trond Velde Bogsrud. Nuclear Medicine in Evaluation and Therapy of Nodular Thyroid 35-62. [Crossref]

1442. Michael Rivera, Jennifer L. Sauter, Michael R. Henry. Description and Classification of Thyroid Cytology 89-110. [Crossref]

1443. Trevor E. Angell, Matthew I. Kim, Erik K. Alexander. Molecular Markers and Thyroid Nodule Evaluation 111-128. [Crossref]

1444. Alan A. Parsa, Hossein Gharib. Thyroxine Therapy for Thyroid Nodules 129-134. [Crossref]

1445. Zubair W. Baloch, David S. Cooper, Hossein Gharib, Erik K. Alexander. Overview of Diagnostic Terminology and Reporting 1-6. [Crossref]

1446. Barbara A. Crothers, Michael R. Henry, Pinar Firat, Mary C. Frates, Esther Diana Rossi. Nondiagnostic/Unsatisfactory 7-18. [Crossref]

1447. Tarik M. Elsheikh, Béatrix Cochand-Priollet, Soon Won Hong, Mary K. Sidawy. Benign 19-48. [Crossref]

1448. Jeffrey F. Krane, Ritu Nayar, Andrew A. Renshaw. Atypia of Undetermined Significance/Follicular Lesion of Undetermined Significance 49-70. [Crossref]

1449. Michael R. Henry, William H. Westra, Jeffrey F. Krane, Fernando Schmitt. Follicular Neoplasm/Suspicious for a Follicular Neoplasm 71-80. [Crossref]

1450. William C. Faquin, Claire W. Michael, Andrew A. Renshaw, Philippe Vielh. Follicular Neoplasm, Hürthle Cell (Oncocytic) Type/Suspicious for a Follicular Neoplasm, Hürthle Cell (Oncocytic) Type 81-100. [Crossref]

1451. Paul A. VanderLaan, Ashish Chandra, Armando C. Filie, Gregory W. Randolph, Celeste N. Powers. Suspicious for Malignancy 101-118. [Crossref]

1452. Marc P. Pusztaszeri, Manon Auger, Edward B. Stelow, Grace C. H. Yang, Miguel A. Sanchez, Virginia A. LiVolsi. Papillary Thyroid Carcinoma, Variants, and Related Tumors 119-156. [Crossref]

1453. Miguel Melo, José M. Cameselle-Teijeiro, Catarina Eloy, Isabel Amendoeira, Paula Soares, Javier Caneiro-Gómez, Manuel Sobrinho-Simões. Therapeutic Options 107-110. [Crossref]

1454. Pierpaolo Trimboli, Alicia Algeciras-Schimnich, Luca Giovanella. Procalcitonin: Are We Ready for Clinical Use? 151-157. [Crossref]

1455. Massimo Salvatori, Claudio Altini, Luca Zagaria, Alfonso Verrillo, Germano Perotti. Aggressive Variants of Thyroid Carcinoma 161-173. [Crossref]

1456. Frederik A. Verburg. Differentiated Thyroid Cancer: Diagnosis, Therapy, and Follow-Up 51-64. [Crossref]

1457. Luca Giovanella, Federica D'Aurizio, Renato Tozzoli, Camilla Schalin-Jantti, Ulla Feldt-Rasmussen. Thyroglobulin and Thyroglobulin Antibodies 65-91. [Crossref]

1458. Cosimo Durante, Francesca Rosignolo, Marialuisa Sponziello, Antonella Verrienti, Sebastiano Filetti. Circulating Molecular Biomarkers in Thyroid Cancer 93-105. [Crossref]

Downloaded by Memorial Sloan Kettering from www.liebertpub.com at 08/14/19. For personal use only.

1459. Giuseppe Costante, Yassine Lalami, Christiane Jungels, Ahmad Awada. Calcitonin and Carcinoembryonic Antigen for the Diagnosis and Management of Medullary Thyroid Carcinoma 133-150. [Crossref]

1460. Christopher H. Chapman, Adam Garsa. Thyroid Cancer 243-258. [Crossref]

1461. Savvas Frangos, Ioannis Iakovou. New Approaches in the Management of Thyroid Cancer 45-58. [Crossref]

1462. Ettore Seregni, Alice Lorenzoni, Laura Fugazzola. Radioiodine Therapy of Thyroid Cancer 59-68. [Crossref]

1463. Lorenzo Bianchi. Radioiodine Therapy of Thyroid Cancer Dosimetry 69-76. [Crossref]

1464. Lucia Setti, Vicinelli Riccardo, Gianluigi Ciocia, Emilio Bombardieri, Laura Evangelista. Published Guidelines on Radioisotopic Treatments of Thyroid Diseases 77-92. [Crossref]

1465. Allen S. Ho, Ellie Maghami. Surgical Perspectives in Head and Neck Cancer 103-122. [Crossref]

1466. Robert A. Levine, J. Woody Sistrunk. History of Thyroid Ultrasound 1-14. [Crossref]

1467. Stacey Klyn, Mira Milas. Surgical Trends in Ultrasound Applications for the Treatment of Thyroid Nodules, Thyroid Cancer, and Parathyroid Disease 293-311. [Crossref]

1468. Mark A. Lupo, Daniel S. Duick. Ultrasound-Guided Fine-Needle Biopsy of Thyroid Nodules 359-388. [Crossref]

1469. Petros Tsamatropoulos, Roberto Valcavi. Laser and Radiofrequency Ablation Procedures 389-428. [Crossref]

1470. Andrea Frasoldati, Petros Tsamatropoulos, Daniel S. Duick. Percutaneous Ethanol Injection (PEI) for Thyroid Cysts and Other Neck Lesions 429-464. [Crossref]

1471. J. Woody Sistrunk. Authoring Quality Ultrasound Reports 517-533. [Crossref]

1472. Robert A. Levine. Doppler Ultrasound 43-70. [Crossref]

1473. Vijaya Chockalingam, Sarah Smith, Mira Milas. Normal Neck Anatomy and Method of Performing Ultrasound Examination 71-106. [Crossref]

1474. Stephanie L. Lee. Diffuse Thyroid Disease (DTD) and Thyroiditis 141-187. [Crossref]

1475. Susan J. Mandel, Jill E. Langer. Ultrasound of Thyroid Nodules 189-223. [Crossref]

1476. Catherine F. Sinclair, Dipti Kamani, Gregory W. Randolph, Barry Sacks, H. Jack Baskin. Ultrasound and Mapping of Neck Lymph Nodes 225-262. [Crossref]

1477. Nancy A. LaVine. Thyroid Dysfunction 153-166. [Crossref]

1478. Solomon Abay, Adam B. Winick. Biopsy Techniques 451-461. [Crossref]

1479. Andrew J. Bauer, Steven G. Waguespack, Amelia Grover, Gary L. Francis. Thyroid Neoplasia 439-476. [Crossref]

1480. Abdelhamid H. Elgazzar, Ismet Sarikaya. Endocrine System 1-39. [Crossref]

1481. Kosma Wolinski. 231. [Crossref]

1482. Xin Jing. Thyroid Fine Needle Aspiration Cytology 19-42. [Crossref]

1483. Ujjal K. Mallick, Clive Harmer. Pragmatism, Personalised Oncology, International Partnership for Research and Quality: The New Paradigm for Thyroid Cancer 1-3. [Crossref]

1484. Sana A. Ghaznavi, R. Michael Tuttle. Risk Stratification and Current Management of Low Risk Thyroid Cancer 111-120. [Crossref]

1485. Yasuhiro Ito, Akira Miyauchi. Management of Low-Risk Papillary Thyroid Carcinoma and Papillary Microcarcinoma: The Japanese Experience 121-129. [Crossref]

1486. Furio Pacini, Maria Grazia Castagna. Radioiodine Ablation: Current Status 131-135. [Crossref]

1487. Michael Lassmann, Markus Luster, Heribert Hänscheid. Dosimetric Approaches: Current Concepts 137-145. [Crossref]

1488. James D. Brierley, Meredith E. Giuliani. External Radiation in Differentiated Thyroid Cancer in the Era of IMRT and Modern Radiation Planning Techniques 147-152. [Crossref]

1489. Shireen Fatemi, Carole Spencer. Thyroglobulin 155-186. [Crossref]

1490. Amandine Berdelou, Sophie Leboulleux, Martin Schlumberger. Radioiodine Refractory Thyroid Cancer 201-212. [Crossref]

1491. Joanna Klubo-Gwiezdzinska, Yevgenia Kushchayeva, Sudheer Kumar Gara, Electron Kebebew. Familial Non-Medullary Thyroid Cancer 241-270. [Crossref]

1492. Steven G. Waguespack, Jonathan D. Wasserman. Pediatric Differentiated Thyroid Carcinoma 273-294. [Crossref]

1493. Robert C. Smallridge, John D. Casler, Michael E. Menefee. Anaplastic Thyroid Cancer 297-305. [Crossref]

1494. Allan Hackshaw. Thyroid Cancer Trials 339-355. [Crossref]

Downloaded by Memorial Sloan Kettering from www.liebertpub.com at 08/14/19. For personal use only.

1495. Ujjal K. Mallick, Fabián Pitoia. The Barriers to Uniform Implementation of Clinical Practice Guidelines (CPG) for Thyroid Cancer 357-368. [Crossref]

1496. Bryan R. Haugen. The 2015 American Thyroid Association Evidence-Based Guidelines for Management of Patients with Thyroid Nodules and Differentiated Thyroid Cancer: Key Recommendations 17-20. [Crossref]

1497. Dong Gyu Na, Ji-hoon Kim, Eun Ju Ha. Ultrasonography in Diagnosis and Management of Thyroid Cancer: Current International Recommendations 39-59. [Crossref]

1498. Hiro Ishii, Dae S. Kim, John C. Watkinson. Management of Cervical Lymph Nodes in Differentiated Thyroid Cancer 77-97. [Crossref]

1499. C. Carrie Liu, Jennifer Shin. Evidence-Based Medicine: Key Definitions and Concepts 1-14. [Crossref]

1500. Benjamin R. Roman, Ashok R. Shaha. Surgery vs Active Surveillance for Low-Risk Papillary Thyroid Carcinoma 49-57. [Crossref]

1501. Nicole A. Cipriani. Operative Management Versus Observation for Thyroid Nodules Larger than 4 cm with Benign Cytology 69-78. [Crossref]

1502. John Cramer, Robert L. Ferris. Surgical Approach to Thyroid Cancer 319-337. [Crossref]

1503. Dagmar Führer, Harald Lahner. Tumoren endokriner Organe beim alten und geriatrischen Patienten 575-580. [Crossref]

1504. Dagmar Führer, Harald Lahner. Tumoren endokriner Organe beim alten und geriatrischen Patienten 1-6. [Crossref]

1505. Andreas Schäffler, Cornelius Bollheimer, Roland Büttner, Christiane Girlich, Charalampos Aslanidis, Wolfgang Dietmaier, Margarita Bala, Viktoria Guralnik, Thomas Karrasch, Sylvia Schneider. Radiologisches und nuklearmedizinisches Basiswissen für die Diagnostik in der Endokrinologie 225-246. [Crossref]

1506. Andreas Schäffler, Cornelius Bollheimer, Roland Büttner, Christiane Girlich, Charalampos Aslanidis, Wolfgang Dietmaier, Margarita Bala, Viktoria Guralnik, Thomas Karrasch, Sylvia Schneider. Die Schilddrüsenpunktion 301-304. [Crossref]

1507. Rajeev Parameswaran, Amit Agarwal. Evidence-Based Surgery 3-10. [Crossref]

1508. Sue Ping Thang, David Chee-Eng Ng. Radioiodine Therapy for Well-Differentiated Thyroid Cancer 109-120. [Crossref]

1509. David A. Pattison, Julie A. Miller, Bhadrakant Khavar, Jeanne Tie. Management of Distant Metastasis in Differentiated Thyroid Cancer 121-140. [Crossref]

1510. Min En Nga. Updates in Thyroid Cytology 53-70. [Crossref]

1511. Sabaretnam Mayilvaganan, Aromal Chekavar, Roma Pradhan, Amit Agarwal. Imaging in Differentiated Thyroid Cancer 71-84. [Crossref]

1512. Kwok Seng Loh, Donovon Kum Chuen Eu. Neck Dissection in Well-Differentiated Thyroid Cancer 97-108. [Crossref]

1513. Shreya Bhattacharya. 103. [Crossref]

1514. C. J. Auernhammer, M. Reincke. 2018. Funktionsdiagnostik in der Endokrinologie. *Der Internist* **59**:1, 38-47. [Crossref]

1515. Claudia Martinez-Rios, Alan Daneman, Lydia Bajno, Danielle C. M. van der Kaay, Rahim Moineddin, Jonathan D. Wasserman. 2018. Utility of adult-based ultrasound malignancy risk stratifications in pediatric thyroid nodules. *Pediatric Radiology* **48**:1, 74-84. [Crossref]

1516. Huy Gia Vuong, Uyen N. P. Duong, Thong Quang Pham, Hung Minh Tran, Naoki Oishi, Kunio Mochizuki, Tadao Nakazawa, Lewis Hassell, Ryohei Katoh, Tetsuo Kondo. 2018. Clinicopathological Risk Factors for Distant Metastasis in Differentiated Thyroid Carcinoma: A Meta-analysis. *World Journal of Surgery* **42**:4, 1005. [Crossref]

1517. Gabriele Materazzi, Lorenzo Fregoli, Piermarco Papini, Sohail Bakkar, Malince Chicas Vasquez, Paolo Miccoli. 2018. Robot-Assisted Transaxillary Thyroidectomy (RATT): A Series Appraisal of More than 250 Cases from Europe. *World Journal of Surgery* **42**:4, 1018. [Crossref]

1518. Frederik Schultz Pustelnik, Casper Gronbek, Helle Døssing, Nina Nguyen, Steen Joop Bonnema, Laszlo Hegedüs, Christian Godballe, Jesper Roed Sorensen. 2018. The compensatory enlargement of the remaining thyroid lobe following hemithyroidectomy is small and without impact on symptom relief. *European Archives of Oto-Rhino-Laryngology* **275**:1, 161-167. [Crossref]

1519. Zubair A. Khan, Sangita Mehta, Natarajan Sumathi, Muthuswamy Dhiwakar. 2018. Occult invasion of sternothyroid muscle by differentiated thyroid cancer. *European Archives of Oto-Rhino-Laryngology* **275**:1, 233-238. [Crossref]

1520. Angkoon Anuwong, Thanyawat Sasanakietkul, Pornpeera Jitpratoom, Khwannara Ketwong, Hoon Yub Kim, Gianlorenzo Dionigi, Jeremy D. Richmon. 2018. Transoral endoscopic thyroidectomy vestibular approach (TOETVA): indications, techniques and results. *Surgical Endoscopy* **32**:1, 456-465. [Crossref]

Downloaded by Memorial Sloan Kettering from www.liebertpub.com at 08/14/19. For personal use only.

1521. Donika Saporito, Pamela Brock, Heather Hampel, Jennifer Sipos, Soledad Fernandez, Sandya Liyanarachchi, Albert de la Chapelle, Rebecca Nagy. 2018. Penetrance of a rare familial mutation predisposing to papillary thyroid cancer. *Familial Cancer* **17**:3, 431. [Crossref]

1522. Pierpaolo Trimboli, Anna Crescenzi, Luca Giovanella. 2018. Performance of Italian Consensus for the Classification and Reporting of Thyroid Cytology (ICCRTC) in discriminating indeterminate lesions at low and high risk of malignancy. A systematic review and meta-analysis. *Endocrine* **60**:1, 31. [Crossref]

1523. G. Mazziotti, A. M. Formenti, M. B. Panarotto, E. Arvat, A. Chiti, A. Cuocolo, M. E. Dottorini, C. Durante, L. Agate, S. Filetti, F. Felicetti, A. Filice, L. Pace, T. Pellegrino, M. Rodari, M. Salvatori, C. Tranfaglia, A. Versari, D. Viola, S. Frara, A. Berruti, A. Giustina, R. Giubbini. 2018. Real-life management and outcome of thyroid carcinoma-related bone metastases: results from a nationwide multicenter experience. *Endocrine* **59**:1, 90-101. [Crossref]

1524. Nicole M. Iñiguez-Ariza, Marius N. Stan, Keith C. Bible. 2018. Effect of thyroid hormone suppression on control of advanced well-differentiated thyroid cancer. *Endocrine* **59**:1, 228-229. [Crossref]

1525. Bin Xu, Nada Farhat, Justine A. Barletta, Yin P. Hung, Dario de Biase, Gian Piero Casadei, Ayse Mine Onenerk, R. Michael Tuttle, Benjamin R. Roman, Nora Katabi, Vania Nosé, Peter Sadow, Giovanni Tallini, William C. Faquin, Ronald Ghossein. 2018. Should subcentimeter non-invasive encapsulated, follicular variant of papillary thyroid carcinoma be included in the noninvasive follicular thyroid neoplasm with papillary-like nuclear features category?. *Endocrine* **59**:1, 143-150. [Crossref]

1526. Martyna Borowczyk, Ewelina Szczepanek-Parulska, Michał Olejarz, Barbara Więckowska, Frederik A. Verburg, Szymon Dębicki, Bartłomiej Budny, Małgorzata Janicka-Jedyńska, Katarzyna Ziemnicka, Marek Ruchała. 2018. Evaluation of 167 Gene Expression Classifier (GEC) and ThyroSeq v2 Diagnostic Accuracy in the Preoperative Assessment of Indeterminate Thyroid Nodules: Bivariate/HROC Meta-analysis. *Endocrine Pathology* . [Crossref]

1527. Samskruthi P. Murthy, Deepak Balasubramanian, Adharsh Anand, Shashikant Vishnubhai Limbachiya, Narayana Subramaniam, Vasantha Nair, Krishnakumar Thankappan, Subramania Iyer. 2018. Extent of Thyroidectomy in Differentiated Thyroid Cancers —Review of Evidence. *Indian Journal of Surgical Oncology* **9**:1, 90. [Crossref]

1528. Chandan Kumar Jha, Vinita Agrawal, Anjali Mishra, P. K. Pradhan. 2018. Overt Skeletal Metastases in a Patient of Occult (Microscopic) Follicular Thyroid Carcinoma: a Rare Case. *Indian Journal of Surgical Oncology* **9**:1, 68. [Crossref]

1529. Benzon M. Dy, Ashok R. Shaha. 2018. Philosophy on Neck Dissection in Thyroid Cancer—Current Controversies and Consensus. *Indian Journal of Surgical Oncology* **9**:1, 2. [Crossref]

1530. Ivana Kholová, Camilla Schalin-Jäntti. Thyroid Fine Needle Aspiration Cytology 565-572. [Crossref]

1531. Barbara Jarzab, Jolanta Krajewska. Radioactive Iodine 688-692. [Crossref]

1532. Barbara Jarzab, Daria Handkiewicz-Junak, Jolanta Krajewska. Thyroid and Irradiation # . [Crossref]

1533. Sana Ghaznavi, Kirstie Lithgow, Veena Agrawal, Ralf Paschke. Nontoxic Goiter 524-528. [Crossref]

1534. Rossella Elisei. Thyroid Carcinoma 573-585. [Crossref]

1535. Mark P.J. Vanderpump. Epidemiology of Thyroid Disease 486-495. [Crossref]

1536. Laszlo Hegedüs. Thyroid Nodule 529-538. [Crossref]

1537. Kirstie Lithgow, Sana A. Ghaznavi, Alexandra Stephenson, Amita Mahajan, Ralf Paschke. Toxic Adenoma 723-729. [Crossref]

1538. Peter Mazzone. Healthy Patients at Risk for Lung Cancer 197-208. [Crossref]

1539. Lourdes Quintanilla-Dieck, Maisie Shindo. Evidence-Based Practice 175-184. [Crossref]

1540. Martin Schlumberger, Sophie Leboulleux, Bogdan Catargi, Desiree Deandreis, Slimane Zerdoud, Stephane Bardet, Daniela Rusu, Yann Godbert, Camille Buffet, Claire Schvartz, Pierre Vera, Olivier Morel, Danielle Benisvy, Claire Bournaud, Marie-Elisabeth Toubert, Antony Kelly, Ellen Benhamou, Isabelle Borget. 2018. Outcome after ablation in patients with low-risk thyroid cancer (ESTIMABL1): 5-year follow-up results of a randomised, phase 3, equivalence trial. *The Lancet Diabetes & Endocrinology* **6**:8, 618. [Crossref]

1541. Furio Pacini. 2018. Preferred strategy for postsurgical thyroid ablation in low-risk thyroid cancer. *The Lancet Diabetes & Endocrinology* **6**:8, 590. [Crossref]

1542. Melissa J. McGettigan, Robert A. Gatenby. 2018. Radiologic Pearls for Internists: A Case-Based Review. *The American Journal of Medicine* **131**:1, 9-16. [Crossref]

1543. A.S. McQueen, K.S. Bhatia. 2018. Head and neck ultrasound: technical advances, novel applications and the role of elastography. *Clinical Radiology* **73**:1, 81-93. [Crossref]

Downloaded by Memorial Sloan Kettering from www.liebertpub.com at 08/14/19. For personal use only.

1544. Jung Min Bae, Soo Yeon Hahn, Jung Hee Shin, Eun Young Ko. 2018. Inter-exam agreement and diagnostic performance of the Korean thyroid imaging reporting and data system for thyroid nodule assessment: Real-time versus static ultrasonography. *European Journal of Radiology* **98**, 14-19. [Crossref]

1545. Yanan Xu, Le Xu, Jiadong Wang. 2018. Clinical predictors of lymph node metastasis and survival rate in papillary thyroid microcarcinoma: analysis of 3607 patients at a single institution. *Journal of Surgical Research* **221**, 128-134. [Crossref]

1546. Akira Miyauchi, Takumi Kudo, Yasuhiro Ito, Hitomi Oda, Hisanori Sasai, Takuya Higashiyama, Mitsuhiro Fukushima, Hiroo Masuoka, Minoru Kihara, Akihiro Miya. 2018. Estimation of the lifetime probability of disease progression of papillary microcarcinoma of the thyroid during active surveillance. *Surgery* **163**:1, 48-52. [Crossref]

1547. Mashaal Dhir, Kelly L. McCoy, N. Paul Ohori, Cameron D. Adkisson, Shane O. LeBeau, Sally E. Carty, Linwah Yip. 2018. Correct extent of thyroidectomy is poorly predicted preoperatively by the guidelines of the American Thyroid Association for low and intermediate risk thyroid cancers. *Surgery* **163**:1, 81-87. [Crossref]

1548. Marra J. Aghajani, Tao Yang, Charles E. McCafferty, Susannah Graham, Xiaojuan Wu, Navin Niles. 2018. Predictive relevance of programmed cell death protein 1 and tumor-infiltrating lymphocyte expression in papillary thyroid cancer. *Surgery* **163**:1, 130-136. [Crossref]

1549. Rajshri Mainthia, Heather Wachtel, Yufei Chen, Elizabeth Mort, Sareh Parangi, Peter M. Sadow, Carrie C. Lubitz. 2018. Evaluating the projected surgical impact of reclassifying noninvasive encapsulated follicular variant of papillary thyroid cancer as noninvasive follicular thyroid neoplasm with papillary-like nuclear features. *Surgery* **163**:1, 60-65. [Crossref]

1550. Colleen M. Kiernan, Vivian L. Weiss, Mitra Mehrad, Kim Ely, Naira Baregamian, Carmen C. Solórzano. 2018. New terminology —noninvasive follicular neoplasm with papillary-like nuclear features (NIFTP) and its effect on the rate of malignancy at a single institution. *Surgery* **163**:1, 55-59. [Crossref]

1551. Maria F. Bates, Marcos R. Lamas, Reese W. Randle, Kristin L. Long, Susan C. Pitt, David F. Schneider, Rebecca S. Sippel. 2018. Back so soon? Is early recurrence of papillary thyroid cancer really just persistent disease?. *Surgery* **163**:1, 118-123. [Crossref]

1552. Reese W. Randle, Martha A. Zeiger. 2018. Editorial: Implications of implementing NIFTP terminology in the management of patients with thyroid tumors. *Surgery* **163**:1, 66-67. [Crossref]

1553. Aida Taye, Dillon Gurciullo, Brett A. Miles, Ashita Gupta, Randall P. Owen, William B. Inabnet, Jessica N. Beyda, Jennifer L. Marti. 2018. Clinical performance of a next-generation sequencing assay (ThyroSeq v2) in the evaluation of indeterminate thyroid nodules. *Surgery* **163**:1, 97-103. [Crossref]

1554. Courtney J. Balentine, David J. Vanness, David F. Schneider. 2018. Cost-effectiveness of lobectomy versus genetic testing (Afirma®) for indeterminate thyroid nodules: Considering the costs of surveillance. *Surgery* **163**:1, 88-96. [Crossref]

1555. Rosebel Monteiro, Amy Han, Muhammad Etiwy, Andrew Swearingen, Vikram Krishnamurthy, Judy Jin, Joyce J. Shin, Eren Berber, Allan E. Siperstein. 2018. Importance of surgeon-performed ultrasound in the preoperative nodal assessment of patients with potential thyroid malignancy. *Surgery* **163**:1, 112-117. [Crossref]

1556. Christoph F. Dietrich, Thomas Müller, Jörg Bojunga, Yi Dong, Giovanni Mauri, Maija Radzina, Manjiri Dighe, Xin-Wu Cui, Frank Grünwald, Andreas Schuler, Andre Ignee, Huedayi Korkusuz. 2018. Statement and Recommendations on Interventional Ultrasound as a Thyroid Diagnostic and Treatment Procedure. *Ultrasound in Medicine & Biology* **44**:1, 14-36. [Crossref]

1557. Raja R Seethala, Zubair W Baloch, Justine A Barletta, Elham Khanafshar, Ozgur Mete, Peter M Sadow, Virginia A LiVolsi, Yuri E Nikiforov, Giovanni Tallini, Lester DR Thompson. 2018. Noninvasive follicular thyroid neoplasm with papillary-like nuclear features: a review for pathologists. *Modern Pathology* **31**:1, 39-55. [Crossref]

1558. Yaoqi Wang, Jiaxue Gao, Xianying Meng, Zhenxin Wang. 2018. DNA microarray-based resonance light scattering assay for multiplexed detection of DNA mutation in papillary thyroid cancer. *The Analyst* **143**:4, 914-919. [Crossref]

1559. Mitchell Boehnke, Nayana Patel, Kristin McKinney, Toshimasa Clark. 2018. Diagnostic Performance of SRU and ATA Thyroid Nodule Classification Algorithms as Tested With a 1 Million Virtual Thyroid Nodule Model. *Current Problems in Diagnostic Radiology* **47**:1, 10-13. [Crossref]

1560. Ying Wei, Linxue Qian, Ji-Bin Liu, Yujiang Liu. 2018. Sonographic measurement of thyroid nodule changes after microwave ablation: relationship between multiple parameters. *International Journal of Hyperthermia* **34**:5, 660. [Crossref]

1561. So Yeong Jeong, Jung Hwan Baek, Young Jun Choi, Sae Rom Chung, Tae Yon Sung, Won Gu Kim, Tae Yong Kim, Jeong Hyun Lee. 2018. Radiofrequency ablation of primary thyroid carcinoma: efficacy according to the types of thyroid carcinoma. *International Journal of Hyperthermia* **34**:5, 611. [Crossref]

1562. Jianming Li, Yujiang Liu, Jibin Liu, Linxue Qian. 2018. Ultrasound-guided percutaneous microwave ablation versus surgery for papillary thyroid microcarcinoma. *International Journal of Hyperthermia* **34**:5, 653. [Crossref]

Downloaded by Memorial Sloan Kettering from www.liebertpub.com at 08/14/19. For personal use only.

1563. Xin Zhi, Ning Zhao, Yujiang Liu, Ji-Bin Liu, Changsheng Teng, Linxue Qian. 2018. Microwave ablation compared to thyroidectomy to treat benign thyroid nodules. *International Journal of Hyperthermia* **34**:5, 644. [Crossref]

1564. R. Michael Tuttle, Ling Zhang, Ashok Shaha. 2018. A clinical framework to facilitate selection of patients with differentiated thyroid cancer for active surveillance or less aggressive initial surgical management. *Expert Review of Endocrinology & Metabolism* **13**:2, 77. [Crossref]

1565. Ryan P Lau, John D Paulsen, Tamar C Brandler, Cheng Z Liu, Aylin Simsir, Fang Zhou. 2018. Impact of the Reclassification of "Noninvasive Encapsulated Follicular Variant of Papillary Thyroid Carcinoma" to "Noninvasive Follicular Thyroid Neoplasm With Papillary-Like Nuclear Features" on the Bethesda System for Reporting Thyroid Cytopathology. *American Journal of Clinical Pathology* **149**:1, 50-54. [Crossref]

1566. Kristina J. Nicholson, Linwah Yip. 2018. An update on the status of molecular testing for the indeterminate thyroid nodule and risk stratification of differentiated thyroid cancer. *Current Opinion in Oncology* **30**:1, 8-15. [Crossref]

1567. Danielle Elliott Range, Sara Xiaoyin Jiang. 2018. An update on noninvasive follicular thyroid neoplasm with papillary-like nuclear features. *Current Opinion in Oncology* **30**:1, 1-7. [Crossref]

1568. Wen Gao, Teng Zhao, Jun Liang, Yansong Lin. 2018. Is the ratio superior to the number of metastatic lymph nodes in addressing the response in patients with papillary thyroid cancer?. *Medicine* **97**:3, e9664. [Crossref]

1569. Zeenat Jabin, Seong Young Kwon, Hee-Seung Bom, Yansong Lin, Ke Yang, Anri Inaki, Ayu Rosemeilia Dewi, Akram N. Al-Ibraheem, Batool Al Balooshi, Teofilo O.L. San Luis. 2018. Clinico-social factors to choose radioactive iodine dose in differentiated thyroid cancer patients. *Nuclear Medicine Communications* **39**:4, 283. [Crossref]

1570. Chang Won Choi, Hwa Young Ahn. 2018. A Case of Zenker's Diverticulum Mimicking a Right Side Thyroid Nodule. *International Journal of Thyroidology* **11**:1, 56. [Crossref]

1571. Jung Kyu Park, Eon Ju Jeon. 2018. Infection of Thyroid Cyst Occurring 1 Month after Fine-Needle Aspiration in an Immunocompetent Patient. *International Journal of Thyroidology* **11**:2, 182. [Crossref]

1572. Eun Kyung Lee, Young Ki Lee, Yul Hwangbo, You Jin Lee. 2018. A Case Report of Severe Hypocalcemia and Hypothyroidism after Tyrosine Kinase Inhibitor Treatment. *International Journal of Thyroidology* **11**:2, 88. [Crossref]

1573. Sung-Hye You, Kyu Eun Lee, Roh-Eul Yoo, Hye Jeong Choi, Kyeong Cheon Jung, Jae-Kyung Won, Koung Mi Kang, Tae Jin Yoon, Seung Hong Choi, Chul-Ho Sohn, Ji-hoon Kim. 2018. Prevention of total thyroidectomy in noninvasive follicular thyroid neoplasm with papillary-like nuclear features (NIFTP) based on combined interpretation of ultrasonographic and cytopathologic results. *Clinical Endocrinology* **88**:1, 114-122. [Crossref]

1574. Matti L. Gild, Duncan J. Topliss, Diana Learoyd, Francis Parnis, Jeanne Tie, Brett Hughes, John P. Walsh, Donald S.A. McLeod, Roderick J. Clifton-Bligh, Bruce G. Robinson. 2018. Clinical guidance for radioiodine refractory differentiated thyroid cancer. *Clinical Endocrinology* **88**:4, 529. [Crossref]

1575. Hui Li, Ying-qiang Zhang, Chen Wang, Xin Zhang, Xin Li, Yan-song Lin. 2018. Delayed initial radioiodine therapy related to incomplete response in low- to intermediate-risk differentiated thyroid cancer. *Clinical Endocrinology* **88**:4, 601. [Crossref]

1576. Hongxiu Luo, Andrew Tobey, Sungyoung Auh, Craig Cochran, Marina Zemskova, James Reynolds, Cristiane Lima, Kenneth Burman, Leonard Wartofsky, Monica Skarulis, Electron Kebebew, Joanna Klubo-Gwiezdzinska. 2018. The effect of lithium on the progression-free and overall survival in patients with metastatic differentiated thyroid cancer undergoing radioactive iodine therapy. *Clinical Endocrinology* **89**:4, 481. [Crossref]

1577. E. D. Rossi, M. Martini, S. Capodimonti, T. Cenci, M. Bilotta, F. Pierconti, A. Pontecorvi, C. P. Lombardi, G. Fadda, L. M. Larocca. 2018. Morphology combined with ancillary techniques: An algorithm approach for thyroid nodules. *Cytopathology* **29**:5, 418. [Crossref]

1578. Bin Xu, Ronald A Ghossein. 2018. Crucial parameters in thyroid carcinoma reporting - challenges, controversies and clinical implications. *Histopathology* **72**:1, 32-39. [Crossref]

1579. Zubair W Baloch, Virginia A LiVolsi. 2018. Special types of thyroid carcinoma. *Histopathology* **72**:1, 40-52. [Crossref]

1580. Yin P Hung, Justine A Barletta. 2018. A user's guide to non-invasive follicular thyroid neoplasm with papillary-like nuclear features (NIFTP). *Histopathology* **72**:1, 53-69. [Crossref]

1581. Thaís Gomes de Melo, Ligia Vera Montali da Assumpção, Denise Engelbrecht Zantut-Wittmann. 2018. Interplay between Body Size Measures and Thyroid Cancer Aggressiveness: A Retrospective Analysis. *International Journal of Endocrinology* **2018**, 1. [Crossref]

1582. Ben Ma, Weibo Xu, Wenjun Wei, Duo Wen, Zhongwu Lu, Shuwen Yang, Tongzhen Chen, Yulong Wang, Yu Wang, Qinghai Ji. 2018. Clinicopathological and Survival Outcomes of Well-Differentiated Thyroid Carcinoma Undergoing Dedifferentiation: A Retrospective Study from FUSCC. *International Journal of Endocrinology* **2018**, 1-11. [Crossref]

Downloaded by Memorial Sloan Kettering from www.liebertpub.com at 08/14/19. For personal use only.

1583. Fernando Fernández-Ramírez, Luis M. Hurtado-López, Mario A. López, Eva Martínez-Peñafiel, Norma E. Herrera-González, Luis Kameyama, Omar Sepúlveda-Robles. 2018. BRAF 1799T>A Mutation Frequency in Mexican Mestizo Patients with Papillary Thyroid Cancer. *BioMed Research International* **2018**, 1-5. [Crossref]

1584. Jing Hang, Fan Li, Xiao-hui Qiao, Xin-hua Ye, Ao Li, Lian-fang Du. 2018. Combination of Maximum Shear Wave Elasticity Modulus and TIRADS Improves the Diagnostic Specificity in Characterizing Thyroid Nodules: A Retrospective Study. *International Journal of Endocrinology* **2018**, 1. [Crossref]

1585. Xia Wu, Lu Gao, Xiaopeng Guo, Qiang Wang, Zihao Wang, Wei Lian, Wei Liu, Jian Sun, Bing Xing. 2018. GH, IGF-1, and Age Are Important Contributors to Thyroid Abnormalities in Patients with Acromegaly. *International Journal of Endocrinology* **2018**, 1-8. [Crossref]

1586. Yi Chen, Chunfang Zhu, Yingchao Chen, Ningjian Wang, Qin Li, Bing Han, Li Zhao, Chi Chen, Hualing Zhai, Yingli Lu. 2018. The Association of Thyroid Nodules with Metabolic Status: A Cross-Sectional SPECT-China Study. *International Journal of Endocrinology* **2018**, 1-8. [Crossref]

1587. Riju Menon, C. Gopalakrishnan Nair, Misha Babu, Pradeep Jacob, G. Praveen Krishna. 2018. The Outcome of Papillary Thyroid Cancer Associated with Graves' Disease: A Case Control Study. *Journal of Thyroid Research* **2018**, 1-5. [Crossref]

1588. Niki Margari, Ilias Giovannopoulos, Abraham Pouliakis, Emmanouil Mastorakis, Alina Roxani Gouloumi, Ioannis G. Panayiotides, Petros Karakitsos. 2018. Application of Immunocytochemistry on Cell Block Sections for the Investigation of Thyroid Lesions. *Acta Cytologica* **62**:2, 137-144. [Crossref]

1589. Pedro Weslley Souza Rosario. 2018. Nodules ≤1 cm with Highly Suspicious Ultrasound Features and Papillary Microcarcinoma of the Thyroid: Is Fine-Needle Aspiration Cytology Necessary before Deciding on Active Surveillance?. *European Thyroid Journal* **7**:3, 162-162. [Crossref]

1590. Mehmet A. Gulcelik, Lutfi Dogan, Gokhan G. Akgul, Erhan H. Güven, Neşe Ersöz Gulcelik. 2018. Completion Thyroidectomy: Safer than Thought. *Oncology Research and Treatment* **41**:6, 386-390. [Crossref]

1591. Marie Alix Balay, Patrick Aidan, Marie Helene Schlageter, Odette Georges, Taly Meas, Maroun Bechara, Marie Elisabeth Toubert, Isabelle Faugeron, Herve Monpeyssen, Cécile N. Chougnet. 2018. Successful Treatment of Differentiated Thyroid Carcinoma with Transaxillary Robotic Surgery and Radioiodine: The First European Experience. *European Thyroid Journal* **7**:3, 149-154. [Crossref]

1592. Kassia B. Reuters, Maria C.O.C. Mamone, Elsa S. Ikejiri, Cleber P. Camacho, Claudia C.D. Nakabashi, Carolina C.P.S. Janovsky, Ji H. Yang, Danielle M. Andreoni, Rosalia Padovani, Rui M.B. Maciel, Felipe A.B. Vanderlei, Rosa P.M. Biscolla. 2018. Bethesda Classification and Cytohistological Correlation of Thyroid Nodules in a Brazilian Thyroid Disease Center. *European Thyroid Journal* **7**:3, 133-138. [Crossref]

1593. Yvonne Hewett, Subash Ghimire, Bilal Farooqi, Binay K Shah. 2018. Lenvatinib – A multikinase inhibitor for radioiodine-refractory differentiated thyroid cancer. *Journal of Oncology Pharmacy Practice* **24**:1, 28-32. [Crossref]

1594. Gloria Ramos Rivera, Sheila Segura, Mark Suhrland. 2018. Educational Case: Thyroid Neoplasms. *Academic Pathology* **5**, 237428951877747. [Crossref]

1595. Stella Bernardi, Andrea Michelli, Deborah Bonazza, Veronica Calabrò, Fabrizio Zanconati, Gabriele Pozzato, Bruno Fabris. 2018. Usefulness of core needle biopsy for the diagnosis of thyroid Burkitt's lymphoma: a case report and review of the literature. *BMC Endocrine Disorders* **18**:1. . [Crossref]

1596. Krzysztof Kaliszewski, Agnieszka Zubkiewicz-Kucharska, Paweł Kiełb, Jerzy Maksymowicz, Aleksander Krawczyk, Otto Krawiec. 2018. Comparison of the prevalence of incidental and non-incidental papillary thyroid microcarcinoma during 2008–2016: a single-center experience. *World Journal of Surgical Oncology* **16**:1. . [Crossref]

1597. Gherardo Mazziotti, Anna Maria Formenti, Stefano Frara, Roberto Olivetti, Giuseppe Banfi, Maurizio Memo, Roberto Maroldi, Raffaele Giubbini, Andrea Giustina. 2018. High Prevalence of Radiological Vertebral Fractures in Women on Thyroid-Stimulating Hormone–Suppressive Therapy for Thyroid Carcinoma. *The Journal of Clinical Endocrinology & Metabolism* **103**:3, 956. [Crossref]

1598. Ki Wan Park, James X Wu, Lin Du, Angela M Leung, Michael W Yeh, Masha J Livhits. 2018. Decreasing Use of Radioactive Iodine for Low-Risk Thyroid Cancer in California, 1999 to 2015. *The Journal of Clinical Endocrinology & Metabolism* **103**:3, 1095. [Crossref]

1599. Dorina Ylli, Kenneth D Burman, Douglas Van Nostrand, Leonard Wartofsky. 2018. Eliminating the Age Cutoff in Staging of Differentiated Thyroid Cancer: The Safest Road?. *The Journal of Clinical Endocrinology & Metabolism* **103**:5, 1813. [Crossref]

1600. Livia Lamartina, Giorgio Grani, Cosimo Durante, Sebastiano Filetti. 2018. Recent advances in managing differentiated thyroid cancer. *F1000Research* **7**, 86. [Crossref]

Downloaded by Memorial Sloan Kettering from www.liebertpub.com at 08/14/19. For personal use only.

1601. Ji Won Seo, Kyunghwa Han, Jandee Lee, Eun-Kyung Kim, Hee Jung Moon, Jung Hyun Yoon, Vivian Youngjean Park, Hyeon-Man Baek, Jin Young Kwak, Aamir Ahmad. 2018. Application of metabolomics in prediction of lymph node metastasis in papillary thyroid carcinoma. *PLOS ONE* **13**:3, e0193883. [Crossref]

1602. Tetsuya Higuchi, Arifudin Achmad, Duong Duc Binh, Anu Bhattarai, Yoshito Tsushima. 2018. Determining patient selection tool and response predictor for outpatient 30 mCi radioiodine ablation dose in non-metastatic differentiated thyroid carcinoma: a Japanese perspective. *Endocrine Journal* **65**:3, 345-357. [Crossref]

1603. Kiminori Sugino, Mitsuji Nagahama, Wataru Kitagawa, Keiko Ohkuwa, Takashi Uruno, Kenichi Matsuzu, Akifumi Suzuki, Chie Masaki, Junko Akaishi, Kiyomi Y. Hames, Chisato Tomoda, Yuna Ogimi, Koichi Ito. 2018. Clinical factors related to the efficacy of tyrosine kinase inhibitor therapy in radioactive iodine refractory recurrent differentiated thyroid cancer patients. *Endocrine Journal* **65**:3, 299-306. [Crossref]

1604. Miyoko Higuchi, Mitsuyoshi Hirokawa, Risa Kanematsu, Aki Tanaka, Ayana Suzuki, Naoki Yamao, Toshitetsu Hayashi, Seiji Kuma, Akira Miyauchi. 2018. Impact of the modification of the diagnostic criteria in the 2017 Bethesda System for Reporting Thyroid Cytopathology: a report of a single institution in Japan. *Endocrine Journal* **65**:12, 1193-1198. [Crossref]

1605. Giorgio Grani, Livia Lamartina, Vito Cantisani, Marianna Maranghi, Piernatale Lucia, Cosimo Durante. 2018. Interobserver agreement of various thyroid imaging reporting and data systems. *Endocrine Connections* **7**:1, 1-7. [Crossref]

1606. Luis Furuya-Kanamori, Art Sedrakyan, Adedayo A Onitilo, Nasser Bagheri, Paul Glasziou, Suhail A R Doi. 2018. Differentiated thyroid cancer: millions spent with no tangible gain?. *Endocrine-Related Cancer* **25**:1, 51-57. [Crossref]

1607. Maria Lucia D ArboAlves, Manoel Henrique Cintra Gabarra. 2018. Clinical, laboratory and ultrasound profile of patients with thyroid cysts. *Endocrinology&Metabolism International Journal* **6**:6. . [Crossref]

1608. Ramón González Fernández. 2018. Conservative surgery and the total thyroidectomy in well-Differentiated thyroid cancer. *Women's Health* **7**:6. . [Crossref]

1609. Ricardo Mai Rocha, Maria Carmen Lopes Ferreira Siva Santos, Carlos Musso, Marco Homero de Sá Santos, Marcelo Lemos de-Almeida, Gustavo Peixoto Soares Miguel. 2018. Carcinoma bem diferenciado de tireoide: perfil epidemiológico, resultados cirúrgicos e resposta oncológica. *Revista do Colégio Brasileiro de Cirurgiões* **45**:5. . [Crossref]

1610. Hoon Yub Kim, Ralph P. Tufano, Young Jun Chai, Marcin Barczynski, Özer Makay, Che-Wei Wu, Eren Berber, Hui Sun, Gianlorenzo Dionigi. 2018. Intraoperative Neural Monitoring in Thyroid Surgery: Role and Responsibility of Surgeon. *Journal of Endocrine Surgery* **18**:1, 49. [Crossref]

1611. Giuseppe Navarra, Guido Nicola Zanghì, Francesco Freni, Bruno Galletti, Francesco Galletti, Grazia Pagano, Andrea Cogliandolo, Alberto Barbera, Salvatore Lazzara, Gianlorenzo Dionigi. 2018. Treatment Decision Making in Papillary Thyroid Microcarcinoma. *Journal of Endocrine Surgery* **18**:2, 110. [Crossref]

1612. Sang Wook Jo, Ha Kyoung Park, Tae Kwun Ha. 2018. Prediction of Contralateral Occult Malignant Nodule in Patients with Unilaterally Confined Papillary Thyroid Carcinomas. *Journal of Endocrine Surgery* **18**:3, 191. [Crossref]

1613. S. V. Vertyankin, I. A. Turlykova, V. L. Meshcheryakov, V. V. Grekov, V. V. Yakubenko. 2018. On the issue of classification of approaches and surgical techniques in thyroid and parathyroid surgery. *Endoskopicheskaya khirurgiya* **24**:3, 56. [Crossref]

1614. A. V. Sidorin, A. Yu. Abrosimov, T. I. Rogunovich, P. O. Rumyantsev, K. S. Nizhegorodova, P. A. Isaev, A. P. Shinkarkina, S. Yamasita, V. A. Saenko. 2018. Clinical, morphological, and prognostic features of papillary thyroid carcinoma with different BRAF mutational status assessed by immunohistochemistry. *Arkhiv patologii* **80**:3, 19. [Crossref]

1615. João Roberto M. Martins. 2018. The Janus faces of thyroid carcinoma. *Archives of Endocrinology and Metabolism* **62**:1, 1-3. [Crossref]

1616. Inés Califano, Susana Deutsch, Alicia Löwenstein, Carmen Cabezón, Fabián Pitoia. 2018. Outcomes of patients with bone metastases from differentiated thyroid cancer. *Archives of Endocrinology and Metabolism* **62**:1, 14-20. [Crossref]

1617. José M. Domínguez, Flavia Nilo, María T. Martínez, José M. Massardo, Sueli Muñoz, Tania Contreras, Rocío Carmona, Joaquín Jerez, Hernán González, Nicolás Droppelmann, Augusto León. 2018. Papillary thyroid microcarcinoma: characteristics at presentation, and evaluation of clinical and histological features associated with a worse prognosis in a Latin American cohort. *Archives of Endocrinology and Metabolism* **62**:1, 6-13. [Crossref]

1618. Carolina Ferraz. 2018. Can current molecular tests help in the diagnosis of indeterminate thyroid nodule FNAB?. *Archives of Endocrinology and Metabolism* **62**:6, 576-584. [Crossref]

1619. Fabián Pitoia, Angélica Schmidt, Fernanda Bueno, Erika Abelleira, Fernando Jerkovich. 2018. Rare complications of multikinase inhibitor treatment. *Archives of Endocrinology and Metabolism* **62**:6, 636-640. [Crossref]

1620. Debora L. S. Danilovic, Suemi Marui. 2018. Critical analysis of molecular tests in indeterminate thyroid nodules. *Archives of Endocrinology and Metabolism* **62**:6, 572-575. [Crossref]

Downloaded by Memorial Sloan Kettering from www.liebertpub.com at 08/14/19. For personal use only.

1621. Jie-Eun Lee, Dong Hwa Lee, Tae Jung Oh, Kyoung Min Kim, Sung Hee Choi, Soo Lim, Young Joo Park, Do Joon Park, Hak Chul Jang, Jae Hoon Moon. 2018. Clinical Feasibility of Monitoring Resting Heart Rate Using a Wearable Activity Tracker in Patients With Thyrotoxicosis: Prospective Longitudinal Observational Study. *JMIR mHealth and uHealth* **6**:7, e159. [Crossref]

1622. Samuel A. Stewart, Murali Rajaraman, Andreu F. Costa. 2018. Web-Based Tool for Standardized Reporting of Thyroid Ultrasound Studies. *American Journal of Roentgenology* **210**:1, 39-42. [Crossref]

1623. Manolhas Karkada, Andreu F. Costa, Syed Ali Imran, Robert D. Hart, Martin Bullock, Gabriela Ilie, Murali Rajaraman. 2018. Incomplete Thyroid Ultrasound Reports for Patients With Thyroid Nodules: Implications Regarding Risk Assessment and Management. *American Journal of Roentgenology* **211**:6, 1348. [Crossref]

1624. V. I. Kolomiytsev, V. N. Marina, O. V. Lukavetskiy, Yu. P. Dovgan. 2018. EVALUATION OF THE ULTRASONOGRAPHIC SCALE IN THYROID CANCER RISK STRATIFICATION. *World of Medicine and Biology* **14**:65, 078. [Crossref]

1625. O. V. Chernenko. 2018. RELATIONSHIP BETWEEN THYROID STIMULATING HORMONE AND THYROID CANCER. *Bulletin of Problems Biology and Medicine* **2**:4, 84. [Crossref]

1626. I. Erdem Toslak, B. Martin, G.A. Barkan, A.I. Kılıç, J.E. Lim-Dunham. 2018. Patterns of Sonographically Detectable Echogenic Foci in Pediatric Thyroid Carcinoma with Corresponding Histopathology: An Observational Study. *American Journal of Neuroradiology* **39**:1, 156-161. [Crossref]

1627. Sarah B. Fisher, Nancy D. Perrier. 2018. The incidental thyroid nodule. *CA: A Cancer Journal for Clinicians* **68**:2, 97. [Crossref]

1628. Hyereen Kim, Bo Hyun Kim, Young Keum Kim, Jeong Mi Kim, Seo Young Oh, Eun Heui Kim, Min Jin Lee, Jong Ho Kim, Yun Kyung Jeon, Sang Soo Kim, Byung Joo Lee, Yong Ki Kim, In Joo Kim. 2018. Prevalence of BRAF V600E Mutation in Follicular Variant of Papillary Thyroid Carcinoma and Non-Invasive Follicular Tumor with Papillary-Like Nuclear Features (NIFTP) in a BRAF V600E Prevalent Area. *Journal of Korean Medical Science* **33**:27. . [Crossref]

1629. Hyun Kyung Lim, Eun Ju Ha, In Young Youn, Jung Hyun Yoon, Jung Hwan Baek, Kyung Hyun Do, Miyoung Choi, Jin A Choi, Min Lee, Dong Gyu Na. 2018. Guidelines for Primary Imaging Test and Biopsy Methods in the Diagnosis of Thyroid Nodules: Joint Report by the Korean Society of Radiology and National Evidence-Based Healthcare Collaborating Agency. *Journal of the Korean Society of Radiology* **79**:1, 1. [Crossref]

1630. Ik Jung Hwang, Dong Wook Kim, Yoo Jin Lee, Hye Jung Choo, Soo Jin Jung, Hye Jin Baek. 2018. Ultrasonographic Interval Changes in Solid Thyroid Nodules after Ultrasonography-Guided Fine-Needle Aspiration. *Korean Journal of Radiology* **19**:1, 158. [Crossref]

1631. Silvia Oddo, Edineia Felix, Michele Mussap, Massimo Giusti. 2018. Quality of Life in Patients Treated with Percutaneous Laser Ablation for Non-Functioning Benign Thyroid Nodules: A Prospective Single-Center Study. *Korean Journal of Radiology* **19**:1, 175. [Crossref]

1632. Min Ji Hong, Dong Gyu Na, Jung Hwan Baek, Jin Yong Sung, Ji-Hoon Kim. 2018. Impact of Nodule Size on Malignancy Risk Differs according to the Ultrasonography Pattern of Thyroid Nodules. *Korean Journal of Radiology* **19**:3, 534. [Crossref]

1633. Eun Ju Ha, Hyun Kyung Lim, Jung Hyun Yoon, Jung Hwan Baek, Kyung Hyun Do, Miyoung Choi, Jin A Choi, Min Lee, Dong Gyu Na. 2018. Primary Imaging Test and Appropriate Biopsy Methods for Thyroid Nodules: Guidelines by Korean Society of Radiology and National Evidence-Based Healthcare Collaborating Agency. *Korean Journal of Radiology* **19**:4, 623. [Crossref]

1634. Ji-hoon Kim, Jung Hwan Baek, Hyun Kyung Lim, Hye Shin Ahn, Seon Mi Baek, Yoon Jung Choi, Young Jun Choi, Sae Rom Chung, Eun Ju Ha, Soo Yeon Hahn, So Lyung Jung, Dae Sik Kim, Soo Jin Kim, Yeo Koon Kim, Chang Yoon Lee, Jeong Hyun Lee, Kwang Hwi Lee, Young Hen Lee, Jeong Seon Park, Hyesun Park, Jung Hee Shin, Chong Hyun Suh, Jin Yong Sung, Jung Suk Sim, Inyoung Youn, Miyoung Choi, Dong Gyu Na. 2018. 2017 Thyroid Radiofrequency Ablation Guideline: Korean Society of Thyroid Radiology. *Korean Journal of Radiology* **19**:4, 632. [Crossref]

1635. Jooyeon Cho, Jung Hee Shin, Soo Yeon Hahn, Young Lyun Oh. 2018. Columnar Cell Variant of Papillary Thyroid Carcinoma: Ultrasonographic and Clinical Differentiation between the Indolent and Aggressive Types. *Korean Journal of Radiology* **19**:5, 1000. [Crossref]

1636. Soo Yeon Hahn, Jung Hee Shin, Eun Young Ko, Jung Min Bae, Ji Soo Choi, Ko Woon Park. 2018. Complementary Role of Elastography Using Carotid Artery Pulsation in the Ultrasonographic Assessment of Thyroid Nodules: A Prospective Study. *Korean Journal of Radiology* **19**:5, 992. [Crossref]

1637. Sunghwan Suh, Yun Hak Kim, Tae Sik Goh, Dae Cheon Jeong, Chi-Seung Lee, Jeon Yeob Jang, Wonjae Cha, Myoung-Eun Han, Seong-Jang Kim, In Joo Kim, Kyoungjune Pak. 2018. mRNA Expression of SLC5A5 and SLC2A Family Genes in Papillary Thyroid Cancer: An Analysis of The Cancer Genome Atlas. *Yonsei Medical Journal* **59**:6, 746. [Crossref]

1638. Yoo Jin Lee, Dong Wook Kim, Gi Won Shin, Young Jin Heo, Jin Wook Baek, Young Jun Cho, Young Mi Park, Ha Kyoung Park, Tae Kwun Ha, Do Hun Kim, Soo Jin Jung, Ji Sun Park, Ki Jung Ahn, Hye Jin Baek. 2018. Appropriate Frequency and Interval

Downloaded by Memorial Sloan Kettering from www.liebertpub.com at 08/14/19. For personal use only.

of Neck Ultrasonography Surveillance during the First 10Years after Total Thyroidectomy in Patients with Papillary Thyroid Carcinoma. *Frontiers in Endocrinology* **9**. . [Crossref]

1639. Hye-Seon Oh, Hyemi Kwon, Suyeon Park, Mijin Kim, Min Ji Jeon, Tae Yong Kim, Young Kee Shong, Won Bae Kim, Jene Choi, Won Gu Kim, Dong Eun Song. 2018. Comparison of Immunohistochemistry and Direct Sanger Sequencing for Detection of the BRAF V600E Mutation in Thyroid Neoplasm. *Endocrinology and Metabolism* **33**:1, 62. [Crossref]

1640. Jie-Eun Lee, Dong Hwa Lee, Tae Jung Oh, Kyoung Min Kim, Sung Hee Choi, Soo Lim, Young Joo Park, Do Joon Park, Hak Chul Jang, Jae Hoon Moon. 2018. Validity and Reliability of the Korean Version of the Hyperthyroidism Symptom Scale. *Endocrinology and Metabolism* **33**:1, 70. [Crossref]

1641. Nicole M. Iñiguez-Ariza, Juan P. Brito. 2018. Management of Low-Risk Papillary Thyroid Cancer. *Endocrinology and Metabolism* **33**:2, 185. [Crossref]

1642. Sung Hye Kong, Jung Ah Lim, Young Shin Song, Shinje Moon, Ye An Kim, Min Joo Kim, Sun Wook Cho, Jae Hoon Moon, Ka Hee Yi, Do Joon Park, Bo Youn Cho, Young Joo Park. 2018. Star-Shaped Intense Uptake of 131 I on Whole Body Scans Can Reflect Good Therapeutic Effects of Low-Dose Radioactive Iodine Treatment of 1.1 GBq. *Endocrinology and Metabolism* **33**:2, 228. [Crossref]

1643. Jae Hoon Moon, Ji-hoon Kim, Eun Kyung Lee, Kyu Eun Lee, Sung Hye Kong, Yeo Koon Kim, Woo-jin Jung, Chang Yoon Lee, Roh-Eul Yoo, Yul Hwangbo, Young Shin Song, Min Joo Kim, Sun Wook Cho, Su-jin Kim, Eun Jae Jung, June Young Choi, Chang Hwan Ryu, You Jin Lee, Jeong Hun Hah, Yuh-Seog Jung, Junsun Ryu, Yunji Hwang, Sue K. Park, Ho Kyung Sung, Ka Hee Yi, Do Joon Park, Young Joo Park. 2018. Study Protocol of Multicenter Prospective Cohort Study of Active Surveillance on Papillary Thyroid Microcarcinoma (MAeSTro). *Endocrinology and Metabolism* **33**:2, 278. [Crossref]

1644. Iwao SUGITANI. 2018. Introduction of Multi-Kinase Inhibitors for the Treatment of Thyroid Cancer. *Nihon Rinsho Geka Gakkai Zasshi (Journal of Japan Surgical Association)* **79**:1, 1-11. [Crossref]

1645. J Jonklaas, SRK Murthy, D Liu, J Klubo-Gwiezdzinska, J Krishnan, KD Burman, L Boyle, N Carrol, E Felger, Y P Loh. 2018. Novel biomarker SYT12 may contribute to predicting papillary thyroid cancer outcomes. *Future Science OA* **4**:1, FSO249. [Crossref]

1646. Natalie A. Calcatera, Waseem Lutfi, Paritosh Suman, Nicholas R. Suss, Chi-Hsiung Wang, Richard A. Prinz, David J. Winchester, Tricia A. Moo-Young. 2018. CONCORDANCE OF PRE-OPERATIVE CLINICAL STAGE WITH PATHOLOGIC STAGE IN PATIENTS ≥45 YEARS OLD WITH WELL-DIFFERENTIATED THYROID CANCER. *Endocrine Practice* **24**:1, 27-32. [Crossref]

1647. Quan-Yang Duh, Wen T. Shen. 2018. CLINICAL IMPLICATIONS OF POSTOPERATIVE UPSTAGING OF DIFFERENTIATED THYROID CANCER BASED UPON PATHOLOGIC EVALUATION. *Endocrine Practice* **24**:1, 124-125. [Crossref]

1648. Young Woo Chang, Hye Yoon Lee, Hwan Soo Kim, Hoon Yub Kim, Jae Bok Lee, Gil Soo Son. 2018. Extent of central lymph node dissection for papillary thyroid carcinoma in the isthmus. *Annals of Surgical Treatment and Research* **94**:5, 229. [Crossref]

1649. Min Joo Kim, Ka Hee Yi. 2018. Thyroid nodules with discordant results of ultrasonographic and fine-needle aspiration findings. *Journal of the Korean Medical Association* **61**:4, 225. [Crossref]

1650. Jae Hoon Moon, Young Joo Park. 2018. Diagnosis and treatment of low-risk papillary thyroid microcarcinoma. *Journal of the Korean Medical Association* **61**:4, 232. [Crossref]

1651. Vicki J. Schnadig. 2018. Overdiagnosis of Thyroid Cancer: Is This Not an Ethical Issue for Pathologists As Well As Radiologists and Clinicians?. *Archives of Pathology & Laboratory Medicine* **142**:9, 1018. [Crossref]

1652. Huihui Ren, Zhelong Liu, Siyue Liu, Xinrong Zhou, Hong Wang, Jinchao Xu, Daowen Wang, Gang Yuan. 2018. Profile and clinical implication of circular RNAs in human papillary thyroid carcinoma. *PeerJ* **6**, e5363. [Crossref]

1653. Michelle-Linh T. Nguyen, Jiaqi Hu, Katherine G. Hastings, Eric J. Daza, Mark R. Cullen, Lisa A. Orloff, Latha P. Palaniappan. 2017. Thyroid cancer mortality is higher in Filipinos in the United States: An analysis using national mortality records from 2003 through 2012. *Cancer* **123**:24, 4860-4867. [Crossref]

1654. Beatriz Godoi Cavalheiro, Ana Kober Nogueira Leite, Leandro Luongo de Matos, Aline Palermo Miazaki, Jan Marcel Ientile, Marco Aurelio V. Kulcsar, Claudio Roberto Cernea. 2017. Malignancy Rates in Thyroid Nodules Classified as Bethesda Categories III and IV: Retrospective Data from a Tertiary Center. *International Journal of Endocrinology and Metabolism* **16**:1. . [Crossref]

1655. Francesco Felicetti, Alice Nervo, Alessandro Piovesan, Rita Berardelli, Filippo Marchisio, Marco Gallo, Emanuela Arvat. 2017. Tyrosine kinase inhibitors rechallenge in solid tumors: a review of literature and a case description with lenvatinib in thyroid cancer. *Expert Review of Anticancer Therapy* **17**:12, 1093-1098. [Crossref]

1656. Fish Stephanie A.. 2017. Shear-Wave Elastography in Thyroid Nodules Fails to Discriminate Between Benign and Malignant Tumors. *Clinical Thyroidology* **29**:12, 457-460. [Citation] [Full Text] [PDF] [PDF Plus]

Downloaded by Memorial Sloan Kettering from www.liebertpub.com at 08/14/19. For personal use only.

1657. Biermann Martin. 2017. FDG-Avid Thyroid Incidentalomas on PET–CT Ordered for Other Malignancies Have No Prognostic Significance in a Large Retrospective Cohort. *Clinical Thyroidology* **29**:12, 461-464. [Citation] [Full Text] [PDF] [PDF Plus]

1658. Livhits Masha J., Yeh Michael W.. 2017. Rate of Nodule Growth on Surveillance Ultrasound Predicts Risk of Malignancy. *Clinical Thyroidology* **29**:12, 465-467. [Citation] [Full Text] [PDF] [PDF Plus]

1659. Emerson Charles H.. 2017. Second Radioactive Iodine Treatment Alone Is of Little Benefit in Treating Patients with Locoregional Persistent Differentiated Thyroid Carcinoma Who Previously Have Been Treated with Total Thyroidectomy and Ablative Radioactive Iodine. *Clinical Thyroidology* **29**:12, 468-471. [Citation] [Full Text] [PDF] [PDF Plus]

1660. Sacks Wendy. 2017. Lymphovascular Invasion Is a Predictor of Prognosis for Patients with Well-Differentiated Papillary Thyroid Carcinoma. *Clinical Thyroidology* **29**:12, 478-481. [Citation] [Full Text] [PDF] [PDF Plus]

1661. Ha Eun Ju, Baek Jung Hwan, Na Dong Gyu. 2017. Risk Stratification of Thyroid Nodules on Ultrasonography: Current Status and Perspectives. *Thyroid* **27**:12, 1463-1468. [Abstract] [Full Text] [PDF] [PDF Plus]

1662. Hernandez-Prera Juan C., Machado Rosalie A., Asa Sylvia L., Baloch Zubair, Faquin William C., Ghossein Ronald, LiVolsi Virginia A., Lloyd Ricardo V., Mete Ozgur, Nikiforov Yuri E., Seethala Raja R., Suster Saul, Thompson Lester D., Turk Andrew T., Sadow Peter M., Urken Mark L., Wenig Bruce M.. 2017. Pathologic Reporting of Tall-Cell Variant of Papillary Thyroid Cancer: Have We Reached a Consensus?. *Thyroid* **27**:12, 1498-1504. [Abstract] [Full Text] [PDF] [PDF Plus] [Supplementary Material]

1663. Lamartina Livia, Durante Cosimo, Lucisano Giuseppe, Grani Giorgio, Bellantone Rocco, Lombardi Celestino Pio, Pontecorvi Alfredo, Arvat Emanuela, Felicetti Francesco, Zatelli Maria C., Rossi Roberta, Puxeddu Efisio, Morelli Silvia, Torlontano Massimo, Crocetti Umberto, Montesano Teresa, Giubbini Raffaele, Orlandi Fabio, Aimaretti Gianluca, Monzani Fabio, Attard Marco, Francese Cecilia, Antonelli Alessandro, Limone Paolo, Rossetto Ruth, Fugazzola Laura, Meringolo Domenico, Bruno Rocco, Tumino Salvatore, Ceresini Graziano, Centanni Marco, Monti Salvatore, Salvatore Domenico, Spiazzi Giovanna, Mian Caterina, Persani Luca, Barbaro Daniele, Nicolucci Antonio, Filetti Sebastiano. 2017. Are Evidence-Based Guidelines Reflected in Clinical Practice? An Analysis of Prospectively Collected Data of the Italian Thyroid Cancer Observatory. *Thyroid* **27**:12, 1490-1497. [Abstract] [Full Text] [PDF] [PDF Plus] [Supplementary Material]

1664. Ha Su Min, Ahn Hye Shin, Baek Jung Hwan, Ahn Hwa Young, Chung Yun Jae, Cho Bo Youn, Park Sung Bin. 2017. Validation of Three Scoring Risk-Stratification Models for Thyroid Nodules. *Thyroid* **27**:12, 1550-1557. [Abstract] [Full Text] [PDF] [PDF Plus] [Supplementary Material]

1665. Klein Hesselink Mariëlle S., Bocca Gianni, Hummel Yoran M., Brouwers Adrienne H., Burgerhof Johannes G.M., van Dam Eveline W.C.M., Gietema Jourik A., Havekes Bas, van den Heuvel-Eibrink Marry M., Corssmit Eleonora P.M., Kremer Leontien C.M., Netea-Maier Romana T., van der Pal Helena J.H., Peeters Robin P., Plukker John T.M., Ronckers Cécile M., van Santen Hanneke M., van der Meer Peter, Links Thera P., Tissing Wim J.E.. 2017. Diastolic Dysfunction is Common in Survivors of Pediatric Differentiated Thyroid Carcinoma. *Thyroid* **27**:12, 1481-1489. [Abstract] [Full Text] [PDF] [PDF Plus] [Supplementary Material]

1666. Kuo Eric J., Thi William J., Zheng Feibi, Zanocco Kyle A., Livhits Masha J., Yeh Michael W.. 2017. Individualizing Surgery in Papillary Thyroid Carcinoma Based on a Detailed Sonographic Assessment of Extrathyroidal Extension. *Thyroid* **27**:12, 1544-1549. [Abstract] [Full Text] [PDF] [PDF Plus]

1667. David N. Poller. 2017. Value of cytopathologist review of ultrasound examinations in non-diagnostic/unsatisfactory thyroid FNA. *Diagnostic Cytopathology* **45**:12, 1084-1087. [Crossref]

1668. Chelsea Anderson, Stephanie M. Engel, Mark A. Weaver, Jose P. Zevallos, Hazel B. Nichols. 2017. Birth rates after radioactive iodine treatment for differentiated thyroid cancer. *International Journal of Cancer* **141**:11, 2291-2295. [Crossref]

1669. Bo-Young Kim, Ji-Eun Choi, Eunkyu Lee, Young-Ik Son, Chung-Hwan Baek, Sun Woo Kim, Man Ki Chung. 2017. Prognostic factors for recurrence of locally advanced differentiated thyroid cancer. *Journal of Surgical Oncology* **116**:7, 877-883. [Crossref]

1670. Shuai Xue, Peisong Wang, Jia Liu, Guang Chen. 2017. Radioactive Iodine Ablation Decrease Recurrences in Papillary Thyroid Microcarcinoma with Lateral Lymph Node Metastasis in Chinese Patients. *World Journal of Surgery* **41**:12, 3139-3146. [Crossref]

1671. Pierpaolo Trimboli, Gaetano Paone, Maria Chiara Zatelli, Luca Ceriani, Luca Giovanella. 2017. Real-time elastography in autonomously functioning thyroid nodules: relationship with TSH levels, scintigraphy, and ultrasound patterns. *Endocrine* **58**:3, 488-494. [Crossref]

1672. Sunghwan Suh, Yun Hak Kim, Tae Sik Goh, Jin Lee, Dae Cheon Jeong, Sae-Ock Oh, Jong Chul Hong, Seong Jang Kim, In Joo Kim, Kyoungjune Pak. 2017. Outcome prediction with the revised American joint committee on cancer staging system and American thyroid association guidelines for thyroid cancer. *Endocrine* **58**:3, 495-502. [Crossref]

1673. Soon-Hyun Ahn, So-Yeon Park, Sang Il Choi. 2017. Comparison of Consecutive Results from Fine Needle Aspiration and Core Needle Biopsy in Thyroid Nodules. *Endocrine Pathology* **28**:4, 332-338. [Crossref]

Downloaded by Memorial Sloan Kettering from www.liebertpub.com at 08/14/19. For personal use only.

1674. Prasanna Santhanam, Lilja B. Solnes, Steven B. Rowe. 2017. Molecular imaging of advanced thyroid cancer: iodinated radiotracers and beyond. *Medical Oncology* **34**:12. . [Crossref]

1675. Lester D. R. Thompson, Hannah B. Herrera, Sean K. Lau. 2017. Thyroglossal Duct Cyst Carcinomas in Pediatric Patients: Report of Two Cases with a Comprehensive Literature Review. *Head and Neck Pathology* **11**:4, 442-449. [Crossref]

1676. Sang-Woo Lee. 2017. SPECT/CT in the Treatment of Differentiated Thyroid Cancer. *Nuclear Medicine and Molecular Imaging* **51**:4, 297-303. [Crossref]

1677. Adriana Tamburello, Giorgio Treglia, Domenico Albano, Francesco Bertagna, Luca Giovanella. 2017. Prevalence and clinical significance of focal incidental 18F-FDG uptake in different organs: an evidence-based summary. *Clinical and Translational Imaging* **5**:6, 525-532. [Crossref]

1678. Leonardo Pace, Michele Klain, Luca Tagliabue, Giovanni Storto. 2017. The current and evolving role of FDG–PET/CT in personalized iodine-131 therapy of differentiated thyroid cancer. *Clinical and Translational Imaging* **5**:6, 533-544. [Crossref]

1679. Claudio M. Pacella. 2017. Image-guided thermal ablation of benign thyroid nodules. *Journal of Ultrasound* **20**:4, 347-349. [Crossref]

1680. G. Sapuppo, F. Palermo, M. Russo, M. Tavarelli, R. Masucci, S. Squatrito, R. Vigneri, G. Pellegriti. 2017. Latero-cervical lymph node metastases (N1b) represent an additional risk factor for papillary thyroid cancer outcome. *Journal of Endocrinological Investigation* **40**:12, 1355-1363. [Crossref]

1681. Kyoung Ho Oh, June Choi, Jeong-Soo Woo, Seung Kuk Baek, Kwang Yoon Jung, Min Ji Koh, Young-Sik Kim, Soon Young Kwon. 2017. Role of laminin 332 in lymph node metastasis of papillary thyroid carcinoma. *Auris Nasus Larynx* **44**:6, 729-734. [Crossref]

1682. Mansoor Alramadhan, Jun Ho Choe, Jun Ho Lee, Jung Han Kim, Jee Soo Kim. 2017. Propensity score-matched analysis of the endoscopic bilateral axillo-breast approach (BABA) versus conventional open thyroidectomy in patients with benign or intermediate fine-needle aspiration cytology results, a retrospective study. *International Journal of Surgery* **48**, 9-15. [Crossref]

1683. Tie Wang, Hoon Yub Kim, Che-Wei Wu, Stefano Rausei, Hui Sun, Francesca Pia Pergolizzi, Gianlorenzo Dionigi. 2017. Analyzing cost-effectiveness of neural-monitoring in recurrent laryngeal nerve recovery course in thyroid surgery. *International Journal of Surgery* **48**, 180-188. [Crossref]

1684. R. Vigneri, P. Malandrino, F. Gianì, M. Russo, P. Vigneri. 2017. Heavy metals in the volcanic environment and thyroid cancer. *Molecular and Cellular Endocrinology* **457**, 73-80. [Crossref]

1685. Danila Cuomo, Immacolata Porreca, Gilda Cobellis, Roberta Tarallo, Giovanni Nassa, Geppino Falco, Antonio Nardone, Francesca Rizzo, Massimo Mallardo, Concetta Ambrosino. 2017. Carcinogenic risk and Bisphenol A exposure: A focus on molecular aspects in endoderm derived glands. *Molecular and Cellular Endocrinology* **457**, 20-34. [Crossref]

1686. Eleftherios Spartalis, Demetrios Moris, Periklis Tomos. 2017. Sternal metastasis as first presentation of a well-differentiated papillary thyroid carcinoma. *Surgery* **162**:6, 1336-1337. [Crossref]

1687. Han Luo, Hongliu Yang, Wanjun Zhao, Qianqian Han, Li Zeng, Huairong Tang, Jingqiang Zhu. 2017. Elevated free triiodothyronine may lead to female sexual dysfunction in Chinese urban women: A hospital-based survey. *Scientific Reports* **7**:1. . [Crossref]

1688. Chunping Liu, Shuntao Wang, Wen Zeng, Yawen Guo, Zeming Liu, Tao Huang. 2017. Total tumour diameter is superior to unifocal diameter as a predictor of papillary thyroid microcarcinoma prognosis. *Scientific Reports* **7**:1. . [Crossref]

1689. Zhong-Ling Qiu, Wei-Jun Wei, Chen-Tian Shen, Hong-Jun Song, Xin-Yun Zhang, Zhen-Kui Sun, Quan-Yong Luo. 2017. Diagnostic Performance of 18F-FDG PET/CT in Papillary Thyroid Carcinoma with Negative 131I-WBS at first Postablation, Negative Tg and Progressively Increased TgAb Level. *Scientific Reports* **7**:1. . [Crossref]

1690. Andrey Bychkov, Usanee Vutrapongwatana, Supatporn Tepmongkol, Somboon Keelawat. 2017. PSMA expression by microvasculature of thyroid tumors – Potential implications for PSMA theranostics. *Scientific Reports* **7**:1. . [Crossref]

1691. A. Campennì, M. Siracusa, R. M. Ruggeri, R. Laudicella, S. A. Pignata, S. Baldari, L. Giovanella. 2017. Differentiating malignant from benign thyroid nodules with indeterminate cytology by 99mTc-MIBI scan: a new quantitative method for improving diagnostic accuracy. *Scientific Reports* **7**:1. . [Crossref]

1692. Yan Zhang, Yu-kun Luo, Ming-bo Zhang, Jie Li, Chang-tian Li, Jie Tang, Jun-lai Li. 2017. Values of ultrasound features and MMP-9 of papillary thyroid carcinoma in predicting cervical lymph node metastases. *Scientific Reports* **7**:1. . [Crossref]

1693. Ya-Ping He, Hui-Xiong Xu, Chong-Ke Zhao, Li-Ping Sun, Xiao-Long Li, Wen-Wen Yue, Le-Hang Guo, Dan Wang, Wei-Wei Ren, Qiao Wang, Shen Qu. 2017. Cytologically indeterminate thyroid nodules: increased diagnostic performance with combination of US TI-RADS and a new scoring system. *Scientific Reports* **7**:1. . [Crossref]

Downloaded by Memorial Sloan Kettering from www.liebertpub.com at 08/14/19. For personal use only.

1694. Chong Hyun Suh, Jung Hwan Baek, Young Jun Choi, Tae Yong Kim, Tae Yon Sung, Dong Eun Song, Jeong Hyun Lee. 2017. Efficacy and safety of core-needle biopsy in initially detected thyroid nodules via propensity score analysis. *Scientific Reports* **7**:1. . [Crossref]

1695. Thomas A. Werner, Levent Dizdar, Inga Nolten, Jasmin C. Riemer, Sabrina Mersch, Sina C. Schütte, Christiane Driemel, Pablo E. Verde, Katharina Raba, Stefan A. Topp, Matthias Schott, Wolfram T. Knoefel, Andreas Krieg. 2017. Survivin and XIAP – two potential biological targets in follicular thyroid carcinoma. *Scientific Reports* **7**:1. . [Crossref]

1696. Ying Wang, Kai-Rong Lei, Ya-Ping He, Xiao-Long Li, Wei-Wei Ren, Chong-Ke Zhao, Xiao-Wan Bo, Dan Wang, Cheng-Yu Sun, Hui-Xiong Xu. 2017. Malignancy risk stratification of thyroid nodules: comparisons of four ultrasound Thyroid Imaging Reporting and Data Systems in surgically resected nodules. *Scientific Reports* **7**:1. . [Crossref]

1697. Jieli Luo, Chao Zhang, Fengbo Huang, Jianshe Chen, Yang Sun, Kailun Xu, Pintong Huang. 2017. Risk of malignancy in thyroid nodules: predictive value of puncture feeling of grittiness in the process of fine-needle aspiration. *Scientific Reports* **7**:1. . [Crossref]

1698. Julietta V. Rau, Marco Fosca, Valerio Graziani, Chiara Taffon, Massimiliano Rocchia, Marco Caricato, Paolo Pozzilli, Andrea Onetti Muda, Anna Crescenzi. 2017. Proof-of-concept Raman spectroscopy study aimed to differentiate thyroid follicular patterned lesions. *Scientific Reports* **7**:1. . [Crossref]

1699. Moran Amit, Shorook Na'ara, Demilza Francis, Wisam Matanis, Sagit Zolotov, Birgit Eisenhaber, Frank Eisenhaber, Michal Weiler Sagie, Leonid Malkin, Salem Billan, Tomer Charas, Ziv Gil. 2017. Post-translational Regulation of Radioactive Iodine Therapy Response in Papillary Thyroid Carcinoma. *JNCI: Journal of the National Cancer Institute* **109**:12. . [Crossref]

1700. Hideto Takahashi, Kunihiko Takahashi, Hiroki Shimura, Seiji Yasumura, Satoru Suzuki, Akira Ohtsuru, Sanae Midorikawa, Tetsuya Ohira, Hitoshi Ohto, Shunichi Yamashita, Kenji Kamiya. 2017. Simulation of expected childhood and adolescent thyroid cancer cases in Japan using a cancer-progression model based on the National Cancer Registry. *Medicine* **96**:48, e8631. [Crossref]

1701. Natascha Roehlen, Szilvia Takacs, Olaf Ebeling, Jochen Seufert, Katharina Laubner. 2017. Ectopic papillary thyroid carcinoma within a thyroglossal duct cyst. *Medicine* **96**:48, e8921. [Crossref]

1702. Bai Lin, Wen Qiang, Zhang Wenqi, Yu Tianyu, Zhao Lina, Ji Bin. 2017. Clinical response to radioactive iodine therapy for prophylactic central neck dissection is not superior to total thyroidectomy alone in cN0 patients with papillary thyroid cancer. *Nuclear Medicine Communications* **38**:12, 1036-1040. [Crossref]

1703. Miribi Rho, Eun-Kyung Kim, Hee Jung Moon, Jung Hyun Yoon, Vivian Y. Park, Kyunghwa Han, Jin Young Kwak. 2017. Clinical Parameter for Deciding the BRAFV600E Mutation Test in Atypia of Undetermined Significance/Follicular Lesion of Undetermined Significance Thyroid Nodules. *Ultrasound Quarterly* **33**:4, 284-288. [Crossref]

1704. Aldona Kowalska, Agnieszka Walczyk, Artur Kowalik, Iwona Pałyga, Danuta Gąsior-Perczak, Tomasz Trybek, Janusz Kopczyński, Maciej Kajor, Estera Mikina, Monika Szymonek, Klaudia Gadawska-Juszczyk, Dorota Szyska-Skrobot, Katarzyna Lizis-Kolus, Stefan Hurej, Magdalena Chrapek, Małgorzata Chłopek, Stanisław Góźdź. 2017. Response to therapy of papillary thyroid cancer of known BRAF status. *Clinical Endocrinology* **87**:6, 815-824. [Crossref]

1705. J. D. Sinnott, R. Mortimer, J. Smith, E. Skelton, K. Drinkwater, D. Lipscomb, D. C. Howlett. 2017. The effect of routine radiological reporting of thyroid incidentalomas on rates of thyroid needle biopsy, thyroid surgery and detection of thyroid malignancy. *Clinical Endocrinology* **87**:6, 825-831. [Crossref]

1706. K.-I. Yi, S. Ahn, D.Y. Park, J.-C. Lee, B.-J. Lee, S.-G. Wang, W. Cha. 2017. False-positive cytopathology results for papillary thyroid carcinoma: A trap for thyroid surgeons. *Clinical Otolaryngology* **42**:6, 1153-1160. [Crossref]

1707. M. Jaconi, M. Manzoni, A. I. Pincelli, V. Giardini, M. Scardilli, A. Smith, G. Fellegara, F. Pagni. 2017. The impact of the non-invasive follicular thyroid neoplasm with papillary-like nuclear feature terminology in the routine diagnosis of thyroid tumours. *Cytopathology* **28**:6, 495-502. [Crossref]

1708. K. Kakudo, M. Higuchi, M. Hirokawa, S. Satoh, C. K. Jung, A. Bychkov. 2017. Thyroid FNA cytology in Asian practice-Active surveillance for indeterminate thyroid nodules reduces overtreatment of thyroid carcinomas. *Cytopathology* **28**:6, 455-466. [Crossref]

1709. M. Decaussin-Petrucci, F. Descotes, L. Depaepe, V. Lapras, M.-L. Denier, F. Borson-Chazot, J.-C. Lifante, J. Lopez. 2017. Molecular testing of BRAF, RAS and TERT on thyroid FNAs with indeterminate cytology improves diagnostic accuracy. *Cytopathology* **28**:6, 482-487. [Crossref]

1710. C. Saglietti, A. M. Onenerk, W. C. Faquin, G. P. Sykiotis, S. Ziadi, M. Bongiovanni. 2017. FNA diagnosis of poorly differentiated thyroid carcinoma. A review of the recent literature. *Cytopathology* **28**:6, 467-474. [Crossref]

1711. Ruigang Lu, Yuxin Meng, Yan Zhang, Wei Zhao, Xun Wang, Mulan Jin, Ruijun Guo. 2017. Superb microvascular imaging (SMI) compared with conventional ultrasound for evaluating thyroid nodules. *BMC Medical Imaging* **17**:1. . [Crossref]

1712. Nori L. Bradley, Sam M. Wiseman. 2017. Papillary thyroid microcarcinoma: the significance of high risk features. *BMC Cancer* **17**:1. . [Crossref]

Downloaded by Memorial Sloan Kettering from www.liebertpub.com at 08/14/19. For personal use only.

1713. Huan Zhao, Yong Wang, Min-jie Wang, Zhi-hui Zhang, Hai-rui Wang, Bing Zhang, Hui-qin Guo. 2017. Influence of presence/absence of thyroid gland on the cutoff value for thyroglobulin in lymph-node aspiration to detect metastatic papillary thyroid carcinoma. *BMC Cancer* **17**:1. . [Crossref]

1714. Yuchen Jin, Min Liu, Lingxiao Cheng, Libo Chen. 2017. Successful pregnancy without disease progression of radioiodine refractory papillary thyroid carcinoma: a case report. *BMC Cancer* **17**:1. . [Crossref]

1715. Donnie Funch, Douglas Ross, Betsey M. Gardstein, Heather S. Norman, Lauren A. Sanders, Atheline Major-Pedersen, Helge Gydesen, David D. Dore. 2017. Performance of claims-based algorithms for identifying incident thyroid cancer in commercial health plan enrollees receiving antidiabetic drug therapies. *BMC Health Services Research* **17**:1. . [Crossref]

1716. Shuai Xue, Peisong Wang, Jia Liu, Guang Chen. 2017. Total thyroidectomy may be more reasonable as initial surgery in unilateral multifocal papillary thyroid microcarcinoma: a single-center experience. *World Journal of Surgical Oncology* **15**:1. . [Crossref]

1717. Jian-Jun Li, Ping Chen Jue-Ru Zheng, Yao-Zong Wang. 2017. The correlations between DNA methylation and polymorphisms in the promoter region of the human telomerase reverse transcriptase (hTERT) gene with postoperative recurrence in patients with thyroid carcinoma (TC). *World Journal of Surgical Oncology* **15**:1. . [Crossref]

1718. Wenzheng Chen, Qingfeng Liu, Yunxia Lv, Debin Xu, Wanzhi Chen, Jichun Yu. 2017. Special role of JUN in papillary thyroid carcinoma based on bioinformatics analysis. *World Journal of Surgical Oncology* **15**:1. . [Crossref]

1719. Xingjie Yin, Chunping Liu, Yawen Guo, Xiaoyu Li, Na Shen, Xiangwang Zhao, Pan Yu, Shan Wang, Zeming Liu. 2017. Influence of tumor extent on central lymph node metastasis in solitary papillary thyroid microcarcinomas: a retrospective study of 1092 patients. *World Journal of Surgical Oncology* **15**:1. . [Crossref]

1720. S. Muller, M. Senne, A. Kirschniak, A. Königsrainer, R. Bares, C. Falch. 2017. Impact of surgical resection extension on outcome for primary well-differentiated thyroid cancer—a retrospective analysis. *World Journal of Surgical Oncology* **15**:1. . [Crossref]

1721. Se Hyun Paek, Byung Seup Kim, Kyung Ho Kang, Hee Sung Kim. 2017. False-negative BRAF V600E mutation results on fine-needle aspiration cytology of papillary thyroid carcinoma. *World Journal of Surgical Oncology* **15**:1. . [Crossref]

1722. Shih-Wei Chen, Yen-Kung Chen. 2017. High CEA levels in a case of resected colorectal cancer: delayed diagnosis of metachronous medullary thyroid cancer. *World Journal of Surgical Oncology* **15**:1. . [Crossref]

1723. Brian Hung-Hin Lang, Arnold L. H. Wu. 2017. High intensity focused ultrasound (HIFU) ablation of benign thyroid nodules – a systematic review. *Journal of Therapeutic Ultrasound* **5**:1. . [Crossref]

1724. Jason J. Xu, Eugene Yu, Caitlin McMullen, Jesse Pasternak, Jim Brierley, Richard Tsang, Han Zhang, Antoine Eskander, Lorne Rotstein, Anna M. Sawka, Ralph Gilbert, Jonathan Irish, Patrick Gullane, Dale Brown, John R. de Almeida, David P. Goldstein. 2017. Patterns of regional recurrence in papillary thyroid cancer patients with lateral neck metastases undergoing neck dissection. *Journal of Otolaryngology - Head & Neck Surgery* **46**:1. . [Crossref]

1725. Lewis D. Hahn, Christian A. Kunder, Michelle M. Chen, Lisa A. Orloff, Terry S. Desser. 2017. Indolent thyroid cancer: knowns and unknowns. *Cancers of the Head & Neck* **2**:1. . [Crossref]

1726. Shunji Takahashi, Naomi Kiyota, Makoto Tahara. 2017. Optimal use of lenvatinib in the treatment of advanced thyroid cancer. *Cancers of the Head & Neck* **2**:1. . [Crossref]

1727. M. Sollini, L. Cozzi, G. Pepe, L. Antunovic, A. Lania, L. Di Tommaso, P. Magnoni, P. A. Erba, M. Kirienko. 2017. [18F]FDG-PET/CT texture analysis in thyroid incidentalomas: preliminary results. *European Journal of Hybrid Imaging* **1**:1. . [Crossref]

1728. Trevor E Angell, Chirag M Vyas, Marco Medici, Zhihong Wang, Justine A Barletta, Carol B Benson, Edmund S Cibas, Nancy L Cho, Gerard M Doherty, Peter M Doubilet, Mary C Frates, Atul A Gawande, Howard T Heller, Matthew I Kim, Jeffrey F Krane, Ellen Marqusee, Francis D Moore, Matt A Nehs, Ann Marie Zavacki, P Reed Larsen, Erik K Alexander. 2017. Differential Growth Rates of Benign vs. Malignant Thyroid Nodules. *The Journal of Clinical Endocrinology & Metabolism* **102**:12, 4642-4647. [Crossref]

1729. Young Shin Song, Jung Ah Lim, Hye Sook Min, Min Joo Kim, Hoon Sung Choi, Sun Wook Cho, Jae Hoon Moon, Ka Hee Yi, Do Joon Park, Bo Youn Cho, Young Joo Park. 2017. Changes in the clinicopathological characteristics and genetic alterations of follicular thyroid cancer. *European Journal of Endocrinology* **177**:6, 465-473. [Crossref]

1730. Mayara Peres Barbosa, Denise Momesso, Daniel Alves Bulzico, Terence Farias, Fernando Dias, Roberto Araújo Lima, Rossana Corbo, Mario Vaisman, Fernanda Vaisman. 2017. Metastatic lymph node characteristics as predictors of recurrence/persistence in the neck and distant metastases in differentiated thyroid cancer. *Archives of Endocrinology and Metabolism* **61**:6, 584-589. [Crossref]

1731. Leonardo Bandeira, Rosália do Prado Padovani, Ana Luiza Ticly, Adriano Namo Cury, Nilza Maria Scalissi, Marília Martins Silveira Marone, Carolina Ferraz. 2017. Thyroglobulin levels before radioactive iodine therapy and dynamic risk stratification after 1 year in patients with differentiated thyroid cancer. *Archives of Endocrinology and Metabolism* **61**:6, 590-599. [Crossref]

Downloaded by Memorial Sloan Kettering from www.liebertpub.com at 08/14/19. For personal use only.

1732. Maja Davidson, Randall J. Olsen, April A. Ewton, Richard J. Robbins. 2017. PANCREAS METASTASES FROM PAPILLARY THYROID CARCINOMA: A REVIEW OF THE LITERATURE. *Endocrine Practice* **23**:12, 1425-1429. [Crossref]

1733. Erdal Uysal, Seyit Mehmet Ceylan, Efe Sezgin, Hasan Bakir, Ahmet Orhan Gurer, Basar Aksoy, Mehmet Bastemir. 2017. Evaluation of Hemocytometer Parameters as Potential Biomarkers in Benign Multinodular Goiter and Papillary Thyroid Carcinoma. *Iranian Red Crescent Medical Journal* **19**:12. . [Crossref]

1734. Dorothée Bouron-Dal Soglio, Leanne de Kock, Richard Gauci, Nelly Sabbaghian, Elizabeth Thomas, Helen C. Atkinson, Nicholas Pachter, Simon Ryan, John P. Walsh, M. Priyanthi Kumarasinghe, Karen Carpenter, Ayça Aydoğan, Colin J.R. Stewart, William D. Foulkes, Catherine S. Choong. 2017. A Case Report of Syndromic Multinodular Goitre in Adolescence: Exploring the Phenotype Overlap between Cowden and DICER1 Syndromes. *European Thyroid Journal* . [Crossref]

1735. Aly Bernard Khalil, Roberto Dina, Karim Meeran, Ali M. Bakir, Saf Naqvi, Alia Al Tikritti, Nader Lessan, Maha T. Barakat. 2017. Indeterminate Thyroid Nodules: A Pragmatic Approach. *European Thyroid Journal* . [Crossref]

1736. Dario Tumino, Francesco Frasca, Kate Newbold. 2017. Updates on the Management of Advanced, Metastatic, and Radioiodine Refractory Differentiated Thyroid Cancer. *Frontiers in Endocrinology* **8**. . [Crossref]

1737. Jia-Jing Xia, Meng-Sen Li, Li Zheng, You-Zhen Shi. 2017. Nondiagnostic cytological results on ultrasound-guided fine needle aspiration: Does the thyroid nodule depth matter?. *Clinical Hemorheology and Microcirculation* **67**:2, 115-124. [Crossref]

1738. Agustina D. Abelardo. 2017. Thyroid Fine-Needle Aspiration Practice in the Philippines. *Journal of Pathology and Translational Medicine* **51**:6, 555-559. [Crossref]

1739. Shipra Agarwal, Deepali Jain. 2017. Thyroid Cytology in India: Contemporary Review and Meta-analysis. *Journal of Pathology and Translational Medicine* **51**:6, 533-547. [Crossref]

1740. Zhiyan Liu, Dongge Liu, Bowen Ma, Xiaofang Zhang, Peng Su, Li Chen, Qingdong Zeng. 2017. History and Practice of Thyroid Fine-Needle Aspiration in China, Based on Retrospective Study of the Practice in Shandong University Qilu Hospital. *Journal of Pathology and Translational Medicine* **51**:6, 528-532. [Crossref]

1741. Andrey Bychkov, Kennichi Kakudo, SoonWon Hong. 2017. Current Practices of Thyroid Fine-Needle Aspiration in Asia: A Missing Voice. *Journal of Pathology and Translational Medicine* **51**:6, 517-520. [Crossref]

1742. Shinya Satoh, Hiroyuki Yamashita, Kennichi Kakudo. 2017. Thyroid Cytology: The Japanese System and Experience at Yamashita Thyroid Hospital. *Journal of Pathology and Translational Medicine* **51**:6, 548-554. [Crossref]

1743. Chan Kwon Jung, SoonWon Hong, Andrey Bychkov, Kennichi Kakudo. 2017. The Use of Fine-Needle Aspiration (FNA) Cytology in Patients with Thyroid Nodules in Asia: A Brief Overview of Studies from the Working Group of Asian Thyroid FNA Cytology. *Journal of Pathology and Translational Medicine* **51**:6, 571-578. [Crossref]

1744. Roberta Malaguarnera, Veronica Vella, Maria Luisa Nicolosi, Antonino Belfiore. 2017. Insulin Resistance: Any Role in the Changing Epidemiology of Thyroid Cancer?. *Frontiers in Endocrinology* **8**. . [Crossref]

1745. Caiyun He, Jiangjun Ma, Yongle Jiang, Xuan Su, Xiao Zhang, Weichao Chen, Zulu Ye, Tiancheng Deng, Wenze Deng, Ankui Yang. 2017. Associations between RET tagSNPs and their haplotypes and susceptibility, clinical severity, and thyroid function in patients with differentiated thyroid cancer. *PLOS ONE* **12**:11, e0187968. [Crossref]

1746. Mallika Bhat, Matty Mozzor, Savneek Chugh, Vamsi Buddharaju, Monica Schwarcz, Guy Valiquette. 2017. Dosing of radioactive iodine in end-stage renal disease patient with thyroid cancer. *Echo Research and Practice* . [Crossref]

1747. Fish Stephanie A.. 2017. Validation of American Thyroid Association Ultrasound Risk Assessment of Thyroid Nodules Selected for Ultrasound Fine-Needle Aspiration. *Clinical Thyroidology* **29**:11, 411-414. [Citation] [Full Text] [PDF] [PDF Plus]

1748. Biermann Martin. 2017. Punctate Echogenic Foci on Thyroid Ultrasound Do Not Necessarily Represent Calcifications on Histopathology. *Clinical Thyroidology* **29**:11, 415-418. [Citation] [Full Text] [PDF] [PDF Plus]

1749. Hershman Jerome M.. 2017. Multifocality Is Not an Independent Risk Factor for Recurrence of Papillary Thyroid Cancer. *Clinical Thyroidology* **29**:11, 437-439. [Citation] [Full Text] [PDF] [PDF Plus]

1750. Kim Eun Young, Lee Kwan Ho, Park Yong Lai, Park Chan Heun, Lee Cho Rok, Jeong Jong Ju, Nam Kee-Hyun, Chung Woong Youn, Yun Ji-Sup. 2017. Single-Incision, Gasless, Endoscopic Trans-Axillary Total Thyroidectomy: A Feasible and Oncologic Safe Surgery in Patients with Papillary Thyroid Carcinoma. *Journal of Laparoendoscopic & Advanced Surgical Techniques* **27**:11, 1158-1164. [Abstract] [Full Text] [PDF] [PDF Plus]

1751. Eszlinger Markus, Ullmann Maha, Ruschenburg Ilka, Böhme Katharina, Görke Fabian, Franzius Christiane, Adam Sabine, Molwitz Thomas, Landvogt Christian, Amro Bassam, Hach Anja, Feldmann Berit, Graf Dieter, Wefer Antje, Niemann Rainer, Bullmann Catharina, Klaushenke Günther, Santen Reinhard, Tönshoff Gregor, Ivancevic Velimir, Kögler Andreas, Bell Eberhard, Lorenz Bernd, Kluge Gerald, Hartenstein Christoph, Paschke Ralf. 2017. Low Malignancy Rates in Fine-Needle Aspiration Cytologies in a Primary Care Setting in Germany. *Thyroid* **27**:11, 1385-1392. [Abstract] [Full Text] [PDF] [PDF Plus]

Downloaded by Memorial Sloan Kettering from www.liebertpub.com at 08/14/19. For personal use only.

1752. Sung Tae-Yon, Cho Jae Won, Lee Yu-mi, Lee Yi Ho, Kwon Hyemi, Jeon Min Ji, Kim Won Gu, Choi Young Jun, Song Dong Eun, Chung Ki-Wook, Yoon Jong Ho, Hong Suck Joon. 2017. Dynamic Risk Stratification in Stage I Papillary Thyroid Cancer Patients Younger Than 45 Years of Age. *Thyroid* **27**:11, 1400-1407. [Abstract] [Full Text] [PDF] [PDF Plus]

1753. Grani Giorgio, Bruno Rocco, Lucisano Giuseppe, Costante Giuseppe, Meringolo Domenico, Puxeddu Efisio, Torlontano Massimo, Tumino Salvatore, Attard Marco, Lamartina Livia, Nicolucci Antonio, Cooper David S., Filetti Sebastiano, Durante Cosimo. 2017. Temporal Changes in Thyroid Nodule Volume: Lack of Effect on Paranodular Thyroid Tissue Volume. *Thyroid* **27**:11, 1378-1384. [Abstract] [Full Text] [PDF] [PDF Plus] [Supplementary Material]

1754. Bardet Stéphane, Ciappuccini Renaud, Pellot-Barakat Claire, Monpeyssen Hervé, Michels Jean-Jacques, Tissier Frédérique, Blanchard David, Menegaux Fabrice, de Raucourt Dominique, Lefort Muriel, Reznik Yves, Rouxel Agnès, Heutte Natacha, Brenac Frédérique, Leconte Alexandra, Buffet Camille, Clarisse Bénédicte, Leenhardt Laurence. 2017. Shear Wave Elastography in Thyroid Nodules with Indeterminate Cytology: Results of a Prospective Bicentric Study. *Thyroid* **27**:11, 1441-1449. [Abstract] [Full Text] [PDF] [PDF Plus]

1755. Pontius Lauren N., Oyekunle Taofik O., Thomas Samantha M., Stang Michael T., Scheri Randall P., Roman Sanziana A., Sosa Julie A.. 2017. Projecting Survival in Papillary Thyroid Cancer: A Comparison of the Seventh and Eighth Editions of the American Joint Commission on Cancer/Union for International Cancer Control Staging Systems in Two Contemporary National Patient Cohorts. *Thyroid* **27**:11, 1408-1416. [Abstract] [Full Text] [PDF] [PDF Plus] [Supplementary Material]

1756. Hedman Christel, Strang Peter, Djärv Therese, Widberg Ida, Lundgren Catharina Ihre. 2017. Anxiety and Fear of Recurrence Despite a Good Prognosis: An Interview Study with Differentiated Thyroid Cancer Patients. *Thyroid* **27**:11, 1417-1423. [Abstract] [Full Text] [PDF] [PDF Plus]

1757. Cibas Edmund S., Ali Syed Z.. 2017. The 2017 Bethesda System for Reporting Thyroid Cytopathology. *Thyroid* **27**:11, 1341-1346. [Abstract] [Full Text] [PDF] [PDF Plus]

1758. Andrew A. Renshaw, Ewing W. Gould. 2017. Adequate sampling of multiple thyroid nodules by fine-needle aspiration. *Cancer Cytopathology* **125**:11, 848-853. [Crossref]

1759. Jeffrey K. Mito, Erik K. Alexander, Trevor E. Angell, Justine A. Barletta, Matthew A. Nehs, Edmund S. Cibas, Jeffrey F. Krane. 2017. A modified reporting approach for thyroid FNA in the NIFTP era: A 1-year institutional experience. *Cancer Cytopathology* **125**:11, 854-864. [Crossref]

1760. Mousa A. Al-Abbadi, Sameera Q. Shareef, Mohammad M. Yousef, Nidal M. Almasri, Huda E. Mustafa, Hameed Aljawad, Jassim A. Ali, Alan Groves, Yasmen Alsaihati. 2017. A follow-up study on thyroid aspirates reported as atypia of undetermined significance/follicular lesion of undetermined significance and follicular neoplasm/suspicious for follicular neoplasm: A multicenter study from the Arabian Gulf region. *Diagnostic Cytopathology* **45**:11, 983-988. [Crossref]

1761. Ji Hye Lee, Kyunghwa Han, Eun-Kyung Kim, Hee Jung Moon, Jung Hyun Yoon, Vivian Y. Park, Jin Young Kwak. 2017. Validation of the modified 4-tiered categorization system through comparison with the 5-tiered categorization system of the 2015 American Thyroid Association guidelines for classifying small thyroid nodules on ultrasound. *Head & Neck* **39**:11, 2208-2215. [Crossref]

1762. José M. Domínguez, Flavia Nilo, Tania Contreras, Rocío Carmona, Nicolás Droppelmann, Hernán González, Virginia Iturrieta, R. Michael Tuttle. 2017. Neck Sonography and Suppressed Thyroglobulin Have High Sensitivity for Identifying Recurrent/Persistent Disease in Patients With Low-risk Thyroid Cancer Treated With Total Thyroidectomy and Radioactive Iodine Ablation, Making Stimulated Thyroglobulin Unne. *Journal of Ultrasound in Medicine* **36**:11, 2299-2307. [Crossref]

1763. Suvi Renkonen, Riikka Lindén, Leif Bäck, Robert Silén, Hanna Mäenpää, Laura Tapiovaara, Katri Aro. 2017. Accuracy of preoperative MRI to assess lateral neck metastases in papillary thyroid carcinoma. *European Archives of Oto-Rhino-Laryngology* **274**:11, 3977-3983. [Crossref]

1764. Sohail Bakkar, Anello Marcello Poma, Caterina Corsini, Mario Miccoli, Carlo Enrico Ambrosini, Paolo Miccoli. 2017. Underestimated risk of cancer in solitary thyroid nodules ≥3 cm reported as benign. *Langenbeck's Archives of Surgery* **402**:7, 1089-1094. [Crossref]

1765. M. Russo, P. Malandrino, M. Moleti, F. Vermiglio, M. A. Violi, I. Marturano, E. Minaldi, R. Vigneri, G. Pellegriti, C. Regalbuto. 2017. Tall cell and diffuse sclerosing variants of papillary thyroid cancer: outcome and predicting value of risk stratification methods. *Journal of Endocrinological Investigation* **40**:11, 1235-1241. [Crossref]

1766. Wan-jun Zhao, Han Luo, Yi-mei Zhou, Wen-yu Dai, Jing-qiang Zhu. 2017. Evaluating the effectiveness of prophylactic central neck dissection with total thyroidectomy for cN0 papillary thyroid carcinoma: An updated meta-analysis. *European Journal of Surgical Oncology* **43**:11, 1989-2000. [Crossref]

Downloaded by Memorial Sloan Kettering from www.liebertpub.com at 08/14/19. For personal use only.

1767. A.R. Shaha, C.E. Silver, P. Angelos, I.J. Nixon, J.P. Rodrigo, A. Sanabria, V. Vander Poorten, M.D. Williams, A. Rinaldo, A. Ferlito. 2017. The central compartment – Center of controversy, confusion, and concern in management of differentiated thyroid cancer. *European Journal of Surgical Oncology* **43**:11, 1981-1984. [Crossref]

1768. Josefina C. Farrá, Omar Picado, Sophia Liu, Wenqi Ouyang, Richard Teo, Alexa M. Franco, John I. Lew. 2017. Clinically significant cancer rates in incidentally discovered thyroid nodules by routine imaging. *Journal of Surgical Research* **219**, 341-346. [Crossref]

1769. Jillian L. Simard, Sheetal M. Kircher, Aarati Didwania, Mita Sanghavi Goel. 2017. Screening for Recurrence and Secondary Cancers. *Medical Clinics of North America* **101**:6, 1167-1180. [Crossref]

1770. S. Zerdoud, S. Leboulleux, J. Clerc, L. Leenhardt, C. Bournaud, A. Al Ghuzlan, I. Keller, S. Bardet, A.-L. Giraudet, L. Groussin, F. Sebag, R. Garrel, P.-J. Lamy, M.-E. Toubert, É. Mirallié, E. Hindié, D. Taïeb. 2017. Traitement par iode 131 des cancers thyroïdiens différenciés : recommandations 2017 des sociétés françaises SFMN/SFE/SFP/SFBC/AFCE/SFORL. *Médecine Nucléaire* **41**, S1-S22. [Crossref]

1771. A.-L. Giraudet, S. Bardet, M.-E. Toubert, P.-J. Lamy, S. Zerdoud, S. Leboulleux, J. Clerc, L. Leenhardt, C. Bournaud, A. Al Ghuzlan, I. Keller, L. Groussin, F. Sebag, R. Garrel, E. Mirallié, D. Taïeb, E. Hindié. 2017. Imagerie moléculaire et biomarqueurs des cancers thyroïdiens de souche vésiculaire : recommandations 2017 de SFMN/SFE/SFP/SFBC/AFCE/SFORL. *Médecine Nucléaire* **41**, S23-S33. [Crossref]

1772. Y. Benameur, O.A. Sahel, S.N. Oueriagli, H. Bouyaallaoui, A. Biyi, A. Doudouh. 2017. Les carcinomes papillaires de la thyroïde révélés par examen TEP/TDM au 18 F-FDG : à propos de deux cas et revue de la littérature. *Médecine Nucléaire* **41**:6, 442-446. [Crossref]

1773. Q. Bigueur, M.H. Bouin Pineau, M. Hadzic, J.L. Kraimps, R. Perdrisot, C. Cheze Le Rest. 2017. Intérêt de la TEP/TDM au 18 FDG dans les sous-types histologiques agressifs de cancers thyroïdiens (oncocytaire et peu différencié). *Médecine Nucléaire* **41**:6, 386-396. [Crossref]

1774. Axel Sahovaler, David H. Yeh, Deric Morrison, Sandrine de Ribaupierre, Jonathan Izawa, Adam Power, Richard Inculet, Neil Parry, David A. Palma, Mark Landis, Andrew Leung, Kevin Fung, S. Danielle MacNeil, John Yoo, Anthony C. Nichols. 2017. The incidence and management of non-head and neck incidentalomas for the head and neck surgeon. *Oral Oncology* **74**, 98-104. [Crossref]

1775. Qian Li, Xueying Lin, Yuhong Shao, Feixiang Xiang, Anthony E. Samir. 2017. Imaging and Screening of Thyroid Cancer. *Radiologic Clinics of North America* **55**:6, 1261-1271. [Crossref]

1776. Qin Xie, Hui Chen, Jing Ai, Ying-lei Gao, Mei-yu Geng, Jian Ding, Yi Chen. 2017. Evaluation of in vitro and in vivo activity of a multityrosine kinase inhibitor, AL3810, against human thyroid cancer. *Acta Pharmacologica Sinica* **38**:11, 1533-1542. [Crossref]

1777. Gunjan Garg, Mohammed Taoudi Benchekroun, Tony Abraham. 2017. FDG-PET/CT in the Postoperative Period: Utility, Expected Findings, Complications, and Pitfalls. *Seminars in Nuclear Medicine* **47**:6, 579-594. [Crossref]

1778. Atena Aghaei, Narjess Ayati, Susan Shafiei, Bita Abbasi, S. Rasoul Zakavi. 2017. Comparison of treatment efficacy 1 and 2 years after thyroid remnant ablation with 1110 versus 5550 MBq of iodine-131 in patients with intermediate-risk differentiated thyroid cancer. *Nuclear Medicine Communications* **38**:11, 927-931. [Crossref]

1779. Xinyu Wu, Hao Gu, Yongju Gao, Bo Li, Ruitai Fan. 2017. Clinical outcomes and prognostic factors of radioiodine ablation therapy for lymph node metastases from papillary thyroid carcinoma. *Nuclear Medicine Communications* 1. [Crossref]

1780. Minjung Seo, Yon Seon Kim, Jong Cheol Lee, Myung Woul Han, Eun Sook Kim, Kyung Bin Kim, Seol Hoon Park. 2017. Low-Dose Radioactive Iodine Ablation Is Sufficient in Patients With Small Papillary Thyroid Cancer Having Minor Extrathyroidal Extension and Central Lymph Node Metastasis (T3 N1a). *Clinical Nuclear Medicine* **42**:11, 842-846. [Crossref]

1781. Terri Benskin, Iris Zachary, Magda Esebua, Uzma Khan. Collaborations across disciplines: MU thyroid nodule electronic database (MU-TNED), a multidisciplinary informatics approach 658-662. [Crossref]

1782. C. M. Kitahara, E. L. Yanik, P. W. Ladenson, B. Y. Hernandez, C. F. Lynch, K. S. Pawlish, E. A. Engels. 2017. Risk of Thyroid Cancer Among Solid Organ Transplant Recipients. *American Journal of Transplantation* **17**:11, 2911-2921. [Crossref]

1783. Pedro Weslley Rosario. 2017. Ultrasonography and cytology as predictors of noninvasive follicular thyroid (NIFTP) neoplasm with papillary-like nuclear features: importance of the differential diagnosis with the invasive encapsulated follicular variant of papillary thyroid cancer. *Clinical Endocrinology* **87**:5, 635-636. [Crossref]

1784. Huy Gia Vuong, Ahmed M.A. Altibi, Uyen N.P. Duong, Lewis Hassell. 2017. Prognostic implication of BRAF and TERT promoter mutation combination in papillary thyroid carcinoma-A meta-analysis. *Clinical Endocrinology* **87**:5, 411-417. [Crossref]

1785. Jung Hee Shin. 2017. The author's reply "Ultrasonography and cytology as predictors of noninvasive follicular thyroid (NIFTP) neoplasm with papillary-like nuclear features: importance of the differential diagnosis with the invasive encapsulated follicular variant of papillary. *Clinical Endocrinology* **87**:5, 637-637. [Crossref]

Downloaded by Memorial Sloan Kettering from www.liebertpub.com at 08/14/19. For personal use only.

1786. Yehree Kim, Jong-Lyel Roh, Gyungyup Gong, Kyung-Ja Cho, Seung-Ho Choi, Soon Yuhl Nam, Sang Yoon Kim. 2017. Risk Factors for Lateral Neck Recurrence of N0/N1a Papillary Thyroid Cancer. *Annals of Surgical Oncology* **24**:12, 3609-3616. [Crossref]

1787. Jolanta Krajewska, Ewa Chmielik, Barbara Jarząb. 2017. Dynamic risk stratification in the follow-up of thyroid cancer: what is still to be discovered in 2017?. *Endocrine-Related Cancer* **24**:11, R387-R402. [Crossref]

1788. Faisal Baig, Shirley Liu, Hoi-Chun Lam, Shea-Ping Yip, Helen Law, Michael Ying. 2017. Shear Wave Elastography Combining with Conventional Grey Scale Ultrasound Improves the Diagnostic Accuracy in Differentiating Benign and Malignant Thyroid Nodules. *Applied Sciences* **7**:11, 1103. [Crossref]

1789. Ki Nam Park, Se A Lee, Sang Kuk Lee, Jae Hyun Jeong, Sang Woo Sun, Jung Ja Gwak, Seung Won Lee. 2017. Predictive Factors for Occult Contralateral Papillary Thyroid Carcinoma in Patients with Ipsilateral Multifocality on Frozen Biopsy. *Korean Journal of Otorhinolaryngology-Head and Neck Surgery* **60**:10, 517-521. [Crossref]

1790. Seung Taek Lim, Ye Won Jeon, Young Jin Suh. 2017. The Prognostic Values of Preoperative Tumor Volume and Tumor Diameter in T1N0 Papillary Thyroid Cancer. *Cancer Research and Treatment* **49**:4, 890-897. [Crossref]

1791. Se Jin Nam, Jin Young Kwak, Hee Jung Moon, Jung Hyun Yoon, Eun-Kyung Kim, Ja Seung Koo. 2017. Large (≥3cm) thyroid nodules with benign cytology: Can Thyroid Imaging Reporting and Data System (TIRADS) help predict false-negative cytology?. *PLOS ONE* **12**:10, e0186242. [Crossref]

1792. Chae Moon Hong, Byeong-Cheol Ahn. 2017. Redifferentiation of Radioiodine Refractory Differentiated Thyroid Cancer for Reapplication of I-131 Therapy. *Frontiers in Endocrinology* **8**. . [Crossref]

1793. E. V. Chernenko, N. A. Shapoval, M. N. Antonyuk, T. V. Ogryzko, O. N. Sulaieva. 2017. TSH and Thyroid Hormones' Influence on Thyroid Cancer Development. *Ukraïns´kij žurnal medicini, bìologìï ta sportu* **2**:5, 112-115. [Crossref]

1794. 2017. Subclinical Hypothyroidism. *New England Journal of Medicine* **377**:14, 1404-1404. [Crossref]

1795. Sarah N Hamilton, Eric Tran, Eric Berthelet, Jonn Wu. 2017. The role of external beam radiation therapy in well-differentiated thyroid cancer. *Expert Review of Anticancer Therapy* **17**:10, 905-910. [Crossref]

1796. Siegrid G. A. de Meer, Wessel M. C. M. Vorselaars, Jakob W. Kist, Marcel P. M. Stokkel, Bart de Keizer, Gerlof D. Valk, Inne H. M. Borel Rinkes, Menno R. Vriens. 2017. Follow-up of patients with thyroglobulin-antibodies: Rising Tg-Ab trend is a risk factor for recurrence of differentiated thyroid cancer. *Endocrine Research* **42**:4, 302-310. [Crossref]

1797. Assadipour Yasmine, Yeh Michael W., Livhits Masha J.. 2017. Most Low-Risk Papillary Thyroid Cancers Remain Stable During Active Surveillance. *Clinical Thyroidology* **29**:10, 368-370. [Citation] [Full Text] [PDF] [PDF Plus]

1798. Fish Stephanie A.. 2017. Ultrasound Has a Role in Predicting Tumor Invasiveness in Follicular Variant of Papillary Thyroid Carcinoma. *Clinical Thyroidology* **29**:10, 371-374. [Citation] [Full Text] [PDF] [PDF Plus]

1799. Hershman Jerome M.. 2017. A 10-Gene Classifier Can Accurately Diagnose Malignant Versus Benign Cytologically Indeterminate Thyroid Nodules. *Clinical Thyroidology* **29**:10, 375-377. [Citation] [Full Text] [PDF] [PDF Plus]

1800. Biermann Martin. 2017. Tumor-Volume–Doubling Time of Pulmonary Metastases in Follicular-Cell–Derived Thyroid Carcinoma May Allow More Appropriate Selection of Patients for Multikinase Inhibitor Therapy. *Clinical Thyroidology* **29**:10, 378-381. [Citation] [Full Text] [PDF] [PDF Plus]

1801. Sacks Wendy. 2017. Thyroid Cancer Tumor Board: To Surveil or Not to Surveil? That Is the Question. *Clinical Thyroidology* **29**:10, 398-400. [Citation] [Full Text] [PDF] [PDF Plus]

1802. Ruhlmann Marcus, Ruhlmann Jürgen, Görges Rainer, Herrmann Ken, Antoch Gerald, Keller Hans-Wilhelm, Ruhlmann Verena. 2017. 18F-Fluorodeoxyglucose Positron Emission Tomography/Computed Tomography May Exclude Malignancy in Sonographically Suspicious and Scintigraphically Hypofunctional Thyroid Nodules and Reduce Unnecessary Thyroid Surgeries. *Thyroid* **27**:10, 1300-1306. [Abstract] [Full Text] [PDF] [PDF Plus]

1803. Ha Su Min, Kim Jae Kyun, Baek Jung Hwan. 2017. Detection of Malignancy Among Suspicious Thyroid Nodules <1 cm on Ultrasound with Various Thyroid Image Reporting and Data Systems. *Thyroid* **27**:10, 1307-1315. [Abstract] [Full Text] [PDF] [PDF Plus] [Supplementary Material]

1804. Hall Stephen F., Irish Jonathan, Groome Patti, Griffiths Rebecca, Hurlbut David. 2017. Do Lower-Risk Thyroid Cancer Patients Who Live in Regions with More Aggressive Treatments Have Better Outcomes?. *Thyroid* **27**:10, 1246-1257. [Abstract] [Full Text] [PDF] [PDF Plus]

1805. Suh Chong Hyun, Choi Young Jun, Lee Jong Jin, Shim Woo Hyun, Baek Jung Hwan, Chung Han Cheol, Shong Young Kee, Song Dong Eun, Sung Tae Yon, Lee Jeong Hyun. 2017. Comparison of Core-Needle Biopsy and Fine-Needle Aspiration for Evaluating Thyroid Incidentalomas Detected by 18F-Fluorodeoxyglucose Positron Emission Tomography/Computed Tomography: A Propensity Score Analysis. *Thyroid* **27**:10, 1258-1266. [Abstract] [Full Text] [PDF] [PDF Plus]

Downloaded by Memorial Sloan Kettering from www.liebertpub.com at 08/14/19. For personal use only.

1806. Chinn Steven B., Zafereo Mark E., Waguespack Steven G., Edeiken Beth S., Roberts Dianna B., Clayman Gary L.. 2017. Long-Term Outcomes of Lateral Neck Dissection in Patients with Recurrent or Persistent Well-Differentiated Thyroid Cancer. *Thyroid* **27**:10, 1291-1299. [Abstract] [Full Text] [PDF] [PDF Plus]

1807. Valderrabano Pablo, Khazai Laila, Thompson Zachary J., Leon Marino E., Otto Kristen J., Hallanger-Johnson Julie E., Wadsworth J. Trad, Wenig Bruce M., Chung Christine H., Centeno Barbara A., McIver Bryan. 2017. Cancer Risk Stratification of Indeterminate Thyroid Nodules: A Cytological Approach. *Thyroid* **27**:10, 1277-1284. [Abstract] [Full Text] [PDF] [PDF Plus] [Supplementary Material]

1808. Oh Hye-Seon, Park Suyeon, Kim Mijin, Kwon Hyemi, Song Eyun, Sung Tae-Yon, Lee Yu-Mi, Kim Won Gu, Kim Tae Yong, Shong Young Kee, Kim Won Bae, Jeon Min Ji. 2017. Young Age and Male Sex Are Predictors of Large-Volume Central Neck Lymph Node Metastasis in Clinical N0 Papillary Thyroid Microcarcinomas. *Thyroid* **27**:10, 1285-1290. [Abstract] [Full Text] [PDF] [PDF Plus] [Supplementary Material]

1809. J. B. Wang, K. Wu, L. H. Shi, Y. Y. Sun, F. B. Li, L. Xie. 2017. In situ preservation of the inferior parathyroid gland during central neck dissection for papillary thyroid carcinoma. *British Journal of Surgery* **104**:11, 1514-1522. [Crossref]

1810. Z. Al-Qurayshi, E. Kandil, G. W. Randolph. 2017. Cost-effectiveness of intraoperative nerve monitoring in avoidance of bilateral recurrent laryngeal nerve injury in patients undergoing total thyroidectomy. *British Journal of Surgery* **104**:11, 1523-1531. [Crossref]

1811. Hye In Kim, Tae Hyuk Kim, Jun-Ho Choe, Jung-Han Kim, Jee Soo Kim, Young Lyun Oh, Soo Yeon Hahn, Jung Hee Shin, Hye Won Jang, Young Nam Kim, Hosu Kim, Hyeon Seon Ahn, Kyunga Kim, Sun Wook Kim, Jae Hoon Chung. 2017. Restratification of survival prognosis of N1b papillary thyroid cancer by lateral lymph node ratio and largest lymph node size. *Cancer Medicine* **6**:10, 2244-2251. [Crossref]

1812. Michela Marina, Gian Paolo Ceda, Luigi Corcione, Paolo Sgargi, Maria Michiara, Enrico Maria Silini, Graziano Ceresini. 2017. Size of thyroid carcinoma by histotype and variants: A population-based study in a mildly iodine-deficient area. *Head & Neck* **39**:10, 2095-2103. [Crossref]

1813. Marybeth Cunnane, Natalia Kyriazidis, Dipti Kamani, Amy F. Juliano, Hillary R. Kelly, Hugh D. Curtin, Samuel R. Barber, Gregory W. Randolph. 2017. A novel thyroid cancer nodal map classification system to facilitate nodal localization and surgical management: The A to D map. *The Laryngoscope* **127**:10, 2429-2436. [Crossref]

1814. Lucy L. Shi, Carol DeSantis, Ahmedin Jemal, Amy Y. Chen. 2017. Changes in thyroid cancer incidence, post-2009 American Thyroid Association guidelines. *The Laryngoscope* **127**:10, 2437-2441. [Crossref]

1815. Jin Hwa Kim, Jung-Soo Pyo, Won Jin Cho. 2017. Clinicopathological Significance and Prognosis of Medullary Thyroid Microcarcinoma: A Meta-analysis. *World Journal of Surgery* **41**:10, 2551-2558. [Crossref]

1816. Shi-tong Yu, Ping Han, Faya Liang, Qian Cai, Peiliang Lin, Renhui Chen, Xiaoming Huang. 2017. Three-dimensional versus two-dimensional endoscopic-assisted thyroidectomy via the anterior chest approach: a preliminary report. *Surgical Endoscopy* **31**:10, 4194-4200. [Crossref]

1817. Seo Young Sohn, Young Nam Kim, Hye In Kim, Tae Hyuk Kim, Sun Wook Kim, Jae Hoon Chung. 2017. Validation of dynamic risk stratification in pediatric differentiated thyroid cancer. *Endocrine* **58**:1, 167-175. [Crossref]

1818. Chen-Tian Shen, Xin-Yun Zhang, Zhong-Ling Qiu, Zhen-Kui Sun, Wei-Jun Wei, Hong-Jun Song, Quan-Yong Luo. 2017. Thyroid autoimmune antibodies in patients with papillary thyroid carcinoma: a double-edged sword?. *Endocrine* **58**:1, 176-183. [Crossref]

1819. I. V. Shevchyk, B. A. Cobian, S. R. Martinez. 2017. Age-based disparities in the use of total thyroidectomy for papillary thyroid carcinoma. *Clinical and Translational Oncology* **19**:10, 1253-1259. [Crossref]

1820. Chae Moon Hong, Choon-Young Kim, Seung Hyun Son, Ji-hoon Jung, Chang-Hee Lee, Ju Hye Jeong, Shin Young Jeong, Sang-Woo Lee, Jaetae Lee, Byeong-Cheol Ahn. 2017. I-131 biokinetics of remnant normal thyroid tissue and residual thyroid cancer in patients with differentiated thyroid cancer: comparison between recombinant human TSH administration and thyroid hormone withdrawal. *Annals of Nuclear Medicine* **31**:8, 582-589. [Crossref]

1821. Hee Jeong Park, Jung-Joon Min, Hee-Seung Bom, Jahae Kim, Ho-Chun Song, Seong Young Kwon. 2017. Early stimulated thyroglobulin for response prediction after recombinant human thyrotropin-aided radioiodine therapy. *Annals of Nuclear Medicine* **31**:8, 616-622. [Crossref]

1822. Rossella Elisei, Francesco Trimarchi. 2017. Comunicare con la persona con cancro della tiroide in progressione. *L'Endocrinologo* **18**:5, 224-230. [Crossref]

1823. Luigi Bartalena, Francesco Trimarchi, Paolo Vitti. 2017. Noduli tiroidei benigni: terapia con L-tiroxina sì o no?. *L'Endocrinologo* **18**:5, 240-241. [Crossref]

Downloaded by Memorial Sloan Kettering from www.liebertpub.com at 08/14/19. For personal use only.

1824. Haliimah A. Nattabi, Norhafidzah M. Sharif, Noorazrul Yahya, Rozilawati Ahmad, Mazlyfarina Mohamad, Faizah M. Zaki, Ahmad N. Yusoff. 2017. Is Diagnostic Performance of Quantitative 2D-Shear Wave Elastography Optimal for Clinical Classification of Benign and Malignant Thyroid Nodules?. *Academic Radiology* . [Crossref]

1825. Óscar González, Carles Zafon, Enric Caubet, Amparo García-Burillo, Xavier Serres, José Manuel Fort, Jordi Mesa, Joan Castell, Isabel Roca, Santiago Ramón y Cajal, Carmela Iglesias. 2017. Selective sentinel lymph node biopsy in papillary thyroid carcinoma in patients with no preoperative evidence of lymph node metastasis. *Endocrinología, Diabetes y Nutrición (English ed.)* **64**:8, 451-455. [Crossref]

1826. Karan Saluja, Randall T. Butler, Kristen B. Pytynia, Bihong Zhao, Ron J. Karni, Randal S. Weber, Adel K. El-Naggar. 2017. Mucoepidermoid carcinoma post–radioactive iodine treatment of papillary thyroid carcinoma: unique presentation and putative etiologic association. *Human Pathology* **68**, 189-192. [Crossref]

1827. Amanda K. Price, Reese W. Randle, David F. Schneider, Rebecca S. Sippel, Susan C. Pitt. 2017. Papillary thyroid microcarcinoma: decision-making, extent of surgery, and outcomes. *Journal of Surgical Research* **218**, 237-245. [Crossref]

1828. Daniel Thomas Ginat, Anca M. Avram. 2017. Chapter 4 Thyroid Malignancy: Staging and Restaging. *Seminars in Ultrasound, CT and MRI* **38**:5, 495-505. [Crossref]

1829. Ping Dong, Ni Chen, Lin Li, Rui Huang. 2017. An upper cervical cord compression secondary to occult follicular thyroid carcinoma metastases successfully treated with multiple radioiodine therapies. *Medicine* **96**:41, e8215. [Crossref]

1830. Barbara Salvatore, Michele Klain, Emanuele Nicolai, Domenico D'Amico, Gianluca De Matteis, Marco Raddi, Rosa Fonti, Teresa Pellegrino, Giovanni Storto, Alberto Cuocolo, Leonardo Pace. 2017. Prognostic role of FDG PET/CT in patients with differentiated thyroid cancer treated with 131-iodine empiric therapy. *Medicine* **96**:42, e8344. [Crossref]

1831. Wen Liu, Ruochuan Cheng, Yanjun Su, Chang Diao, Jun Qian, Jianming Zhang, Yunhai Ma, Yinxia Fan. 2017. Risk factors of central lymph node metastasis of papillary thyroid carcinoma. *Medicine* **96**:43, e8365. [Crossref]

1832. Sandip Basu, Ashwini Kalshetty. 2017. Volumetric high-resolution computed tomography in evaluating pulmonary metastases from differentiated thyroid carcinoma. *Nuclear Medicine Communications* **38**:10, 881-882. [Crossref]

1833. D. Ozdemir, N. Bestepe, S. Faki, A. Kilicarslan, O. Parlak, R. Ersoy, B. Cakir. 2017. Comparison of thyroid fine needle aspiration biopsy results before and after implementation of Bethesda classification. *Cytopathology* **28**:5, 400-406. [Crossref]

1834. Alex C. Essenmacher, Peter H. Joyce, Simon C. Kao, Monica Epelman, Liuska M. Pesce, Michael P. D'Alessandro, Yutaka Sato, Craig M. Johnson, Daniel J. Podberesky. 2017. Sonographic Evaluation of Pediatric Thyroid Nodules. *RadioGraphics* **37**:6, 1731-1752. [Crossref]

1835. Michael Canfarotta, Douglas Moote, Christine Finck, Rebecca Riba-Wolman, Shefali Thaker, Trudy J. Lerer, Richard J. Payne, Valerie Cote. 2017. McGill Thyroid Nodule Score in Differentiating Benign and Malignant Pediatric Thyroid Nodules: A Pilot Study. *Otolaryngology–Head and Neck Surgery* **157**:4, 589-595. [Crossref]

1836. Scott Shapiro, Majed Pharaon, Brian Kellermeyer. 2017. Cost-effectiveness of Gene Expression Classifier Testing of Indeterminate Thyroid Nodules Utilizing a Real Cohort Comparator. *Otolaryngology–Head and Neck Surgery* **157**:4, 596-601. [Crossref]

1837. Huy Gia Vuong, Ahmed MA Altibi, Uyen NP Duong, Hanh TT Ngo, Thong Quang Pham, Hung Minh Tran, Naoki Oishi, Kunio Mochizuki, Tadao Nakazawa, Lewis Hassell, Ryohei Katoh, Tetsuo Kondo. 2017. Role of molecular markers to predict distant metastasis in papillary thyroid carcinoma: Promising value of TERT promoter mutations and insignificant role of BRAF mutations—a meta-analysis. *Tumor Biology* **39**:10, 101042831771391. [Crossref]

1838. Si Hyoung Kim, Jun Goo Kang, Chul Sik Kim, Sung-Hee Ihm, Moon Gi Choi, Hyung Joon Yoo, Seong Jin Lee. 2017. The dipeptidyl peptidase-IV inhibitor gemigliptin alone or in combination with NVP-AUY922 has a cytotoxic activity in thyroid carcinoma cells. *Tumor Biology* **39**:10, 101042831772206. [Crossref]

1839. Pablo Valderrabano, Bryan McIver. 2017. Evaluation and Management of Indeterminate Thyroid Nodules. *Cancer Control* **24**:5, 107327481772923. [Crossref]

1840. Richa Singh, Jorge Avila, Kahee Jo, Kevin T. K. Nguyen, Nika Roa Carrillo, Eric C. Huang, Michael J. Campbell. 2017. Patients with Non-invasive Follicular Thyroid Neoplasm with Papillary-Like Nuclear Features are Unlikely to have Malignant Preoperative Cytology. *Annals of Surgical Oncology* **24**:11, 3300-3305. [Crossref]

1841. Eun Sil Kim, Younghen Lee, Hyungsuk Seo, Gil Soo Son, Soon Young Kwon, Young-Sik Kim, Ji-A Seo, Nan Hee Kim, Sang-il Suh, Inseon Ryoo, Sung-Hye You. 2017. Clinical features of recently diagnosed papillary thyroid carcinoma in elderly patients aged 65 and older based on 10 years of sonographic experience at a single institution in Korea. *Ultrasonography* **36**:4, 355-362. [Crossref]

1842. Hye Jung Kim. 2017. Updated guidelines on the preoperative staging of thyroid cancer. *Ultrasonography* **36**:4, 292-299. [Crossref]

Downloaded by Memorial Sloan Kettering from www.liebertpub.com at 08/14/19. For personal use only.

1843. Dingyuan Luo, Haibo Chen, Xiaojuan Li, Penghui Lu, Miaoyun Long, Xinzhi Peng, Shaojian Lin, Langping Tan, Yue Zhu, Nengtai Ouyang, Honghao Li. 2017. Activation of the ROCK1/MMP-9 pathway is associated with the invasion and poor prognosis in papillary thyroid carcinoma. *International Journal of Oncology* **51**:4, 1209-1218. [Crossref]

1844. Dania Hirsch, Sigal Levy, Gloria Tsvetov, Alexander Gorshtein, Ilana Slutzky-Shraga, Amit Akirov, Eyal Robenshtok, Ilan Shimon, Carlos A. Benbassat. 2017. LONG-TERM OUTCOMES AND PROGNOSTIC FACTORS IN PATIENTS WITH DIFFERENTIATED THYROID CANCER AND DISTANT METASTASES. *Endocrine Practice* **23**:10, 1193-1200. [Crossref]

1845. Eric J. Kuo, James X. Wu, Ning Li, Kyle A. Zanocco, Michael W. Yeh, Masha J. Livhits. 2017. NONOPERATIVE MANAGEMENT OF DIFFERENTIATED THYROID CANCER IN CALIFORNIA: A POPULATION-LEVEL ANALYSIS OF 29,978 PATIENTS. *Endocrine Practice* **23**:10, 1262-1269. [Crossref]

1846. Hasan Demirhan, Bahtiyar Hamit, Ahmet Volkan Sünter, Özgür Yiğit. 2017. Are total thyroidectomy and loboisthmectomy effective and safe in benign thyroid diseases? An analysis of 420 patients. *The European Research Journal* . [Crossref]

1847. Ji H. Yang, Rui M. B. Maciel, Claudia C. D. Nakabashi, Carolina C. P. S. Janovsky, Rosalia P. Padovani, Danielle Macellaro, Cléber P. Camacho, Akemi Osawa, Jairo Wagner, Rosa Paula M. Biscolla. 2017. Clinical utility of 18F-FDG PET/CT in the follow-up of a large cohort of patients with high-risk differentiated thyroid carcinoma. *Archives of Endocrinology and Metabolism* **61**:5, 416-425. [Crossref]

1848. Mohammad Hossein Khosravi, Ali Kouhi, Masoumeh Saeedi, Ali Bagherihagh, Mohammad Hosein Amirzade-Iranaq. Thyroid Cancers: Considerations, Classifications, and Managements . [Crossref]

1849. Alex González Bóssolo, Michelle Mangual Garcia, Paula Jeffs González, Miosotis Garcia, Guillermo Villarmarzo, Jose Hernán Martinez. 2017. A new paradigm in low-risk papillary microcarcinoma: active surveillance. *Endocrinology, Diabetes & Metabolism Case Reports* . [Crossref]

1850. Biermann Martin. 2017. Large Retrospective Study Confirms the 2015 American Thyroid Association Guidelines for Classifying Small Thyroid Nodules on Ultrasound. *Clinical Thyroidology* **29**:9, 344-347. [Citation] [Full Text] [PDF] [PDF Plus]

1851. Leung Angela M.. 2017. Racial and Insurer-Based Disparities of Care Exist Among Thyroid Cancer Patients in the United States. *Clinical Thyroidology* **29**:9, 351-353. [Citation] [Full Text] [PDF] [PDF Plus]

1852. Yabuta Tomonori, Matsuse Michiko, Hirokawa Mitsuyoshi, Yamashita Shunichi, Mitsutake Norisato, Miyauchi Akira. 2017. TERT Promoter Mutations Were Not Found in Papillary Thyroid Microcarcinomas That Showed Disease Progression on Active Surveillance. *Thyroid* **27**:9, 1206-1207. [Citation] [Full Text] [PDF] [PDF Plus]

1853. Hahn Soo Yeon, Shin Jung Hee, Oh Young Lyun, Kim Tae Hyuk, Lim Yaeji, Choi Ji Soo. 2017. Role of Ultrasound in Predicting Tumor Invasiveness in Follicular Variant of Papillary Thyroid Carcinoma. *Thyroid* **27**:9, 1177-1184. [Abstract] [Full Text] [PDF] [PDF Plus]

1854. Robenshtok Eyal, Nachalon Yuval, Benbassat Carlos, Hirsch Dania, Shimon Ilan, Grossman Alon, Diker-Cohen Talia, Akirov Amit, Popovtzer Aharon. 2017. Disease Severity at Presentation in Patients with Disease-Related Mortality from Differentiated Thyroid Cancer: Implications for the 2015 ATA Guidelines. *Thyroid* **27**:9, 1171-1176. [Abstract] [Full Text] [PDF] [PDF Plus]

1855. Kim Mijin, Kim Won Gu, Oh Hye-Seon, Park Suyeon, Kwon Hyemi, Song Dong Eun, Kim Tae Yong, Shong Young Kee, Kim Won Bae, Sung Tae-Yon, Jeon Min Ji. 2017. Comparison of the Seventh and Eighth Editions of the American Joint Committee on Cancer/Union for International Cancer Control Tumor-Node-Metastasis Staging System for Differentiated Thyroid Cancer. *Thyroid* **27**:9, 1149-1155. [Abstract] [Full Text] [PDF] [PDF Plus]

1856. Huang Funan, Ajavon Antoinette, Huang Erya, Lettieri John, Liu Rong, Peña Carol, Berse Matthias. 2017. No Effect of Levothyroxine and Levothyroxine-Induced Subclinical Thyrotoxicosis on the Pharmacokinetics of Sorafenib in Healthy Male Subjects. *Thyroid* **27**:9, 1118-1127. [Abstract] [Full Text] [PDF] [PDF Plus]

1857. Park Suyeon, Kim Won Gu, Han Minkyu, Jeon Min Ji, Kwon Hyemi, Kim Mijin, Sung Tae-Yon, Kim Tae Yong, Kim Won Bae, Hong Suck Joon, Shong Young Kee. 2017. Thyrotropin Suppressive Therapy for Low-Risk Small Thyroid Cancer: A Propensity Score–Matched Cohort Study. *Thyroid* **27**:9, 1164-1170. [Abstract] [Full Text] [PDF] [PDF Plus] [Supplementary Material]

1858. Baiju R. Shah, Rebecca Griffiths, Stephen F. Hall. 2017. Thyroid cancer incidence among Asian immigrants to Ontario, Canada: A population-based cohort study. *Cancer* **123**:17, 3320-3325. [Crossref]

1859. Jen-Fan Hang, William H. Westra, David S. Cooper, Syed Z. Ali. 2017. The impact of noninvasive follicular thyroid neoplasm with papillary-like nuclear features on the performance of the Afirma gene expression classifier. *Cancer Cytopathology* **125**:9, 683-691. [Crossref]

1860. Sudarshana Roychoudhury, Fabiola Souza, Cecilia Gimenez, Ryan Glass, Rubina Cocker, Karen Chau, Nina Kohn, Kasturi Das. 2017. Utility of intraoperative frozen sections for thyroid nodules with prior fine needle aspiration cytology diagnosis. *Diagnostic Cytopathology* **45**:9, 789-794. [Crossref]

Downloaded by Memorial Sloan Kettering from www.liebertpub.com at 08/14/19. For personal use only.

1861. Meghan E. Rowe, Marcela Osorio, Ilya Likhterov, Mark L. Urken. 2017. Evaluation of ultrasound reporting for thyroid cancer diagnosis and surveillance. *Head & Neck* **39**:9, 1756-1760. [Crossref]

1862. Laura Boucai, Victor Bernet, Ashok Shaha, Maisie L. Shindo, Brendan C. Stack, Robert M. Tuttle. 2017. Surgical considerations for papillary thyroid microcarcinomas. *Journal of Surgical Oncology* **116**:3, 269-274. [Crossref]

1863. Wouter P. Kluijfhout, Frederick T. Drake, Jesse D. Pasternak, Toni Beninato, Menno R. Vriens, Wen T. Shen, Jessica E. Gosnell, Chienying Liu, Insoo Suh, Quan-Yang Duh. 2017. Incidental positive lymph nodes in patients with papillary thyroid cancer is independently associated with recurrent disease. *Journal of Surgical Oncology* **116**:3, 275-280. [Crossref]

1864. Jong-Lyel Roh, Jun Woo Park, Junhyeop Jeong, Gyungyup Gong, Kyung-Ja Cho, Seung-Ho Choi, Soon Yuhl Nam, Sang Yoon Kim. 2017. Extranodal extension of lymph node metastasis as a prognostic indicator of recurrence and survival in papillary thyroid carcinoma. *Journal of Surgical Oncology* **116**:4, 450-458. [Crossref]

1865. Emad Kandil, Muhammad A. Anwar, Jeremy Bamford, Rizwan Aslam, Gregory W. Randolph. 2017. Electrophysiological identification of nonrecurrent laryngeal nerves. *The Laryngoscope* **127**:9, 2189-2193. [Crossref]

1866. Ken Watanabe, Mayuki Uchiyama, Kunihiko Fukuda. 2017. The outcome of I-131 ablation therapy for intermediate and high-risk differentiated thyroid cancer using a strict definition of successful ablation. *Japanese Journal of Radiology* **35**:9, 505-510. [Crossref]

1867. Yuanxin Liang, Tao Zuo. 2017. Papillary Thyroid Carcinoma Cervical Lymph Node Metastasis with Cystic Change Differentiated from Congenital Cystic Lesions with the Assistance of Immunohistochemistry: A Case Study. *Head and Neck Pathology* **11**:3, 301-305. [Crossref]

1868. Arvind Krishnamurthy, Vijayalakshmi Ramshankar. 2017. Recent Advances in Our Understanding of Well-Differentiated Thyroid Cancers. *Indian Journal of Surgical Oncology* **8**:3, 255-257. [Crossref]

1869. F. Nabhan, K. Porter, L. Senter, M. D. Ringel. 2017. Anti-thyroglobulin antibodies do not significantly increase the risk of finding iodine avid metastases on post-radioactive iodine ablation scan in low-risk thyroid cancer patients. *Journal of Endocrinological Investigation* **40**:9, 1015-1021. [Crossref]

1870. Davide Giordano, Andrea Frasoldati, Enrico Gabrielli, Carmine Pernice, Michele Zini, Andrea Castellucci, Simonetta Piana, Alessia Ciarrocchi, Silvio Cavuto, Verter Barbieri. 2017. Long-term outcomes of central neck dissection for cN0 papillary thyroid carcinoma. *American Journal of Otolaryngology* **38**:5, 576-581. [Crossref]

1871. Samuel J. Trosman, Rohith Bhargavan, Brandon L. Prendes, Brian B. Burkey, Joseph Scharpf. 2017. The contemporary utility of intraoperative frozen sections in thyroid surgery. *American Journal of Otolaryngology* **38**:5, 614-617. [Crossref]

1872. Karole Collier, John Sataloff, Chris Wirtalla, Lindsay Kuo, Giorgos C. Karakousis, Rachel R. Kelz. 2017. Understanding readmissions following operations of the thyroid and parathyroid glands. *The American Journal of Surgery* **214**:3, 501-508. [Crossref]

1873. Nazanene H. Esfandiari, Maria Papaleontiou. 2017. Biochemical Testing in Thyroid Disorders. *Endocrinology and Metabolism Clinics of North America* **46**:3, 631-648. [Crossref]

1874. Douglas Van Nostrand. 2017. Selected Controversies of Radioiodine Imaging and Therapy in Differentiated Thyroid Cancer. *Endocrinology and Metabolism Clinics of North America* **46**:3, 783-793. [Crossref]

1875. Michelle Melany, Sardius Chen. 2017. Thyroid Cancer. *Endocrinology and Metabolism Clinics of North America* **46**:3, 691-711. [Crossref]

1876. P.W. Rosario. 2017. Is radioiodine ablation necessary for patients with low-risk papillary thyroid carcinoma and tumor >4 cm?. *European Journal of Surgical Oncology* **43**:9, 1802-1803. [Crossref]

1877. J.L. Marti, L.G.T. Morris, A.S. Ho. 2017. Reply to: Radioiodine ablation necessary for patients with low-risk papillary thyroid carcinoma and tumor >4 cm?. *European Journal of Surgical Oncology* **43**:9, 1804. [Crossref]

1878. Alaa M. Sewefy, Tohamy A. Tohamy, Tarek M. Esmael, Ahmed M. Atyia. 2017. Intra-capsular total thyroid enucleation versus total thyroidectomy in treatment of benign multinodular goiter. A prospective randomized controlled clinical trial. *International Journal of Surgery* **45**, 29-34. [Crossref]

1879. Andrew A Renshaw, Edwin W Gould. 2017. Impact of Noninvasive Follicular Thyroid Neoplasm With Papillary-Like Features on Adequacy Criteria and Risk of Malignancy of Thyroid Fine-Needle Aspiration. *American Journal of Clinical Pathology* **148**:3, 259-263. [Crossref]

1880. Jiru Yuan, Jinghua Li, Xiaoyi Chen, Zhenwei Zhong, Zhengbo Chen, Ying Yin, Jialin Du, Shuzhen Cong, Zeyu Wu. 2017. Predictors of lymph nodes posterior to the right recurrent laryngeal nerve metastasis in patients with papillary thyroid carcinoma. *Medicine* **96**:35, e7908. [Crossref]

1881. Sheng-Fong Kuo, Tsung-Ying Ho, Miaw-Jene Liou, Kun-Ju Lin, Ru-Chin Cheng, Sheng-Chieh Chan, Bie-Yui Huang, Soh-Ching Ng, Feng-Hsuan Liu, Hung-Yu Chang, Sheng-Hwu Hsieh, Kun-Chun Chiang, Huang-Yang Chen, Ta-You Lo, Chih-

Downloaded by Memorial Sloan Kettering from www.liebertpub.com at 08/14/19. For personal use only.

Lang Lin, Jen-Der Lin. 2017. Higher body weight and distant metastasis are associated with higher radiation exposure to the household environment from patients with thyroid cancer after radioactive iodine therapy. *Medicine* **96**:35, e7942. [Crossref]

1882. Anping Su, Bin Wang, Yanping Gong, Rixiang Gong, Zhihui Li, Jingqiang Zhu. 2017. Risk factors of hypoparathyroidism following total thyroidectomy with central lymph node dissection. *Medicine* **96**:39, e8162. [Crossref]

1883. Jianwei Zheng, Huimin Song, Shuyan Cai, Yunlei Wang, Xiaofeng Han, Haoliang Wu, Zhigang Gao, Fanrong Qiu. 2017. Evaluation of clinical significance and risk factors of incidental parathyroidectomy due to thyroidectomy. *Medicine* **96**:39, e8175. [Crossref]

1884. Fulvio Basolo, Elisabetta Macerola, Clara Ugolini, David N. Poller, Zubair Baloch. 2017. The Molecular Landscape of Noninvasive Follicular Thyroid Neoplasm With Papillary-like Nuclear Features (NIFTP). *Advances In Anatomic Pathology* **24**:5, 252-258. [Crossref]

1885. Guohua Shen, Zhongzhi Qi, Rui Huang, Bin Liu, Anren Kuang. 2017. False-Positive Uptake of Radioiodine in Renal Hamartoma in a Patient With Differentiated Thyroid Cancer. *Clinical Nuclear Medicine* **42**:9, 709-710. [Crossref]

1886. Hye In Kim, Tae Hyuk Kim, Hosu Kim, Young Nam Kim, Hye Won Jang, Jung-Han Kim, Kyu Yeon Hur, Jae Hoon Chung, Sun Wook Kim. 2017. Delayed TSH recovery after dose adjustment during TSH-suppressive levothyroxine therapy of thyroid cancer. *Clinical Endocrinology* **87**:3, 286-291. [Crossref]

1887. Kwanhoon Jo, Min-Hee Kim, Jeonghoon Ha, Yejee Lim, Sohee Lee, Ja Seong Bae, Chan Kwon Jung, Moo Il Kang, Bong Yun Cha, Dong-Jun Lim. 2017. Prognostic value of preoperative anti-thyroglobulin antibody in differentiated thyroid cancer. *Clinical Endocrinology* **87**:3, 292-299. [Crossref]

1888. Laura Sterian Ward, Danilo Villagelin. 2017. Thyroid function after TSH suppression for thyroid cancer: When is optimal time to check?. *Clinical Endocrinology* **87**:3, 231-232. [Crossref]

1889. Brian Hung-Hin Lang, Yu-Cho Woo, Carlos K. H. Wong. 2017. High-Intensity Focused Ultrasound for Treatment of Symptomatic Benign Thyroid Nodules: A Prospective Study. *Radiology* **284**:3, 897-906. [Crossref]

1890. Ji Hye Lee, Kyunghwa Han, Eun-Kyung Kim, Hee Jung Moon, Jung Hyun Yoon, Vivian Y. Park, Jin Young Kwak. 2017. Risk Stratification of Thyroid Nodules With Atypia of Undetermined Significance/Follicular Lesion of Undetermined Significance (AUS/FLUS) Cytology Using Ultrasonography Patterns Defined by the 2015 ATA Guidelines. *Annals of Otology, Rhinology & Laryngology* **126**:9, 625-633. [Crossref]

1891. Melissa A. Pynnonen, M. Boyd Gillespie, Benjamin Roman, Richard M. Rosenfeld, David E. Tunkel, Laura Bontempo, Itzhak Brook, Davoren Ann Chick, Maria Colandrea, Sandra A. Finestone, Jason C. Fowler, Christopher C. Griffith, Zeb Henson, Corinna Levine, Vikas Mehta, Andrew Salama, Joseph Scharpf, Deborah R. Shatzkes, Wendy B. Stern, Jay S. Youngerman, Maureen D. Corrigan. 2017. Clinical Practice Guideline: Evaluation of the Neck Mass in Adults. *Otolaryngology–Head and Neck Surgery* **157**:2_suppl, S1-S30. [Crossref]

1892. Melissa A. Pynnonen, M. Boyd Gillespie, Benjamin Roman, Richard M. Rosenfeld, David E. Tunkel, Laura Bontempo, Itzhak Brook, Davoren Ann Chick, Maria Colandrea, Sandra A. Finestone, Jason C. Fowler, Christopher C. Griffith, Zeb Henson, Corinna Levine, Vikas Mehta, Andrew Salama, Joseph Scharpf, Deborah R. Shatzkes, Wendy B. Stern, Jay S. Youngerman, Maureen D. Corrigan. 2017. Clinical Practice Guideline: Evaluation of the Neck Mass in Adults Executive Summary. *Otolaryngology–Head and Neck Surgery* **157**:3, 355-371. [Crossref]

1893. Fei Wang, Xiaolong Yu, Xiaopei Shen, Guangwu Zhu, Yueye Huang, Rengyun Liu, David Viola, Rossella Elisei, Efisio Puxeddu, Laura Fugazzola, Carla Colombo, Barbara Jarzab, Agnieszka Czarniecka, Alfred K Lam, Caterina Mian, Federica Vianello, Linwah Yip, Garcilaso Riesco-Eizaguirre, Pilar Santisteban, Christine J O'Neill, Mark S Sywak, Roderick Clifton-Bligh, Bela Bendlova, Vlasta Sýkorová, Yangang Wang, Shiguo Liu, Jiajun Zhao, Shihua Zhao, Mingzhao Xing. 2017. The Prognostic Value of Tumor Multifocality in Clinical Outcomes of Papillary Thyroid Cancer. *The Journal of Clinical Endocrinology & Metabolism* **102**:9, 3241-3250. [Crossref]

1894. Ari J Wassner, Margaret Della Vecchia, Petr Jarolim, Henry A Feldman, Stephen A Huang. 2017. Prevalence and Significance of Thyroglobulin Antibodies in Pediatric Thyroid Cancer. *The Journal of Clinical Endocrinology & Metabolism* **102**:9, 3146-3153. [Crossref]

1895. Hyemi Kwon, Min Ji Jeon, Won Gu Kim, Suyeon Park, Mijin Kim, Tae Yong Kim, Minkyu Han, Dong Eun Song, Tae-Yon Sung, Jong Ho Yoon, Suck Joon Hong, Jin-Sook Ryu, Young Kee Shong, Won Bae Kim. 2017. Lack of Efficacy of Radioiodine Remnant Ablation for Papillary Thyroid Microcarcinoma: Verification Using Inverse Probability of Treatment Weighting. *Annals of Surgical Oncology* **24**:9, 2596-2602. [Crossref]

1896. Nicole K. Zern, Roderick Clifton-Bligh, Anthony J. Gill, Ahmad Aniss, Stan Sidhu, Leigh Delbridge, Diana Learoyd, Bruce Robinson, Mark Sywak. 2017. Disease Progression in Papillary Thyroid Cancer with Biochemical Incomplete Response to Initial Therapy. *Annals of Surgical Oncology* **24**:9, 2611-2616. [Crossref]

Downloaded by Memorial Sloan Kettering from www.liebertpub.com at 08/14/19. For personal use only.

1897. Vincenzo Marotta, Concetta Sciammarella, Maria Grazia Chiofalo, Claudio Gambardella, Claudio Bellevicine, Marica Grasso, Giovanni Conzo, Giovanni Docimo, Gerardo Botti, Simona Losito, Giancarlo Troncone, Maurizio De Palma, Laura Giacomelli, Luciano Pezzullo, Annamaria Colao, Antongiulio Faggiano. 2017. Hashimoto's thyroiditis predicts outcome in intrathyroidal papillary thyroid cancer. *Endocrine-Related Cancer* **24**:9, 485-493. [Crossref]

1898. Carlos Alberto Buchpiguel. 2017. Is the 18F-FDG PET/CT the definite resource to detect the recurrence on high-risk thyroid cancer patients?. *Archives of Endocrinology and Metabolism* **61**:5, 411-413. [Crossref]

1899. Zubair W. Baloch, R. Mack Harrell, Elise M. Brett, Gregory Randolph, Jeffrey R. Garber. 2017. AMERICAN ASSOCIATION OF CLINICAL ENDOCRINOLOGISTS AND AMERICAN COLLEGE OF ENDOCRINOLOGY DISEASE STATE COMMENTARY: MANAGING THYROID TUMORS DIAGNOSED AS NONINVASIVE FOLLICULAR THYROID NEOPLASM WITH PAPILLARY-LIKE NUCLEAR FEATURES. *Endocrine Practice* **23**:9, 1153-1158. [Crossref]

1900. Dan Mei, Bin Lv, Bo Chen, Shan Xiao, Jie Jiang, Yan Xie, Ling Jiang. 2017. All-trans retinoic acid suppresses malignant characteristics of CD133-positive thyroid cancer stem cells and induces apoptosis. *PLOS ONE* **12**:8, e0182835. [Crossref]

1901. Seyedmohammad Pourshahid. 2017. Five-Year Institutional Experience on the Impact of Afirma and ThyroSeq v2 on Indeterminate Thyroid Nodules for Malignancy Prediction. *Women's Health* **5**:6. . [Crossref]

1902. So Yeong Jeong, Jung Hwan Baek, Young Jun Choi, Jeong Hyun Lee. 2017. Ethanol and thermal ablation for malignant thyroid tumours. *International Journal of Hyperthermia* **29**, 1-8. [Crossref]

1903. Brian H. H. Lang, Yu Cho Woo, Keith W. H. Chiu. 2017. The percentage of serum thyroglobulin rise in the first-week did not predict the eventual success of high-intensity focussed ablation (HIFU) for benign thyroid nodules. *International Journal of Hyperthermia* **83**, 1-6. [Crossref]

1904. Gilles Russ, Steen J. Bonnema, Murat Faik Erdogan, Cosimo Durante, Rose Ngu, Laurence Leenhardt. 2017. European Thyroid Association Guidelines for Ultrasound Malignancy Risk Stratification of Thyroid Nodules in Adults: The EU-TIRADS. *European Thyroid Journal* . [Crossref]

1905. Tang Alice L., Falciglia Mercedes, Yang Huaitao, Mark Jonathan R., Steward David L.. 2017. Validation of American Thyroid Association Ultrasound Risk Assessment of Thyroid Nodules Selected for Ultrasound Fine-Needle Aspiration. *Thyroid* **27**:8, 1077-1082. [Abstract] [Full Text] [PDF] [PDF Plus]

1906. Cabanillas Maria E., Terris David J., Sabra Mona M.. 2017. Information for Clinicians: Approach to the Patient with Progressive Radioiodine-Refractory Thyroid Cancer—When to Use Systemic Therapy. *Thyroid* **27**:8, 987-993. [Citation] [Full Text] [PDF] [PDF Plus]

1907. Hedman Christel, Djärv Therese, Strang Peter, Lundgren Catharina Ihre. 2017. Effect of Thyroid-Related Symptoms on Long-Term Quality of Life in Patients with Differentiated Thyroid Carcinoma: A Population-Based Study in Sweden. *Thyroid* **27**:8, 1034-1042. [Abstract] [Full Text] [PDF] [PDF Plus]

1908. Silva-Vieira Margarida, Carrilho Vaz Sofia, Esteves Susana, Ferreira Teresa C., Limbert Edward, Salgado Lucília, Leite Valeriano. 2017. Second Primary Cancer in Patients with Differentiated Thyroid Cancer: Does Radioiodine Play a Role?. *Thyroid* **27**:8, 1068-1076. [Abstract] [Full Text] [PDF] [PDF Plus]

1909. Klubo-Gwiezdzinska Joanna, Yang Lily, Merkel Roxanne, Patel Dhaval, Nilubol Naris, Merino Maria J., Skarulis Monica, Sadowski Samira M., Kebebew Electron. 2017. Results of Screening in Familial Non-Medullary Thyroid Cancer. *Thyroid* **27**:8, 1017-1024. [Abstract] [Full Text] [PDF] [PDF Plus] [Supplementary Material]

1910. González Hernán E., Martínez José R., Vargas-Salas Sergio, Solar Antonieta, Veliz Loreto, Cruz Francisco, Arias Tatiana, Loyola Soledad, Horvath Eleonora, Tala Hernán, Traipe Eufrosina, Meneses Manuel, Marín Luis, Wohllk Nelson, Diaz René E., Véliz Jesús, Pineda Pedro, Arroyo Patricia, Mena Natalia, Bracamonte Milagros, Miranda Giovanna, Bruce Elsa, Urra Soledad. 2017. A 10-Gene Classifier for Indeterminate Thyroid Nodules: Development and Multicenter Accuracy Study. *Thyroid* **27**:8, 1058-1067. [Abstract] [Full Text] [PDF] [PDF Plus] [Supplementary Material]

1911. Mona M. Sabra, Eric J. Sherman, R. Michael Tuttle. 2017. Tumor volume doubling time of pulmonary metastases predicts overall survival and can guide the initiation of multikinase inhibitor therapy in patients with metastatic, follicular cell-derived thyroid carcinoma. *Cancer* **123**:15, 2955-2964. [Crossref]

1912. Marc Pusztaszeri, Manon Auger. 2017. Update on the cytologic features of papillary thyroid carcinoma variants. *Diagnostic Cytopathology* **45**:8, 714-730. [Crossref]

1913. Mohammed T. Lilo, Justin A. Bishop, Syed Z. Ali. 2017. Hobnail variant of papillary thyroid carcinoma: A case with an unusual presentation. *Diagnostic Cytopathology* **45**:8, 754-756. [Crossref]

1914. Neerav Goyal, Michael Pakdaman, Dipti Kamani, Diana Caragacianu, David Goldenberg, Gregory W. Randolph. 2017. Mapping the distribution of nodal metastases in papillary thyroid carcinoma: Where exactly are the nodes?. *The Laryngoscope* **127**:8, 1959-1964. [Crossref]

Downloaded by Memorial Sloan Kettering from www.liebertpub.com at 08/14/19. For personal use only.

1915. Sohail Bakkar, Marco Biricotti, Gianni Stefanini, Carlo Enrico Ambrosini, Gabriele Materazzi, Paolo Miccoli. 2017. The extent of surgery in thyroglossal cyst carcinoma. *Langenbeck's Archives of Surgery* **402**:5, 799-804. [Crossref]

1916. Michela Marina, Gian Paolo Ceda, Raffaella Aldigeri, Graziano Ceresini. 2017. Causes of referral to the first endocrine visit of patients with thyroid carcinoma in a mildly iodine-deficient area. *Endocrine* **57**:2, 247-255. [Crossref]

1917. Giorgio Grani, Livia Lamartina, Valeria Ascoli, Daniela Bosco, Francesco Nardi, Ferdinando D'Ambrosio, Antonello Rubini, Laura Giacomelli, Marco Biffoni, Sebastiano Filetti, Cosimo Durante, Vito Cantisani. 2017. Ultrasonography scoring systems can rule out malignancy in cytologically indeterminate thyroid nodules. *Endocrine* **57**:2, 256-261. [Crossref]

1918. Tae Hyuk Kim, Chang-Seok Ki, Soo Yeon Hahn, Young Lyun Oh, Hye Won Jang, Sun Wook Kim, Jae Hoon Chung, Jung Hee Shin. 2017. Ultrasonographic prediction of highly aggressive telomerase reverse transcriptase (TERT) promoter-mutated papillary thyroid cancer. *Endocrine* **57**:2, 234-240. [Crossref]

1919. Amanda La Greca, Fabián Pitoia, R. Michael Tuttle. 2017. The "broken chair" in patients with differentiated thyroid cancer. *Endocrine* **57**:2, 359-360. [Crossref]

1920. U. Mousa, A. S. Yikilmaz, A. Nar. 2017. Stimulated thyroglobulin values above 5.6?ng/ml before radioactive iodine ablation treatment following levothyroxine withdrawal is associated with a 2.38-fold risk of relapse in Tg-ab negative subjects with differentiated thyroid cancer. *Clinical and Translational Oncology* **19**:8, 1028-1034. [Crossref]

1921. Carlos K. H. Wong, Brian H. H. Lang, Hill M. S. Yu, Cindy L. K. Lam. 2017. EQ-5D-5L and SF-6D Utility Measures in Symptomatic benign Thyroid Nodules: Acceptability and Psychometric Evaluation. *The Patient - Patient-Centered Outcomes Research* **10**:4, 447-454. [Crossref]

1922. Jianfu Xia, Huiling Chen, Qiang Li, Minda Zhou, Limin Chen, Zhennao Cai, Yang Fang, Hong Zhou. 2017. Ultrasound-based differentiation of malignant and benign thyroid Nodules: An extreme learning machine approach. *Computer Methods and Programs in Biomedicine* **147**, 37-49. [Crossref]

1923. Zviadi Aburjania, Samuel Jang, Celina Montemayor-Garcia, Ricardo V. Lloyd, David F. Schneider, Rebecca S. Sippel, Herbert Chen, Dawn M. Elfenbein. 2017. Encapsulated follicular variant of papillary thyroid cancer: are these tumors really benign?. *Journal of Surgical Research* **216**, 138-142. [Crossref]

1924. Jonathon O. Russell, James Clark, Salem I. Noureldine, Angkoon Anuwong, Mai G. Al Khadem, Hoon Yub Kim, Vaninder K. Dhillon, Gianlorenzo Dionigi, Ralph P. Tufano, Jeremy D. Richmon. 2017. Transoral thyroidectomy and parathyroidectomy ? A North American series of robotic and endoscopic transoral approaches to the central neck. *Oral Oncology* **71**, 75-80. [Crossref]

1925. Tae Hyuk Kim, Young Nam Kim, Hye In Kim, So Young Park, Jun-Ho Choe, Jung-Han Kim, Jee Soo Kim, Young Lyun Oh, Soo Yeon Hahn, Jung Hee Shin, Kyunga Kim, Jong Gill Jeong, Sun Wook Kim, Jae Hoon Chung. 2017. Prognostic value of the eighth edition AJCC TNM classification for differentiated thyroid carcinoma. *Oral Oncology* **71**, 81-86. [Crossref]

1926. Yoon Joo Cho, Eun Ju Ha, Miran Han, Jin Wook Choi. 2017. US Elastography Using Carotid Artery Pulsation May Increase the Diagnostic Accuracy for Thyroid Nodules with US-Pathology Discordance. *Ultrasound in Medicine & Biology* **43**:8, 1587-1595. [Crossref]

1927. Christine M. Chan, Jonathan Young, Jeremy Prager, Sharon Travers. 2017. Pediatric Thyroid Cancer. *Advances in Pediatrics* **64**:1, 171-190. [Crossref]

1928. Lei Ye, Xiaoyi Zhou, Fengjiao Huang, Weixi Wang, Yicheng Qi, Heng Xu, Yang Shu, Liyun Shen, Xiaochun Fei, Jing Xie, Min Cao, Yulin Zhou, Wei Zhu, Shu Wang, Guang Ning, Weiqing Wang. 2017. The genetic landscape of benign thyroid nodules revealed by whole exome and transcriptome sequencing. *Nature Communications* **8**:1. . [Crossref]

1929. Robin T. Vollmer. 2017. Defining Papillary Carcinoma of the Thyroid. *American Journal of Clinical Pathology* **148**:2, 100-107. [Crossref]

1930. Min Liu, Li Chai, Qiong Luo, Maomei Ruan, Lingxiao Cheng, Zhongwei Lv, Libo Chen. 2017. 99mTc-pertechnetate-avid metastases from differentiated thyroid cancer are prone to benefit from 131I therapy. *Medicine* **96**:33, e7631. [Crossref]

1931. Sin-Di Lee, Chin Hu, Nan-Jing Peng. 2017. Incidental Thyroid Nodule Noted on Intra-arterial Hepatic MAA Scan Before 90Y-SIRT. *Clinical Nuclear Medicine* **42**:8, 641-642. [Crossref]

1932. Megan R Haymart, Nazanene H Esfandiari, Michael T Stang, Julia Ann Sosa. 2017. Controversies in the Management of Low-Risk Differentiated Thyroid Cancer. *Endocrine Reviews* **38**:4, 351-378. [Crossref]

1933. Jie-Jen Lee, Tao-Yeuan Wang, Chien-Liang Liu, Ming-Nan Chien, Ming-Jen Chen, Yi-Chiung Hsu, Ching-Hsiang Leung, Shih-Ping Cheng. 2017. Dipeptidyl Peptidase IV as a Prognostic Marker and Therapeutic Target in Papillary Thyroid Carcinoma. *The Journal of Clinical Endocrinology & Metabolism* **102**:8, 2930-2940. [Crossref]

Downloaded by Memorial Sloan Kettering from www.liebertpub.com at 08/14/19. For personal use only.

1934. Wenjing Zhao, Lei You, Xianming Hou, Shaobo Chen, Xiaoxia Ren, Ge Chen, Yupei Zhao. 2017. The Effect of Prophylactic Central Neck Dissection on Locoregional Recurrence in Papillary Thyroid Cancer After Total Thyroidectomy: A Systematic Review and Meta-Analysis. *Annals of Surgical Oncology* **24**:8, 2189-2198. [Crossref]

1935. Huy Gia Vuong, Tetsuo Kondo, Uyen N P Duong, Thong Quang Pham, Naoki Oishi, Kunio Mochizuki, Tadao Nakazawa, Lewis Hassell, Ryohei Katoh. 2017. Prognostic impact of vascular invasion in differentiated thyroid carcinoma: a systematic review and meta-analysis. *European Journal of Endocrinology* **177**:2, 207-216. [Crossref]

1936. Vincent A. Leung, Anish Kirpalani, Gevork Mnatzakanian, Errol Colak, Paraskevi A. Vlachou. 2017. Effect of a Biopsy Center on Adequacy Rates of Thyroid Nodule Fine-Needle Aspiration. *American Journal of Roentgenology* **209**:2, 358-362. [Crossref]

1937. Pierpaolo Trimboli, Camilla Virili, Francesco Romanelli, Anna Crescenzi, Luca Giovanella. 2017. Galectin-3 Performance in Histologic and Cytologic Assessment of Thyroid Nodules: A Systematic Review and Meta-Analysis. *International Journal of Molecular Sciences* **18**:8, 1756. [Crossref]

1938. Dagmara Rusinek, Ewa Chmielik, Jolanta Krajewska, Michal Jarzab, Malgorzata Oczko-Wojciechowska, Agnieszka Czarniecka, Barbara Jarzab. 2017. Current Advances in Thyroid Cancer Management. Are We Ready for the Epidemic Rise of Diagnoses?. *International Journal of Molecular Sciences* **18**:8, 1817. [Crossref]

1939. Fabiana Pani, Elisabetta Macerola, Fulvio Basolo, Francesco Boi, Mario Scartozzi, Stefano Mariotti. 2017. Aggressive differentiated thyroid cancer with multiple metastases and NRAS and TERT promoter mutations: A case report. *Oncology Letters* **14**:2, 2186-2190. [Crossref]

1940. Yuri E. Nikiforov. 2017. ROLE OF MOLECULAR MARKERS IN THYROID NODULE MANAGEMENT: THEN AND NOW. *Endocrine Practice* **23**:8, 979-988. [Crossref]

1941. Jolanta Krajewska, Tomasz Gawlik, Barbara Jarzab. 2017. Advances in small molecule therapy for treating metastatic thyroid cancer. *Expert Opinion on Pharmacotherapy* **18**:11, 1049-1060. [Crossref]

1942. Mimi Kim, Hyo Jin Park, Hye Sook Min, Hyeong Ju Kwon, Chan Kwon Jung, Seoung Wan Chae, Hyun Ju Yoo, Yoo Duk Choi, Mi Ja Lee, Jeong Ja Kwak, Dong Eun Song, Dong Hoon Kim, Hye Kyung Lee, Ji Yeon Kim, Sook Hee Hong, Jang Sihn Sohn, Hyun Seung Lee, So Yeon Park, Soon Won Hong, Mi Kyung Shin. 2017. The Use of the Bethesda System for Reporting Thyroid Cytopathology in Korea: A Nationwide Multicenter Survey by the Korean Society of Endocrine Pathologists. *Journal of Pathology and Translational Medicine* **51**:4, 410-417. [Crossref]

1943. Eleonora Molinaro, Cristina Romei, Agnese Biagini, Elena Sabini, Laura Agate, Salvatore Mazzeo, Gabriele Materazzi, Stefano Sellari-Franceschini, Alessandro Ribechini, Liborio Torregrossa, Fulvio Basolo, Paolo Vitti, Rossella Elisei. 2017. Anaplastic thyroid carcinoma: from clinicopathology to genetics and advanced therapies. *Nature Reviews Endocrinology* **13**:11, 644-660. [Crossref]

1944. Derya Cayir, Mine Araz. Radioiodine Therapy of Malignant Thyroid Diseases . [Crossref]

1945. Dmitriy G. Beltsevich, Vladimir E. Vanushko, Pavel O. Rumiantsev, Galina A. Melnichenko, Nikolay S. Kuznetsov, Aleksandr Yu. Abrosimov, Vladimir G. Polyakov, Ali M. Mudunov, Sergey O. Podvyaznikov, Ilja S. Romanov, Andrey P. Polyakov, Ilja V. Sleptsov, Roman A. Chernikov, Sergey L. Vorobyov, Valentin V. Fadeyev. 2017. 2016 Russian clinical practice guidelines for differentiated thyroid cancer diagnosis and treatment. *Endocrine Surgery* **11**:1, 6-27. [Crossref]

1946. Debora Arpaia, Serena Ippolito, Carmela Peirce, Gilda Pontieri, Bernadette Biondi. 2017. Importance of recombinant human thyrotropin as an adjuvant in the radioiodine treatment of thyroid cancer. *Expert Review of Endocrinology & Metabolism* **12**:4, 261-267. [Crossref]

1947. Marco Raffaelli, Luca Sessa, Rocco Bellantone. 2017. Concerns in patients undergoing neck dissection surgery. *Expert Review of Quality of Life in Cancer Care* **2**:4, 203-205. [Crossref]

1948. Orgiazzi Jacques. 2017. For Papillary Thyroid Cancer Discovered During Pregnancy, Delayed Thyroid Surgery with Active Surveillance Is Appropriate. *Clinical Thyroidology* **29**:7, 264-266. [Citation] [Full Text] [PDF] [PDF Plus]

1949. Biermann Martin. 2017. Can Imaging with FDG-PET Help Exclude Malignancy in Cytologically Indeterminate Thyroid Nodules?. *Clinical Thyroidology* **29**:7, 267-270. [Citation] [Full Text] [PDF] [PDF Plus]

1950. Livhits Masha J., Yeh Michael W.. 2017. Extrathyroidal Extension Predicts Decreased Survival in Thyroid Cancer Patients. *Clinical Thyroidology* **29**:7, 271-273. [Citation] [Full Text] [PDF] [PDF Plus]

1951. Cohen Oded, Tzelnick Sharon, Lahav Yonatan, Schindel Doron, Halperin Doron, Yehuda Moshe. 2017. Selection of Atypia/Follicular Lesion of Unknown Significance Patients for Surgery Versus Active Surveillance, Without Using Genetic Testing: A Single Institute Experience, Prospective Analysis, and Recommendations. *Thyroid* **27**:7, 928-935. [Abstract] [Full Text] [PDF] [PDF Plus]

Downloaded by Memorial Sloan Kettering from www.liebertpub.com at 08/14/19. For personal use only.

1952. Hong Min Ji, Na Dong Gyu, Baek Jung Hwan, Sung Jin Yong, Kim Ji-Hoon. 2017. Cytology-Ultrasonography Risk-Stratification Scoring System Based on Fine-Needle Aspiration Cytology and the Korean-Thyroid Imaging Reporting and Data System. *Thyroid* **27**:7, 953-959. [Abstract] [Full Text] [PDF] [PDF Plus]

1953. Kim Min-Hee, Huh Jin-young, Lim Dong-jun, Kang Moo-Il. 2017. Does the Risk of Metabolic Syndrome Increase in Thyroid Cancer Survivors?. *Thyroid* **27**:7, 936-943. [Abstract] [Full Text] [PDF] [PDF Plus]

1954. Kim Hosu, Kim Tae Hyuk, Choe Jun-Ho, Kim Jung-Han, Kim Jee Soo, Oh Young Lyun, Hahn Soo Yeon, Shin Jung Hee, Chi Sang ah, Jung Sin-Ho, Kim Young Nam, Kim Hye In, Kim Sun Wook, Chung Jae Hoon. 2017. Patterns of Initial Recurrence in Completely Resected Papillary Thyroid Carcinoma. *Thyroid* **27**:7, 908-914. [Abstract] [Full Text] [PDF] [PDF Plus] [Supplementary Material]

1955. Kim Mijin, Kim Won Gu, Park Suyeon, Kwon Hyemi, Jeon Min Ji, Lee Sang Min, Lee Jeong Hyun, Kim Tae Yong, Shong Young Kee, Kim Won Bae. 2017. Growth Kinetics of Macronodular Lung Metastases and Survival in Differentiated Thyroid Carcinoma. *Thyroid* **27**:7, 915-922. [Abstract] [Full Text] [PDF] [PDF Plus]

1956. Marina Vivero, Andrew A. Renshaw, Jeffrey F. Krane. 2017. Adequacy criteria for thyroid FNA evaluated by ThinPrep slides only. *Cancer Cytopathology* **125**:7, 534-543. [Crossref]

1957. Pedro Weslley Rosario, Maria Regina Calsolari. 2017. Importance of cytological subclassification of thyroid nodules with Bethesda category III cytology (AUS/FLUS) into architectural atypia only and nuclear atypia: A prospective study. *Diagnostic Cytopathology* **45**:7, 604-607. [Crossref]

1958. Nishant Agrawal, Maria R. Evasovich, Emad Kandil, Salem I. Noureldine, Erin A. Felger, Ralph P. Tufano, Dennis H. Kraus, Lisa A. Orloff, Raymon Grogan, Peter Angelos, Brendan C. Stack, Bryan McIver, Gregory W. Randolph. 2017. Indications and extent of central neck dissection for papillary thyroid cancer: An American Head and Neck Society Consensus Statement. *Head & Neck* **39**:7, 1269-1279. [Crossref]

1959. Anastasios Maniakas, Apostolos Christopoulos, Eric Bissada, Louis Guertin, Marie-Jo Olivier, Jacques Malaise, Tareck Ayad. 2017. Perioperative practices in thyroid surgery: An international survey. *Head & Neck* **39**:7, 1296-1305. [Crossref]

1960. C. M. Laine, K. Landin-Wilhelmsen. 2017. Case report: fast reversal of severe osteoporosis after correction of excessive levothyroxine treatment and long-term follow-up. *Osteoporosis International* **28**:7, 2247-2250. [Crossref]

1961. Sueyoshi Moritani. 2017. Window Resection for Intraluminal Cricotracheal Invasion by Papillary Thyroid Carcinoma. *World Journal of Surgery* **41**:7, 1812-1819. [Crossref]

1962. Nicola M. Hughes, Andreea Nae, Josephine Barry, Brendan Fitzgerald, Linda Feeley, Patrick Sheahan. 2017. Sonographic differences between conventional and follicular variant papillary thyroid carcinoma. *European Archives of Oto-Rhino-Laryngology* **274**:7, 2907-2913. [Crossref]

1963. Qin Yu, Tao Jiang, Aiyun Zhou, Lili Zhang, Cheng Zhang, Pan Xu. 2017. Computer-aided diagnosis of malignant or benign thyroid nodes based on ultrasound images. *European Archives of Oto-Rhino-Laryngology* **274**:7, 2891-2897. [Crossref]

1964. D. Führer, W. A. Scherbaum. 2017. Neues zur Endokrinologe. *Der Diabetologe* **13**:5, 342-354. [Crossref]

1965. Hye Jin Baek, Dong Wook Kim, Song Lee, Inseon Ryoo, Chang Yoon Lee, Yoon Jung Choi, Jin Yong Sung. 2017. Postoperative ultrasonography surveillance in patients with follicular thyroid carcinoma: a multicenter study. *La radiologia medica* **122**:7, 530-537. [Crossref]

1966. Martina Rossi, Sabrina Lupo, Roberta Rossi, Paola Franceschetti, Giorgio Trasforini, Stefania Bruni, Federico Tagliati, Mattia Buratto, Giovanni Lanza, Luca Damiani, Ettore degli Uberti, Maria Chiara Zatelli. 2017. Proposal for a novel management of indeterminate thyroid nodules on the basis of cytopathological subclasses. *Endocrine* **57**:1, 98-107. [Crossref]

1967. Yoon Young Cho, Hye Jeong Kim, Hye Won Jang, Tae Hyuk Kim, Chang-Seok Ki, Sun Wook Kim, Jae Hoon Chung. 2017. The relationship of 19 functional polymorphisms in iodothyronine deiodinase and psychological well-being in hypothyroid patients. *Endocrine* **57**:1, 115-124. [Crossref]

1968. In Hye Chae, Eun-Kyung Kim, Hee Jung Moon, Jung Hyun Yoon, Vivian Y. Park, Jin Young Kwak. 2017. Ultrasound-guided fine needle aspiration versus core needle biopsy: comparison of post-biopsy hematoma rates and risk factors. *Endocrine* **57**:1, 108-114. [Crossref]

1969. Slimane Zerdoud, Anne-Laure Giraudet, Sophie Leboulleux, Laurence Leenhardt, Stéphane Bardet, Jérôme Clerc, Marie-Elisabeth Toubert, Abir Al Ghuzlan, Pierre-Jean Lamy, Claire Bournaud, Isabelle Keller, Frédéric Sebag, Renaud Garrel, Eric Mirallié, Lionel Groussin, Elif Hindié, David Taïeb. 2017. Radioactive iodine therapy, molecular imaging and serum biomarkers for differentiated thyroid cancer: 2017 guidelines of the French Societies of Nuclear Medicine, Endocrinology, Pathology, Biology, Endocrine Surgery and Head and Neck Surgery. *Annales d'Endocrinologie* **78**:3, 162-175. [Crossref]

1970. Kamau O. Peters, Mykola Tronko, Maureen Hatch, Valeriy Oliynyk, Galyna Terekhova, Ruth M. Pfeiffer, Victor M. Shpak, Robert J. McConnell, Vladimir Drozdovitch, Mark P. Little, Lydia B. Zablotska, Kiyohiko Mabuchi, Alina V. Brenner, Elizabeth

Downloaded by Memorial Sloan Kettering from www.liebertpub.com at 08/14/19. For personal use only.

K. Cahoon. 2017. Factors associated with serum thyroglobulin in a Ukrainian cohort exposed to iodine-131 from the accident at the Chernobyl Nuclear Plant. *Environmental Research* **156**, 801-809. [Crossref]

1971. Jinbeom Cho, Yohan Park, Jongmin Baek, Kiyoung Sung. 2017. Single-incision endoscopic thyroidectomy for papillary thyroid cancer: A pilot study. *International Journal of Surgery* **43**, 1-6. [Crossref]

1972. Colleen M. Kiernan, Carmen C. Sol?rzano. 2017. Bethesda Category III, IV, and V Thyroid Nodules: Can Nodule Size Help Predict Malignancy?. *Journal of the American College of Surgeons* **225**:1, 77-82. [Crossref]

1973. Michael G. White, Megan K. Applewhite, Edwin L. Kaplan, Peter Angelos, Dezheng Huo, Raymon H. Grogan. 2017. A Tale of Two Cancers: Traveling to Treat Pancreatic and Thyroid Cancer. *Journal of the American College of Surgeons* **225**:1, 125-136.e6. [Crossref]

1974. Alfredo Ernesto Romero, Rafael Parra Medina, Sandra Isabel Chinchilla Olaya, Amelia de los Reyes Victoria, Augusto Llamas Olier. 2017. Diferencias y controversias entre el reporte de patología y la interpretación clínica en patología tiroidea. II PARTE: Aspectos patológicos y métodos diagnósticos con impacto terapéutico. *Revista Colombiana de Cancerología* **21**:3, 166-172. [Crossref]

1975. David Martinez-Marin, Hari Sreedhar, Vishal K. Varma, Catarina Eloy, Manuel Sobrinho-Simões, André Kajdacsy-Balla, Michael J. Walsh. 2017. Accounting for tissue heterogeneity in infrared spectroscopic imaging for accurate diagnosis of thyroid carcinoma subtypes. *Vibrational Spectroscopy* **91**, 77-82. [Crossref]

1976. Li Yi, Wu Qiong, Wang Yan, Fan Youben, Hu Bing. 2017. Correlation between Ultrasound Elastography and Histologic Characteristics of Papillary Thyroid Carcinoma. *Scientific Reports* **7**:1. . [Crossref]

1977. Hui Huang, Shaoyan Liu, Zhengang Xu, Song Ni, Zongmin Zhang, Xiaolei Wang. 2017. Long-term outcome of thyroid lobectomy for unilateral multifocal papillary carcinoma. *Medicine* **96**:27, e7461. [Crossref]

1978. Jeonghoon Ha, Min Hee Kim, Kwanhoon Jo, Yejee Lim, Ja Seong Bae, Sohee Lee, Moo Il Kang, Bong Yun Cha, Dong Jun Lim. 2017. Recombinant human TSH stimulated thyroglobulin levels at remnant ablation predict structural incomplete response to treatment in patients with differentiated thyroid cancer. *Medicine* **96**:29, e7512. [Crossref]

1979. Trevor E. Angell. 2017. RAS-positive thyroid nodules. *Current Opinion in Endocrinology & Diabetes and Obesity* 1. [Crossref]

1980. Abir A. Ghuzlan, Helton E. Ramos, Martin Schlumberger. 2017. Noninvasive follicular thyroid neoplasm with papillary-like nuclear features. *Current Opinion in Endocrinology & Diabetes and Obesity* 1. [Crossref]

1981. Benjamin R. Roman, Luc G. Morris, Louise Davies. 2017. The thyroid cancer epidemic, 2017 perspective. *Current Opinion in Endocrinology & Diabetes and Obesity* 1. [Crossref]

1982. Anja T. Golubi?, Eva Pasini Nemir, Marijan ?uvi?, Andrea Mutvar, Sanja Kusa?i? Kuna, Marija Despot, Tatjana Samard?i?, Dra?en Hui?. 2017. The value of 18F-DOPA PET/CT in patients with medullary thyroid carcinoma and increased calcitonin values. *Nuclear Medicine Communications* **38**:7, 636-641. [Crossref]

1983. Eun Kyoung Choi, Ari Chong, Jung-Min Ha, Chan Kwon Jung, Joo Hyun O, Sung Hoon Kim. 2017. Clinicopathological characteristics including BRAF V600E mutation status and PET/CT findings in papillary thyroid carcinoma. *Clinical Endocrinology* **87**:1, 73-79. [Crossref]

1984. Min Joo Kim, Myung-Chul Lee, Guk Haeng Lee, Hoon Sung Choi, Sun Wook Cho, Su-jin Kim, Kyu Eun Lee, Young Joo Park, Do Joon Park. 2017. Extent of surgery did not affect recurrence during 7-years follow-up in papillary thyroid cancer sized 1-4?cm: Preliminary results. *Clinical Endocrinology* **87**:1, 80-86. [Crossref]

1985. Elizabeth K. Cahoon, Eldar A. Nadyrov, Olga N. Polyanskaya, Vasilina V. Yauseyenka, Ilya V. Veyalkin, Tamara I. Yeudachkova, Tamara I. Maskvicheva, Victor F. Minenko, Wayne Liu, Vladimir Drozdovitch, Kiyohiko Mabuchi, Mark P. Little, Lydia B. Zablotska, Robert J. McConnell, Maureen Hatch, Kamau O. Peters, Alexander V. Rozhko, Alina V. Brenner. 2017. Risk of Thyroid Nodules in Residents of Belarus Exposed to Chernobyl Fallout as Children and Adolescents. *The Journal of Clinical Endocrinology & Metabolism* **102**:7, 2207-2217. [Crossref]

1986. Ewa Ruel, Samantha Thomas, Jennifer M. Perkins, Sanziana A. Roman, Julie A. Sosa. 2017. The Impact of Pathologically Positive Lymph Nodes in the Clinically Negative Neck: An Analysis of 39,301 Patients with Papillary Thyroid Cancer. *Annals of Surgical Oncology* **24**:7, 1935-1942. [Crossref]

1987. Yi Ho Lee, Yu Mi Lee, Tae Yon Sung, Jong Ho Yoon, Dong Eun Song, Tae Yong Kim, Jung Hwan Baek, Jin Suk Ryu, Ki Wook Chung, Suck Joon Hong. 2017. Is Male Gender a Prognostic Factor for Papillary Thyroid Microcarcinoma?. *Annals of Surgical Oncology* **24**:7, 1958-1964. [Crossref]

1988. Ok Kyu Song, Ja Seung Koo, Jin Young Kwak, Hee Jung Moon, Jung Hyun Yoon, Eun-Kyung Kim. 2017. Metastatic renal cell carcinoma in the thyroid gland: ultrasonographic features and the diagnostic role of core needle biopsy. *Ultrasonography* **36**:3, 252-259. [Crossref]

Downloaded by Memorial Sloan Kettering from www.liebertpub.com at 08/14/19. For personal use only.

1989. Min Ji Jeon, Won Gu Kim, Hyemi Kwon, Mijin Kim, Suyeon Park, Hye-Seon Oh, Minkyu Han, Tae-Yon Sung, Ki-Wook Chung, Suck Joon Hong, Tae Yong Kim, Young Kee Shong, Won Bae Kim. 2017. Clinical outcomes after delayed thyroid surgery in patients with papillary thyroid microcarcinoma. *European Journal of Endocrinology* **177**:1, 25-31. [Crossref]

1990. Massimo Giusti, Barbara Massa, Margherita Balestra, Paola Calamaro, Stefano Gay, Simone Schiaffino, Giovanni Turtulici, Simonetta Zupo, Eleonora Monti, Gianluca Ansaldo. 2017. Retrospective cytological evaluation of indeterminate thyroid nodules according to the British Thyroid Association 2014 classification and comparison of clinical evaluation and outcomes. *Journal of Zhejiang University-SCIENCE B* **18**:7, 555-566. [Crossref]

1991. C.H. Suh, J.H. Baek, C. Park, Y.J. Choi, J.H. Lee. 2017. The Role of Core Needle Biopsy for Thyroid Nodules with Initially Indeterminate Results on Previous Fine-Needle Aspiration: A Systematic Review and Meta-Analysis. *American Journal of Neuroradiology* **38**:7, 1421-1426. [Crossref]

1992. Hye Jin Baek, Dong Wook Kim, Chang Yoon Lee, Jung Yin Huh, Jin Yong Sung, Yoon Jung Choi. 2017. ANALYSIS OF POSTOPERATIVE ULTRASONOGRAPHY SURVEILLANCE AFTER HEMITHYROIDECTOMY IN PATIENTS WITH PAPILLARY THYROID MICROCARCINOMA: A MULTICENTER STUDY. *Endocrine Practice* **23**:7, 794-802. [Crossref]

1993. Maria Papaleontiou, Paul G. Gauger, Megan R. Haymart. 2017. REFERRAL OF OLDER THYROID CANCER PATIENTS TO A HIGH-VOLUME SURGEON: RESULTS OF A MULTIDISCIPLINARY PHYSICIAN SURVEY. *Endocrine Practice* **23**:7, 808-815. [Crossref]

1994. Grant Harrison, Julie Ann Sosa, Xiaoyin Jiang. 2017. Evaluation of the Afirma Gene Expression Classifier in Repeat Indeterminate Thyroid Nodules. *Archives of Pathology & Laboratory Medicine* **141**:7, 985-989. [Crossref]

1995. Jing Kong, Jian-chu Li, Hong-yan Wang, Ya-hong Wang, Rui-na Zhao, Ying Zhang, Jin Jin. 2017. Role of Superb Micro-Vascular Imaging in the Preoperative Evaluation of Thyroid Nodules: Comparison With Power Doppler Flow Imaging. *Journal of Ultrasound in Medicine* **36**:7, 1329-1337. [Crossref]

1996. Wynne Yuru Chua, Jill E. Langer, Lisa P. Jones. 2017. Surveillance Neck Sonography After Thyroidectomy for Papillary Thyroid Carcinoma: Pitfalls in the Diagnosis of Locally Recurrent and Metastatic Disease. *Journal of Ultrasound in Medicine* **36**:7, 1511-1530. [Crossref]

1997. Rasha Hamdy Hamed. 2017. Is postoperative radioactive iodine associated with a survival advantage among.... *Forum of Clinical Oncology* **8**:1, 23-27. [Crossref]

1998. Artur Kowalik, Aldona Kowalska, Agnieszka Walczyk, Renata Chodurska, Janusz Kopczy?ski, Magdalena Chrapek, El?bieta Wypi?rkiewicz, Ma?gorzata Ch?opek, Liliana Pi?ciak, Danuta G?sior-Perczak, Iwona Pa?yga, Krzysztof Gruszczy?ski, Ewelina Nowak, Stanis?aw G??d?. 2017. Evaluation of molecular diagnostic approaches for the detection of BRAF p.V600E mutations in papillary thyroid cancer: Clinical implications. *PLOS ONE* **12**:6, e0179691. [Crossref]

1999. Lawrence A. Shirley, Natalie B. Jones, John E. Phay. 2017. The Role of Central Neck Lymph Node Dissection in the Management of Papillary Thyroid Cancer. *Frontiers in Oncology* **7**. . [Crossref]

2000. Sabrina Jegerlehner, Jean-Luc Bulliard, Drahomir Aujesky, Nicolas Rodondi, Simon Germann, Isabelle Konzelmann, Arnaud Chiolero. 2017. Overdiagnosis and overtreatment of thyroid cancer: A population-based temporal trend study. *PLOS ONE* **12**:6, e0179387. [Crossref]

2001. Zora Hammoudeh, Dragomira Nikolova, Lubomir Balabanski, Samuil Ivanov, Radoslava Vazharova, Sabine Weidner, Maxim Malinov, Draga Toncheva. 2017. Screening of pharmacogenetic variants associated with drug sensitivity in patients with papillary thyroid carcinoma using next generation sequencing. *Biotechnology & Biotechnological Equipment* **7**, 1-5. [Crossref]

2002. Brian H. H. Lang, Yu-Cho Woo, Keith Wan-Hang Chiu. 2017. Vocal cord paresis following single-session high intensity focused ablation (HIFU) treatment of benign thyroid nodules: incidence and risk factors. *International Journal of Hyperthermia* **32**, 1-7. [Crossref]

2003. Maureen D. Moore, Suraj Panjwani, Katherine D. Gray, Brendan M. Finnerty, Rasa Zarnegar, Thomas J. Fahey. 2017. The role of molecular diagnostic testing in the management of thyroid nodules. *Expert Review of Molecular Diagnostics* **17**:6, 567-576. [Crossref]

2004. Tze Ling Loh, Sergios Latis, Rohana Bibi Ali, Hemi Patel. 2017. Insular carcinoma arising on a background of follicular carcinoma, thyrolipomatosis and amyloid goitre. *BMJ Case Reports* **13**, bcr-2017-219747. [Crossref]

2005. Hershman Jerome M.. 2017. Thyroid Cancer Incidence and Mortality Are Increasing. *Clinical Thyroidology* **29**:6, 221-223. [Citation] [Full Text] [PDF] [PDF Plus]

2006. Fish Stephanie A.. 2017. High-Intensity Focused Ultrasound Is Useful in the Treatment of Symptomatic Benign Thyroid Nodules. *Clinical Thyroidology* **29**:6, 229-231. [Citation] [Full Text] [PDF] [PDF Plus]

Downloaded by Memorial Sloan Kettering from www.liebertpub.com at 08/14/19. For personal use only.

2007. Biermann Martin, Haugland Hans Kristian. 2017. Does Core Needle Biopsy Have A Role in the Evaluation of Thyroid Nodules with Indeterminate Cytology?. *Clinical Thyroidology* **29**:6, 232-234. [Citation] [Full Text] [PDF] [PDF Plus]

2008. Livhits Masha J., Yeh Michael W.. 2017. Delaying Surgery by More Than 1 Year for Selected Patients with Papillary Thyroid Microcarcinoma Does Not Compromise Outcomes. *Clinical Thyroidology* **29**:6, 241-243. [Citation] [Full Text] [PDF] [PDF Plus]

2009. Ma Chao, Feng Fang, Wang Shaoyan, Fu Hongliang, Wu Shuqi, Ye Zhiyi, Chen Suyun, Wang Hui. 2017. Chinese Data of Efficacy of Low- and High-Dose Iodine-131 for the Ablation of Thyroid Remnant. *Thyroid* **27**:6, 832-837. [Abstract] [Full Text] [PDF] [PDF Plus]

2010. Tavarelli Martina, Sarfati Julie, Chereau Nathalie, Tissier Frederique, Golmard Jean Louis, Ghander Cécile, Lussey-Lepoutre Charlotte, Trésallet Christophe, Menegaux Fabrice, Leenhardt Laurence, Buffet Camille. 2017. Heterogeneous Prognoses for pT3 Papillary Thyroid Carcinomas and Impact of Delayed Risk Stratification. *Thyroid* **27**:6, 778-786. [Abstract] [Full Text] [PDF] [PDF Plus]

2011. Zanella André, Scheffel Rafael Selbach, Pasa Marina Weber, Dora José Miguel, Maia Ana Luiza. 2017. Role of Postoperative Stimulated Thyroglobulin as Prognostic Factor for Differentiated Thyroid Cancer in Children and Adolescents. *Thyroid* **27**:6, 787-792. [Abstract] [Full Text] [PDF] [PDF Plus]

2012. Oh Hye-Seon, Kim Won Gu, Park Suyeon, Kim Mijin, Kwon Hyemi, Jeon Min Ji, Lee Jeong Hyun, Baek Jung Hwan, Song Dong Eun, Kim Tae Yong, Shong Young Kee, Kim Won Bae. 2017. Serial Neck Ultrasonographic Evaluation of Changes in Papillary Thyroid Carcinoma During Pregnancy. *Thyroid* **27**:6, 773-777. [Abstract] [Full Text] [PDF] [PDF Plus] [Supplementary Material]

2013. Tuttle R. Michael, Haugen Bryan, Perrier Nancy D.. 2017. Updated American Joint Committee on Cancer/Tumor-Node-Metastasis Staging System for Differentiated and Anaplastic Thyroid Cancer (Eighth Edition): What Changed and Why?. *Thyroid* **27**:6, 751-756. [Citation] [Full Text] [PDF] [PDF Plus]

2014. Ayse M. Onenerk, Marc P. Pusztaszeri, Sule Canberk, William C. Faquin. 2017. Triage of the indeterminate thyroid aspirate: What are the options for the practicing cytopathologist?. *Cancer Cytopathology* **125**:S6, 477-485. [Crossref]

2015. Arnoldo Piccardo, Matteo Puntoni, Gianluca Bottoni, Giorgio Treglia, Luca Foppiani, Mattia Bertoli, Ugo Catrambone, Anselmo Arlandini, Bassam Dib, Vania Altrinetti, Michela Massollo, Irene Bossert, Manlio Cabria, Francesco Bertagna, Luca Giovanella. 2017. Differentiated Thyroid Cancer lymph-node relapse. Role of adjuvant radioactive iodine therapy after lymphadenectomy. *European Journal of Nuclear Medicine and Molecular Imaging* **44**:6, 926-934. [Crossref]

2016. Sandip Basu, Ashwini Kalshetty. 2017. Monitoring metastatic lesions in TENIS, initiating multi-targeted tyrosine kinase inhibitors and follow-up: should the newer FDG PET-CT quantitative indices be the defining objective parameter in clinical trials?. *European Journal of Nuclear Medicine and Molecular Imaging* **44**:6, 1092-1094. [Crossref]

2017. Jérôme Clerc, Frederik A. Verburg, Anca M. Avram, Luca Giovanella, Elif Hindié, David Taïeb. 2017. Radioiodine treatment after surgery for differentiated thyroid cancer: a reasonable option. *European Journal of Nuclear Medicine and Molecular Imaging* **44**:6, 918-925. [Crossref]

2018. Eleonora Horvath, Claudio F. Silva, Sergio Majlis, Ignacio Rodriguez, Velimir Skoknic, Alex Castro, Hugo Rojas, Juan-Pablo Niedmann, Arturo Madrid, Felipe Capdeville, Carolina Whittle, Ricardo Rossi, Miguel Domínguez, Hernán Tala. 2017. Prospective validation of the ultrasound based TIRADS (Thyroid Imaging Reporting And Data System) classification: results in surgically resected thyroid nodules. *European Radiology* **27**:6, 2619-2628. [Crossref]

2019. Ling Chen, Youzhi Zhu, Ke Zheng, Huihao Zhang, Hongkun Guo, Li Zhang, Kunlin Wu, Lingjun Kong, Weihong Ruan, Jianying Hu, Xin Zhang, Xiangjin Chen. 2017. The presence of cancerous nodules in lymph nodes is a novel indicator of distant metastasis and poor survival in patients with papillary thyroid carcinoma. *Journal of Cancer Research and Clinical Oncology* **143**:6, 1035-1042. [Crossref]

2020. Matthias Schmidt. 2017. So erkennen und behandeln Sie die Hyperthyreose. *CME* **14**:6, 9-23. [Crossref]

2021. Valentina Zilioli, Alessia Peli, Maria Beatrice Panarotto, Giancarlo Magri, Ahmed Alkraisheh, Christiane Wiefels, Carlo Rodella, Raffaele Giubbini. 2017. Differentiated thyroid carcinoma: Incremental diagnostic value of 131I SPECT/CT over planar whole body scan after radioiodine therapy. *Endocrine* **56**:3, 551-559. [Crossref]

2022. Fanny Piotrkowski-Viale, Adriana Reyes, Alicia Dios, Fabian Pitoia, Alicia Lowenstein, Patricia Glikman. 2017. Effects of sample storage and diluents in the reliability of thyroglobulin measurement in the washout of fine needle aspirates. *Endocrine* **56**:3, 504-508. [Crossref]

2023. Kristine S. Wong, Kyle C. Strickland, Trevor E. Angell, Matthew A. Nehs, Erik K. Alexander, Edmund S. Cibas, Jeffrey F. Krane, Brooke E. Howitt, Justine A. Barletta. 2017. The Flip Side of NIFTP: an Increase in Rates of Unfavorable Histologic Parameters in the Remainder of Papillary Thyroid Carcinomas. *Endocrine Pathology* **28**:2, 171-176. [Crossref]

Downloaded by Memorial Sloan Kettering from www.liebertpub.com at 08/14/19. For personal use only.

2024. Lester D. R. Thompson, Hannah B. Herrera, Sean K. Lau. 2017. Thyroglossal Duct Cyst Carcinomas: A Clinicopathologic Series of 22 Cases with Staging Recommendations. *Head and Neck Pathology* **11**:2, 175-185. [Crossref]

2025. Gianlorenzo Dionigi, Alessandro Bacuzzi, Matteo Lavazza, Davide Inversini, Luigi Boni, Stefano Rausei, Hoon Yub Kim, Angkoon Anuwong. 2017. Transoral endoscopic thyroidectomy: preliminary experience in Italy. *Updates in Surgery* **69**:2, 225-234. [Crossref]

2026. Pietro Giorgio Cal?, Celestino Pio Lombardi, Francesco Podda, Luca Sessa, Luigi Santini, Giovanni Conzo. 2017. Role of prophylactic central neck dissection in clinically node-negative differentiated thyroid cancer: assessment of the risk of regional recurrence. *Updates in Surgery* **69**:2, 241-248. [Crossref]

2027. Paolo Miccoli, Sohail Bakkar. 2017. Surgical management of papillary thyroid carcinoma: an overview. *Updates in Surgery* **69**:2, 145-150. [Crossref]

2028. Carmela De Crea, Marco Raffaelli, Luca Sessa, Celestino Pio Lombardi, Rocco Bellantone. 2017. Surgical approach to level VI in papillary thyroid carcinoma: an overview. *Updates in Surgery* **69**:2, 205-209. [Crossref]

2029. J. H. An, H. Y. Kim, S. G. Kim, H. Dralle, G. W. Randolph, E. Piantanida, M. L. Tanda, G. Dionigi. 2017. Endpoints for screening thyroid cancer in the Republic of Korea: thyroid specialists' perspectives. *Journal of Endocrinological Investigation* **40**:6, 683-685. [Crossref]

2030. Furio Pacini. 2017. Endopoints for screening thyroid cancer in the Republic of Korea: thyroid specialists' perspectives. *Journal of Endocrinological Investigation* **40**:6, 689-690. [Crossref]

2031. Maria Grazia Castagna. 2017. Il follow-up del carcinoma differenziato della tiroide secondo le linee guida ATA 2016. *L'Endocrinologo* **18**:S1, 48-50. [Crossref]

2032. Rossella Elisei, Eleonora Molinaro, Francesco Trimarchi. 2017. C'è ancora indicazione alla terapia radioablativa con 131-I nel carcinoma tiroideo differenziato a basso rischio?. *L'Endocrinologo* **18**:S1, 51-53. [Crossref]

2033. Jena D French, Keith Bible, Christine Spitzweg, Bryan R Haugen, Mabel Ryder. 2017. Leveraging the immune system to treat advanced thyroid cancers. *The Lancet Diabetes & Endocrinology* **5**:6, 469-481. [Crossref]

2034. Mohammad Hossein Khosravi. 2017. Thyroglobulin antibodies may serve as predictive marker for papillary thyroid carcinoma in indeterminate cytology: Acceptable or not?. *The American Journal of Surgery* **213**:6, 1189-1190. [Crossref]

2035. C. Resteghini, S. Cavalieri, D. Galbiati, R. Granata, S. Alfieri, C. Bergamini, P. Bossi, L. Licitra, L.D. Locati. 2017. Management of tyrosine kinase inhibitors (TKI) side effects in differentiated and medullary thyroid cancer patients. *Best Practice & Research Clinical Endocrinology & Metabolism* **31**:3, 349-361. [Crossref]

2036. R. Michael Tuttle, Marcia S. Brose, Enrique Grande, Sun Wook Kim, Makoto Tahara, Mona M. Sabra. 2017. Novel concepts for initiating multitargeted kinase inhibitors in radioactive iodine refractory differentiated thyroid cancer. *Best Practice & Research Clinical Endocrinology & Metabolism* **31**:3, 295-305. [Crossref]

2037. Furio Pacini. 2017. Which patient with thyroid cancer deserves systemic therapy and when?. *Best Practice & Research Clinical Endocrinology & Metabolism* **31**:3, 291-294. [Crossref]

2038. Jorge Rojo Álvaro, Begoña Bermejo Fraile, Edelmiro Menéndez Torre, Eva Ardanaz, Marcela Guevara, Emma Anda Apiñániz. 2017. Increased incidence of thyroid cancer in Navarra (Spain). Evolution and clinical characteristics, 1986–2010. *Endocrinología, Diabetes y Nutrición (English ed.)* **64**:6, 303-309. [Crossref]

2039. Juan C. Galofré. 2017. Thyroid cancer incidence: The discovery of the hidden iceberg. *Endocrinología, Diabetes y Nutrición (English ed.)* **64**:6, 285-287. [Crossref]

2040. Jorge Rojo Álvaro, Begoña Bermejo Fraile, Edelmiro Menéndez Torre, Eva Ardanaz, Marcela Guevara, Emma Anda Apiñániz. 2017. Aumento de la incidencia de cáncer de tiroides en Navarra. Evolución y características clínicas, 1986-2010. *Endocrinología, Diabetes y Nutrición* **64**:6, 303-309. [Crossref]

2041. Juan C. Galofré. 2017. Incidencia de cáncer de tiroides: el descubrimiento del iceberg oculto. *Endocrinología, Diabetes y Nutrición* **64**:6, 285-287. [Crossref]

2042. Óscar González, Carles Zafon, Enric Caubet, Amparo García-Burillo, Xavier Serres, José Manuel Fort, Jordi Mesa, Joan Castell, Isabel Roca, Santiago Ramón y Cajal, Carmela Iglesias. 2017. Biopsia selectiva del ganglio centinela en el carcinoma papilar de tiroides en pacientes sin evidencia preoperatoria de metástasis ganglionar. *Endocrinología, Diabetes y Nutrición* . [Crossref]

2043. Michael C. Sullivan, Paul H. Graham, Erik K. Alexander, Daniel T. Ruan, Matthew A. Nehs, Atul A. Gawande, Francis D. Moore, Brooke E. Howitt, Kyle C. Strickland, Jeffrey F. Krane, Justine A. Barletta, Nancy L. Cho. 2017. Prevalence of Contralateral Tumors in Patients with Follicular Variant of Papillary Thyroid Cancer. *Journal of the American College of Surgeons* **224**:6, 1021-1027. [Crossref]

2044. Jack M. Monchik. 2017. Invited Commentary. *Journal of the American College of Surgeons* **224**:6, 1027-1028. [Crossref]

Downloaded by Memorial Sloan Kettering from www.liebertpub.com at 08/14/19. For personal use only.

2045. Kristen L. Partyka, Howard H. Wu. 2017. Fine-needle aspirates of thyroid microcarcinoma. *Journal of the American Society of Cytopathology* . [Crossref]

2046. Valentina Maggisano, Marilena Celano, Giovanni Enrico Lombardo, Saverio Massimo Lepore, Marialuisa Sponziello, Francesca Rosignolo, Antonella Verrienti, Federica Baldan, Efisio Puxeddu, Cosimo Durante, Sebastiano Filetti, Giuseppe Damante, Diego Russo, Stefania Bulotta. 2017. Silencing of hTERT blocks growth and migration of anaplastic thyroid cancer cells. *Molecular and Cellular Endocrinology* **448**, 34-40. [Crossref]

2047. Leire P?rez Garc?a, Mar?a ?ngeles Ant?n Miguel, Clara Rosario Fuentes G?mez. 2017. Medullary thyroid carcinoma in a patient with Birt-Hogg-Dube syndrome. *Medicina Cl?nica (English Edition)* **148**:11, 528-529. [Crossref]

2048. Leire Pérez García, María Ángeles Antón Miguel, Clara Rosario Fuentes Gómez. 2017. Carcinoma medular de tiroides en un paciente con síndrome de Birt-Hogg-Dubé. *Medicina Clínica* **148**:11, 528-529. [Crossref]

2049. Ming-Nan Chien, Po-Sheng Yang, Jie-Jen Lee, Tao-Yeuan Wang, Yi-Chiung Hsu, Shih-Ping Cheng. 2017. Recurrence-associated genes in papillary thyroid cancer: An analysis of data from The Cancer Genome Atlas. *Surgery* **161**:6, 1642-1650. [Crossref]

2050. Uiju Cho, Ozgur Mete, Min-Hee Kim, Ja Seong Bae, Chan Kwon Jung. 2017. Molecular correlates and rate of lymph node metastasis of non-invasive follicular thyroid neoplasm with papillary-like nuclear features and invasive follicular variant papillary thyroid carcinoma: the impact of rigid criteria to distinguish non-invasive follicular thyroid neoplasm with papillary-like nuclear features. *Modern Pathology* **30**:6, 810-825. [Crossref]

2051. Genpeng Li, Jianyong Lei, Qian Peng, Ke Jiang, Wenjie Chen, Wanjun Zhao, Zhihui Li, Rixiang Gong, Tao Wei, Jingqiang Zhu. 2017. Lymph node metastasis characteristics of papillary thyroid carcinoma located in the isthmus. *Medicine* **96**:24, e7143. [Crossref]

2052. Arun Upadhyaya, Zhaowei Meng, Peng Wang, Guizhi Zhang, Qiang Jia, Jian Tan, Xue Li, Tianpeng Hu, Na Liu, Pingping Zhou, Sen Wang, Xiaoxia Liu, Huiying Wang, Chunmei Zhang, Fengxiao Zhao, Ziyu Yan. 2017. Effects of first radioiodine ablation on functions of salivary glands in patients with differentiated thyroid cancer. *Medicine* **96**:25, e7164. [Crossref]

2053. Carla Colombo, Marina Muzza, Maria Carla Proverbio, Giulia Ercoli, Michela Perrino, Valentina Cirello, Leonardo Vicentini, Stefano Ferrero, Laura Fugazzola. 2017. Segregation and expression analyses of hyaluronan-binding protein 2 (HABP2): insights from a large series of familial non-medullary thyroid cancers and literature review. *Clinical Endocrinology* **86**:6, 837-844. [Crossref]

2054. Min Ji Jeon, Mi Sun Chung, Hyemi Kwon, Mijin Kim, Suyeon Park, Jung Hwan Baek, Dong Eun Song, Tae-Yon Sung, Suck Joon Hong, Tae Yong Kim, Won Bae Kim, Young Kee Shong, Jeong Hyun Lee, Won Gu Kim. 2017. Features of papillary thyroid microcarcinoma associated with lateral cervical lymph node metastasis. *Clinical Endocrinology* **86**:6, 845-851. [Crossref]

2055. Gila Lithwick-Yanai, Nir Dromi, Alexander Shtabsky, Sara Morgenstern, Yulia Strenov, Meora Feinmesser, Vladimir Kravtsov, Marino E Leon, Marián Hajdúch, Syed Z Ali, Christopher J VandenBussche, Xinmin Zhang, Leonor Leider-Trejo, Asia Zubkov, Sergey Vorobyov, Michal Kushnir, Yaron Goren, Sarit Tabak, Etti Kadosh, Hila Benjamin, Temima Schnitzer-Perlman, Hagai Marmor, Maria Motin, Danit Lebanony, Sharon Kredo-Russo, Heather Mitchell, Melissa Noller, Alexis Smith, Olivia Dattner, Karin Ashkenazi, Mats Sanden, Kenneth A Berlin, Dganit Bar, Eti Meiri. 2017. Multicentre validation of a microRNA-based assay for diagnosing indeterminate thyroid nodules utilising fine needle aspirate smears. *Journal of Clinical Pathology* **70**:6, 500-507. [Crossref]

2056. Cheng Zhao, Wenbin Jiang, Yuxiu Gao, Weidong Niu, Xiaojuan Zhang, Lei Xin. 2017. Risk factors for lymph node metastasis (LNM) in patients with papillary thyroid microcarcinoma (PTMC): role of preoperative ultrasound. *Journal of International Medical Research* **45**:3, 1221-1230. [Crossref]

2057. Rudolf Hoermann, John E. M. Midgley, Johannes W. Dietrich, Rolf Larisch. 2017. Dual control of pituitary thyroid stimulating hormone secretion by thyroxine and triiodothyronine in athyreotic patients. *Therapeutic Advances in Endocrinology and Metabolism* **8**:6, 83-95. [Crossref]

2058. Miguel Melo, Adriana Gaspar da Rocha, Rui Batista, João Vinagre, Maria João Martins, Gracinda Costa, Cristina Ribeiro, Francisco Carrilho, Valeriano Leite, Cláudia Lobo, José Manuel Cameselle-Teijeiro, Bruno Cavadas, Luísa Pereira, Manuel Sobrinho-Simões, Paula Soares. 2017. TERT, BRAF, and NRAS in Primary Thyroid Cancer and Metastatic Disease. *The Journal of Clinical Endocrinology & Metabolism* **102**:6, 1898-1907. [Crossref]

2059. Luca Giovanella, Chiara Cosma, Mario Plebani. 2017. Letter to the Editor: What Is the Role of Serum Thyroglobulin Measurement in Patients With Differentiated Thyroid Cancer Treated Without Radioactive Iodine?. *The Journal of Clinical Endocrinology & Metabolism* **102**:6, 2113-2114. [Crossref]

2060. Hyemi Kwon, Hye-Seon Oh, Mijin Kim, Suyeon Park, Min Ji Jeon, Won Gu Kim, Won Bae Kim, Young Kee Shong, Dong Eun Song, Jung Hwan Baek, Ki-Wook Chung, Tae Yong Kim. 2017. Active Surveillance for Patients With Papillary Thyroid

Downloaded by Memorial Sloan Kettering from www.liebertpub.com at 08/14/19. For personal use only.

Microcarcinoma: A Single Center's Experience in Korea. *The Journal of Clinical Endocrinology & Metabolism* **102**:6, 1917-1925. [Crossref]

2061. Denise P. Momesso, R. Michael Tuttle. 2017. Response to Letter: What Is the Role of Serum Thyroglobulin Measurement in Patients With Differentiated Thyroid Cancer Treated Without Radioactive Iodine?. *The Journal of Clinical Endocrinology & Metabolism* **102**:6, 2115-2116. [Crossref]

2062. Hye Mi Gweon, Eun Ju Son, Jeong-Ah Kim, Ji Hyun Youk. 2017. Predictive Factors for Active Surveillance of Subcentimeter Thyroid Nodules with Highly Suspicious US Features. *Annals of Surgical Oncology* **24**:6, 1540-1545. [Crossref]

2063. Brian Hung-Hin Lang, Carlos K. H. Wong, Kai Pun Wong, Kelvin Ka-Wan Chu, Tony W. H. Shek. 2017. Effect of Thyroid Remnant Volume on the Risk of Hypothyroidism After Hemithyroidectomy: A Prospective Study. *Annals of Surgical Oncology* **24**:6, 1525-1532. [Crossref]

2064. Anna Angelousi, Georgios K Dimitriadis, Georgios Zografos, Svenja Nölting, Gregory Kaltsas, Ashley Grossman. 2017. Molecular targeted therapies in adrenal, pituitary and parathyroid malignancies. *Endocrine-Related Cancer* **24**:6, R239-R259. [Crossref]

2065. Christopher W Rowe, Jonathan W Paul, Craig Gedye, Jorge M Tolosa, Cino Bendinelli, Shaun McGrath, Roger Smith. 2017. Targeting the TSH receptor in thyroid cancer. *Endocrine-Related Cancer* **24**:6, R191-R202. [Crossref]

2066. Ana Kober N. Leite, Beatriz G. Cavalheiro, Marco Aurélio Kulcsar, Ana de Oliveira Hoff, Lenine G. Brandão, Claudio Roberto Cernea, Leandro L. Matos. 2017. Deaths related to differentiated thyroid cancer: a rare but real event. *Archives of Endocrinology and Metabolism* **61**:3, 222-227. [Crossref]

2067. Ricardo Luiz Costantin Delfim, Leticia Carrasco Garcez da Veiga, Ana Paula Aguiar Vidal, Flávia Paiva Proença Lobo Lopes, Mário Vaisman, Patrícia de Fatima dos Santos Teixeira. 2017. Likelihood of malignancy in thyroid nodules according to a proposed Thyroid Imaging Reporting and Data System (TI-RADS) classification merging suspicious and benign ultrasound features. *Archives of Endocrinology and Metabolism* **61**:3, 211-221. [Crossref]

2068. Cristiane Gomes Lima, Leonard Wartofsky. 2017. Two themes in thyroid cancer: artful diagnosis and shortened lives. *Archives of Endocrinology and Metabolism* **61**:3, 205-207. [Crossref]

2069. William D. Middleton, Sharlene A. Teefey, Carl C. Reading, Jill E. Langer, Michael D. Beland, Margaret M. Szabunio, Terry S. Desser. 2017. Multiinstitutional Analysis of Thyroid Nodule Risk Stratification Using the American College of Radiology Thyroid Imaging Reporting and Data System. *American Journal of Roentgenology* **208**:6, 1331-1341. [Crossref]

2070. Daniela Victoria Pirela Araque, Archie Bleyer, Juan P Brito. 2017. Thyroid cancer in adolescents and young adults. *Future Oncology* **13**:14, 1253-1261. [Crossref]

2071. Benedikt Schmidbauer, Karin Menhart, Dirk Hellwig, Jirka Grosse. 2017. Differentiated Thyroid Cancer?Treatment: State of the Art. *International Journal of Molecular Sciences* **18**:6, 1292. [Crossref]

2072. Mariusz Stasiołek, Zbigniew Adamczewski, Przemysław Śliwka, Bartosz Puła, Bolesław Karwowski, Anna Merecz-Sadowska, Marek Dedecjus, Andrzej Lewiński. 2017. The Molecular Effect of Diagnostic Absorbed Doses from 131I on Papillary Thyroid Cancer Cells In Vitro. *Molecules* **22**:6, 993. [Crossref]

2073. Jeonghoon Ha, Dong Jun Lim. 2017. Guidelines for the Postoperative Treatment of Thyroid Cancer: Levothyroxine and Calcium/Vitamin D Supplements. *The Korean Journal of Medicine* **92**:3, 245-250. [Crossref]

2074. Jin-Fen Wang, Tao Wu, Kun-Peng Hu, Wen Xu, Bo-Wen Zheng, Ge Tong, Zhi-Cheng Yao, Bo Liu, Jie Ren. 2017. Complications Following Radiofrequency Ablation of Benign Thyroid Nodules. *Chinese Medical Journal* **130**:11, 1361-1370. [Crossref]

2075. Su Min Ha, Jin Yong Sung, Jung Hwan Baek, Dong Gyu Na, Ji-hoon Kim, Hyunju Yoo, Ducky Lee, Dong Whan Choi. 2017. Radiofrequency ablation of small follicular neoplasms: initial clinical outcomes. *International Journal of Hyperthermia* **34**, 1-7. [Crossref]

2076. Carrie Lubitz, Ayman Ali, Tiannan Zhan, Curtis Heberle, Craig White, Yasuhiro Ito, Akira Miyauchi, G. Scott Gazelle, Chung Yin Kong, Chin Hur. 2017. The thyroid cancer policy model: A mathematical simulation model of papillary thyroid carcinoma in The U.S. population. *PLOS ONE* **12**:5, e0177068. [Crossref]

2077. Dan Wang, Hui-Jun Fu, Hui-Xiong Xu, Le-Hang Guo, Xiao-Long Li, Ya-Ping He, Xiao-Wan Bo, Chong-Ke Zhao, Li-Ping Sun, Feng Lu, Kun Zhang, Qing Wei. 2017. Comparison of fine needle aspiration and non-aspiration cytology for diagnosis of thyroid nodules: A prospective, randomized, and controlled trial. *Clinical Hemorheology and Microcirculation* **66**:1, 67-81. [Crossref]

2078. Eleonora Molinaro, Rossella Elisei, Cristina Romei. 2017. Clinical impact of molecular techniques for the presurgical diagnosis of differentiated thyroid cancer diagnosis. *Expert Review of Endocrinology & Metabolism* **12**:3, 207-214. [Crossref]

2079. Biermann Martin. 2017. How Often Does a Thyroid Cancer Patient Need to Undergo Surveillance with Cervical Ultrasound?. *Clinical Thyroidology* **29**:5, 173-175. [Citation] [Full Text] [PDF] [PDF Plus]

Downloaded by Memorial Sloan Kettering from www.liebertpub.com at 08/14/19. For personal use only.

2080. Livhits Masha J., Yeh Michael W.. 2017. Many Patients Who Become Hypothyroid After Lobectomy Will Recover Normal Thyroid Function Without Supplementation. *Clinical Thyroidology* **29**:5, 183-185. [Citation] [Full Text] [PDF] [PDF Plus]

2081. Fish Stephanie A.. 2017. 124I PET–CT May Be Useful in Identifying Radioiodine-Avid Lesions in Differentiated Thyroid Cancer. *Clinical Thyroidology* **29**:5, 195-197. [Citation] [Full Text] [PDF] [PDF Plus]

2082. Youngwirth Linda M., Adam Mohamed A., Scheri Randall P., Roman Sanziana A., Sosa Julie A.. 2017. Extrathyroidal Extension Is Associated with Compromised Survival in Patients with Thyroid Cancer. *Thyroid* **27**:5, 626-631. [Abstract] [Full Text] [PDF] [PDF Plus]

2083. Cavallo Allison, Johnson Daniel N., White Michael G., Siddiqui Saaduddin, Antic Tatjana, Mathew Melvy, Grogan Raymon H., Angelos Peter, Kaplan Edwin L., Cipriani Nicole A.. 2017. Thyroid Nodule Size at Ultrasound as a Predictor of Malignancy and Final Pathologic Size. *Thyroid* **27**:5, 641-650. [Abstract] [Full Text] [PDF] [PDF Plus]

2084. Moon Shinje, Song Young Shin, Kim Ye An, Lim Jung Ah, Cho Sun Wook, Moon Jae Hoon, Hahn Seokyung, Park Do Joon, Park Young Joo. 2017. Effects of Coexistent BRAFV600E and TERT Promoter Mutations on Poor Clinical Outcomes in Papillary Thyroid Cancer: A Meta-Analysis. *Thyroid* **27**:5, 651-660. [Abstract] [Full Text] [PDF] [PDF Plus] [Supplementary Material]

2085. Chung Sae Rom, Baek Jung Hwan, Park Hye Sun, Choi Young Jun, Sung Tae-Yon, Song Dong Eun, Kim Tae Yong, Lee Jeong Hyun. 2017. Ultrasound-Pathology Discordant Nodules on Core-Needle Biopsy: Malignancy Risk and Management Strategy. *Thyroid* **27**:5, 707-713. [Abstract] [Full Text] [PDF] [PDF Plus]

2086. Nickel Brooke, Brito Juan P., Barratt Alexandra, Jordan Susan, Moynihan Ray, McCaffery Kirsten. 2017. Clinicians' Views on Management and Terminology for Papillary Thyroid Microcarcinoma: A Qualitative Study. *Thyroid* **27**:5, 661-671. [Abstract] [Full Text] [PDF] [PDF Plus]

2087. Lang Brian Hung-Hin, Woo Yu-Cho, Chiu Keith Wan-Hang. 2017. Single-Session High-Intensity Focused Ultrasound Treatment in Large-Sized Benign Thyroid Nodules. *Thyroid* **27**:5, 714-721. [Abstract] [Full Text] [PDF] [PDF Plus]

2088. Lili Gao, Ben Ma, Li Zhou, Yu Wang, Shuwen Yang, Ning Qu, Yi Gao, Qinghai Ji. 2017. The impact of presence of Hashimoto's thyroiditis on diagnostic accuracy of ultrasound-guided fine-needle aspiration biopsy in subcentimeter thyroid nodules: A retrospective study from FUSCC. *Cancer Medicine* **6**:5, 1014-1022. [Crossref]

2089. Sylvan C. Baca, Kristine S. Wong, Kyle C. Strickland, Howard T. Heller, Matthew I. Kim, Justine A. Barletta, Edmund S. Cibas, Jeffrey F. Krane, Ellen Marqusee, Trevor E. Angell. 2017. Qualifiers of atypia in the cytologic diagnosis of thyroid nodules are associated with different Afirma gene expression classifier results and clinical outcomes. *Cancer Cytopathology* **125**:5, 313-322. [Crossref]

2090. Liena Zhao, Dora Dias-Santagata, Peter M. Sadow, William C. Faquin. 2017. Cytological, molecular, and clinical features of noninvasive follicular thyroid neoplasm with papillary-like nuclear features versus invasive forms of follicular variant of papillary thyroid carcinoma. *Cancer Cytopathology* **125**:5, 323-331. [Crossref]

2091. Ilya Likhterov, Laura L. Dos Reis, Mark L. Urken. 2017. Central compartment management in patients with papillary thyroid cancer presenting with metastatic disease to the lateral neck: Anatomic pathways of lymphatic spread. *Head & Neck* **39**:5, 853-859. [Crossref]

2092. Jose Manuel Gonzalez Carvalho, Dennis Görlich, Otmar Schober, Christian Wenning, Burkhard Riemann, Frederik Anton Verburg, Alexis Vrachimis. 2017. Evaluation of 131I scintigraphy and stimulated thyroglobulin levels in the follow up of patients with DTC: a retrospective analysis of 1420 patients. *European Journal of Nuclear Medicine and Molecular Imaging* **44**:5, 744-756. [Crossref]

2093. Christian Pirich, Gregor Schweighofer-Zwink. 2017. Less is more: reconsidering the need for regular use of diagnostic whole body radioiodine scintigraphy in the follow-up of differentiated thyroid cancer. *European Journal of Nuclear Medicine and Molecular Imaging* **44**:5, 741-743. [Crossref]

2094. Rana Terlemez, Kenan Akgün, Deniz Palamar, Sinan Boz, Hidayet Sarı. 2017. The clinical importance of the thyroid nodules during anti-tumor necrosis factor therapy in patients with axial spondyloarthritis. *Clinical Rheumatology* **36**:5, 1071-1076. [Crossref]

2095. Pedro Weslley Rosario, Alexandre Lemos da Silva, Marcelo Saldanha Nunes, Michelle Aparecida Ribeiro Borges, Gabriela Franco Mourão, Maria Regina Calsolari. 2017. Risk of malignancy in 1502 solid thyroid nodules >1 cm using the new ultrasonographic classification of the American Thyroid Association. *Endocrine* **56**:2, 442-445. [Crossref]

2096. Roy Lirov, Francis P. Worden, Mark S. Cohen. 2017. The Treatment of Advanced Thyroid Cancer in the Age of Novel Targeted Therapies. *Drugs* **77**:7, 733-745. [Crossref]

2097. F. D. Dellal, D. Özdemir, A. A. Tam, H. Baser, H. Tatli Dogan, O. Parlak, R. Ersoy, B. Cakir. 2017. Clinicopathological features of thyroid cancer in the elderly compared to younger counterparts: single-center experience. *Journal of Endocrinological Investigation* **40**:5, 471-479. [Crossref]

Downloaded by Memorial Sloan Kettering from www.liebertpub.com at 08/14/19. For personal use only.

2098. Jordan Wong, Kaidi Liu, Celia Siu, Steven Jones, Marlise Sovka, Don Wilson, Sam M. Wiseman. 2017. Management of PET diagnosed thyroid incidentalomas in British Columbia Canada: Critical importance of the PET report. *The American Journal of Surgery* **213**:5, 950-957. [Crossref]

2099. Alexandra Inman, Kaidi Liu, Kaye Ong, Pari Tiwari, Patrick Vos, Adam White, Sam M. Wiseman. 2017. Completeness of ultrasound reporting impacts time to biopsy for benign and malignant thyroid nodules. *The American Journal of Surgery* **213**:5, 931-935. [Crossref]

2100. Jinhao Liu, Wei Sun, Wenwu Dong, Zhihong Wang, Yuan Qin, Ting Zhang, Hao Zhang. 2017. HSP90 inhibitor NVP-AUY922 induces cell apoptosis by disruption of the survivin in papillary thyroid carcinoma cells. *Biochemical and Biophysical Research Communications* **487**:2, 313-319. [Crossref]

2101. J.J. Díez, P. Iglesias, T. Alonso-Gordoa, E. Grande. 2017. Mejoría en la calidad del manejo de los pacientes tras la implementación de un comité multidisciplinar de tumores endocrinos: análisis de la experiencia de 5 años. *Revista de Calidad Asistencial* **32**:3, 187-189. [Crossref]

2102. K.L. Newbold, G. Flux, J. Wadsley. 2017. Radioiodine for High Risk and Radioiodine Refractory Thyroid Cancer: Current Concepts in Management. *Clinical Oncology* **29**:5, 307-309. [Crossref]

2103. V.D. Tarasova, R.M. Tuttle. 2017. Current Management of Low Risk Differentiated Thyroid Cancer and Papillary Microcarcinoma. *Clinical Oncology* **29**:5, 290-297. [Crossref]

2104. B. Freudenthal, G.R. Williams. 2017. Thyroid Stimulating Hormone Suppression in the Long-term Follow-up of Differentiated Thyroid Cancer. *Clinical Oncology* **29**:5, 325-328. [Crossref]

2105. P. Asimakopoulos, I.J. Nixon, A.R. Shaha. 2017. Differentiated and Medullary Thyroid Cancer: Surgical Management of Cervical Lymph Nodes. *Clinical Oncology* **29**:5, 283-289. [Crossref]

2106. L. Dal Maso, A. Tavilla, F. Pacini, D. Serraino, B.A.C. van Dijk, M.D. Chirlaque, R. Capocaccia, N. Larrañaga, M. Colonna, D. Agius, E. Ardanaz, J. Rubió-Casadevall, A. Kowalska, S. Virdone, S. Mallone, H. Amash, R. De Angelis, M. Hackl, N. Zielonke, E. Van Eycken, K. Henau, Z. Valerianova, N. Dimitrova, M. Sekerija, L. Dušek, M. Zvolský, H. Storm, G. Engholm, M. Mägi, T. Aareleid, N. Malila, K. Seppä, M. Velten, A.V. Guizard, J. Faivre, A.S. Woronoff, B. Tretarre, N. Bossard, Z. Uhry, M. Colonna, F. Molinié, S. Bara, C. Schvartz, B. Lapôtre-Ledoux, P. Grosclaude, R. Stabenow, S. Luttmann, A. Eberle, H. Brenner, A. Nennecke, J. Engel, G. Schubert-Fritschle, J. Heidrich, B. Holleczek, A. Katalinic, J.G. Jónasson, L. Tryggvadóttir, H. Comber, G. Mazzoleni, A. Bulatko, C. Buzzoni, A. Giacomin, A. Sutera Sardo, A. Mazzei, S. Ferretti, A. Barchielli, A. Caldarella, G. Gatta, M. Sant, H. Amash, C. Amati, P. Baili, F. Berrino, S. Bonfarnuzzo, L. Botta, R. Capocaccia, F. Di Salvo, R. Foschi, C. Margutti, E. Meneghini, P. Minicozzi, A. Trama, D. Serraino, A. Zucchetto, R. De Angelis, M. Caldora, E. Carrani, S. Francisci, S. Mallone, D. Pierannunzio, P. Roazzi, S. Rossi, M. Santaquilani, A. Tavilla, F. Pannozzo, S. Busco, R.A. Filiberti, M. Vercelli, P. Ricci, M. Autelitano, G. Spagnoli, C. Cirilli, M. Fusco, M.F. Vitale, M. Usala, F. Vitale, B. Ravazzolo, M. Michiara, R. Tumino, L. Mangone, M. Vicentini, F. Falcini, A. Iannelli, O. Sechi, R. Cesaraccio, S. Piffer, A. Madeddu, F. Tisano, S. Maspero, A.C. Fanetti, R. Zanetti, S. Rosso, P. Candela, T. Scuderi, F. Stracci, A. Rocca, G. Tagliabue, P. Contiero, M. Rugge, S. Tognazzo, S. Pildava, G. Smailyte, N. Calleja, D. Agius, T.B. Johannesen, J. Rachtan, S. Góźdź, R. Mężyk, J. Błaszczyk, M. Bębenek, M. Bielska-Lasota, G. Forjaz de Lacerda, M.J. Bento, C. Castro, A. Miranda, A. Mayer-da-Silva, C. Safaei Diba, M. Primic-Zakelj, M. Errezola, J. Bidaurrazaga, J.M. Díaz García, A.I. Marcos-Navarro, R. Marcos-Gragera, A. Izquierdo Font, M.J. Sanchez, E. Molina, C. Navarro, M.D. Chirlaque, C. Moreno-Iribas, E. Ardanaz, J. Galceran, M. Carulla, M. Lambe, S. Khan, M. Mousavi, C. Bouchardy, M. Usel, S.M. Ess, H. Frick, M. Lorez, S.M. Ess, C. Herrmann, A. Bordoni, A. Spitale, I. Konzelmann, O. Visser, V. Ho, R. Otter, M. Coleman, C. Allemani, B. Rachet, J. Rashbass, J. Broggio, J. Verne, A. Gavin, C. Donnelly, D.H. Brewster, D.W. Huws, C. White. 2017. Survival of 86,690 patients with thyroid cancer: A population-based study in 29 European countries from EUROCARE-5. *European Journal of Cancer* **77**, 140-152. [Crossref]

2107. C. Dobrinja, M. Troian, T. Cipolat Mis, G. Rebez, S. Bernardi, B. Fabris, L. Piscopello, P. Makovac, F. Di Gregorio, N. de Manzini. 2017. Rationality in prophylactic central neck dissection in clinically node-negative (cN0) papillary thyroid carcinoma: Is there anything more to say? A decade experience in a single-center. *International Journal of Surgery* **41**, S40-S47. [Crossref]

2108. Maija Radzina, Vito Cantisani, Madara Rauda, Michael Bachmann Nielsen, Caroline Ewertsen, Ferdinando D'Ambrosio, Peteris Prieditis, Salvatore Sorrenti. 2017. Update on the role of ultrasound guided radiofrequency ablation for thyroid nodule treatment. *International Journal of Surgery* **41**, S82-S93. [Crossref]

2109. C. Dobrinja, M. Pastoricchio, M. Troian, F. Da Canal, S. Bernardi, B. Fabris, N. de Manzini. 2017. Partial thyroidectomy for papillary thyroid microcarcinoma: Is completion total thyroidectomy indicated?. *International Journal of Surgery* **41**, S34-S39. [Crossref]

2110. Franklin N. Tessler, William D. Middleton, Edward G. Grant, Jenny K. Hoang, Lincoln L. Berland, Sharlene A. Teefey, John J. Cronan, Michael D. Beland, Terry S. Desser, Mary C. Frates, Lynwood W. Hammers, Ulrike M. Hamper, Jill E. Langer, Carl C.

Downloaded by Memorial Sloan Kettering from www.liebertpub.com at 08/14/19. For personal use only.

Reading, Leslie M. Scoutt, A. Thomas Stavros. 2017. ACR Thyroid Imaging, Reporting and Data System (TI-RADS): White Paper of the ACR TI-RADS Committee. *Journal of the American College of Radiology* **14**:5, 587-595. [Crossref]

2111. Ashok R. Shaha. 2017. Extrathyroidal extension—what does it mean. *Oral Oncology* **68**, 50-52. [Crossref]

2112. Kyunghwa Han, Eun-Kyung Kim, Jin Young Kwak. 2017. 1.5–2 cm tumor size was not associated with distant metastasis and mortality in small thyroid cancer: A population-based study. *Scientific Reports* **7**:1. . [Crossref]

2113. Renfei Wang, Yueqian Zhang, Jian Tan, Guizhi Zhang, Ruiguo Zhang, Wei Zheng, Yajing He. 2017. Analysis of radioiodine therapy and prognostic factors of differentiated thyroid cancer patients with pulmonary metastasis. *Medicine* **96**:19, e6809. [Crossref]

2114. Prasanna Santhanam, David Taieb, Lilja Solnes, Wael Marashdeh, Paul W. Ladenson. 2017. Utility of I-124 PET/CT in identifying radioiodine avid lesions in differentiated thyroid cancer: a systematic review and meta-analysis. *Clinical Endocrinology* **86**:5, 645-651. [Crossref]

2115. Jung Hyun Yoon, Kyunghwa Han, Eun-Kyung Kim, Hee Jung Moon, Jin Young Kwak. 2017. Diagnosis and Management of Small Thyroid Nodules: A Comparative Study with Six Guidelines for Thyroid Nodules. *Radiology* **283**:2, 560-569. [Crossref]

2116. Behzad Salari, Rebecca J. Hammon, Dipti Kamani, Gregory W. Randolph. 2017. Staged Surgery for Advanced Thyroid Cancers: Safety and Oncologic Outcomes of Neural Monitored Surgery. *Otolaryngology–Head and Neck Surgery* **156**:5, 816-821. [Crossref]

2117. Nicholas E. Khan, Andrew J. Bauer, Kris Ann P. Schultz, Leslie Doros, Rosamma M. Decastro, Alexander Ling, Maya B. Lodish, Laura A. Harney, Ron G. Kase, Ann G. Carr, Christopher T. Rossi, Amanda Field, Anne K. Harris, Gretchen M. Williams, Louis P. Dehner, Yoav H. Messinger, D. Ashley Hill, Douglas R. Stewart. 2017. Quantification of Thyroid Cancer and Multinodular Goiter Risk in the DICER1 Syndrome: A Family-Based Cohort Study. *The Journal of Clinical Endocrinology & Metabolism* **102**:5, 1614-1622. [Crossref]

2118. Tae Hyuk Kim, Chang-Seok Ki, Hye Seung Kim, Kyunga Kim, Jun-Ho Choe, Jung-Han Kim, Jee Soo Kim, Young Lyun Oh, Soo Yeon Hahn, Jung Hee Shin, Hye Won Jang, Sun Wook Kim, Jae Hoon Chung. 2017. Refining Dynamic Risk Stratification and Prognostic Groups for Differentiated Thyroid Cancer With TERT Promoter Mutations. *The Journal of Clinical Endocrinology & Metabolism* **102**:5, 1757-1764. [Crossref]

2119. Luca Giovanella, Luca Ceriani, Pierpaolo Trimboli. 2017. Letter to the Editor: "Postoperative Thyroglobulin and Neck Ultrasound in the Risk Restratification and Decision to Perform 131I Ablation". *The Journal of Clinical Endocrinology & Metabolism* **102**:5, 1783-1784. [Crossref]

2120. Rossella Elisei, Francesca Binchi, Antonio Matrone. 2017. Response to Letter: "Postoperative Thyroglobulin and Neck Ultrasound in the Risk Restratification and Decision to Perform 131I Ablation". *The Journal of Clinical Endocrinology & Metabolism* **102**:5, 1785-1786. [Crossref]

2121. Roeland J. W. Middelbeek, Brian T. O'Neill, Michiya Nishino, Johanna A. Pallotta. 2017. Concurrent Intrathyroidal Thyroid Cancer and Thyroid Cancer in Struma Ovarii: A Case Report and Literature Review. *Journal of the Endocrine Society* **1**:5, 396-400. [Crossref]

2122. Colleen M. Kiernan, Martin A. Whiteside, Carmen C. Solorzano. 2017. Cancer Registries: Can We Improve the Quality of Thyroid Cancer Data?. *Annals of Surgical Oncology* **24**:5, 1202-1207. [Crossref]

2123. Jinhao Liu, Wei Sun, Wenwu Dong, Zhihong Wang, Ping Zhang, Ting Zhang, Hao Zhang. 2017. Risk factors for post-thyroidectomy haemorrhage: a meta-analysis. *European Journal of Endocrinology* **176**:5, 591-602. [Crossref]

2124. P Trimboli, V Zilioli, M Imperiali, L Ceriani, L Giovanella. 2017. High-sensitive basal serum thyroglobulin 6–12 months after thyroid ablation is strongly associated with early response to therapy and event-free survival in patients with low-to-intermediate risk differentiated thyroid carcinomas. *European Journal of Endocrinology* **176**:5, 497-504. [Crossref]

2125. Zaid Al-Qurayshi, Mohamed A Shama, Gregory W Randolph, Emad Kandil. 2017. Minimal extrathyroidal extension does not affect survival of well-differentiated thyroid cancer. *Endocrine-Related Cancer* **24**:5, 221-226. [Crossref]

2126. Marcia S Brose, Johannes Smit, Chia-Chi Lin, Fabian Pitoia, Marc Fellous, Yoriko DeSanctis, Martin Schlumberger, Masayuki Tori, Iwao Sugitani. 2017. Timing of multikinase inhibitor initiation in differentiated thyroid cancer. *Endocrine-Related Cancer* **24**:5, 237-242. [Crossref]

2127. Bengür Taşkıran, Güven Barış Cansu. 2017. Eksenatid Tedavisinde Tiroid İnce İğne Aspirasyon Biyopsisi ve Kalsitonin Yıkamanın Yeri Role of Thyroid Fine Needle Aspiration Biopsy and Calcitonin Wash-Out During Exenatide Therapy. *Osmangazi Journal of Medicine* **39**:2, 40-44. [Crossref]

2128. Abbas Ali Tam, Didem Ozdemir, Berna Evranos Ogmen, Sevgul Fakı, Ersin Gurkan Dumlu, Aylin Kılıc Yazgan, Reyhan Ersoy, Bekir Cakır. 2017. SHOULD MULTIFOCAL PAPILLARY THYROID CARCINOMAS CLASSIFIED AS T1A WITH A TUMOR DIAMETER SUM OF 1 TO 2 CENTIMETERS BE RECLASSIFIED AS T1B?. *Endocrine Practice* **23**:5, 526-535. [Crossref]

Downloaded by Memorial Sloan Kettering from www.liebertpub.com at 08/14/19. For personal use only.

2129. Qin Ye, Jennifer S. Woo, Qunzi Zhao, Ping Wang, Pintong Huang, Lirong Chen, Xin Li, Kanlun Xu, Ying Yong, Stephanie (Sung-Eun) Yang, Jianyu Rao. 2017. Fine-Needle Aspiration Versus Frozen Section in the Evaluation of Malignant Thyroid Nodules in Patients With the Diagnosis of Suspicious for Malignancy or Malignancy by Fine-Needle Aspiration. *Archives of Pathology & Laboratory Medicine* **141**:5, 684-689. [Crossref]

2130. Maria Papaleontiou, David T. Hughes, Cui Guo, Mousumi Banerjee, Megan R. Haymart. 2017. Population-Based Assessment of Complications following Surgery for Thyroid Cancer. *The Journal of Clinical Endocrinology & Metabolism* . [Crossref]

2131. Brian H. H. Lang, Yu-Cho Woo, Keith Wan-Hang Chiu. 2017. High-intensity focused ablation (HIFU) of single benign thyroid nodule rarely alters underlying thyroid function. *International Journal of Hyperthermia* 1-7. [Crossref]

2132. Abdullah Şişik, Fatih Başak, Emin Köse. 2017. Tiroid nodüllerine güncel yaklaşım: "2015 ATA" ve "2016 AACE/ACE/AME" kılavuzları derlemesi. *ARCHIVES OF CLINICAL AND EXPERIMENTAL MEDICINE* **2**:1, 18-18. [Crossref]

2133. Jung Suk Sim, Jung Hwan Baek, Joongyub Lee, Woojin Cho, Sung Il Jung. 2017. Radiofrequency ablation of benign thyroid nodules: depicting early sign of regrowth by calculating vital volume. *International Journal of Hyperthermia* **39**, 1-6. [Crossref]

2134. Francesca Rosignolo, Lorenzo Memeo, Fabio Monzani, Cristina Colarossi, Valeria Pecce, Antonella Verrienti, Cosimo Durante, Giorgio Grani, Livia Lamartina, Stefano Forte, Daniela Martinetti, Dario Giuffrida, Diego Russo, Fulvio Basolo, Sebastiano Filetti, Marialuisa Sponziello. 2017. MicroRNA-based molecular classification of papillary thyroid carcinoma. *International Journal of Oncology* . [Crossref]

2135. David F. Schneider, Linda M. Cherney Stafford, Nicole Brys, Caprice C. Greenberg, Courtney J. Balentine, Dawn M. Elfenbein, Susan C. Pitt. 2017. GAUGING THE EXTENT OF THYROIDECTOMY FOR INDETERMINATE THYROID NODULES: AN ONCOLOGIC PERSPECTIVE. *Endocrine Practice* **23**:4, 442-450. [Crossref]

2136. Nidhi Agrawal, Collette E. Abbott, Cheng Liu, Stella Kang, Laura Tipton, Kepal Patel, Mark Persky, Lizabeth King, Fang-Ming Deng, Michael Bannan, Jennifer B. Ogilvie, Keith Heller, Steven P. Hodak. 2017. NONINVASIVE FOLLICULAR TUMOR WITH PAPILLARY-LIKE NUCLEAR FEATURES: NOT A TEMPEST IN A TEAPOT. *Endocrine Practice* **23**:4, 451-457. [Crossref]

2137. Fish Stephanie A.. 2017. Postoperative Thyroglobulin and Neck Ultrasound Are Useful for Risk Restratification and Decision to Perform 131I Ablation. *Clinical Thyroidology* **29**:4, 136-139. [Citation] [Full Text] [PDF] [PDF Plus]

2138. Biermann Martin. 2017. Intensity of 18F-FDG Uptake in Metastatic Differentiated Thyroid Cancer Fails to Predict Growth in Individual Metastatic Lesions. *Clinical Thyroidology* **29**:4, 140-142. [Citation] [Full Text] [PDF] [PDF Plus]

2139. Leung Angela M.. 2017. Thyroid Nodules Do Not Increase in Size During Pregnancy. *Clinical Thyroidology* **29**:4, 150-152. [Citation] [Full Text] [PDF] [PDF Plus]

2140. Choi Young Jun, Baek Jung Hwan, Park Hye Sun, Shim Woo Hyun, Kim Tae Yong, Shong Young Kee, Lee Jeong Hyun. 2017. A Computer-Aided Diagnosis System Using Artificial Intelligence for the Diagnosis and Characterization of Thyroid Nodules on Ultrasound: Initial Clinical Assessment. *Thyroid* **27**:4, 546-552. [Abstract] [Full Text] [PDF] [PDF Plus]

2141. Woo Jung-Woo, Kim Seo Ki, Park Inhye, Choe Jun Ho, Kim Jung-Han, Kim Jee Soo. 2017. A Novel Gel Pad Laryngeal Ultrasound for Vocal Cord Evaluation. *Thyroid* **27**:4, 553-557. [Abstract] [Full Text] [PDF] [PDF Plus]

2142. Ito Mitsuru, Miyauchi Akira, Hisakado Mako, Yoshioka Waka, Ide Akane, Kudo Takumi, Nishihara Eijun, Kihara Minoru, Ito Yasuhiro, Kobayashi Kaoru, Miya Akihiro, Fukata Shuji, Nishikawa Mitsushige, Nakamura Hirotoshi, Amino Nobuyuki. 2017. Biochemical Markers Reflecting Thyroid Function in Athyreotic Patients on Levothyroxine Monotherapy. *Thyroid* **27**:4, 484-490. [Abstract] [Full Text] [PDF] [PDF Plus]

2143. Tulchinsky Mark, Avram Anca M.. 2017. Re: "Long-Term Outcomes of Patients with Papillary Thyroid Cancer Undergoing Remnant Ablation with 30 Millicurie Radioiodine" by Mujammami et al. (Thyroid 2016;26:951–958): Patient Cohort Definition Makes No Sense. *Thyroid* **27**:4, 591-591. [Citation] [Full Text] [PDF] [PDF Plus]

2144. Park Suyeon, Kim Won Gu, Song Eyun, Oh Hye-Seon, Kim Mijin, Kwon Hyemi, Jeon Min Ji, Kim Tae Yong, Shong Young Kee, Kim Won Bae. 2017. Dynamic Risk Stratification for Predicting Recurrence in Patients with Differentiated Thyroid Cancer Treated Without Radioactive Iodine Remnant Ablation Therapy. *Thyroid* **27**:4, 524-530. [Abstract] [Full Text] [PDF] [PDF Plus]

2145. Shen Feng-Chih, Hsieh Ching-Jung, Huang I-Chin, Chang Yen-Hsiang, Wang Pei-Wen. 2017. Dynamic Risk Estimates of Outcome in Chinese Patients with Well-Differentiated Thyroid Cancer After Total Thyroidectomy and Radioactive Iodine Remnant Ablation. *Thyroid* **27**:4, 531-536. [Abstract] [Full Text] [PDF] [PDF Plus]

2146. Griffin Andrew, Brito Juan P., Bahl Manisha, Hoang Jenny K.. 2017. Applying Criteria of Active Surveillance to Low-Risk Papillary Thyroid Cancer Over a Decade: How Many Surgeries and Complications Can Be Avoided?. *Thyroid* **27**:4, 518-523. [Abstract] [Full Text] [PDF] [PDF Plus]

Downloaded by Memorial Sloan Kettering from www.liebertpub.com at 08/14/19. For personal use only.

2147. Haugen Bryan R., Sawka Anna M., Alexander Erik K., Bible Keith C., Caturegli Patrizio, Doherty Gerard M., Mandel Susan J., Morris John C., Nassar Aziza, Pacini Furio, Schlumberger Martin, Schuff Kathryn, Sherman Steven I., Somerset Hilary, Sosa Julie Ann, Steward David L., Wartofsky Leonard, Williams Michelle D.. 2017. American Thyroid Association Guidelines on the Management of Thyroid Nodules and Differentiated Thyroid Cancer Task Force Review and Recommendation on the Proposed Renaming of Encapsulated Follicular Variant Papillary Thyroid Carcinoma Without Invasion to Noninvasive Follicular Thyroid Neoplasm with Papillary-Like Nuclear Features. *Thyroid* **27**:4, 481-483. [Abstract] [Full Text] [PDF] [PDF Plus]

2148. Xu Bin, Tallini Giovanni, Scognamiglio Theresa, Roman Benjamin R., Tuttle R. Michael, Ghossein Ronald A.. 2017. Outcome of Large Noninvasive Follicular Thyroid Neoplasm with Papillary-Like Nuclear Features. *Thyroid* **27**:4, 512-517. [Abstract] [Full Text] [PDF] [PDF Plus]

2149. Anthony P. Polednak. 2017. Relationship of the recurrent laryngeal nerve to the inferior thyroid artery: A comparison of findings from two systematic reviews. *Clinical Anatomy* **30**:3, 318-321. [Crossref]

2150. Tiffany Rui Xuan Gan, Min En Nga, Jeffrey Huey Yew Lum, Wendy Meihua Wong, Wee Boon Tan, Rajeev Parameswaran, Kee Yuan Ngiam. 2017. Thyroid cytology-nuclear versus architectural atypia within the "Atypia of undetermined significance/follicular lesion of undetermined significance" Bethesda category have significantly different rates of malignancy. *Cancer Cytopathology* **125**:4, 245-256. [Crossref]

2151. Pedro Weslley Rosario, Alexandre Lemos Silva, Maria Regina Calsolari. 2017. Is fine needle aspiration really not necessary in patients with thyroid nodules ≤ 1 cm with highly suspicious features on ultrasonography and candidates for active surveillance?. *Diagnostic Cytopathology* **45**:4, 294-296. [Crossref]

2152. Sudarshana Roychoudhury, Melissa Klein, Fabiola Souza, Cecilia Gimenez, Alice Laser, Rubina Shaheen Cocker, Karen Chau, Kasturi Das. 2017. How "suspicious" is that nodule? Review of "suspicious" Afirma gene expression classifier in high risk thyroid nodules. *Diagnostic Cytopathology* **45**:4, 308-311. [Crossref]

2153. Marcela Osorio, Sami P. Moubayed, Henry Su, Mark L. Urken. 2017. Systematic review of site distribution of bone metastases in differentiated thyroid cancer. *Head & Neck* **39**:4, 812-818. [Crossref]

2154. Joon-Hyop Lee, Yoo Seung Chung, Young Don Lee. 2017. A variation in recurrence patterns of papillary thyroid cancer with disease progression: A long-term follow-up study. *Head & Neck* **39**:4, 767-771. [Crossref]

2155. Che-Wei Wu, Xiaoli Liu, Marcin Barczyński, Hoon Yub Kim, Gianlorenzo Dionigi, Hui Sun, Feng-Yu Chiang, Dipti Kamani, Gregory W. Randolph. 2017. Optimal stimulation during monitored thyroid surgery: EMG response characteristics in a porcine model. *The Laryngoscope* **127**:4, 998-1005. [Crossref]

2156. Marie Terroir, Isabelle Borget, François Bidault, Marcel Ricard, Frédéric Deschamps, Dana Hartl, Lambros Tselikas, Laurent Dercle, Jean Lumbroso, Eric Baudin, Amandine Berdelou, Désirée Deandreis, Martin Schlumberger, Sophie Leboulleux. 2017. The intensity of 18FDG uptake does not predict tumor growth in patients with metastatic differentiated thyroid cancer. *European Journal of Nuclear Medicine and Molecular Imaging* **44**:4, 638-646. [Crossref]

2157. Ahmad M. Eweida, Mahmoud F. Sakr, Yasser Hamza, Mohamed R. Khalil, Essam Gabr, Tarek Koraitim, Hatem F. Al-Wagih, Waleed Abo-Elwafa, Tarek Ezzat Abdel-Aziz, Ahmed A. Diab, Basma El-Sabaa, Aman S. Nabawi. 2017. Level I lymph node involvement in patients with N1b papillary thyroid carcinoma: a prospective study. *European Archives of Oto-Rhino-Laryngology* **274**:4, 1951-1958. [Crossref]

2158. I. Christakis, I.-D. Kafetzis, S. Dimas, N. Roukounakis. 2017. Pathological findings in 377 patients with differentiated thyroid cancer in a single centre. *Hellenic Journal of Surgery* **89**:2, 79-86. [Crossref]

2159. S. Morbelli, G. Ferrarazzo, E. Pomposelli, F. Pupo, G. Pesce, I. Calamia, F. Fiz, A. Clapasson, M. Bauckneht, M. Minuto, G. Sambuceti, M. Giusti, M. Bagnasco. 2017. Relationship between circulating anti-thyroglobulin antibodies (TgAb) and tumor metabolism in patients with differentiated thyroid cancer (DTC): prognostic implications. *Journal of Endocrinological Investigation* **40**:4, 417-424. [Crossref]

2160. Jean-Louis Wémeau, Christine Do Cao, Miriam Ladsous, Emmanuelle Leteurtre. 2017. Nodules de la thyroïde : de meilleures quantifications du risque de malignité. *Bulletin de l'Académie Nationale de Médecine* **201**:4-6, 681-697. [Crossref]

2161. Martin Schlumberger. 2017. Cancer papillaire de la thyroïde : vers une désescalade thérapeutique. *Bulletin de l'Académie Nationale de Médecine* **201**:4-6, 699-706. [Crossref]

2162. Sayid Shafi Zuhur, Derya Baykiz, Sonat Pinar Kara, Ertan Sahin, Idris Kuzu, Gulsah Elbuken. 2017. Relationship Among Pulmonary Hypertension, Autoimmunity, Thyroid Hormones and Dyspnea in Patients With Hyperthyroidism. *The American Journal of the Medical Sciences* **353**:4, 374-380. [Crossref]

2163. C. Cappelli, I. Pirola, B. Agosti, A. Tironi, E. Gandossi, P. Incardona, F. Marini, A. Guerini, M. Castellano. 2017. Complications after fine-needle aspiration cytology: a retrospective study of 7449 consecutive thyroid nodules. *British Journal of Oral and Maxillofacial Surgery* **55**:3, 266-269. [Crossref]

Downloaded by Memorial Sloan Kettering from www.liebertpub.com at 08/14/19. For personal use only.

2164. Guodong Fu, Olena Polyakova, Christina MacMillan, Ranju Ralhan, Paul G. Walfish. 2017. Programmed Death - Ligand 1 Expression Distinguishes Invasive Encapsulated Follicular Variant of Papillary Thyroid Carcinoma from Noninvasive Follicular Thyroid Neoplasm with Papillary-like Nuclear Features. *EBioMedicine* **18**, 50-55. [Crossref]

2165. Mar?a Jes?s Ladra Gonz?lez, Diego Peteiro Gonz?lez, Elvin Aliyev, Francisco Barreiro Morandeira, Jos? M. Cameselle-Teijeiro. 2017. Comments on ?Incidental versus non-incidental thyroid carcinoma: Clinical presentation, surgical management and prognosis?. *Endocrinolog?a, Diabetes y Nutrici?n (English ed.)* **64**:4, 232-233. [Crossref]

2166. María Jesús Ladra González, Diego Peteiro González, Elvin Aliyev, Francisco Barreiro Morandeira, José M. Cameselle-Teijeiro. 2017. Comentarios sobre «Carcinoma de tiroides incidental versus no incidental: presentación clínica, tratamiento quirúrgico y pronóstico». *Endocrinología, Diabetes y Nutrición* **64**:4, 232-233. [Crossref]

2167. Sylvia L. Asa. 2017. The evolution of differentiated thyroid cancer. *Pathology* **49**:3, 229-237. [Crossref]

2168. Héctor Enrique Torres Rivas, Luis Manuel Fernández Fernández. 2017. El patólogo intervencionista. Punción aspiración con aguja fina «ecoguiada» realizada por citopatólogo. Una realidad en España. *Revista Española de Patología* **50**:2, 72-81. [Crossref]

2169. Mariela Margarita Mac Dermott, Alicia Gauna, Judith E.W. de Yampey. 2017. Impacto del compromiso ganglionar en el pronóstico y la evolución del carcinoma papilar de tiroides. *Revista Argentina de Endocrinología y Metabolismo* **54**:2, 51-63. [Crossref]

2170. Erika Abelleira, Fernanda Bueno, Anabella Smulever, Fabi?n Pitoia. 2017. Riesgo din?mico en pacientes con c?ncer diferenciado de tiroides no ablacionados. *Revista Argentina de Endocrinolog?a y Metabolismo* **54**:2, 69-75. [Crossref]

2171. Angelica Schmidt, Graciela Cross, Fabi?n Pitoia. 2017. Met?stasis a distancia en c?ncer diferenciado de tiroides: diagn?stico y tratamiento. *Revista Argentina de Endocrinolog?a y Metabolismo* **54**:2, 92-100. [Crossref]

2172. Jung-Woo Woo, Inhye Park, Jun Ho Choe, Jung-Han Kim, Jee Soo Kim. 2017. Comparison of ultrasound frequency in laryngeal ultrasound for vocal cord evaluation. *Surgery* **161**:4, 1108-1112. [Crossref]

2173. Lu-Ying Gao, Ying Wang, Yu-Xin Jiang, Xiao Yang, Ru-Yu Liu, Xue-Hua Xi, Shen-Ling Zhu, Rui-Na Zhao, Xing-Jian Lai, Xiao-Yan Zhang, Bo Zhang. 2017. Ultrasound is helpful to differentiate Bethesda class III thyroid nodules. *Medicine* **96**:16, e6564. [Crossref]

2174. Husniye Baser, Bekir Cakir, Oya Topaloglu, Afra Alkan, Sefika Burcak Polat, Hayriye Tatli Dogan, Mustafa Omer Yazicioğlu, Cevdet Aydin, Reyhan Ersoy. 2017. Diagnostic accuracy of Thyroid Imaging Reporting and Data System in the prediction of malignancy in nodules with atypia and follicular lesion of undetermined significance cytologies. *Clinical Endocrinology* **86**:4, 584-590. [Crossref]

2175. Wouter P. Kluijfhout, Jesse D. Pasternak, Danielle van der Kaay, Menno R. Vriens, Evan J. Propst, Jonathan D. Wasserman. 2017. Is it time to reconsider lobectomy in low-risk paediatric thyroid cancer?. *Clinical Endocrinology* **86**:4, 591-596. [Crossref]

2176. Kristine Zøylner Swan, Viveque Egsgaard Nielsen, Bo Martin Bibby, Steen Joop Bonnema. 2017. Is the reproducibility of shear wave elastography of thyroid nodules high enough for clinical use? A methodological study. *Clinical Endocrinology* **86**:4, 606-613. [Crossref]

2177. Amy M. Manning, Huaitao Yang, Mercedes Falciglia, Jonathan R. Mark, David L. Steward. 2017. Thyroid Ultrasound-Guided Fine-Needle Aspiration Cytology Results: Observed Increase in Indeterminate Rate over the Past Decade. *Otolaryngology–Head and Neck Surgery* **156**:4, 611-615. [Crossref]

2178. Suyeon Park, Min Ji Jeon, Eyun Song, Hye-Seon Oh, Mijin Kim, Hyemi Kwon, Tae Yong Kim, Suck Joon Hong, Young Kee Shong, Won Bae Kim, Tae-Yon Sung, Won Gu Kim. 2017. Clinical Features of Early and Late Postoperative Hypothyroidism After Lobectomy. *The Journal of Clinical Endocrinology & Metabolism* **102**:4, 1317-1324. [Crossref]

2179. Jung Hee Shin. 2017. Ultrasonographic imaging of papillary thyroid carcinoma variants. *Ultrasonography* **36**:2, 103-110. [Crossref]

2180. Jung Hwan Baek. 2017. Current status of core needle biopsy of the thyroid. *Ultrasonography* **36**:2, 83-85. [Crossref]

2181. Hyemi Kwon, Min Ji Jeon, Won Gu Kim, Suyeon Park, Mijin Kim, Dong Eun Song, Tae-Yon Sung, Jong Ho Yoon, Suck Joon Hong, Tae Yong Kim, Young Kee Shong, Won Bae Kim. 2017. A comparison of lobectomy and total thyroidectomy in patients with papillary thyroid microcarcinoma: a retrospective individual risk factor-matched cohort study. *European Journal of Endocrinology* **176**:4, 371-378. [Crossref]

2182. Huy Gia Vuong, Tetsuo Kondo, Thong Quang Pham, Naoki Oishi, Kunio Mochizuki, Tadao Nakazawa, Lewis Hassell, Ryohei Katoh. 2017. Prognostic significance of diffuse sclerosing variant papillary thyroid carcinoma: a systematic review and meta-analysis. *European Journal of Endocrinology* **176**:4, 431-439. [Crossref]

2183. J.E. Park, J.H. Lee, K.H. Ryu, H.S. Park, M.S. Chung, H.W. Kim, Y.J. Choi, J.H. Baek. 2017. Improved Diagnostic Accuracy Using Arterial Phase CT for Lateral Cervical Lymph Node Metastasis from Papillary Thyroid Cancer. *American Journal of Neuroradiology* **38**:4, 782-788. [Crossref]

Downloaded by Memorial Sloan Kettering from www.liebertpub.com at 08/14/19. For personal use only.

2184. Silvia Cantara, Carlotta Marzocchi, Tania Pilli, Sandro Cardinale, Raffaella Forleo, Maria Castagna, Furio Pacini. 2017. Molecular Signature of Indeterminate Thyroid Lesions: Current Methods to Improve Fine Needle Aspiration Cytology (FNAC) Diagnosis. *International Journal of Molecular Sciences* **18**:4, 775. [Crossref]

2185. Young Ko, Tae Hwang, Ja Kim, Yoon-La Choi, Seung Lee, Hye Han, Wan Kim, Suk Kim, Kyoung Park. 2017. Diagnostic Limitation of Fine-Needle Aspiration (FNA) on Indeterminate Thyroid Nodules Can Be Partially Overcome by Preoperative Molecular Analysis: Assessment of RET/PTC1 Rearrangement in BRAF and RAS Wild-Type Routine Air-Dried FNA Specimens. *International Journal of Molecular Sciences* **18**:4, 806. [Crossref]

2186. Markus Eszlinger, Lorraine Lau, Sana Ghaznavi, Christopher Symonds, Shamir P. Chandarana, Moosa Khalil, Ralf Paschke. 2017. Molecular profiling of thyroid nodule fine-needle aspiration cytology. *Nature Reviews Endocrinology* **13**:7, 415-424. [Crossref]

2187. Yourha Kim, Min-Hee Kim, Sora Jeon, Jeeyoon Kim, Chankyung Kim, Ja Seong Bae, Chan Kwon Jung. 2017. Prognostic implication of histological features associated with EHD2 expression in papillary thyroid carcinoma. *PLOS ONE* **12**:3, e0174737. [Crossref]

2188. Bao-Ding Chen, Hui-Xiong Xu, Yi-Feng Zhang, Bo-Ji Liu, Le-Hang Guo, Dan-Dan Li, Chong-Ke Zhao, Xiao-Long Li, Dan Wang, Shuang-Shuang Zhao. 2017. The diagnostic performances of conventional strain elastography (SE), acoustic radiation force impulse (ARFI) imaging and point shear-wave speed (pSWS) measurement for non-calcified thyroid nodules. *Clinical Hemorheology and Microcirculation* **65**:3, 259-273. [Crossref]

2189. Brian H. H. Lang, Carlos K. H. Wong, Estella P. M. Ma. 2017. Single-session high intensity focussed ablation (HIFU) versus open cervical hemithyroidectomy for benign thyroid nodule: analysis on early efficacy, safety and voice quality. *International Journal of Hyperthermia* **120**, 1-7. [Crossref]

2190. Nicholas S. Andresen, John M. Buatti, Hamed H. Tewfik, Nitin A. Pagedar, Carryn M. Anderson, John M. Watkins. 2017. Radioiodine Ablation following Thyroidectomy for Differentiated Thyroid Cancer: Literature Review of Utility, Dose, and Toxicity
. *European Thyroid Journal* . [Crossref]

2191. Keun-Ik Yi, Soo-Geun Wang, Byung-Joo Lee, In Ju Kim, Bo Hyun Kim, Sang Soo Kim, Jin-Choon Lee. 2017. The Factors Involved in Bilateral Central Lymph Node Metastasis of Isthmus Papillary Thyroid Cancer. *Korean Journal of Otorhinolaryngology-Head and Neck Surgery* **60**:3, 125-134. [Crossref]

2192. Jen-Der Lin, Shu-Fu Lin, Szu-Tah Chen, Chuen Hsueh, Chia-Lin Li, Tzu-Chieh Chao. 2017. Long-term follow-up of papillary and follicular thyroid carcinomas with bone metastasis. *PLOS ONE* **12**:3, e0173354. [Crossref]

2193. Miguel Melo, Nuno Vicente, Mara Ventura, Adriana Gaspar Da Rocha, Paula Soares, Francisco Carrilho. 2017. The role of ablative treatment in differentiated thyroid cancer management. *Expert Review of Endocrinology & Metabolism* **12**:2, 109-116. [Crossref]

2194. Jolanta Krajewska, Ewa Paliczka-Cieslik, Barbara Jarzab. 2017. Managing tyrosine kinase inhibitors side effects in thyroid cancer. *Expert Review of Endocrinology & Metabolism* **12**:2, 117-127. [Crossref]

2195. Fish Stephanie A.. 2017. Incidental Thyroid Nodules Detected on CT, MRI, or PET-CT Correlate Well with Subsequent Ultrasound Evaluation. *Clinical Thyroidology* **29**:3, 107-109. [Citation] [Full Text] [PDF] [PDF Plus]

2196. Leung Angela M.. 2017. Active Surveillance of Small, Low-Risk Papillary Thyroid Cancers Can Be a Safe Alternative to Surgery in Selected Patients. *Clinical Thyroidology* **29**:3, 97-99. [Citation] [Full Text] [PDF] [PDF Plus]

2197. van der Wardt Robin A.L., Persoon Adrienne C.M., Klein Hesselink Esther N., Links Thera P.. 2017. Long-Term Follow-Up for Differentiated Thyroid Carcinoma Patients: A Reconsideration. *Thyroid* **27**:3, 475-476. [Citation] [Full Text] [PDF] [PDF Plus] [Supplementary Material]

2198. Eszlinger Markus, Böhme Katharina, Ullmann Maha, Görke Fabian, Siebolts Udo, Neumann Anna, Franzius Christiane, Adam Sabine, Molwitz Thomas, Landvogt Christian, Amro Bassam, Hach Anja, Feldmann Berit, Graf Dieter, Wefer Antje, Niemann Rainer, Bullmann Catharina, Klaushenke Günther, Santen Reinhard, Tönshoff Gregor, Ivancevic Velimir, Kögler Andreas, Bell Erhard, Lorenz Bernd, Kluge Gerald, Hartenstein Christoph, Ruschenburg Ilka, Paschke Ralf. 2017. Evaluation of a Two-Year Routine Application of Molecular Testing of Thyroid Fine-Needle Aspirations Using a Seven-Gene Panel in a Primary Referral Setting in Germany. *Thyroid* **27**:3, 402-411. [Abstract] [Full Text] [PDF] [PDF Plus] [Supplementary Material]

2199. Alexander Erik K., Pearce Elizabeth N., Brent Gregory A., Brown Rosalind S., Chen Herbert, Dosiou Chrysoula, Grobman William A., Laurberg Peter, Lazarus John H., Mandel Susan J., Peeters Robin P., Sullivan Scott. 2017. 2017 Guidelines of the American Thyroid Association for the Diagnosis and Management of Thyroid Disease During Pregnancy and the Postpartum. *Thyroid* **27**:3, 315-389. [Abstract] [Full Text] [PDF] [PDF Plus]

2200. Rakhlin Luba, Fish Stephanie, Tuttle R. Michael. 2017. Response to Therapy Status Is an Excellent Predictor of Pregnancy-Associated Structural Disease Progression in Patients Previously Treated for Differentiated Thyroid Cancer. *Thyroid* **27**:3, 396-401. [Abstract] [Full Text] [PDF] [PDF Plus]

Downloaded by Memorial Sloan Kettering from www.liebertpub.com at 08/14/19. For personal use only.

2201. Haymart Megan R., Pearce Elizabeth N.. 2017. How Much Should Thyroid Cancer Impact Plans for Pregnancy?. *Thyroid* **27**:3, 312-314. [Citation] [Full Text] [PDF] [PDF Plus]

2202. Seo Ki Kim, Young Jun Chai, Inhye Park, Jung-Woo Woo, Jun Ho Lee, Kyu Eun Lee, Jun-Ho Choe, Jung-Han Kim, Jee Soo Kim. 2017. Nomogram for predicting central node metastasis in papillary thyroid carcinoma. *Journal of Surgical Oncology* **115**:3, 266-272. [Crossref]

2203. Yasuhiro Ito, Mitsuyoshi Hirokawa, Akira Miyauchi, Takuya Higashiyama, Minoru Kihara, Akihiro Miya. 2017. Prognostic Significance of the Proportion of Tall Cell Components in Papillary Thyroid Carcinoma. *World Journal of Surgery* **41**:3, 742-747. [Crossref]

2204. Eun Ju Ha, Jung Hwan Baek, Jeong Hyun Lee, Jae Kyun Kim, Young Jun Choi, Tae Yon Sung, Tae Yong Kim. 2017. Complications following US-guided core-needle biopsy for thyroid lesions: a retrospective study of 6,169 consecutive patients with 6,687 thyroid nodules. *European Radiology* **27**:3, 1186-1194. [Crossref]

2205. Liang-Sen Liu, Jia Liang, Jun-Hong Li, Xue Liu, Li Jiang, Jian-Xiong Long, Yue-Ming Jiang, Zhi-Xiao Wei. 2017. The incidence and risk factors for central lymph node metastasis in cN0 papillary thyroid microcarcinoma: a meta-analysis. *European Archives of Oto-Rhino-Laryngology* **274**:3, 1327-1338. [Crossref]

2206. Seo Ki Kim, Jung-Woo Woo, Inhye Park, Jun Ho Lee, Jun-Ho Choe, Jung-Han Kim, Jee Soo Kim. 2017. Propensity score-matched analysis of robotic versus endoscopic bilateral axillo-breast approach (BABA) thyroidectomy in papillary thyroid carcinoma. *Langenbeck's Archives of Surgery* **402**:2, 243-250. [Crossref]

2207. Mehmet Hakan Korkmaz, Bülent Öcal, Güleser Saylam, Erman Çakal, Ömer Bayır, Esra Tutal, Emel Çadallı Tatar. 2017. The need of prophylactic central lymph node dissection is controversial in terms of postoperative thyroglobulin follow-up of patients with cN0 papillary thyroid cancer. *Langenbeck's Archives of Surgery* **402**:2, 235-242. [Crossref]

2208. Augustas Beiša, Mindaugas Kvietkauskas, Virgilijus Beiša, Mindaugas Stoškus, Elvyra Ostanevičiūtė, Eugenijus Jasiūnas, Laimonas Griškevičius, Kęstutis Strupas. 2017. The utility of the Bethesda category and its association with BRAF mutation in the prediction of papillary thyroid cancer stage. *Langenbeck's Archives of Surgery* **402**:2, 227-234. [Crossref]

2209. Marina S. Carvalho, Pedro W. Rosario, Gabriela F. Mourão, Maria R. Calsolari. 2017. Chronic lymphocytic thyroiditis does not influence the risk of recurrence in patients with papillary thyroid carcinoma and excellent response to initial therapy. *Endocrine* **55**:3, 954-958. [Crossref]

2210. Hyun Woo Kwon, Ann-Katharina Becker, Jin Mo Goo, Gi Jeong Cheon. 2017. FDG Whole-Body PET/MRI in Oncology: a Systematic Review. *Nuclear Medicine and Molecular Imaging* **51**:1, 22-31. [Crossref]

2211. Elke Oberhofer. 2017. Bei Risikoknoten immer eine Feinnadelbiopsie!. *MMW - Fortschritte der Medizin* **159**:S1, 18-18. [Crossref]

2212. Anna Pisani Mainini, Cristian Monaco, Lorenzo Carlo Pescatori, Chiara De Angelis, Francesco Sardanelli, Luca Maria Sconfienza, Giovanni Mauri. 2017. Image-guided thermal ablation of benign thyroid nodules. *Journal of Ultrasound* **20**:1, 11-22. [Crossref]

2213. Helen Shi, Iulianna Bobanga, Christopher R. McHenry. 2017. Are large thyroid nodules classified as benign on fine needle aspiration more likely to harbor cancer?. *The American Journal of Surgery* **213**:3, 464-466. [Crossref]

2214. Tomás Martín-Hernández, Juan José Díez Gómez, Gonzalo Díaz-Soto, Alberto Torres Cuadro, Elena Navarro González, Amelia Oleaga Alday, Marcel Sambo Salas, Jordi L. Reverter Calatayud, Iñaki Argüelles Jiménez, Isabel Mancha Doblas, Diego Fernández García, Juan Carlos Galofré. 2017. Consensus statement for use and technical requirements of thyroid ultrasound in endocrinology units. *Endocrinología, Diabetes y Nutrición (English ed.)* **64**, 23-30. [Crossref]

2215. Tomás Martín-Hernández, Juan José Díez Gómez, Gonzalo Díaz-Soto, Alberto Torres Cuadro, Elena Navarro González, Amelia Oleaga Alday, Marcel Sambo Salas, Jordi L. Reverter Calatayud, Iñaki Argüelles Jiménez, Isabel Mancha Doblas, Diego Fernández García, Juan Carlos Galofré. 2017. Criterios sobre la utilización y requerimientos técnicos de la ecografía tiroidea en los servicios de endocrinología y nutrición. *Endocrinología, Diabetes y Nutrición* **64**, 23-30. [Crossref]

2216. Hongxun Wu, Bingjie Zhang. 2017. Serum thyroglobulin or thyroglobulin in fine-needle aspiration washout of metastatic lymph nodes: which one should we have confidence in for the surveillance of thyroid carcinoma?. *Journal of the American Society of Cytopathology* **6**:2, 66-72. [Crossref]

2217. P. Oliván-Sasot, M. Falgás-Lacueva, J. García-Sánchez, V. Vera-Pinto, C. Olivas-Arroyo, P. Bello-Arques. 2017. Uso del 177Lu-DOTATATE como terapia en carcinomas de tiroides yodorrefractarios. *Revista Española de Medicina Nuclear e Imagen Molecular* **36**:2, 116-119. [Crossref]

2218. P. Oliván-Sasot, M. Falgás-Lacueva, J. García-Sánchez, V. Vera-Pinto, C. Olivas-Arroyo, P. Bello-Arques. 2017. Use of 177 Lu-dotatate in the treatment of iodine refractory thyroid carcinomas. *Revista Española de Medicina Nuclear e Imagen Molecular (English Edition)* **36**:2, 116-119. [Crossref]

2219. Juan P. Brito, Ian D. Hay. 2017. Overdiagnosis of papillary carcinoma — who benefits?. *Nature Reviews Endocrinology* **13**:3, 131-132. [Crossref]

Downloaded by Memorial Sloan Kettering from www.liebertpub.com at 08/14/19. For personal use only.

2220. Ting Xu, Jing-yu Gu, Xin-hua Ye, Shu-hang Xu, Yang Wu, Xin-yu Shao, De-zhen Liu, Wei-ping Lu, Fei Hua, Bi-min Shi, Jun Liang, Lan Xu, Wei Tang, Chao Liu, Xiao-hong Wu. 2017. Thyroid nodule sizes influence the diagnostic performance of TIRADS and ultrasound patterns of 2015 ATA guidelines: a multicenter retrospective study. *Scientific Reports* **7**:1. . [Crossref]

2221. Markus Luster, Andreas Pfestroff, Heribert Hänscheid, Frederik A. Verburg. 2017. Radioiodine Therapy. *Seminars in Nuclear Medicine* **47**:2, 126-134. [Crossref]

2222. Jennifer L. Powers, Frederick G. Strathmann, Joely A. Straseski. 2017. Thyroglobulin Antibody Screen Prior to Mass Spectrometry Provides Measurable Cost Savings and Optimal Laboratory Utilization. *American Journal of Clinical Pathology* **147**:3, 309-314. [Crossref]

2223. Zheng Liu, Jianyong Lei, Yang Liu, Yuxia Fan, Xiaoming Wang, Xiubo Lu. 2017. Preoperative predictors of lateral neck lymph node metastasis in papillary thyroid microcarcinoma. *Medicine* **96**:10, e6240. [Crossref]

2224. Ju Hye Jeong, Eun Jung Kong, Shin Young Jeong, Sang-Woo Lee, Ihn Ho Cho, Kyung Ah Chun, Jaetae Lee, Byeong-Cheol Ahn. 2017. Clinical outcomes of low-dose and high-dose postoperative radioiodine therapy in patients with intermediate-risk differentiated thyroid cancer. *Nuclear Medicine Communications* **38**:3, 228-233. [Crossref]

2225. Ismaheel O. Lawal, Nozipho E. Nyakale, Lerwine M. Harry, Thabo Lengana, Neo P. Mokgoro, Mariza Vorster, Mike M. Sathekge. 2017. Higher preablative serum thyroid-stimulating hormone level predicts radioiodine ablation effectiveness in patients with differentiated thyroid carcinoma. *Nuclear Medicine Communications* **38**:3, 222-227. [Crossref]

2226. Byeong-Cheol Ahn. 2017. Re. *Clinical Nuclear Medicine* **42**:3, 241. [Crossref]

2227. Andries H. Groen, Mariëlle S. Klein Hesselink, John T.M. Plukker, Wim J. Sluiter, Anouk N.A. van der Horst-Schrivers, Adrienne H. Brouwers, Eef G.W.M. Lentjes, Anneke C. Muller Kobold, Thera P. Links. 2017. Additional value of a high sensitive thyroglobulin assay in the follow-up of patients with differentiated thyroid carcinoma. *Clinical Endocrinology* **86**:3, 419-424. [Crossref]

2228. Mijin Kim, Young Nam Kim, Won Gu Kim, Suyeon Park, Hyemi Kwon, Min Ji Jeon, Hyeon Seon Ahn, Sin-Ho Jung, Sun Wook Kim, Won Bae Kim, Jae Hoon Chung, Young Kee Shong, Tae Hyuk Kim, Tae Yong Kim. 2017. Optimal cut-off age in the TNM Staging system of differentiated thyroid cancer: is 55 years better than 45 years?. *Clinical Endocrinology* **86**:3, 438-443. [Crossref]

2229. Soo Yeon Hahn, Jung Hee Shin, Hyun Kyung Lim, So Lyung Jung, Young Lyun Oh, In Ho Choi, Chan Kwon Jung. 2017. Preoperative differentiation between noninvasive follicular thyroid neoplasm with papillary-like nuclear features (NIFTP) and non-NIFTP. *Clinical Endocrinology* **86**:3, 444-450. [Crossref]

2230. William Clinkscales, Adrian Ong, Shaun Nguyen, Elizabeth Emily Harruff, Marion Boyd Gillespie. 2017. Diagnostic Value of RAS Mutations in Indeterminate Thyroid Nodules: Systematic Review and Meta-analysis. *Otolaryngology–Head and Neck Surgery* **156**:3, 472-479. [Crossref]

2231. Ismet Cengic, Derya Tureli, Hilal Altas, Ferhat Ozden, Onur Bugdayci, Erkin Aribal. 2017. Effects of nodule characteristics on sampling number and duration of thyroid fine-needle aspiration biopsy: size does not matter, but cystic degeneration ratio does. *Acta Radiologica* **58**:3, 286-291. [Crossref]

2232. Zahraa Al-Hilli, Veljko Strajina, Travis J. McKenzie, Geoffrey B. Thompson, David R. Farley, M. Regina Castro, Alicia Algeciras-Schimnich, Melanie L. Richards. 2017. Thyroglobulin Measurement in Fine-Needle Aspiration Improves the Diagnosis of Cervical Lymph Node Metastases in Papillary Thyroid Carcinoma. *Annals of Surgical Oncology* **24**:3, 739-744. [Crossref]

2233. Pedro Weslley Rosario, Gabriela Franco Mourão, Maria Regina Calsolari. 2017. Recombinant human TSH versus thyroid hormone withdrawal in adjuvant therapy with radioactive iodine of patients with papillary thyroid carcinoma and clinically apparent lymph node metastases not limited to the central compartment (cN1b). *Archives of Endocrinology and Metabolism* **61**:2, 167-172. [Crossref]

2234. Fernanda Vaisman. 2017. Serum positive thyroglobulin antibodies: an old problem with new questions. *Archives of Endocrinology and Metabolism* **61**:2, 103-104. [Crossref]

2235. Monica Mangoni, Carlo Gobitti, Rosa Autorino, Lorenzo Cerizza, Carlo Furlan, Renzo Mazzarotto, Fabio Monari, Gabriele Simontacchi, Federica Vianello, Michela Basso, Giuseppe Zanirato Rambaldi, Elvio Russi, Luca Tagliaferri. 2017. External Beam Radiotherapy in Thyroid Carcinoma: Clinical Review and Recommendations of the AIRO "Radioterapia Metabolica" Group. *Tumori Journal* **103**:2, 114-123. [Crossref]

2236. Feng Mao, Hui-Xiong Xu, Chong-Ke Zhao, Xiao-Wan Bo, Xiao-Long Li, Dan-Dan Li, Bo-Ji Liu, Yi-Feng Zhang, Jun-Mei Xu, Shen Qu. 2017. Thyroid imaging reporting and data system in assessment of cytological Bethesda Category III thyroid nodules. *Clinical Hemorheology and Microcirculation* **65**:2, 163-173. [Crossref]

2237. Fatma Dilek Dellal, Husniye Baser, Dilek Arpaci, Abbas Ali Tam, Didem Ozdemir, Aydan Kilicarslan, Ersin Gurkan Dumlu, Reyhan Ersoy, Bekir Cakir. 2017. Rate of Malignancy in Exophytic Thyroid Nodules. *Iranian Journal of Radiology* **In press**:In press. . [Crossref]

Downloaded by Memorial Sloan Kettering from www.liebertpub.com at 08/14/19. For personal use only.

2238. Ji-hoon Kim, Jung Hwan Baek, Jin Yong Sung, Hye Sook Min, Kyung Won Kim, J. Hun Hah, Do Joon Park, Kwang Hyun Kim, Bo Youn Cho, Dong Gyu Na. 2017. Radiofrequency ablation of low-risk small papillary thyroidcarcinoma: preliminary results for patients ineligible for surgery. *International Journal of Hyperthermia* **33**:2, 212-219. [Crossref]

2239. Shu-Fu Lin, Jen-Der Lin, Chuen Hsueh, Ting-Chao Chou, Richard J. Wong. 2017. A cyclin-dependent kinase inhibitor, dinaciclib in preclinical treatment models of thyroid cancer. *PLOS ONE* **12**:2, e0172315. [Crossref]

2240. Stig Andersen, Paneeraq Noahsen, Louise Westergaard, Peter Laurberg. 2017. Reliability of thyroglobulin in serum compared with urinary iodine when assessing individual and population iodine nutrition status. *British Journal of Nutrition* **117**:3, 441-449. [Crossref]

2241. Shamil D Cooray, Duncan J Topliss. 2017. The management of metastatic radioiodine-refractory differentiated thyroid cancer requires an integrated approach including both directed and systemic therapies. *Endocrinology, Diabetes & Metabolism Case Reports* . [Crossref]

2242. Livhits Masha J., Yeh Michael W.. 2017. Age Cutoff of 45 Years May Not Be Appropriate for Papillary Thyroid Cancer Staging. *Clinical Thyroidology* **29**:2, 52-54. [Citation] [Full Text] [PDF] [PDF Plus]

2243. Biermann Martin. 2017. Recurrence Rates in Patients with Intermediate-Risk Differentiated Thyroid Cancer Are Similar after Low-Dose and High-Dose Radioiodine Ablation in a Korean Series. *Clinical Thyroidology* **29**:2, 55-57. [Citation] [Full Text] [PDF] [PDF Plus]

2244. Kim Seo Ki, Park Inhye, Woo Jung-Woo, Lee Jun Ho, Choe Jun-Ho, Kim Jung-Han, Kim Jee Soo. 2017. Predicting Factors for Bilaterality in Papillary Thyroid Carcinoma with Tumor Size <4 cm. *Thyroid* **27**:2, 207-214. [Abstract] [Full Text] [PDF] [PDF Plus]

2245. Lee Seul Gi, Lee Woo Kyung, Lee Hye Sun, Moon Jieun, Lee Cho Rok, Kang Sang Wook, Jeong Jong Ju, Nam Kee-Hyun, Chung Woong Youn, Jo Young Suk, Lee Jandee. 2017. Practical Performance of the 2015 American Thyroid Association Guidelines for Predicting Tumor Recurrence in Patients with Papillary Thyroid Cancer in South Korea. *Thyroid* **27**:2, 174-181. [Abstract] [Full Text] [PDF] [PDF Plus] [Supplementary Material]

2246. Lubitz Carrie C., De Gregorio Lucia, Fingeret Abbey L., Economopoulos Konstantinos P., Termezawi Diana, Hassan Mursal, Parangi Sareh, Stephen Antonia E., Halpern Elkan F., Donelan Karen, Swan J. Shannon. 2017. Measurement and Variation in Estimation of Quality of Life Effects of Patients Undergoing Treatment for Papillary Thyroid Carcinoma. *Thyroid* **27**:2, 197-206. [Abstract] [Full Text] [PDF] [PDF Plus]

2247. Corrêa Nilton Lavatori, de Sá Lidia Vasconcellos, de Mello Rossana Corbo Ramalho. 2017. Estimation of Second Primary Cancer Risk After Treatment with Radioactive Iodine for Differentiated Thyroid Carcinoma. *Thyroid* **27**:2, 261-270. [Abstract] [Full Text] [PDF] [PDF Plus]

2248. Bryan R. Haugen. 2017. 2015 American Thyroid Association Management Guidelines for Adult Patients with Thyroid Nodules and Differentiated Thyroid Cancer: What is new and what has changed?. *Cancer* **123**:3, 372-381. [Crossref]

2249. Pierpaolo Trimboli, Franco Fulciniti, Valentina Zilioli, Luca Ceriani, Luca Giovanella. 2017. Accuracy of international ultrasound risk stratification systems in thyroid lesions cytologically classified as indeterminate. *Diagnostic Cytopathology* **45**:2, 113-117. [Crossref]

2250. You-Bin Lee, Yoon Young Cho, Ju Young Jang, Tae Hyuk Kim, Hye Won Jang, Jae Hoon Chung, Young Lyun Oh, Sun Wook Kim. 2017. Current status and diagnostic values of the Bethesda system for reporting thyroid cytopathology in a papillary thyroid carcinoma-prevalent area. *Head & Neck* **39**:2, 269-274. [Crossref]

2251. Young Jun Choi, Jung Hwan Baek, Chong Hyun Suh, Woo Hyun Shim, Boseul Jeong, Jae Kyun Kim, Dong Eun Song, Tae Yong Kim, Ki-Wook Chung, Jeong Hyun Lee. 2017. Core-needle biopsy versus repeat fine-needle aspiration for thyroid nodules initially read as atypia/follicular lesion of undetermined significance. *Head & Neck* **39**:2, 361-369. [Crossref]

2252. Amir Sabet, Ina Binse, Semih Dogan, Andrea Koch, Sandra J. Rosenbaum-Krumme, Hans-Jürgen Biersack, Kim Biermann, Samer Ezziddin. 2017. Distinguishing synchronous from metachronous manifestation of distant metastases: a prognostic feature in differentiated thyroid carcinoma. *European Journal of Nuclear Medicine and Molecular Imaging* **44**:2, 190-195. [Crossref]

2253. Savvas Frangos, Ioannis P. Iakovou, Robert J. Marlowe, Nicolaos Eftychiou, Loukia Patsali, Anna Vanezi, Androulla Savva, Vassilis Mpalaris, Evanthia I. Giannoula. 2017. Acknowledging gray areas: 2015 vs. 2009 American Thyroid Association differentiated thyroid cancer guidelines on ablating putatively low-intermediate-risk patients. *European Journal of Nuclear Medicine and Molecular Imaging* **44**:2, 185-189. [Crossref]

2254. Frederik A. Verburg, Markus Luster, Luca Giovanella. 2017. Adjuvant post-operative I-131 therapy in differentiated thyroid carcinoma: are the 2015 ATA guidelines an exact science or a dark art?. *European Journal of Nuclear Medicine and Molecular Imaging* **44**:2, 183-184. [Crossref]

Downloaded by Memorial Sloan Kettering from www.liebertpub.com at 08/14/19. For personal use only.

2255. Soo-Yeon Kim, Hye Sun Lee, Jieun Moon, Eun-Kyung Kim, Hee Jung Moon, Jung Hyun Yoon, Jin Young Kwak. 2017. Fine-needle aspiration versus core needle biopsy for diagnosis of thyroid malignancy and neoplasm: a matched cohort study. *European Radiology* **27**:2, 801-811. [Crossref]

2256. T. Ben Ghachem, I. Yeddes, I. Meddeb, A. Bahloul, A. Mhiri, I. Slim, M. F. Ben Slimene. 2017. A comparison of low versus high radioiodine administered activity in patients with low-risk differentiated thyroid cancer. *European Archives of Oto-Rhino-Laryngology* **274**:2, 655-660. [Crossref]

2257. Jung-Woo Woo, Seo Ki Kim, Inhye Park, Jun Ho Choe, Jung-Han Kim, Jee Soo Kim. 2017. A novel robotic surgical technique for thyroid surgery: bilateral axillary approach (BAA). *Surgical Endoscopy* **31**:2, 667-672. [Crossref]

2258. Amit Tirosh, Ilan Shimon. 2017. Complications of acromegaly: thyroid and colon. *Pituitary* **20**:1, 70-75. [Crossref]

2259. Sebastiano Filetti, Paul W. Ladenson, Marco Biffoni, Maria Giuseppina D'Ambrosio, Laura Giacomelli, Stefania Lopatriello. 2017. The true cost of thyroid surgery determined by a micro-costing approach. *Endocrine* **55**:2, 519-529. [Crossref]

2260. Wen-Wen Yue, Shu-Rong Wang, Feng Lu, Li-Ping Sun, Le-Hang Guo, Yong-Lin Zhang, Xiao-Long Li, Hui-Xiong Xu. 2017. Radiofrequency ablation vs. microwave ablation for patients with benign thyroid nodules: a propensity score matching study. *Endocrine* **55**:2, 485-495. [Crossref]

2261. Brian Hung-Hin Lang, Tony W. H. Shek, Arnold L. H Wu, Koon Yat Wan. 2017. The total number of tissue blocks per centimetre of tumor significantly correlated with the risk of distant metastasis in patients with minimally invasive follicular thyroid carcinoma. *Endocrine* **55**:2, 496-502. [Crossref]

2262. Ahmed Deniwar, AbdulRahman Y. Hammad, Daniah Bu Ali, Nuha Alsaleh, Maha Lahlouh, Andrew B. Sholl, Krzysztof Moroz, Rizwan Aslam, Tina Thethi, Emad Kandil. 2017. Optimal timing for a repeat fine-needle aspiration biopsy of thyroid nodule following an initial nondiagnostic fine-needle aspiration. *The American Journal of Surgery* **213**:2, 433-437. [Crossref]

2263. Anne-Laure Giraudet, David Taïeb. 2017. PET imaging for thyroid cancers: Current status and future directions. *Annales d'Endocrinologie* **78**:1, 38-42. [Crossref]

2264. A.A. Elsayed, C. Murdoch, S. Murray, K. Bashir. 2017. Can thyroid surgery be decided based on ultrasonographic findings, irrespective of cytopathological findings? Five-year retrospective study in a district general hospital. *Clinical Radiology* **72**:2, 170-174. [Crossref]

2265. Miguel Paja Fano, Aitziber Ugalde Olano, Elena Fuertes Thomas, Amelia Oleaga Alday. 2017. Immunohistochemical detection of the BRAF V600E mutation in papillary thyroid carcinoma. Evaluation against real-time polymerase chain reaction. *Endocrinología, Diabetes y Nutrición (English ed.)* **64**:2, 75-81. [Crossref]

2266. Miguel Paja Fano, Aitziber Ugalde Olano, Elena Fuertes Thomas, Amelia Oleaga Alday. 2017. Detección inmunohistoquímica de la mutación BRAF V600E en el carcinoma papilar de tiroides. Evaluación frente a la reacción en cadena de la polimerasa en tiempo real. *Endocrinología, Diabetes y Nutrición* **64**:2, 75-81. [Crossref]

2267. Sayaka Kuba, Kosho Yamanouchi, Naomi Hayashida, Shigeto Maeda, Toshiyuki Adachi, Chika Sakimura, Fusako Kawakami, Hiroshi Yano, Megumi Matsumoto, Ryota Otsubo, Shuntaro Sato, Hikaru Fujioka, Tamotsu Kuroki, Takeshi Nagayasu, Susumu Eguchi. 2017. Total thyroidectomy versus thyroid lobectomy for papillary thyroid cancer: Comparative analysis after propensity score matching: A multicenter study. *International Journal of Surgery* **38**, 143-148. [Crossref]

2268. Ashok R. Shaha. 2017. Lobectomy vs total thyroidectomy – Have we resolved the debate?. *International Journal of Surgery* **38**, 141-142. [Crossref]

2269. Stavroula A. Paschou, Andromachi Vryonidou, Dimitrios G. Goulis. 2017. Thyroid nodules: A guide to assessment, treatment and follow-up. *Maturitas* **96**, 1-9. [Crossref]

2270. Abbas Ali Tam, Didem Özdemir, Neslihan Çuhacı, Hüsniye Başer, Ahmet Dirikoç, Cevdet Aydın, Aylin Kılıç Yazgan, Reyhan Ersoy, Bekir Çakır. 2017. Can ratio of the biggest tumor diameter to total tumor diameter be a new parameter in the differential diagnosis of agressive and favorable multifocal papillary thyroid microcarcinoma?. *Oral Oncology* **65**, 1-7. [Crossref]

2271. Young Chan Lee, Se Young Na, Gi Cheol Park, Ju Hyun Han, Seung Woo Kim, Young Gyu Eun. 2017. Occult lymph node metastasis and risk of regional recurrence in papillary thyroid cancer after bilateral prophylactic central neck dissection: A multi-institutional study. *Surgery* **161**:2, 465-471. [Crossref]

2272. Christopher R. McHenry, Iuliana D. Bobanga. 2017. Accurate terminology and definitions are essential in clinical research. *Surgery* **161**:2, 475-476. [Crossref]

2273. Jahae Kim, Sang-Geon Cho, Sae-Ryung Kang, Seong Young Kwon, Dong-Hyeok Cho, Jin-Seong Cho, Ho-Chun Song. 2017. Preparation for radioactive iodine therapy is not a risk factor for the development of hyponatremia in thyroid cancer patients. *Medicine* **96**:5, e6004. [Crossref]

Downloaded by Memorial Sloan Kettering from www.liebertpub.com at 08/14/19. For personal use only.

2274. Wei Li, Danyang Sun, Hui Ming, Guizhi Zhang, Jian Tan. 2017. A rare case report of very low thyroglobulin and a negative whole-body scan in a patient with a solid variant of papillary thyroid carcinoma with distant metastases. *Medicine* **96**:7, e6086. [Crossref]

2275. Jinjing Zhong, Jianyong Lei, Ke Jiang, Zhihui Li, Rixiang Gong, Jingqiang Zhu. 2017. Synchronous papillary thyroid carcinoma and breast ductal carcinoma. *Medicine* **96**:7, e6114. [Crossref]

2276. Brian H.-H. Lang, Tony W.H. Shek, Koon Y. Wan. 2017. The significance of unrecognized histological high-risk features on response to therapy in papillary thyroid carcinoma measuring 1-4 cm: implications for completion thyroidectomy following lobectomy. *Clinical Endocrinology* **86**:2, 236-242. [Crossref]

2277. Maria Regina Marrocos Machado, Marcos Roberto Tavares, Carlos Alberto Buchpiguel, Maria Cristina Chammas. 2017. Ultrasonographic Evaluation of Cervical Lymph Nodes in Thyroid Cancer. *Otolaryngology–Head and Neck Surgery* **156**:2, 263-271. [Crossref]

2278. Jee Hyun An, Kee-Ho Song, Dong-Lim Kim, Suk Kyeong Kim. 2017. Effects of thyroid hormone withdrawal on metabolic and cardiovascular parameters during radioactive iodine therapy in differentiated thyroid cancer. *Journal of International Medical Research* **45**:1, 38-50. [Crossref]

2279. Fadi Nabhan, Matthew D Ringel. 2017. Thyroid nodules and cancer management guidelines: comparisons and controversies. *Endocrine-Related Cancer* **24**:2, R13-R26. [Crossref]

2280. Luca Morandi, Alberto Righi, Francesca Maletta, Paola Rucci, Fabio Pagni, Marco Gallo, Sabrina Rossi, Leonardo Caporali, Anna Sapino, Ricardo V Lloyd, Sofia Asioli. 2017. Somatic mutation profiling of hobnail variant of papillary thyroid carcinoma. *Endocrine-Related Cancer* **24**:2, 107-117. [Crossref]

2281. Angelica Schmidt, Laura Iglesias, Michele Klain, Fabián Pitoia, Martin J. Schlumberger. 2017. Radioactive iodine-refractory differentiated thyroid cancer: an uncommon but challenging situation. *Archives of Endocrinology and Metabolism* **61**:1, 81-89. [Crossref]

2282. Ishita Singh, Athanasios Bikas, Carlos A. Garcia, Sameer Desale, Leonard Wartofsky, Kenneth D. Burman. 2017. 18 F-FDG-PET SUV AS A PROGNOSTIC MARKER OF INCREASING SIZE IN THYROID CANCER TUMORS. *Endocrine Practice* **23**:2, 182-189. [Crossref]

2283. Jawairia Shakil, Mohammed Z. Ansari, Jett Brady, Jiaqiong Xu, Richard J. Robbins. 2017. LOWER RATES OF RESIDUAL/RECURRENT DISEASE IN PATIENTS WITH INCIDENTALLY DISCOVERED THYROID CARCINOMA. *Endocrine Practice* **23**:2, 163-169. [Crossref]

2284. David J. S. Becker-Weidman, Neil Malhotra, David F. Reilly, Naveen Selvam, Laurence Parker, Levon N. Nazarian. 2017. Imaging Surveillance in Patients After a Benign Fine-Needle Aspiration Biopsy of the Thyroid: Associated Cost and Incidence of Subsequent Cancer. *American Journal of Roentgenology* **208**:2, 358-361. [Crossref]

2285. Jennifer E. Lim-Dunham, Iclal Erdem Toslak, Khalid Alsabban, Amany Aziz, Brendan Martin, Gokcan Okur, Katherine C. Longo. 2017. Ultrasound risk stratification for malignancy using the 2015 American Thyroid Association Management Guidelines for Children with Thyroid Nodules and Differentiated Thyroid Cancer. *Pediatric Radiology* **86**. . [Crossref]

2286. Pierpaolo Trimboli, Federica D'Aurizio, Renato Tozzoli, Luca Giovanella. 2017. Measurement of thyroglobulin, calcitonin, and PTH in FNA washout fluids. *Clinical Chemistry and Laboratory Medicine (CCLM)* **55**:7. . [Crossref]

2287. Marilena Celano, Chiara Mignogna, Francesca Rosignolo, Marialuisa Sponziello, Michelangelo Iannone, Saverio Massimo Lepore, Giovanni Enrico Lombardo, Valentina Maggisano, Antonella Verrienti, Stefania Bulotta, Cosimo Durante, Carla Di Loreto, Giuseppe Damante, Diego Russo. 2017. Expression of YAP1 in aggressive thyroid cancer. *Endocrine* **163**. . [Crossref]

2288. Søren Feddersen, Lars Bastholt, Susanne M Pedersen. 2017. Stabilization of circulating thyroglobulin mRNA transcripts in patients treated for differentiated thyroid carcinoma. *Annals of Clinical Biochemistry* **83**, 000456321667153. [Crossref]

2289. Waddah Katrangi, Stephan K.G. Grebe, Alicia Algeciras-Schimnich. 2017. Analytical and clinical performance of thyroglobulin autoantibody assays in thyroid cancer follow-up. *Clinical Chemistry and Laboratory Medicine (CCLM)*, ahead of print. [Crossref]

2290. Hye In Kim, Tae Hyuk Kim, Hosu Kim, Young Nam Kim, Hye Won Jang, Jae Hoon Chung, Seong Mi Moon, Byung Woo Jhun, Hyun Lee, Won-Jung Koh, Sun Wook Kim. 2017. Effect of Rifampin on Thyroid Function Test in Patients on Levothyroxine Medication. *PLOS ONE* **12**:1, e0169775. [Crossref]

2291. Pierpaolo Trimboli, Valentina Zilioli, Mauro Imperiali, Luca Giovanella. 2017. Thyroglobulin autoantibodies before radioiodine ablation predict differentiated thyroid cancer outcome. *Clinical Chemistry and Laboratory Medicine (CCLM)*, ahead of print. [Crossref]

2292. Biermann Martin. 2017. Lymph Node Mapping with Ultrasound Is Highly Useful in the Preoperative Workup of Patients with Thyroid Cancer. *Clinical Thyroidology* **29**:1, 16-18. [Citation] [Full Text] [PDF] [PDF Plus]

Downloaded by Memorial Sloan Kettering from www.liebertpub.com at 08/14/19. For personal use only.

2293. Tomoda Chisato, Sugino Kiminori, Ito Koichi. 2017. Bleeding of Papillary Thyroid Recurrent Carcinoma in the Parapharyngeal and Nasopharyngeal Spaces Is Markedly Improved After Treatment with Lenvatinib. *Clinical Thyroidology* **29**:1, 35-37. [Citation] [Full Text] [PDF] [PDF Plus]

2294. Pearce Elizabeth N.. 2017. Thyroid Cancer Overdiagnosis Is a Result of Screening Programs in South Korea. *Clinical Thyroidology* **29**:1, 8-10. [Citation] [Full Text] [PDF] [PDF Plus]

2295. Lang Brian Hung-Hin, Shek Tony W.H., Chan Angel On-Kei, Lo Chung-Yau, Wan Koon Yat. 2017. Significance of Size of Persistent/Recurrent Central Nodal Disease on Surgical Morbidity and Response to Therapy in Reoperative Neck Dissection for Papillary Thyroid Carcinoma. *Thyroid* **27**:1, 67-73. [Abstract] [Full Text] [PDF] [PDF Plus]

2296. Najafian Alireza, Noureldine Salem, Azar Faris, Atallah Chady, Trinh Gina, Schneider Eric B., Tufano Ralph P., Zeiger Martha A.. 2017. RAS Mutations, and RET/PTC and PAX8/PPAR-gamma Chromosomal Rearrangements Are Also Prevalent in Benign Thyroid Lesions: Implications Thereof and A Systematic Review. *Thyroid* **27**:1, 39-48. [Abstract] [Full Text] [PDF] [PDF Plus] [Supplementary Material]

2297. Merten Michele M., Castro M. Regina, Zhang Jun, Durski Jolanta, Ryder Mabel. 2017. Examining the Role of Preoperative Positron Emission Tomography/Computerized Tomography in Combination with Ultrasonography in Discriminating Benign from Malignant Cytologically Indeterminate Thyroid Nodules. *Thyroid* **27**:1, 95-102. [Abstract] [Full Text] [PDF] [PDF Plus]

2298. Wong Kai-Pun, Au Kin-Pan, Lam Shi, Lang Brian Hung-Hin. 2017. Lessons Learned After 1000 Cases of Transcutaneous Laryngeal Ultrasound (TLUSG) with Laryngoscopic Validation: Is There a Role of TLUSG in Patients Indicated for Laryngoscopic Examination Before Thyroidectomy?. *Thyroid* **27**:1, 88-94. [Abstract] [Full Text] [PDF] [PDF Plus]

2299. Thibaut Raguin, Olivier Schneegans, Jean-François Rodier, Pierre-Philippe Volkmar, Eric Sauleau, Christian Debry, Guillaume Debonnecaze, Jean-Pierre Ghnassia, Agnès Dupret-Bories. 2017. Value of fine-needle aspiration in evaluating large thyroid nodules. *Head & Neck* **39**:1, 32-36. [Crossref]

2300. Marin Prpic, Davor Kust, Ivan Kruljac, Lora Stanka Kirigin, Tomislav Jukic, Nina Dabelic, Ante Bolanca, Zvonko Kusic. 2017. Prediction of radioactive iodine remnant ablation failure in patients with differentiated thyroid cancer: A cohort study of 740 patients. *Head & Neck* **39**:1, 109-115. [Crossref]

2301. Gregory W. Randolph, Dipti Kamani. 2017. Intraoperative electrophysiologic monitoring of the recurrent laryngeal nerve during thyroid and parathyroid surgery: Experience with 1,381 nerves at risk. *The Laryngoscope* **127**:1, 280-286. [Crossref]

2302. Marta E. Heilbrun, Justin Cramer, Brian E. Chapman. Structured Reporting: The Value Concept for Radiologists 99-107. [Crossref]

2303. Rossella Elisei, Laura Agate, Sara Mazzarri, Valeria Bottici, Federica Guidoccio, Eleonora Molinaro, Giuseppe Boni, Marco Ferdeghini, Giuliano Mariani. Diagnostic Applications of Nuclear Medicine: Thyroid Tumors 545-583. [Crossref]

2304. Federica Orsini, Sara Mazzarri, Erinda Puta, Federica Guidoccio, Alice Lorenzoni, Giuliano Mariani. Radiopharmaceuticals for Therapy 99-113. [Crossref]

2305. Rossella Elisei, Laura Agate, Sara Mazzarri, Valeria Bottici, Federica Guidoccio, Eleonora Molinaro, Giuseppe Boni, Marco Ferdeghini, Giuliano Mariani. Radionuclide Therapy of Thyroid Tumors 1197-1241. [Crossref]

2306. Giovanni Ceccarini, Ferruccio Santini, Paolo Vitti. Tests of Thyroid Function 1-23. [Crossref]

2307. Steen Joop Bonnema, Laszlo Hegedüs. Nontoxic Goiter 1-38. [Crossref]

2308. Markus Eszlinger, Laszlo Hegedüs, Ralf Paschke. Thyroid Nodule 1-38. [Crossref]

2309. Willy Marcos Valencia, Hermes Florez. Endocrinology 269-282. [Crossref]

2310. R. Michael Tuttle, Lilah F. Morris, Bryan R. Haugen, Jatin P. Shah, Julie A. Sosa, Eric Rohren, Rathan M. Subramaniam, Jennifer L. Hunt, Nancy D. Perrier. 881. [Crossref]

2311. Megan R. Haymart, Nazanene H. Esfandiari. Incidence and Epidemiology 1-10. [Crossref]

2312. Snehal G. Patel, Linwah Yip. Surgical Intervention for Indeterminate Thyroid Nodules 147-162. [Crossref]

2313. Heather Stuart, Steven Rodgers, Janice L. Pasieka. Staging for Papillary Thyroid Cancer 165-185. [Crossref]

2314. Kathryn E. Coan, Tracy S. Wang. Importance of Surgeon Experience in the Surgical Management of Thyroid Cancer 187-198. [Crossref]

2315. Scott A. Rivkees, Catherine A. Dinauer. The Pediatric Thyroid Nodule and Papillary Thyroid Cancer Management 199-216. [Crossref]

2316. Jennifer R. Cracchiolo, Ashok R. Shaha. Papillary Thyroid Microcarcinomas 219-230. [Crossref]

2317. Jonathan Mark, David L. Steward. Surgical Management of Low-Risk Papillary Thyroid Cancer 231-240. [Crossref]

Downloaded by Memorial Sloan Kettering from www.liebertpub.com at 08/14/19. For personal use only.

2318. Joy C. Chen, Christopher R. McHenry. Management of Central Compartment Lymph Nodes in Patients with Papillary Thyroid Carcinoma 241-254. [Crossref]

2319. J. D. Pasternak, W. T. Shen. The Management of the Persistent and Recurrent Cervical Lymph Node Metastases 255-262. [Crossref]

2320. Trevor E. Angell, Erik K. Alexander. Thyroid Nodular Disease and Thyroid Cancer During Pregnancy 263-271. [Crossref]

2321. Rebecca L. Weiss, Angela M. Leung. Initial Radioiodine Ablation 297-313. [Crossref]

2322. Naykky Singh Ospina, M. Regina Castro. Treatment of Recurrent/Metastatic Thyroid Cancer with Radioactive Iodine 315-329. [Crossref]

2323. Jennifer M. Perkins. Surveillance of Treated Thyroid Cancer Patients and Thyroid Hormone Replacement and Suppression 331-350. [Crossref]

2324. Beatriz Olson. Integrative Approaches to Patients Undergoing Thyroid Surgery 351-376. [Crossref]

2325. Naris Nilubol, Xavier Keutgen, Electron Kebebew. Follicular and Hürthle Cell Carcinoma 379-393. [Crossref]

2326. Ming Yann Lim, Mark Zafereo, Elizabeth Grubbs. Locally Advanced Differentiated Thyroid Cancer 395-417. [Crossref]

2327. James D. Brierley, Meredith E. Giuliani, Richard W. Tsang. External Beam Radiation for Locally Advanced and Metastatic Differentiated Thyroid Cancer 419-431. [Crossref]

2328. Dwight Owen, Manisha H. Shah. Systemic Therapy for Advanced Metastatic Thyroid Cancer 433-450. [Crossref]

2329. Jennifer A Sipos. Ultrasound of the Thyroid and Soft Tissues of the Neck 23-45. [Crossref]

2330. Denise Carneiro-Pla. Thyroid Nodule Biopsy 47-58. [Crossref]

2331. Idris Tolgay Ocal, Mohiedean Ghofrani. The Bethesda System for Reporting Thyroid Cytopathology (BSRTC) 59-92. [Crossref]

2332. James X. Wu, Masha Livhits, Ali Sepahdari, Michael W. Yeh. Cross-Sectional Imaging for the Evaluation of Thyroid Nodules and Cancer 93-102. [Crossref]

2333. Elizabeth H. Holt. Surveillance of Benign Thyroid Nodules 103-111. [Crossref]

2334. Marelle Yehuda, Elizabeth O. Westfall, Mira Milas, Andrew G. Gianoukakis. Thyroid and Parathyroid Ultrasound: Comprehensive and Problem-Focused Point-of-Care Utilization in Clinical Practice 3-10. [Crossref]

2335. Jill E. Langer. Feature Illustration: Echogenicity, Composition, and Shape 87-94. [Crossref]

2336. William D. Middleton. Feature Illustration: Vascularity 113-127. [Crossref]

2337. Susan J. Mandel. The Application of Sonographic Patterns to Risk Stratification of Thyroid Nodules 131-142. [Crossref]

2338. Yufei Chen, Sareh Parangi. Challenges in Pattern Recognition: Navigating Assessment of Thyroid Features and the Subjectivity of Ultrasound Interpretation 143-151. [Crossref]

2339. Jennifer A. Sipos. Rationale for the Evaluation of Cervical Lymph Nodes in the Setting of Thyroid Cancer 197-206. [Crossref]

2340. Ilya Likhterov, Mark L. Urken. Key Components of a Comprehensive Thyroid and Parathyroid Ultrasound Report 11-16. [Crossref]

2341. Marlon A. Guerrero. Sonographic Appearance of Abnormal Cervical Lymph Nodes in the Preoperative and Reoperative/"Empty" Neck: A Surgeon's Perspective 215-225. [Crossref]

2342. Robert A. Levine, John Interlandi. The Procedure of Ultrasound-Guided Percutaneous Biopsy of Thyroid and Cervical Lymph Nodes: Technical Steps, Pitfalls, and Pearls 309-321. [Crossref]

2343. Nicole A. Massoll. The Preparation of Biopsy Specimens for Routine and Molecular Cytology: Technical Steps, Pearls, and Pitfalls 323-329. [Crossref]

2344. P. Ryan Hungerford, John Woody Sistrunk. Pathways to Thyroid and Parathyroid Ultrasound Certification 17-23. [Crossref]

2345. Vikram D. Krishnamurthy, Eren Berber, Joyce J. Shin. Intraoperative Use of Ultrasound in Thyroid, Parathyroid, and Cervical Lymph Node Surgery 361-365. [Crossref]

2346. Petros Tsamatropoulos, Andrea Frasoldati. Alcohol Ablation of Thyroid and Parathyroid Lesions and Lymph Nodes 367-378. [Crossref]

2347. Petros Tsamatropoulos, Roberto Valcavi. HIFU and RFA Ablation for Thyroid and Parathyroid Disease 379-390. [Crossref]

2348. Jill E. Langer. Ultrasound for Radiologists: What I Learned from Lifetime Practice 421-425. [Crossref]

2349. Renee K. Dversdal, Teresa Wu. Ultrasound for Primary Care Practitioners and Emergency Medicine Physicians 427-435. [Crossref]

2350. Dina Elaraj. 3D Ultrasound 59-66. [Crossref]

Downloaded by Memorial Sloan Kettering from www.liebertpub.com at 08/14/19. For personal use only.

2351. Manish Dhyani, Changtian Li, Anthony E. Samir, Antonia E. Stephen. Elastography: Applications and Limitations of a New Technology 67-73. [Crossref]
2352. Vito Cantisani, Hektor Grazhdani, Emanuele David, Christoph Frank Dietrich, Maija Radzina, Antonio Pio Masciotra, Chandra Bortolotto, Fabrizio Calliada, Ferdinando D'Ambrosio. Thyroid Gland 161-181. [Crossref]
2353. Wayne Koch, Eleni M. Rettig, Daniel Q. Sun. Head and Neck Essentials in Global Surgery 443-474. [Crossref]
2354. Nisar Zaidi, Eren Berber. Endocrine Surgery in Cirrhotic Patients 285-300. [Crossref]
2355. Milan Halenka, Zdeněk Fryšák. Multinodular Goiter 119-128. [Crossref]
2356. Milan Halenka, Zdeněk Fryšák. Lesions with Intermediate Suspicion of Malignancy 145-153. [Crossref]
2357. Milan Halenka, Zdeněk Fryšák. Follicular Thyroid Carcinoma 155-163. [Crossref]
2358. Milan Halenka, Zdeněk Fryšák. Papillary Thyroid Carcinoma 165-245. [Crossref]
2359. Milan Halenka, Zdeněk Fryšák. Medullary Thyroid Carcinoma 247-256. [Crossref]
2360. Milan Halenka, Zdeněk Fryšák. Percutaneous Ethanol Injection Therapy 365-382. [Crossref]
2361. Milan Halenka, Zdeněk Fryšák. Ultrasound-Guided Fine-Needle Aspiration Biopsy (US-FNAB) 383-392. [Crossref]
2362. Milan Halenka, Zdeněk Fryšák. Solid Nodule 93-103. [Crossref]
2363. Milan Halenka, Zdeněk Fryšák. Complex Nodule 105-117. [Crossref]
2364. Benjamin Schmidt, Louise Davies. The Rising Incidence of Thyroid Cancer: Contributions from Healthcare Practice and Biologic Risk Factors 1-13. [Crossref]
2365. Melanie Goldfarb, Trevan Fischer. Pediatric Thyroid Cancer 125-133. [Crossref]
2366. Yasuhiro Ito, Akira Miyauchi, Hitomi Oda. Active Surveillance as the Initial Course of Action in Low-Risk Papillary Microcarcinoma 135-141. [Crossref]
2367. David T. Hughes, Paul G. Gauger. Surgical Treatment of Papillary and Follicular Thyroid Cancer 143-152. [Crossref]
2368. Nicole Zern, Mark Sywak. The Debate for Elective Lymph Node Dissection in Papillary Thyroid Carcinoma 171-179. [Crossref]
2369. Iain J. Nixon, Ashok R. Shaha. The Debate against Elective Lymph Node Dissection in Papillary Thyroid Carcinoma 181-188. [Crossref]
2370. Jonathan Black, Lawrence Kim. Differentiated Thyroid Cancer: Prognostic and Risk Assessment Systems 189-204. [Crossref]
2371. Nicole M. Iniguez-Ariza, Suneetha Kaggal, Ian D. Hay. Role of Radioactive Iodine for Remnant Ablation in Patients with Papillary Thyroid Cancer 205-222. [Crossref]
2372. Jennifer M. Perkins. Considerations in Thyrotropin-Stimulating Hormone Suppression in Individuals with Differentiated Thyroid Cancer 223-232. [Crossref]
2373. Jorge Daniel Oldan, Jenny Hoang, Terry Zekon Wong. Imaging Modalities in the Diagnosis of Recurrent or Metastatic Thyroid Cancer 233-254. [Crossref]
2374. Kristin L. Long, Nancy D. Perrier. Operative Treatment of Recurrent or Metastatic Disease 255-262. [Crossref]
2375. Naifa Lamki Busaidy, Tania Jaber. Local and Systemic Treatment of Unresectable Disease 263-280. [Crossref]
2376. Deepa Kirk. Surveillance Strategies After Initial Treatment of Differentiated Thyroid Cancer 281-311. [Crossref]
2377. Jennifer Rosen, Vardan Papoian. Evaluation of a Thyroid Nodule 29-35. [Crossref]
2378. Laura N. Purcell, Paula D. Strassle, Jen Jen Yeh. Molecular Diagnostic Approaches and Their Clinical Utility 65-77. [Crossref]
2379. Cord Sturgeon, Dina Elaraj, Anthony Yang. Clinical Presentation and Diagnosis of Papillary Thyroid Cancer 79-91. [Crossref]
2380. Reese W. Randle, Rebecca S. Sippel. Clinical Presentation and Diagnosis of Follicular Thyroid Cancer 93-103. [Crossref]
2381. Benjamin Gigliotti, Sareh Parangi. Clinical Presentation and Diagnosis of Hürthle Cell Thyroid Cancer 105-114. [Crossref]
2382. Shirley Yan, Shelby Holt, Saad Khan, Fiemu Nwariaku. High-Risk and Poorly Differentiated Thyroid Cancer 115-123. [Crossref]
2383. Doina Piciu. Hybrid Positron Emission Tomography in Endocrinology 237-287. [Crossref]
2384. Doina Piciu, Patriciu Achimaș-Cadariu, Alexandru Irimie, Andra Piciu. The Thyroid Gland 61-177. [Crossref]
2385. Mohammad Amin Tabatabaiefar, Abbas Moridnia, Laleh Shariati. Cancers of the Endocrine System 499-530. [Crossref]
2386. Dehua Chen, Cheng Shi, Mei Wang, Qiao Pan. Thyroid Nodule Classification Using Hierarchical Recurrent Neural Network with Multiple Ultrasound Reports 765-773. [Crossref]
2387. F Billmann. Euthyreote Knotenstruma (inklusive Basedow und Rezidivstruma) 15-34. [Crossref]
2388. Won Woo Lee, Yong-Whee Bahk. 18F-NaF PET/CT in Bone and Joint Diseases 539-552. [Crossref]

Downloaded by Memorial Sloan Kettering from www.liebertpub.com at 08/14/19. For personal use only.

2389. Zeng Gui Wu, Xing Qiang Yan, Ru Si Su, Zhao Sheng Ma, Bo Jian Xie, Fei Lin Cao. 2017. How Many Contralateral Carcinomas in Patients with Unilateral Papillary Thyroid Microcarcinoma are Preoperatively Misdiagnosed as Benign?. *World Journal of Surgery* **41**:1, 129-135. [Crossref]

2390. C. R. McHenry, H. Shi. 2017. The Extent of Surgery for Papillary Thyroid Microcarcinoma: The Controversy Continues. *World Journal of Surgery* **41**:1, 136-137. [Crossref]

2391. Kosma Wolinski, Adam Stangierski, Marek Ruchala. 2017. Comparison of diagnostic yield of core-needle and fine-needle aspiration biopsies of thyroid lesions: Systematic review and meta-analysis. *European Radiology* **27**:1, 431-436. [Crossref]

2392. A. Gaisser. 2017. Onkologie und Versorgung in Fach- und Publikumsmedien. *Der Onkologe* **23**:1, 63-67. [Crossref]

2393. Fabian Pitoia, Erika Abelleira, Graciela Cross. 2017. Thyroglobulin levels measured at the time of remnant ablation to predict response to treatment in differentiated thyroid cancer after thyroid hormone withdrawal or recombinant human TSH. *Endocrine* **55**:1, 200-208. [Crossref]

2394. Aysenur Ozderya, Sule Temizkan, Aylin Ege Gul, Sule Ozugur, Mehmet Sargin, Kadriye Aydin. 2017. Correlation of BRAF mutation and SUVmax levels in thyroid cancer patients incidentally detected in 18F-fluorodeoxyglucose positron emission tomography. *Endocrine* **55**:1, 215-222. [Crossref]

2395. Yuan Qu, Rui Huang, Lin Li. 2017. Low- and high-dose radioiodine therapy for low-/intermediate-risk differentiated thyroid cancer: a preliminary clinical trial. *Annals of Nuclear Medicine* **31**:1, 71-83. [Crossref]

2396. Gregory Kline, Hossein Sadrzadeh. Thyroid disorders 41-93. [Crossref]

2397. Gerry Thomas. Somatic Genomics of Childhood Thyroid Cancer 121-132. [Crossref]

2398. Akira Ohtsuru, Sanae Midorikawa, Satoru Suzuki, Hiroki Shimura, Takashi Matsuzuka, Shunichi Yamashita. Five-Year Interim Report of Thyroid Ultrasound Examinations in the Fukushima Health Management Survey 145-153. [Crossref]

2399. Sanae Midorikawa, Akira Ohtsuru, Satoru Suzuki, Koichi Tanigawa, Hitoshi Ohto, Masafumi Abe, Kenji Kamiya. Psychosocial Impact of the Thyroid Examination of the Fukushima Health Management Survey 165-173. [Crossref]

2400. Iwao Sugitani. Management of Papillary Thyroid Carcinoma in Japan 185-193. [Crossref]

2401. . Endokrinologie 145-184. [Crossref]

2402. A. Tuba Kendi, Valeria M. Moncayo, Jonathon A. Nye, James R. Galt, Raghuveer Halkar, David M. Schuster. 2017. Radionuclide Therapies in Molecular Imaging and Precision Medicine. *PET Clinics* **12**:1, 93-103. [Crossref]

2403. Christopher Sadler. 2017. Initial Evaluation and Workup of Thyroid Nodules in Adults. *Physician Assistant Clinics* **2**:1, 73-86. [Crossref]

2404. Giacomo Sturniolo, Francesco Vermiglio, Mariacarla Moleti. 2017. Thyroid cancer in lingual thyroid and thyroglossal duct cyst. *Endocrinología, Diabetes y Nutrición (English ed.)* **64**:1, 40-43. [Crossref]

2405. Giacomo Sturniolo, Francesco Vermiglio, Mariacarla Moleti. 2017. Thyroid cancer in lingual thyroid and thyroglossal duct cyst. *Endocrinología, Diabetes y Nutrición* **64**:1, 40-43. [Crossref]

2406. Mitsuhiro Tsuboi, Hiromitsu Takizawa, Mariko Aoyama, Akira Tangoku. 2017. Surgical treatment of locally advanced papillary thyroid carcinoma after response to lenvatinib: A case report. *International Journal of Surgery Case Reports* **41**, 89-92. [Crossref]

2407. José Miguel Baião, Andreia Guimarães, Nídia Moreira, João Guardado Correia, Cristina Uriarte Rosenvinge, Diana Gonçalves, Mercedes Agundez Calvo. 2017. Acute paraparesis as presentation of an occult follicular thyroid carcinoma: A case report. *International Journal of Surgery Case Reports* **41**, 498-501. [Crossref]

2408. Edmund S. Cibas, Syed Z. Ali. 2017. The 2017 Bethesda System for Reporting Thyroid Cytopathology. *Journal of the American Society of Cytopathology* **6**:6, 217. [Crossref]

2409. Fabián Pitoia, Angelica Schmidt, Fernanda Bueno, Yamile Mocarbel, Fernando Jerkovich, Erika Abelleira. 2017. Guía práctica para el manejo de efectos adversos por inhibidores multicinasas (sorafenib y vandetanib) en pacientes con cáncer de tiroides avanzado. *Revista Argentina de Endocrinología y Metabolismo* **54**:1, 8-20. [Crossref]

2410. Young Jun Chai, Jin Wook Yi, So Won Oh, Young A Kim, Ka Hee Yi, Ju Han Kim, Kyu Eun Lee. 2017. Upregulation of SLC2 (GLUT) family genes is related to poor survival outcomes in papillary thyroid carcinoma: Analysis of data from The Cancer Genome Atlas. *Surgery* **161**:1, 188-194. [Crossref]

2411. Snehal G. Patel, Sally E. Carty, Kelly L. McCoy, N. Paul Ohori, Shane O. LeBeau, Raja R. Seethala, Marina N. Nikiforova, Yuri E. Nikiforov, Linwah Yip. 2017. Preoperative detection of RAS mutation may guide extent of thyroidectomy. *Surgery* **161**:1, 168-175. [Crossref]

Downloaded by Memorial Sloan Kettering from www.liebertpub.com at 08/14/19. For personal use only.

2412. Wouter P. Kluijfhout, Jesse D. Pasternak, Frederick T. Drake, Toni Beninato, Wen T. Shen, Jessica E. Gosnell, Insoo Suh, Liu C, Quan-Yang Duh. 2017. Application of the new American Thyroid Association guidelines leads to a substantial rate of completion total thyroidectomy to enable adjuvant radioactive iodine. *Surgery* **161**:1, 127-133. [Crossref]

2413. Shriya Venkatesh, Jesse D. Pasternak, Toni Beninato, Frederick T. Drake, Wouter P. Kluijfhout, Chienying Liu, Jessica E. Gosnell, Wen T. Shen, Orlo H. Clark, Quan-Yang Duh, Insoo Suh. 2017. Cost-effectiveness of active surveillance versus hemithyroidectomy for micropapillary thyroid cancer. *Surgery* **161**:1, 116-126. [Crossref]

2414. Susan C. Pitt, Carrie C. Lubitz. 2017. Editorial: Complex decision making in thyroid cancer: Costs and consequences–is less more?. *Surgery* **161**:1, 134-136. [Crossref]

2415. Alexander L. Shifrin, Michele Fischer, Trevor Paul, Brian Erler, Katherine Gheysens, Prachi Baodhankar, Joanna W. Song-Yang, Samantha Taylor, Venkata Arun Timmaraju, Arthur Topilow, Alidad Mireskandari, Gyanendra Kumar. 2017. Mutational analysis of metastatic lymph nodes from papillary thyroid carcinoma in adult and pediatric patients. *Surgery* **161**:1, 176-187. [Crossref]

2416. David Cosgrove, Richard Barr, Joerg Bojunga, Vito Cantisani, Maria Cristina Chammas, Manjiri Dighe, Sudhir Vinayak, Jun-Mei Xu, Christoph F. Dietrich. 2017. WFUMB Guidelines and Recommendations on the Clinical Use of Ultrasound Elastography: Part 4. Thyroid. *Ultrasound in Medicine & Biology* **43**:1, 4-26. [Crossref]

2417. Chunping Liu, Tianwen Chen, Wen Zeng, Shuntao Wang, Yiquan Xiong, Zeming Liu, Tao Huang. 2017. Reevaluating the prognostic significance of male gender for papillary thyroid carcinoma and microcarcinoma: a SEER database analysis. *Scientific Reports* **7**:1. . [Crossref]

2418. Helena Luna Pais, Irina Alho, Inês Vendrell, André Mansinho, Luís Costa. 2017. Radionuclides in oncology clinical practice – review of the literature. *Dalton Transactions* **46**:42, 14475-14487. [Crossref]

2419. Agathoklis Konstantinidis, Elizabeth Tracy, Julie Ann Sosa, Sanziana A. Roman. 2017. Risk prediction in children and adults less than 45 years old with papillary thyroid cancer. *Expert Review of Endocrinology & Metabolism* **12**:5, 355. [Crossref]

2420. Mariana Canepa, Tarik M. Elsheikh, Debra A. Sabo, Ashley M. Kolosiwsky, Jordan P. Reynolds. 2017. Atypical Histiocytoid Cells in Metastatic Papillary Thyroid Carcinoma. *American Journal of Clinical Pathology* **148**:1, 58. [Crossref]

2421. Ho-Sheng Lin, David J. Terris. 2017. An update on the status of nerve monitoring for thyroid/parathyroid surgery. *Current Opinion in Oncology* **29**:1, 14-19. [Crossref]

2422. Markus Luster, Andreas Pfestroff, Frederik A. Verburg. 2017. Recent advances in nuclear medicine in endocrine oncology. *Current Opinion in Oncology* **29**:1, 1-6. [Crossref]

2423. Joseph Scharpf, Dipti Kamani, Peter M. Sadow, Gregory W. Randolph. 2017. The follicular variant of papillary thyroid cancer and noninvasive follicular thyroid neoplasm with papillary-like nuclear features (NIFTP). *Current Opinion in Oncology* **29**:1, 20-24. [Crossref]

2424. Hwa Bin Kim, Hyoung Shin Lee, Sung Won Kim, Seok Won Jeon, Ji Ah Song, Kang Dae Lee. 2017. Clinical Value of Blood Neutrophil to Lymphocyte Ratio in Patients with Papillary Thyroid Carcinoma with Neck Lymph Node Metastasis. *International Journal of Thyroidology* **10**:2, 89. [Crossref]

2425. Inmaculada Prior-Sánchez, Ana Barrera Martín, Estefanía Moreno Ortega, Juan A. Vallejo Casas, María Á. Gálvez Moreno. 2017. Is a second recombinant human thyrotropin stimulation test useful? The value of postsurgical undetectable stimulated thyroglobulin level at the time of remnant ablation on clinical outcome. *Clinical Endocrinology* **86**:1, 97-107. [Crossref]

2426. Soo Yeon Hahn, Jung Hee Shin, Hyun Kyung Lim, So Lyung Jung. 2017. Follicular variant of papillary thyroid carcinoma: comparison of ultrasound-guided core needle biopsy and ultrasound-guided fine needle aspiration in a multicentre study. *Clinical Endocrinology* **86**:1, 113-119. [Crossref]

2427. Naris Nilubol, Roxanne Merkel, Lily Yang, Dhaval Patel, James C. Reynolds, Samira M. Sadowski, Vladimir Neychev, Electron Kebebew. 2017. A phase II trial of valproic acid in patients with advanced, radioiodine-resistant thyroid cancers of follicular cell origin. *Clinical Endocrinology* **86**:1, 128-133. [Crossref]

2428. Bin Liu, Yu Chen, Lisha Jiang, Ying He, Rui Huang, Anren Kuang. 2017. Is postablation whole-body 131 I scintigraphy still necessary in intermediate-risk papillary thyroid cancer patients with pre-ablation stimulated thyroglobulin <1 ng/mL?. *Clinical Endocrinology* **86**:1, 134-140. [Crossref]

2429. Joel T. Adler, Heidi Yeh, Giuseppe Barbesino, Carrie C. Lubitz. 2017. Reassessing risks and benefits of living kidney donors with a history of thyroid cancer. *Clinical Transplantation* **31**:11, e13114. [Crossref]

2430. Amy V. Chudgar, Jagruti C. Shah. 2017. Pictorial Review of False-Positive Results on Radioiodine Scintigrams of Patients with Differentiated Thyroid Cancer. *RadioGraphics* **37**:1, 298-315. [Crossref]

2431. Rachel Jug, Xiaoyin Jiang. 2017. Noninvasive Follicular Thyroid Neoplasm with Papillary-Like Nuclear Features: An Evidence-Based Nomenclature Change. *Pathology Research International* **2017**, 1-6. [Crossref]

Downloaded by Memorial Sloan Kettering from www.liebertpub.com at 08/14/19. For personal use only.

2432. Ting-ting Zhang, Ning Qu, Jia-qian Hu, Rong-liang Shi, Duo Wen, Guo-hua Sun, Qing-hai Ji. 2017. Mediastinal Lymph Node Metastases in Thyroid Cancer: Characteristics, Predictive Factors, and Prognosis. *International Journal of Endocrinology* **2017**, 1-10. [Crossref]

2433. Hamiyet Donmez-Altuntas, Fahri Bayram, Nazmiye Bitgen, Sibel Ata, Zuhal Hamurcu, Gulden Baskol. 2017. Increased Chromosomal and Oxidative DNA Damage in Patients with Multinodular Goiter and Their Association with Cancer. *International Journal of Endocrinology* **2017**, 1-7. [Crossref]

2434. Abdou Sy, Eric Joël Regonne, Aminata Fofana, Yves Diandy, Malick Ndiaye. 2017. Indications and Morbidity of Reoperative Thyroid Surgeries in a Military Hospital of Senegal. *International Journal of Otolaryngology* **2017**, 1. [Crossref]

2435. Soh-Ching Ng, Sheng-Fong Kuo, Szu-Tah Chen, Chuen Hsueh, Bie-Yu Huang, Jen-Der Lin. 2017. Therapeutic Outcomes of Patients with Multifocal Papillary Thyroid Microcarcinomas and Larger Tumors. *International Journal of Endocrinology* **2017**, 1-8. [Crossref]

2436. Yihao Liu, Lei Su, Haipeng Xiao. 2017. Review of Factors Related to the Thyroid Cancer Epidemic. *International Journal of Endocrinology* **2017**, 1-9. [Crossref]

2437. Marilena Celano, Francesca Rosignolo, Valentina Maggisano, Valeria Pecce, Michelangelo Iannone, Diego Russo, Stefania Bulotta. 2017. MicroRNAs as Biomarkers in Thyroid Carcinoma. *International Journal of Genomics* **2017**, 1. [Crossref]

2438. Carlo Cappelli, Ilenia Pirola, Elena Gandossi, Claudio Casella, Davide Lombardi, Barbara Agosti, Fiorella Marini, Andrea Delbarba, Maurizio Castellano. 2017. TSH Variability of Patients Affected by Differentiated Thyroid Cancer Treated with Levothyroxine Liquid Solution or Tablet Form. *International Journal of Endocrinology* **2017**, 1-5. [Crossref]

2439. Joji Kawabe, Shigeaki Higashiyama, Mitsuharu Sougawa, Atsushi Yoshida, Kohei Kotani, Susumu Shiomi. 2017. Usefulness of Stereotactic Radiotherapy Using CyberKnife for Recurrent Lymph Node Metastasis of Differentiated Thyroid Cancer. *Case Reports in Endocrinology* **2017**, 1-3. [Crossref]

2440. Vijay Gopal Eranki. 2017. A Recurrent Episode of Dermatomyositis Associated with Papillary Thyroid Cancer. *Case Reports in Endocrinology* **2017**, 1-2. [Crossref]

2441. Roberto Negro, Gabriele Greco, Ermenegildo Colosimo. 2017. Ultrasound Risk Categories for Thyroid Nodules and Cytology Results: A Single Institution?s Experience after the Adoption of the 2016 Update of Medical Guidelines by the American Association of Clinical Endocrinologists and Associazione Medici Endocrinologi. *Journal of Thyroid Research* **2017**, 1-6. [Crossref]

2442. Ali S. Alzahrani, Haneen Alomar, Nada Alzahrani. 2017. Thyroid Cancer in Saudi Arabia: A Histopathological and Outcome Study. *International Journal of Endocrinology* **2017**, 1-7. [Crossref]

2443. Gustavo Cancela e Penna, Henrique Gomes Mendes, Adele O. Kraft, Cynthia Koeppel Berenstein, Bernardo Fonseca, Wagner José Martorina, Andreise Laurian N. R. de Souza, Gustavo Meyer de Moraes, Kamilla Maria Araújo Brandão Rajão, Bárbara Érika Caldeira Araújo Sousa. 2017. Simultaneous Papillary Carcinoma in Thyroglossal Duct Cyst and Thyroid. *Case Reports in Endocrinology* **2017**, 1-5. [Crossref]

2444. Vanesa Varela Pose, María Patricia Fierro Alanis, Anaberta Bermudez Naveira, Oskarina Lourdes Silva Gonzalez, Jorge Fernandez Noya, Urbano Anido Herranz, Rafael Lopez Lopez. 2017. Unusual Case of Superior Vena Cava Syndrome Caused by Intravascular Thyroid Metastasis. *Case Reports in Oncological Medicine* **2017**, 1. [Crossref]

2445. Aili Guo, Yuuki Kaminoh, Terra Forward, Frank L. Schwartz, Scott Jenkinson. 2017. Fine Needle Aspiration of Thyroid Nodules Using the Bethesda System for Reporting Thyroid Cytopathology: An Institutional Experience in a Rural Setting. *International Journal of Endocrinology* **2017**, 1-6. [Crossref]

2446. Salvatore Ulisse, Daniela Bosco, Francesco Nardi, Angela Nesca, Eleonora D'Armiento, Valeria Guglielmino, Corrado De Vito, Salvatore Sorrenti, Daniele Pironi, Francesco Tartaglia, Stefano Arcieri, Antonio Catania, Massimo Monti, Angelo Filippini, Valeria Ascoli. 2017. Thyroid Imaging Reporting and Data System Score Combined with the New Italian Classification for Thyroid Cytology Improves the Clinical Management of Indeterminate Nodules. *International Journal of Endocrinology* **2017**, 1-8. [Crossref]

2447. Elna Kochummen, Schuyler Tong, Vatcharapan Umpaichitra, Vivian L. Chin. 2017. A Unique Case of Bilateral Hürthle Cell Adenoma in an Adolescent. *Hormone Research in Paediatrics* **87**:2, 136-142. [Crossref]

2448. Fabián Pitoia, Fernando Jerkovich, Anabella Smulever, Gabriela Brenta, Fernanda Bueno, Graciela Cross. 2017. Should Age at Diagnosis Be Included as an Additional Variable in the Risk of Recurrence Classification System in Patients with Differentiated Thyroid Cancer. *European Thyroid Journal* **6**:3, 160-166. [Crossref]

2449. Zaid Al-Qurayshi, Daniah Bu Ali, Sudesh Srivastav, Emad Kandil. 2017. Financial Implication of Radioactive Iodine Therapy for Early-Stage Papillary Thyroid Cancer. *Oncology* **93**:2, 122-126. [Crossref]

Downloaded by Memorial Sloan Kettering from www.liebertpub.com at 08/14/19. For personal use only.

2450. Ralf Paschke, Silvia Cantara, Anna Crescenzi, Barbara Jarzab, Thomas J. Musholt, Manuel Sobrinho Simoes. 2017. European Thyroid Association Guidelines regarding Thyroid Nodule Molecular Fine-Needle Aspiration Cytology Diagnostics. *European Thyroid Journal* 115-129. [Crossref]

2451. Alexis Lacout, Emmanuel Chamorey, Juliette Thariat, Mostafa El Hajjam, Carole Chevenet, Renaud Schiappa, Pierre Yves Marcy. 2017. Insight into Differentiated Thyroid Cancer Gross Pathological Specimen Shrinkage and Its Influence on TNM Staging. *European Thyroid Journal* **6**:6, 315-320. [Crossref]

2452. Maria M Pineyro, Jimena Pereda, Pamela Schou, Karina de los Santos, Soledad de la Peña, Benedicta Caserta, Raul Pisabarro. 2017. Papillary Thyroid Microcarcinoma Arising Within a Mature Ovarian Teratoma: Case Report and Review of the Literature. *Clinical Medicine Insights: Endocrinology and Diabetes* **10**, 117955141771252. [Crossref]

2453. Uthman Alamoudi, Eric Levi, Matthew H. Rigby, S. Mark Taylor, Jonathan R. B. Trites, Robert D. Hart. 2017. The Incidental Thyroid Lesion in Parathyroid Disease Management. *OTO Open* **1**:1, 2473974X1770108. [Crossref]

2454. N. Hagenimana, J. Dallaire, É. Vallée, M. Belzile. 2017. Thyroid incidentalomas on 18FDG-PET/CT: a metabolico-pathological correlation. *Journal of Otolaryngology - Head & Neck Surgery* **46**:1. . [Crossref]

2455. Ji Won Kim, Jong-Lyel Roh, Gyungyup Gong, Kyung-Ja Cho, Seung-Ho Choi, Soon Yuhl Nam, Sang Yoon Kim. 2017. Extent of Extrathyroidal Extension as a Significant Predictor of Nodal Metastasis and Extranodal Extension in Patients with Papillary Thyroid Carcinoma. *Annals of Surgical Oncology* **24**:2, 460. [Crossref]

2456. ## #. 2017. Research Progress of Differentiated Thyroid Carcinoma. *Medical Diagnosis* **07**:03, 60-64. [Crossref]

2457. Meng Yang, Lingyi Zhao, Xujin He, Na Su, ChenYang Zhao, Hewen Tang, Tao Hong, Wenbo Li, Fang Yang, Lin Lin, Bing Zhang, Rui Zhang, Yuxin Jiang, Changhui Li. 2017. Photoacoustic/ultrasound dual imaging of human thyroid cancers: an initial clinical study. *Biomedical Optics Express* **8**:7, 3449. [Crossref]

2458. Ján Sojak, Marian Sičák, Adrian Kališ, Michal Slašťan. 2017. Papillary Thyroid Carcinoma: Analysis of the Central Compartment's Lymph Nodes Metastases. *Acta Medica (Hradec Kralove, Czech Republic)* **60**:1, 44-50. [Crossref]

2459. Aya Sawa, Tomohiro Chiba, Jun Ishii, Hiroyuki Yamamoto, Hisato Hara, Hiroshi Kamma. 2017. Effects of sorafenib and an adenylyl cyclase activator on in vitro growth of well-differentiated thyroid cancer cells. *Endocrine Journal* **64**:11, 1115-1123. [Crossref]

2460. Nami Takada, Mitsuyoshi Hirokawa, Ayana Suzuki, Miyoko Higuchi, Seiji Kuma, Akira Miyauchi. 2017. Reappraisal of “cyst fluid only” on thyroid fine-needle aspiration cytology. *Endocrine Journal* **64**:8, 759-765. [Crossref]

2461. Mitsuyoshi Hirokawa, Takumi Kudo, Hisashi Ota, Ayana Suzuki, Kaoru Kobayashi, Akira Miyauchi. 2017. Preoperative diagnostic algorithm of primary thyroid lymphoma using ultrasound, aspiration cytology, and flow cytometry. *Endocrine Journal* **64**:9, 859-865. [Crossref]

2462. Nami Takada, Mitsuyoshi Hirokawa, Masahiro Ito, Aki Ito, Ayana Suzuki, Miyoko Higuchi, Seiji Kuma, Toshitetsu Hayashi, Masao Kishikawa, Shuichi Horikawa, Akira Miyauchi. 2017. Papillary thyroid carcinoma with desmoid-type fibromatosis: A clinical, pathological, and immunohistochemical study of 14 cases. *Endocrine Journal* **64**:10, 1017-1023. [Crossref]

2463. Xiaopei Shen, Rengyun Liu, Mingzhao Xing. 2017. A six-genotype genetic prognostic model for papillary thyroid cancer. *Endocrine-Related Cancer* **24**:1, 41-52. [Crossref]

2464. Ja Ryung Han, Jin Hyang Jung, Wan Wook Kim, Jeeyeon Lee, Ho Yong Park, Hye Jung Kim, Ji-Young Park. 2017. Bilateral Papillary Thyroid Cancer Increases the Risk of Lymph Node Metastasis Compared with Unilateral Multifocal Papillary Thyroid Cancer. *Journal of Endocrine Surgery* **17**:2, 63. [Crossref]

2465. Tae Yoon Lee, Sohee Lee, Ja Seong Bae. 2017. Staging of Differentiated Thyroid Cancer from a Single Institution: Comparison of the 7th and 8th Editions of AJCC/UICC Staging. *Journal of Endocrine Surgery* **17**:2, 80. [Crossref]

2466. Su Yeon Jeong, Yoo Seok Kim, Kweon Cheon Kim. 2017. Predictive Factors for Central Neck Lymph Node Metastasis in Patients with Papillary Thyroid Microcarcinoma without Suspicious Metastasis by Preoperative Ultrasonography. *Journal of Endocrine Surgery* **17**:3, 114. [Crossref]

2467. Yoon Hyeong Byeon, Jung Eun Choi, Jeong Yeong Park, Jeong Hyun Song, Kyeong Jun Yeo, Eun Jung Kong, Su Hwan Kang, Soo Jung Lee. 2017. Diagnostic Accuracy of PET/MR for Evaluating Central Lymph Node Status in Patients with Papillary Thyroid Carcinoma. *Journal of Endocrine Surgery* **17**:3, 122. [Crossref]

2468. Myung-Chul Chang. 2017. Bone Mineral Density in Thyroid Cancer Patients: Data from the Korea National Health and Nutrition Examination Survey. *Journal of Endocrine Surgery* **17**:4, 153. [Crossref]

2469. Su Jung Kim, Jeonghun Lee, Euy Young Soh. 2017. The Clinical Significance of the BRAF Mutation in Patients with Papillary Thyroid Cancer. *Journal of Endocrine Surgery* **17**:4, 175. [Crossref]

Downloaded by Memorial Sloan Kettering from www.liebertpub.com at 08/14/19. For personal use only.

2470. Jin-Woo Park, Ki-Wook Chung, Ji-Sup Yun, Hyungju Kwon, Hoon Yub Kim, Kee Hyun Nam, Kyoung Sik Park, Min Ho Park, Ja Sung Bae, Hyun Jo Youn, Kyu Eun Lee, Chi Young Lim, Jin Hyang Jung, Jun-Ho Choe, Lee Su Kim, Su Jung Lee, Jung Han Yoon. 2017. Surgical Treatment Guidelines for Patients with Differentiated Thyroid Cancer: The Korean Association of Thyroid and Endocrine Surgeons (KATES) Guidelines Taskforce. *Korean Journal of Endocrine Surgery* **17**:1, 1. [Crossref]

2471. M Sara Rosenthal, Kenneth B Ain, Peter Angelos, Ryoko Hatanaka, Masaru Motojima. 2017. Problematic clinical trials in thyroid cancer: the issue of papillary carcinoma and observational approaches. *International Journal of Endocrine Oncology* **4**:3, 127. [Crossref]

2472. C.H. Suh, J.H. Baek, Y.J. Choi, J.H. Lee. 2017. Performance of CT in the Preoperative Diagnosis of Cervical Lymph Node Metastasis in Patients with Papillary Thyroid Cancer: A Systematic Review and Meta-Analysis. *American Journal of Neuroradiology* **38**:1, 154-161. [Crossref]

2473. Tsukasa MURAKAMI. 2017. Ultrasound examination of thyroid nodules. *Choonpa Igaku* **44**:3, 253-259. [Crossref]

2474. Dong Gyu Na, Jung Hwan Baek, So Lyung Jung, Ji-hoon Kim, Jin Yong Sung, Kyu Sun Kim, Jeong Hyun Lee, Jung Hee Shin, Yoon Jung Choi, Eun Ju Ha, Hyun Kyung Lim, Soo Jin Kim, Soo Yeon Hahn, Kwang Hwi Lee, Young Jun Choi, Inyoung Youn, Young Joong Kim, Hye Shin Ahn, Ji Hwa Ryu, Seon Mi Baek, Jung Suk Sim, Chan Kwon Jung, Joon Hyung Lee. 2017. Core Needle Biopsy of the Thyroid: 2016 Consensus Statement and Recommendations from Korean Society of Thyroid Radiology. *Korean Journal of Radiology* **18**:1, 217. [Crossref]

2475. Jung Hwan Baek, Dong Gyu Na, Hye Sun Park. 2017. RE: Management of Low-Risk Papillary Thyroid Microcarcinoma. *Korean Journal of Radiology* **18**:2, 408. [Crossref]

2476. M. Dietlein, A. Drzezga. 2017. Taste dysfunction (dysgeusia) and radioiodine therapy of thyroid cancer – be aware of side effects by antidepressants and sedatives. *Nuklearmedizin* **56**:4, 125-131. [Crossref]

2477. A. Todica, S. Haidvogl, W. P. Fendler, H. Ilhan, A. Rominger, A. R. Haug, P. Bartenstein, S. Lehner. 2017. Effectiveness of Reduced Radioiodine Activity for Thyroid Remnant Ablation after Total Thyroidectomy in Patients with Low to Intermediate Risk Differentiated Thyroid Carcinoma. *Nuklearmedizin* **56**:6, 211-218. [Crossref]

2478. P. Seifert, M. Freesmeyer. 2017. Preoperative diagnostics in differentiated thyroid carcinoma. *Nuklearmedizin* **56**:6, 201-210. [Crossref]

2479. Tae Yong Kim, Young Kee Shong. 2017. Active Surveillance of Papillary Thyroid Microcarcinoma: A Mini-Review from Korea. *Endocrinology and Metabolism* **32**:4, 399. [Crossref]

2480. Chan Kwon Jung, Jung Hwan Baek. 2017. Recent Advances in Core Needle Biopsy for Thyroid Nodules. *Endocrinology and Metabolism* **32**:4, 407. [Crossref]

2481. Massimo Giusti, Lucia Conte, Anna Maria Repetto, Stefano Gay, Paola Marroni, Miranda Mittica, Michele Mussap. 2017. Detection of Polyethylene Glycol Thyrotropin (TSH) Precipitable Percentage (Macro-TSH) in Patients with a History of Thyroid Cancer. *Endocrinology and Metabolism* **32**:4, 460. [Crossref]

2482. Ahmet DİRİKOÇ, Sevgül FAKI, Hüsniye BAŞER, Didem ÖZDEMİR, Cevdet AYDIN, Reyhan ERSOY, Mehmet KILIÇ, Aydan KILIÇARSLAN, Bekir ÇAKIR. 2017. Thyroid malignancy risk in different clinical thyroid diseases. *TURKISH JOURNAL OF MEDICAL SCIENCES* **47**, 1509-1519. [Crossref]

2483. Takashi Hirai, Atsushi Hanamoto, Motoyuki Suzuki, Norihiko Takemoto, Takahiro Michiba, Hidenori Inohara. 2017. Thyroid Cancer Treated with Tyrosine Kinase Inhibitor at Osaka University. *Nippon Jibiinkoka Gakkai Kaiho* **120**:10, 1231-1238. [Crossref]

2484. Ana Kober Nogueira Leite, Marco Aurélio Vamondes Kulcsar, Beatriz de Godoi Cavalheiro, Evandro Sobroza de Mello, Venâncio Avancini F. Alves, Claudio Roberto Cernea, Leandro Luongo Matos. 2017. DEATH RELATED TO PULMONARY METASTASIS IN PATIENTS WITH DIFFERENTIATED THYROID CANCER. *Endocrine Practice* **23**:1, 72-78. [Crossref]

2485. Eun Young Kim, Kee Hoon Hyun, Yong Lai Park, Chan Heun Park, Ji-Sup Yun. 2017. Risk factors associated with high thyroglobulin level following radioactive iodine ablation, measured 12 months after treatment for papillary thyroid carcinoma. *Annals of Surgical Treatment and Research* **92**:1, 1. [Crossref]

2486. Yigit Turk, Ozer Makay, Murat Ozdemir, Gozde Ertunc, Batuhan Demir, Gokhan Icoz, Mahir Akyildiz, Mustafa Yilmaz. 2017. Routine calcitonin measurement in nodular thyroid disease management: is it worthwhile?. *Annals of Surgical Treatment and Research* **92**:4, 173. [Crossref]

2487. Duzgun Yildirim, Deniz Alis, Sabri Sirolu, Cesur Samanci, Fethi Emre Ustabasioglu, Bulent Colakoglu. 2017. Current Radiological Approach in Thyroid Nodules. *Journal of Cancer Therapy* **08**:05, 423-442. [Crossref]

2488. Mohamed Abdulaziz Al Dawish, Asirvatham Alwin Robert, Aljuboury Muna, Alkharashi Eyad, Abdullah Al Ghamdi, Khalid Al Hajeri, Mohammed A Thabet, Rim Braham. 2017. Bethesda System for Reporting Thyroid Cytopathology: A three-year study at a tertiary care referral center in Saudi Arabia. *World Journal of Clinical Oncology* **8**:2, 151. [Crossref]

Downloaded by Memorial Sloan Kettering from www.liebertpub.com at 08/14/19. For personal use only.

2489. J. Matthew Debnam, Michael Kwon, Bruno D. Fornage, Savitri Krishnamurthy, Gary L. Clayman, Beth S. Edeiken-Monroe. 2017. Sonographic Evaluation of Intrathyroid Metastases. *Journal of Ultrasound in Medicine* **36**:1, 69-76. [Crossref]

2490. Grace C. H. Yang, Karen O. Fried. 2017. Most Thyroid Cancers Detected by Sonography Lack Intranodular Vascularity on Color Doppler Imaging: Review of the Literature and Sonographic-Pathologic Correlations for 698 Thyroid Neoplasms. *Journal of Ultrasound in Medicine* **36**:1, 89-94. [Crossref]

2491. Sarah J. Morgan, Susanne Neumann, Bernice Marcus-Samuels, Marvin C. Gershengorn. 2016. Thyrotropin Stimulates Differentiation Not Proliferation of Normal Human Thyrocytes in Culture. *Frontiers in Endocrinology* **7**. . [Crossref]

2492. Krzysztof Kaliszewski, Marta Strutyńska-Karpińska, Agnieszka Zubkiewicz-Kucharska, Beata Wojtczak, Paweł Domosławski, Waldemar Balcerzak, Tadeusz Łukieńczuk, Zdzisław Forkasiewicz. 2016. Should the Prevalence of Incidental Thyroid Cancer Determine the Extent of Surgery in Multinodular Goiter?. *PLOS ONE* **11**:12, e0168654. [Crossref]

2493. Chenlei Shi, Yong Guo, Yichen Lv, Abiyasi Nanding, Tiefeng Shi, Huadong Qin, Jianjun He. 2016. Clinicopathological Features and Prognosis of Papillary Thyroid Microcarcinoma for Surgery and Relationships with the BRAFV600E Mutational Status and Expression of Angiogenic Factors. *PLOS ONE* **11**:12, e0167414. [Crossref]

2494. Christopher W Rowe, Kirsten Murray, Andrew Woods, Sandeep Gupta, Roger Smith, Katie Wynne. 2016. Management of metastatic thyroid cancer in pregnancy: risk and uncertainty. *Endocrinology, Diabetes & Metabolism Case Reports* . [Crossref]

2495. Livhits Masha J., Yeh Michael W.. 2016. Lateral Lymph-Node Dissection for Papillary Thyroid Cancer Should Be Limited to Clinically Positive Compartments. *Clinical Thyroidology* **28**:12, 363-365. [Citation] [Full Text] [PDF] [PDF Plus]

2496. Sacks Wendy. 2016. Radiofrequency Ablation Is a Treatment Option for Low-Risk Papillary Thyroid Microcarcinoma. *Clinical Thyroidology* **28**:12, 369-371. [Citation] [Full Text] [PDF] [PDF Plus]

2497. Fish Stephanie A.. 2016. Clinicopathologic Factors and Thyroid Nodule Sonographic Features Can Predict Central Lymph Node Metastasis in Papillary Thyroid Microcarcinoma. *Clinical Thyroidology* **28**:12, 372-375. [Citation] [Full Text] [PDF] [PDF Plus]

2498. Rössing Ronja Maria, Jentzen Walter, Nagarajah James, Bockisch Andreas, Görges Rainer. 2016. Serum Thyroglobulin Doubling Time in Progressive Thyroid Cancer. *Thyroid* **26**:12, 1712-1718. [Abstract] [Full Text] [PDF] [PDF Plus]

2499. Tomoda Chisato, Sugino Kiminori, Matsuzu Kenichi, Uruno Takashi, Ohkuwa Keiko, Kitagawa Wataru, Nagahama Mitsuji, Ito Koichi. 2016. Cervical Lymph Node Metastases After Thyroidectomy for Papillary Thyroid Carcinoma Usually Remain Stable for Years. *Thyroid* **26**:12, 1706-1711. [Abstract] [Full Text] [PDF] [PDF Plus]

2500. Wang Kun, Wu Gaosong. 2016. Intraoperative Neuromonitoring in Selective Neck Dissection for Thyroid Cancer: SND (IIa–Vb) with Wu Gaosong's Procedure. *VideoEndocrinology* **3**:4. . [Abstract] [Full Text]

2501. Xiaoyin "Sara" Jiang, Grant P. Harrison, Michael B. Datto. 2016. Young Investigator Challenge: Molecular testing in noninvasive follicular thyroid neoplasm with papillary-like nuclear features. *Cancer Cytopathology* **124**:12, 893-900. [Crossref]

2502. Sherry Tang, Andrew Buck, Claudia Jones, Xiaoyin "Sara" Jiang. 2016. The utility of thyroglobulin washout studies in predicting cervical lymph node metastases: One academic medical center's experience. *Diagnostic Cytopathology* **44**:12, 964-968. [Crossref]

2503. Joseph Scharpf, Michael Tuttle, Richard Wong, Drew Ridge, Russell Smith, Dana Hartl, Robert Levine, Gregory Randolph. 2016. Comprehensive management of recurrent thyroid cancer: An American Head and Neck Society consensus statement. *Head & Neck* **38**:12, 1862-1869. [Crossref]

2504. Yonghong Hao, Chu Pan, WeiWei Chen, Tao Li, WenZhen Zhu, JianPin Qi. 2016. Differentiation between malignant and benign thyroid nodules and stratification of papillary thyroid cancer with aggressive histological features: Whole-lesion diffusion-weighted imaging histogram analysis. *Journal of Magnetic Resonance Imaging* **44**:6, 1546-1555. [Crossref]

2505. Shih-Ping Cheng, Po-Sheng Yang, Ming-Nan Chien, Ming-Jen Chen, Jie-Jen Lee, Chien-Liang Liu. 2016. Aberrant expression of tumor-associated carbohydrate antigen Globo H in thyroid carcinoma. *Journal of Surgical Oncology* **114**:7, 853-858. [Crossref]

2506. Jonathon O. Russell, Salem I. Noureldine, Mai G. Al Khadem, Ralph P. Tufano. 2016. Minimally invasive and remote-access thyroid surgery in the era of the 2015 American Thyroid Association guidelines. *Laryngoscope Investigative Otolaryngology* **1**:6, 175-179. [Crossref]

2507. Yi-Chiung Hsu, Chien-Liang Liu, Po-Sheng Yang, Chung-Hsin Tsai, Jie-Jen Lee, Shih-Ping Cheng. 2016. Interaction of Age at Diagnosis with Transcriptional Profiling in Papillary Thyroid Cancer. *World Journal of Surgery* **40**:12, 2922-2929. [Crossref]

2508. Amandine Crombé, Xavier Buy, Yann Godbert, Nicolas Alberti, Michèle Kind, Françoise Bonichon, Jean Palussière. 2016. 23 Lung Metastases Treated by Radiofrequency Ablation Over 10 Years in a Single Patient: Successful Oncological Outcome of a Metastatic Cancer Without Altered Respiratory Function. *CardioVascular and Interventional Radiology* **39**:12, 1779-1784. [Crossref]

2509. Salvatore Benvenga. 2016. A journey from brain to muscle across the thyroid continent. *Reviews in Endocrine and Metabolic Disorders* **17**:4, 459-463. [Crossref]

Downloaded by Memorial Sloan Kettering from www.liebertpub.com at 08/14/19. For personal use only.

2510. Luca Giovanella, Federica D'Aurizio, Alfredo Campenni', Rosaria Maddalena Ruggeri, Sergio Baldari, Frederik Anton Verburg, Pierpaolo Trimboli, Luca Ceriani. 2016. Searching for the most effective thyrotropin (TSH) threshold to rule-out autonomously functioning thyroid nodules in iodine deficient regions. *Endocrine* **54**:3, 757-761. [Crossref]

2511. Rafael Fernandes Nunes, Felipe de Galiza Barbosa, Marcelo A. Queiroz. 2016. Hybrid PET/MR: Updated Clinical Use and Potential Applications. *Current Radiology Reports* **4**:12. . [Crossref]

2512. B. Biondi, L. Bartalena, L. Chiovato, A. Lenzi, S. Mariotti, F. Pacini, A. Pontecorvi, P. Vitti, F. Trimarchi. 2016. Recommendations for treatment of hypothyroidism with levothyroxine and levotriiodothyronine: a 2016 position statement of the Italian Society of Endocrinology and the Italian Thyroid Association. *Journal of Endocrinological Investigation* **39**:12, 1465-1474. [Crossref]

2513. Maria E Cabanillas, David G McFadden, Cosimo Durante. 2016. Thyroid cancer. *The Lancet* **388**:10061, 2783-2795. [Crossref]

2514. Corinna Wicke, Arnold Trupka. 2016. Schilddrüse und Nebenschilddrüsen: Worauf Sie bei Ihren Patienten achten sollten. *Osteopathische Medizin* **17**:4, 30-34. [Crossref]

2515. Mark Tulchinsky. 2016. Papillary thyroid microcarcinoma and active surveillance. *The Lancet Diabetes & Endocrinology* **4**:12, 974. [Crossref]

2516. Peter Angelos. 2016. Papillary thyroid microcarcinoma and active surveillance. *The Lancet Diabetes & Endocrinology* **4**:12, 975-976. [Crossref]

2517. Sophie Leboulleux, R Michael Tuttle, Furio Pacini, Martin Schlumberger. 2016. Papillary thyroid microcarcinoma and active surveillance – Authors' reply. *The Lancet Diabetes & Endocrinology* **4**:12, 976-977. [Crossref]

2518. Zahraa Al-Hilli, Veljko Strajina, Travis J. McKenzie, Geoffrey B. Thompson, David R. Farley, Melanie L. Richards. 2016. The role of lateral neck ultrasound in detecting single or multiple lymph nodes in papillary thyroid cancer. *The American Journal of Surgery* **212**:6, 1147-1153. [Crossref]

2519. K. Alok Pathak, Andrew L. Goertzen, Richard W. Nason, Thomas Klonisch, William D. Leslie. 2016. A prospective cohort study to assess the role of FDG-PET in differentiating benign and malignant follicular neoplasms. *Annals of Medicine and Surgery* **12**, 27-31. [Crossref]

2520. Arturo Louro González, Ángel Núñez Vázquez, Fernando Cordido Carballido, Natalia Gómez Gómez, Marta Lois Rodríguez, María Cordido Carro. 2016. Patología tiroidea en atención primaria. *FMC - Formación Médica Continuada en Atención Primaria* **23**, 5-33. [Crossref]

2521. Bin Wang, An-Ping Su, Teng-Fei Xing, Han Luo, Wan-Jun Zhao, Jing-Qiang Zhu. 2016. The function of carbon nanoparticles as tracer during thyroid reoperation. *International Journal of Surgery Open* . [Crossref]

2522. Katarzyna Dobruch-Sobczak, Elwira Bakuła Zalewska, Anna Gumińska, Rafał Zenon Słapa, Krzysztof Mlosek, Paweł Wareluk, Wiesław Jakubowski, Marek Dedecjus. 2016. Diagnostic Performance of Shear Wave Elastography Parameters Alone and in Combination with Conventional B-Mode Ultrasound Parameters for the Characterization of Thyroid Nodules: A Prospective, Dual-Center Study. *Ultrasound in Medicine & Biology* **42**:12, 2803-2811. [Crossref]

2523. Jieun Koh, Eun-Kyung Kim, Ji-Ye Kim, Jin Young Kwak, Jung Hyun Yoon, Hee Jung Moon. 2016. Comparison of Ultrasound, Pathologic and Prognostic Characteristics of the Follicular Variant of Papillary Thyroid Cancer According to Fine-Needle Aspiration Cytology. *Ultrasound in Medicine & Biology* **42**:12, 2864-2872. [Crossref]

2524. Na Liu, Zhaowei Meng, Qiang Jia, Jian Tan, Guizhi Zhang, Wei Zheng, Renfei Wang, Xue Li, Tianpeng Hu, Arun Upadhyaya, Pingping Zhou, Sen Wang. 2016. Multiple-factor analysis of the first radioactive iodine therapy in post-operative patients with differentiated thyroid cancer for achieving a disease-free status. *Scientific Reports* **6**:1. . [Crossref]

2525. Wen-Wen Yue, Shu-Rong Wang, Feng Lu, Xiao-Long Li, Hui-Xiong Xu, Li-Ping Sun, Le-Hang Guo, Ya-Ping He, Dan Wang, Zhi-Qiang Yin. 2016. Quality of Life and Cost-Effectiveness of Radiofrequency Ablation versus Open Surgery for Benign Thyroid Nodules: a retrospective cohort study. *Scientific Reports* **6**:1. . [Crossref]

2526. Camille Louvet, Annamaria De Bellis, Bruno Pereira, Claire Bournaud, Antony Kelly, Salwan Maqdasy, Beatrice Roche, Francoise Desbiez, Francoise Borson-Chazot, Igor Tauveron, Marie Batisse-Lignier. 2016. Time course of Graves' orbitopathy after total thyroidectomy and radioiodine therapy for thyroid cancer. *Medicine* **95**:48, e5474. [Crossref]

2527. J. Winter, M. Winter, T. Krohn, A. Heinzel, F.F. Behrendt, R.M. Tuttle, F.M. Mottaghy, F.A. Verburg. 2016. Patients with high-risk differentiated thyroid cancer have a lower I-131 ablation success rate than low-risk ones in spite of a high ablation activity. *Clinical Endocrinology* **85**:6, 926-931. [Crossref]

2528. Nigel Glynn, Mark J. Hannon, Sarah Lewis, Patrick Hillery, Mohammed Al-Mousa, Arnold D. K. Hill, Frank Keeling, Martina Morrin, Christopher J. Thompson, Diarmuid Smith, Derval Royston, Mary Leader, Amar Agha. 2016. Utility of repeat cytological assessment of thyroid nodules initially classified as benign: clinical insights from multidisciplinary care in an Irish tertiary referral centre. *BMC Endocrine Disorders* **16**:1. . [Crossref]

Downloaded by Memorial Sloan Kettering from www.liebertpub.com at 08/14/19. For personal use only.

2529. Dorota Słowińska-Klencka, Martyna Wojtaszek-Nowicka, Stanisław Sporny, Ewa Woźniak-Oseła, Bożena Popowicz, Mariusz Klencki. 2016. The predictive value of sonographic images of follicular lesions – a comparison with nodules unequivocal in FNA – single centre prospective study. *BMC Endocrine Disorders* **16**:1. . [Crossref]

2530. Mingzhao Xing. 2016. Clinical utility of RAS mutations in thyroid cancer: a blurred picture now emerging clearer. *BMC Medicine* **14**:1. . [Crossref]

2531. Giovanni Conzo, Ernesto Tartaglia, Nicola Avenia, Pier Giorgio Calò, Annamaria de Bellis, Katherine Esposito, Claudio Gambardella, Sergio Iorio, Daniela Pasquali, Luigi Santini, Maria Antonia Sinisi, Antonio Agostino Sinisi, Mario Testini, Andrea Polistena, Giuseppe Bellastella. 2016. Role of prophylactic central compartment lymph node dissection in clinically N0 differentiated thyroid cancer patients: analysis of risk factors and review of modern trends. *World Journal of Surgical Oncology* **14**:1. . [Crossref]

2532. Chen-Tian Shen, Zhong-Ling Qiu, Hong-Jun Song, Wei-Jun Wei, Quan-Yong Luo. 2016. miRNA-106a directly targeting RARB associates with the expression of Na+/I– symporter in thyroid cancer by regulating MAPK signaling pathway. *Journal of Experimental & Clinical Cancer Research* **35**:1. . [Crossref]

2533. Alborz Jooya, Joe Saliba, Audrey Blackburn, Michael Tamilia, Michael P. Hier, Alex Mlynarek, Véronique-Isabelle Forest, Louise Rochon, Anca Florea, Hangjun Wang, Richard J. Payne. 2016. The role of repeat fine needle aspiration in the management of indeterminate thyroid nodules. *Journal of Otolaryngology - Head & Neck Surgery* **45**:1. . [Crossref]

2534. Michael W. Deutschmann, Laura Chin-Lenn, Steven C. Nakoneshny, Joseph C. Dort, Janice L. Pasieka, Shamir P. Chandarana. 2016. Practice patterns among thyroid cancer surgeons: implications of performing a prophylactic central neck dissection. *Journal of Otolaryngology - Head & Neck Surgery* **45**:1. . [Crossref]

2535. Johann-Martin Hempel, Roman Kloeckner, Sandra Krick, Daniel Pinto dos Santos, Simin Schadmand-Fischer, Patrick Boeßert, Sotirios Bisdas, Matthias M. Weber, Christian Fottner, Thomas J. Musholt, Mathias Schreckenberger, Matthias Miederer. 2016. Impact of combined FDG-PET/CT and MRI on the detection of local recurrence and nodal metastases in thyroid cancer. *Cancer Imaging* **16**:1. . [Crossref]

2536. Shrikant Tamhane, Hossein Gharib. 2016. Thyroid nodule update on diagnosis and management. *Clinical Diabetes and Endocrinology* **2**:1. . [Crossref]

2537. N Brusca, C Virili, M Cellini, S Capriello, L Gargano, R Salvatori, M Centanni, M G Santaguida. 2016. Early detection of biochemically occult autonomous thyroid nodules. *European Journal of Endocrinology* **175**:6, 615-622. [Crossref]

2538. Pedro Weslley Rosario, Gabriela Franco Mourão, Maurício Buzelin Nunes, Marcelo Saldanha Nunes, Maria Regina Calsolari. 2016. Noninvasive follicular thyroid neoplasm with papillary-like nuclear features. *Endocrine-Related Cancer* **23**:12, 893-897. [Crossref]

2539. Ming Zhang, Oscar Lin. 2016. Molecular Testing of Thyroid Nodules: A Review of Current Available Tests for Fine-Needle Aspiration Specimens. *Archives of Pathology & Laboratory Medicine* **140**:12, 1338-1344. [Crossref]

2540. José Gardiazabal, Philipp Matthies, Jakob Vogel, Benjamin Frisch, Nassir Navab, Sibylle Ziegler, Tobias Lasser. 2016. Flexible mini gamma camera reconstructions of extended sources using step and shoot and list mode. *Medical Physics* **43**:12, 6418-6428. [Crossref]

2541. Livhits Masha J., Yeh Michael W.. 2016. Delaying Radioactive Iodine Ablation for up to One Year Does Not Increase Recurrence for Patients with Differentiated Thyroid Cancer. *Clinical Thyroidology* **28**:11, 346-348. [Citation] [Full Text] [PDF] [PDF Plus]

2542. Zhang Mingbo, Luo Yukun, Zhang Yan, Tang Jie. 2016. Efficacy and Safety of Ultrasound-Guided Radiofrequency Ablation for Treating Low-Risk Papillary Thyroid Microcarcinoma: A Prospective Study. *Thyroid* **26**:11, 1581-1587. [Abstract] [Full Text] [PDF] [PDF Plus]

2543. Zwarthoed Colette, Chatti Kaouthar, Guglielmi Julien, Hichri Maha, Compin Cathy, Darcourt Jacques, Vassaux Georges, Benisvy Danielle, Pourcher Thierry, Cambien Béatrice. 2016. Single-Photon Emission Computed Tomography for Preclinical Assessment of Thyroid Radioiodide Uptake Following Various Combinations of Preparative Measures. *Thyroid* **26**:11, 1614-1622. [Abstract] [Full Text] [PDF] [PDF Plus]

2544. Scheffel Rafael Selbach, Zanella André B., Dora José Miguel, Maia Ana Luiza. 2016. Timing of Radioactive Iodine Administration Does Not Influence Outcomes in Patients with Differentiated Thyroid Carcinoma. *Thyroid* **26**:11, 1623-1629. [Abstract] [Full Text] [PDF] [PDF Plus]

2545. Ippolito Serena, Ippolito Renato, Peirce Carmela, Esposito Roberta, Arpaia Debora, Santoro Ciro, Pontieri Gilda, Cocozza Sara, Galderisi Maurizio, Biondi Bernadette. 2016. Recombinant Human Thyrotropin Improves Endothelial Coronary Flow Reserve in Thyroidectomized Patients with Differentiated Thyroid Cancer. *Thyroid* **26**:11, 1528-1534. [Abstract] [Full Text] [PDF] [PDF Plus]

Downloaded by Memorial Sloan Kettering from www.liebertpub.com at 08/14/19. For personal use only.

2546. Espinosa De Ycaza Ana E., Lowe Kathleen M., Dean Diana S., Castro M. Regina, Fatourechi Vahab, Ryder Mabel, Morris John C., Stan Marius N.. 2016. Risk of Malignancy in Thyroid Nodules with Non-Diagnostic Fine-Needle Aspiration: A Retrospective Cohort Study. *Thyroid* **26**:11, 1598-1604. [Abstract] [Full Text] [PDF] [PDF Plus]

2547. Xu Bin, Ibrahimpasic Tihana, Wang Laura, Sabra Mona M., Migliacci Jocelyn C., Tuttle R. Michael, Ganly Ian, Ghossein Ronald. 2016. Clinicopathologic Features of Fatal Non-Anaplastic Follicular Cell–Derived Thyroid Carcinomas. *Thyroid* **26**:11, 1588-1597. [Abstract] [Full Text] [PDF] [PDF Plus]

2548. Pankratz Daniel G., Hu Zhanzhi, Kim Su Yeon, Monroe Robert J., Wong Mei G., Traweek S. Thomas, Kloos Richard T., Walsh P. Sean, Kennedy Giulia C.. 2016. Analytical Performance of a Gene Expression Classifier for Medullary Thyroid Carcinoma. *Thyroid* **26**:11, 1573-1580. [Abstract] [Full Text] [PDF] [PDF Plus]

2549. Elmira Amirazodi, Evan J. Propst, Catherine T. Chung, Dimitri A. Parra, Jonathan D. Wasserman. 2016. Pediatric thyroid FNA biopsy: Outcomes and impact on management over 24 years at a tertiary care center. *Cancer Cytopathology* **124**:11, 801-810. [Crossref]

2550. Jeffrey F. Krane, Erik K. Alexander, Edmund S. Cibas, Justine A. Barletta. 2016. Coming to terms with NIFTP: A provisional approach for cytologists. *Cancer Cytopathology* **124**:11, 767-772. [Crossref]

2551. Hu Hei, Yongping Song, Jianwu Qin. 2016. A nomogram predicting contralateral central neck lymph node metastasis for papillary thyroid carcinoma. *Journal of Surgical Oncology* **114**:6, 703-707. [Crossref]

2552. Ilya Likhterov, R. Michael Tuttle, Grace C. Haser, Henry K. Su, Donald Bergman, Eran E. Alon, Victor Bernet, Elise Brett, Rhoda Cobin, Eliza H. Dewey, Gerard Doherty, Laura L. Dos Reis, Joshua Klopper, Stephanie L. Lee, Mark A. Lupo, Josef Machac, Jeffrey I. Mechanick, Mira Milas, Lisa Orloff, Gregory Randolph, Douglas S. Ross, Meghan E. Rowe, Robert Smallridge, David Terris, Ralph P. Tufano, Mark L. Urken. 2016. Improving the adoption of thyroid cancer clinical practice guidelines. *The Laryngoscope* **126**:11, 2640-2645. [Crossref]

2553. Davut Sakız, Ahmet Kaya, Mustafa Kulaksizoglu. 2016. Serum Selenium Levels in Euthyroid Nodular Thyroid Diseases. *Biological Trace Element Research* **174**:1, 21-26. [Crossref]

2554. Livia Lamartina, Teresa Montesano, Fabiana Trulli, Marco Attard, Massimo Torlontano, Rocco Bruno, Domenico Meringolo, Fabio Monzani, Salvatore Tumino, Giuseppe Ronga, Marianna Maranghi, Marco Biffoni, Sebastiano Filetti, Cosimo Durante. 2016. Papillary thyroid carcinomas with biochemical incomplete or indeterminate responses to initial treatment: repeat stimulated thyroglobulin assay to identify disease-free patients. *Endocrine* **54**:2, 467-475. [Crossref]

2555. Tomasz Stokowy, Bartosz Wojtas, Barbara Jarzab, Knut Krohn, David Fredman, Henning Dralle, Thomas Musholt, Steffen Hauptmann, Dariusz Lange, László Hegedüs, Ralf Paschke, Markus Eszlinger. 2016. Two-miRNA classifiers differentiate mutation-negative follicular thyroid carcinomas and follicular thyroid adenomas in fine needle aspirations with high specificity. *Endocrine* **54**:2, 440-447. [Crossref]

2556. Naykky Singh Ospina, Spyridoula Maraka, Ana E. Espinosa De Ycaza, Hyeong Sik Ahn, M. Regina Castro, John C. Morris, Victor M. Montori, Juan P. Brito. 2016. Physical exam in asymptomatic people drivers the detection of thyroid nodules undergoing ultrasound guided fine needle aspiration biopsy. *Endocrine* **54**:2, 433-439. [Crossref]

2557. Sophie Leboulleux, R Michael Tuttle, Furio Pacini, Martin Schlumberger. 2016. Papillary thyroid microcarcinoma: time to shift from surgery to active surveillance?. *The Lancet Diabetes & Endocrinology* **4**:11, 933-942. [Crossref]

2558. Jong-Lyel Roh, Ji Won Kim. 2016. Reply to a Letter to the Editor: can we really consider tumor size and surgical extent as predictive factors for recurrence in clinically early-stage papillary thyroid carcinoma patients?. *The American Journal of Surgery* **212**:5, 1031-1032. [Crossref]

2559. Marcelo C. Batista, Carlos E.S. Ferreira, Paulo R.S. Ferreira, Adriana C.L. Faulhaber, André L.O. Silva, Cristóvão L.P. Mangueira. 2016. Analytical and clinical validation of the new ultrasensitive Roche thyroglobulin II assay. *Clinical Biochemistry* . [Crossref]

2560. José-Manuel Gómez-Sáez. 2016. Sunitinib for the treatment of thyroid cancer. *Expert Opinion on Investigational Drugs* **25**:11, 1345-1352. [Crossref]

2561. Chin Hu, Chun-Peng Liu, Jin-Shiung Cheng, Yu-Li Chiu, Hung-Pin Chan, Nan-Jing Peng. 2016. Application of whole-body FDG-PET for cancer screening in a cohort of hospital employees. *Medicine* **95**:44, e5131. [Crossref]

2562. Chenlei Shi, Bo Tian, Shengze Li, Tiefeng Shi, Huadong Qin, Shaoyan Liu. 2016. Enhanced identification and functional protective role of carbon nanoparticles on parathyroid in thyroid cancer surgery. *Medicine* **95**:46, e5148. [Crossref]

2563. Pedro W. Rosario, Gabriela F. Mourão, Maria Regina Calsolari. 2016. Efficacy of adjuvant therapy with 3.7 GBq radioactive iodine in intermediate-risk patients with 'higher risk features' and predictive value of postoperative nonstimulated thyroglobulin. *Nuclear Medicine Communications* **37**:11, 1148-1153. [Crossref]

Downloaded by Memorial Sloan Kettering from www.liebertpub.com at 08/14/19. For personal use only.

2564. Sachin S. Kumbhar, Ryan B. O'Malley, Tracy J. Robinson, Suresh Maximin, Neeraj Lalwani, David R. Byrd, Carolyn L. Wang. 2016. Why Thyroid Surgeons Are Frustrated with Radiologists: Lessons Learned from Pre- and Postoperative US. *RadioGraphics* **36**:7, 2141-2153. [Crossref]

2565. Sara Abu-Ghanem, Oded Cohen, Tom Raz Yarkoni, Dan M. Fliss, Moshe Yehuda. 2016. Intraoperative Frozen Section in "Suspicious for Papillary Thyroid Carcinoma" after Adoption of the Bethesda System. *Otolaryngology–Head and Neck Surgery* **155**:5, 779-786. [Crossref]

2566. Xuan Su, Caiyun He, Jiangjun Ma, Tao Tang, Xiao Zhang, Zulu Ye, Yakang Long, Qiong Shao, Jianyong Shao, Ankui Yang. 2016. RET/PTC Rearrangements Are Associated with Elevated Postoperative TSH Levels and Multifocal Lesions in Papillary Thyroid Cancer without Concomitant Thyroid Benign Disease. *PLOS ONE* **11**:11, e0165596. [Crossref]

2567. Garcilaso Riesco-Eizaguirre, Pilar Santisteban. 2016. ENDOCRINE TUMOURS: Advances in the molecular pathogenesis of thyroid cancer: lessons from the cancer genome. *European Journal of Endocrinology* **175**:5, R203-R217. [Crossref]

2568. A Kukulska, J Krajewska, Z Kołosza, E Paliczka-Cies′lik, Z Puch, E Gubała, A Król, M Kalemba, A Kropin′ska, B Jarząb. 2016. The role of FDG-PET in localization of recurrent lesions of differentiated thyroid cancer (DTC) in patients with asymptomatic hyperthyroglobulinemia in a real clinical practice. *European Journal of Endocrinology* **175**:5, 379-385. [Crossref]

2569. Hannah Nieto, Kristien Boelaert. 2016. WOMEN IN CANCER THEMATIC REVIEW: Thyroid-stimulating hormone in thyroid cancer: does it matter?. *Endocrine-Related Cancer* **23**:11, T109-T121. [Crossref]

2570. Vincenzo Marotta, Concetta Sciammarella, Annamaria Colao, Antongiulio Faggiano. 2016. Application of molecular biology of differentiated thyroid cancer for clinical prognostication. *Endocrine-Related Cancer* **23**:11, R485-R501. [Crossref]

2571. Emma Scott, Diana Learoyd, Roderick J Clifton-Bligh. 2016. Therapeutic options in papillary thyroid carcinoma: current guidelines and future perspectives. *Future Oncology* **12**:22, 2603-2613. [Crossref]

2572. Wen-Han Wang, Shang-Yan Xu, Wei-Wei Zhan. 2016. Clinicopathologic Factors and Thyroid Nodule Sonographic Features for Predicting Central Lymph Node Metastasis in Papillary Thyroid Microcarcinoma. *Journal of Ultrasound in Medicine* **35**:11, 2475-2481. [Crossref]

2573. Luis Furuya-Kanamori, Katy J.L. Bell, Justin Clark, Paul Glasziou, Suhail A.R. Doi. 2016. Prevalence of Differentiated Thyroid Cancer in Autopsy Studies Over Six Decades: A Meta-Analysis. *Journal of Clinical Oncology* **34**:30, 3672-3679. [Crossref]

2574. Athanasios Bikas, Shivangi Vachhani, Kirk Jensen, Vasyl Vasko, Kenneth D. Burman. 2016. Targeted therapies in thyroid cancer: an extensive review of the literature. *Expert Review of Clinical Pharmacology* **9**:10, 1299-1313. [Crossref]

2575. Livhits Masha J., Yeh Michael W.. 2016. Active Surveillance of Neck Nodules with Indeterminate Ultrasound Characteristics Following Thyroidectomy for Differentiated Thyroid Cancer Is Safe. *Clinical Thyroidology* **28**:10, 293-295. [Citation] [Full Text] [PDF] [PDF Plus]

2576. Parangi Sareh. 2016. Patients with Differentiated Thyroid Cancers 1 to 2 cm Are Treated Differently from Those With Tumors Smaller than 1 cm. *Clinical Thyroidology* **28**:10, 296-298. [Citation] [Full Text] [PDF] [PDF Plus]

2577. Ross Douglas S., Burch Henry B., Cooper David S., Greenlee M. Carol, Laurberg Peter, Maia Ana Luiza, Rivkees Scott A., Samuels Mary, Sosa Julie Ann, Stan Marius N., Walter Martin A.. 2016. 2016 American Thyroid Association Guidelines for Diagnosis and Management of Hyperthyroidism and Other Causes of Thyrotoxicosis. *Thyroid* **26**:10, 1343-1421. [Abstract] [Full Text] [PDF] [PDF Plus] [Supplementary Material]

2578. Wendy L. Sacks, Shikha Bose, Zachary S. Zumsteg, Ronnie Wong, Stephen L. Shiao, Glenn D. Braunstein, Allen S. Ho. 2016. Impact of Afirma gene expression classifier on cytopathology diagnosis and rate of thyroidectomy. *Cancer Cytopathology* **124**:10, 722-728. [Crossref]

2579. Alvaro A. Macias, Sunil Eappen, Ilya Malikin, Jeremy Goldfarb, Sharon Kujawa, Paul M. Konowitz, Dipti Kamani, Gregory W. Randolph. 2016. Successful intraoperative electrophysiologic monitoring of the recurrent laryngeal nerve, a multidisciplinary approach: The Massachusetts Eye and Ear Infirmary monitoring collaborative protocol with experience in over 3000 cases. *Head & Neck* **38**:10, 1487-1494. [Crossref]

2580. Amir Sabet, Ina Binse, Hong Grafe, Samer Ezziddin, Rainer Görges, Thorsten D. Poeppel, Andreas Bockisch, Sandra J. Rosenbaum-Krumme. 2016. Prognostic impact of incomplete surgical clearance of radioiodine sensitive local lymph node metastases diagnosed by post-operative 124I-NaI-PET/CT in patients with papillary thyroid cancer. *European Journal of Nuclear Medicine and Molecular Imaging* **43**:11, 1988-1994. [Crossref]

2581. Naykky Singh Ospina, Spyridoula Maraka, Ana Elena Espinosa de Ycaza, Juan P. Brito, M. Regina Castro, John C. Morris, Victor M. Montori. 2016. Prognosis of patients with benign thyroid nodules: a population-based study. *Endocrine* **54**:1, 148-155. [Crossref]

2582. Oya Topaloglu, Husniye Baser, Fatma Neslihan Cuhaci, Nuran Sungu, Abdussamed Yalcin, Reyhan Ersoy, Bekir Cakir. 2016. Malignancy is associated with microcalcification and higher AP/T ratio in ultrasonography, but not with Hashimoto's thyroiditis

Downloaded by Memorial Sloan Kettering from www.liebertpub.com at 08/14/19. For personal use only.

in histopathology in patients with thyroid nodules evaluated as Bethesda Category III (AUS/FLUS) in cytology. *Endocrine* **54**:1, 156-168. [Crossref]

2583. M. Moleti, G. Sturniolo, F. Vermiglio. 2016. Safety of total thyroid ablation in patients with Graves' orbitopathy. *Journal of Endocrinological Investigation* **39**:10, 1199-1201. [Crossref]

2584. M. G. Castagna, S. Cantara, F. Pacini. 2016. Reappraisal of the indication for radioiodine thyroid ablation in differentiated thyroid cancer patients. *Journal of Endocrinological Investigation* **39**:10, 1087-1094. [Crossref]

2585. Antonio Matrone, Rossella Elisei. 2016. La scintigrafia con 99mTecnezio-metossi-isobutil-isonitrile è una metodica utile per caratterizzare il rischio di malignità nei noduli tiroidei a citologia indeterminata. *L'Endocrinologo* **17**:5, 272-273. [Crossref]

2586. Myriem Boufraqech, Joanna Klubo-Gwiezdzinska, Electron Kebebew. 2016. MicroRNAs in the thyroid. *Best Practice & Research Clinical Endocrinology & Metabolism* **30**:5, 603-619. [Crossref]

2587. Ana Lopez-Campistrous, Esther Ekpe Adewuyi, Matthew G.K. Benesch, Yi Man Ko, Raymond Lai, Aducio Thiesen, Jay Dewald, Peng Wang, Karen Chu, Sunita Ghosh, David C. Williams, Larissa J. Vos, David N. Brindley, Todd P.W. McMullen. 2016. PDGFRα Regulates Follicular Cell Differentiation Driving Treatment Resistance and Disease Recurrence in Papillary Thyroid Cancer. *EBioMedicine* **12**, 86-97. [Crossref]

2588. L. Zhang, J. Yang, Q. Sun, Y. Liu, F. Liang, Z. Liu, G. Chen, S. Chen, Z. Shang, Y. Li, X. Li. 2016. Risk factors for lymph node metastasis in papillary thyroid microcarcinoma: Older patients with fewer lymph node metastases. *European Journal of Surgical Oncology (EJSO)* **42**:10, 1478-1482. [Crossref]

2589. I.J. Nixon, C. Suárez, R. Simo, A. Sanabria, P. Angelos, A. Rinaldo, J.P. Rodrigo, L.P. Kowalski, D.M. Hartl, M.L. Hinni, J.P. Shah, A. Ferlito. 2016. The impact of family history on non-medullary thyroid cancer. *European Journal of Surgical Oncology (EJSO)* **42**:10, 1455-1463. [Crossref]

2590. Gonzalo Díaz-Soto, Beatriz Torres, Juan Jose López Gómez, Emilia Gómez Hoyos, Aurelia Villar, Enrique Romero, Daniel A. de Luis. 2016. Economic impact of and satisfaction with a high resolution thyroid nodule clinic at the endocrinology department. *Endocrinología y Nutrición (English Edition)* **63**:8, 414-420. [Crossref]

2591. Gonzalo Díaz-Soto, Beatriz Torres, Juan Jose López Gómez, Emilia Gómez Hoyos, Aurelia Villar, Enrique Romero, Daniel A. de Luis. 2016. Impacto económico y satisfacción de la implantación de una consulta de alta resolución de patología nodular tiroidea en Endocrinología. *Endocrinología y Nutrición* **63**:8, 414-420. [Crossref]

2592. Travis M. Cotton, Jing Xin, John Sandyhya, Roy Lirov, Barbara S. Miller, Mark S. Cohen, Paul G. Gauger, David T. Hughes. 2016. Frozen section analysis in the post-Bethesda era. *Journal of Surgical Research* **205**:2, 393-397. [Crossref]

2593. Chen-Tian Shen, Wei-Jun Wei, Zhong-Ling Qiu, Hong-Jun Song, Quan-Yong Luo. 2016. Afamin promotes glucose metabolism in papillary thyroid carcinoma. *Molecular and Cellular Endocrinology* **434**, 108-115. [Crossref]

2594. Chad M. Hall, Samuel K. Snyder, Yolanda Muñoz Maldonado, Terry C. Lairmore. 2016. Routine central lymph node dissection with total thyroidectomy for papillary thyroid cancer potentially minimizes level VI recurrence. *Surgery* **160**:4, 1049-1058. [Crossref]

2595. Elisabeth Joye Petr, Tobias Else. 2016. Genetic predisposition to endocrine tumors: Diagnosis, surveillance and challenges in care. *Seminars in Oncology* **43**:5, 582-590. [Crossref]

2596. Wenbin Yu, Lijun Zhu, Guohui Xu, Yuntao Song, Guojun Li, Naisong Zhang. 2016. Potential role of carbon nanoparticles in protection of parathyroid glands in patients with papillary thyroid cancer. *Medicine* **95**:42, e5002. [Crossref]

2597. Flavia Magri, Spyridon Chytiris, Luca Chiovato. 2016. The role of elastography in thyroid ultrasonography. *Current Opinion in Endocrinology & Diabetes and Obesity* **23**:5, 416-422. [Crossref]

2598. Enrico Papini, Rinaldo Gugliemi, Claudio Maurizio Pacella. 2016. Laser, radiofrequency, and ethanol ablation for the management of thyroid nodules. *Current Opinion in Endocrinology & Diabetes and Obesity* **23**:5, 400-406. [Crossref]

2599. Pedro W. Rosario, Gabriela F. Mourão, Maria R. Calsolari. 2016. Long-term results of ablation with low radioiodine activity in patients with papillary thyroid carcinoma and predictive value of postoperative nonstimulated thyroglobulin. *Nuclear Medicine Communications* **37**:10, 1024-1029. [Crossref]

2600. Pedro Weslley Rosario, Gabriela Franco Mourão, Maria Regina Calsolari. 2016. Can the follow-up of patients with papillary thyroid carcinoma of low and intermediate risk and excellent response to initial therapy be simplified using second-generation thyroglobulin assays?. *Clinical Endocrinology* **85**:4, 596-601. [Crossref]

2601. Maria Lytrivi, Aglaia Kyrilli, Agnès Burniat, Maria Ruiz Patino, Youri Sokolow, Bernard Corvilain. 2016. Thyroid lobectomy is an effective option for unilateral benign nodular disease. *Clinical Endocrinology* **85**:4, 602-608. [Crossref]

2602. Emmanuel Labourier. 2016. Utility and cost-effectiveness of molecular testing in thyroid nodules with indeterminate cytology. *Clinical Endocrinology* **85**:4, 624-631. [Crossref]

Downloaded by Memorial Sloan Kettering from www.liebertpub.com at 08/14/19. For personal use only.

2603. Brian Hung-Hin Lang, Carlos K. H. Wong. 2016. Lobectomy is a more Cost-Effective Option than Total Thyroidectomy for 1 to 4 cm Papillary Thyroid Carcinoma that do not Possess Clinically Recognizable High-Risk Features. *Annals of Surgical Oncology* **23**:11, 3641-3652. [Crossref]

2604. Cesar Luiz Boguszewski, John Ayuk. 2016. MANAGEMENT OF ENDOCRINE DISEASE: Acromegaly and cancer: an old debate revisited. *European Journal of Endocrinology* **175**:4, R147-R156. [Crossref]

2605. Ceyla Konca Degertekin, Mehmet Muhittin Yalcin, Turgay Cerit, Cigdem Ozkan, Isilay Kalan, Ozlem Turhan Iyidir, Alev Eroglu Altinova, Mujde Akturk, Fusun Toruner, Murat Akin, Nuri Cakir. 2016. Lymph node fine-needle aspiration washout thyroglobulin in papillary thyroid cancer: Diagnostic value and the effect of thyroglobulin antibodies. *Endocrine Research* **41**:4, 281-289. [Crossref]

2606. Carmen V. Villabona, Vineeth Mohan, Karla M. Arce, Julia Diacovo, Alisha Aggarwal, Jessica Betancourt, Hassan Amer, Tessey Jose, Pascual DeSantis, Jose Cabral. 2016. UTILITY OF ULTRASOUND VERSUS GENE EXPRESSION CLASSIFIER IN THYROID NODULES WITH ATYPIA OF UNDETERMINED SIGNIFICANCE. *Endocrine Practice* **22**:10, 1199-1203. [Crossref]

2607. Elliot A. Krauss, Megan Mahon, Jean M. Fede, Lanjing Zhang. 2016. Application of the Bethesda Classification for Thyroid Fine-Needle Aspiration: Institutional Experience and Meta-analysis. *Archives of Pathology & Laboratory Medicine* **140**:10, 1121-1131. [Crossref]

2608. Jueru Zheng, Jianjun Li. 2016. Serum miRNA-203 expression, a potential biomarker for recurrence and prognosis in papillary thyroid carcinoma. *Cancer Biomarkers* 1-7. [Crossref]

2609. Gustavo Cancela e Penna. 2016. Thyroid Nodule <1cm and Low-Risk Papillary Thyroid Microcarcinoma: What are today's Management Options?. *Endocrinology&Metabolism International Journal* **3**:4. . [Crossref]

2610. James A. Fagin, Samuel A. Wells. 2016. Biologic and Clinical Perspectives on Thyroid Cancer. *New England Journal of Medicine* **375**:11, 1054-1067. [Crossref]

2611. Pembegul Gunes, Sule Canberk, Mine Onenerk, Murat Erkan, Nilufer Gursan, Emine Kilinc, Gamze Zeynep Kilicoglu. 2016. A Different Perspective on Evaluating the Malignancy Rate of the Non-Diagnostic Category of the Bethesda System for Reporting Thyroid Cytopathology: A Single Institute Experience and Review of the Literature. *PLOS ONE* **11**:9, e0162745. [Crossref]

2612. Marine Renard, Belén Lloveras, Juana Flores, Jaume Puig, David Benaiges, Antonio Sitges-Serra. 2016. Current dilemmas in the diagnosis and management of follicular thyroid tumors. *Expert Review of Endocrinology & Metabolism* **11**:5, 379-385. [Crossref]

2613. Livhits Masha J., Yeh Michael W.. 2016. Many Thyroid Cancers Detected by Afirma Gene-Expression Classifier Are Noninvasive Encapsulated Follicular Variant of Papillary Thyroid Carcinoma. *Clinical Thyroidology* **28**:9, 261-263. [Citation] [Full Text] [PDF] [PDF Plus]

2614. Jindal Ankur, Khan Uzma. 2016. Is Thyroglobulin Level by Liquid Chromatography Tandem-Mass Spectrometry Always Reliable for Follow-Up of DTC After Thyroidectomy: A Report on Two Patients. *Thyroid* **26**:9, 1334-1335. [Citation] [Full Text] [PDF] [PDF Plus]

2615. Valderrabano Pablo, Montilla-Soler Jaime, Mifsud Mathew, Leon Marino, Centeno Barbara, Khazai Laila, Padhya Tapan, McCaffrey Thomas, Russell Jeffery, McIver Bryan, Otto Kristen. 2016. Hypermetabolism on 18F-Fluorodeoxyglucose Positron Emission Tomography Scan Does Not Influence the Interpretation of Thyroid Cytopathology, and Nodules with a SUVmax <2.5 Are Not at Increased Risk for Malignancy. *Thyroid* **26**:9, 1300-1307. [Abstract] [Full Text] [PDF] [PDF Plus]

2616. Nixon Iain J., Simo Ricard, Newbold Kate, Rinaldo Alessandra, Suarez Carlos, Kowalski Luiz P., Silver Carl, Shah Jatin P., Ferlito Alfio. 2016. Management of Invasive Differentiated Thyroid Cancer. *Thyroid* **26**:9, 1156-1166. [Abstract] [Full Text] [PDF] [PDF Plus]

2617. Malandrino Pasqualino, Russo Marco, Regalbuto Concetto, Pellegriti Gabriella, Moleti Mariacarla, Caff Andrea, Squatrito Sebastiano, Vigneri Riccardo. 2016. Outcome of the Diffuse Sclerosing Variant of Papillary Thyroid Cancer: A Meta-Analysis. *Thyroid* **26**:9, 1285-1292. [Abstract] [Full Text] [PDF] [PDF Plus]

2618. Likhterov Ilya, Osorio Marcela, Moubayed Sami P., Hernandez-Prera Juan C., Rhodes Rosamond, Urken Mark L.. 2016. The Ethical Implications of the Reclassification of Noninvasive Follicular Variant Papillary Thyroid Carcinoma. *Thyroid* **26**:9, 1167-1172. [Abstract] [Full Text] [PDF] [PDF Plus]

2619. Zubair W. Baloch, Raja R. Seethala, William C. Faquin, Mauro G. Papotti, Fulvio Basolo, Guido Fadda, Gregory W. Randolph, Steven P. Hodak, Yuri E. Nikiforov, Susan J. Mandel. 2016. Noninvasive follicular thyroid neoplasm with papillary-like nuclear features (NIFTP): A changing paradigm in thyroid surgical pathology and implications for thyroid cytopathology. *Cancer Cytopathology* **124**:9, 616-620. [Crossref]

2620. Michelle Horton, Laura Been, Cherry Starling, S. Thomas Traweek. 2016. The utility of cellient cell blocks in low-cellularity thyroid fine needle aspiration biopsies. *Diagnostic Cytopathology* **44**:9, 737-741. [Crossref]

Downloaded by Memorial Sloan Kettering from www.liebertpub.com at 08/14/19. For personal use only.

2621. Alexis Vrachimis, Lars Stegger, Christian Wenning, Benjamin Noto, Matthias Christian Burg, Julia Renate Konnert, Thomas Allkemper, Walter Heindel, Burkhard Riemann, Michael Schäfers, Matthias Weckesser. 2016. [68Ga]DOTATATE PET/MRI and [18F]FDG PET/CT are complementary and superior to diffusion-weighted MR imaging for radioactive-iodine-refractory differentiated thyroid cancer. *European Journal of Nuclear Medicine and Molecular Imaging* **43**:10, 1765-1772. [Crossref]

2622. Naykky Singh Ospina, Juan P. Brito, Spyridoula Maraka, Ana E. Espinosa de Ycaza, Rene Rodriguez-Gutierrez, Michael R. Gionfriddo, Ana Castaneda-Guarderas, Khalid Benkhadra, Alaa Al Nofal, Patricia Erwin, John C. Morris, M. Regina Castro, Victor M. Montori. 2016. Diagnostic accuracy of ultrasound-guided fine needle aspiration biopsy for thyroid malignancy: systematic review and meta-analysis. *Endocrine* **53**:3, 651-661. [Crossref]

2623. Maria Joana Santos, Maria João Bugalho. 2016. Papillary thyroid carcinoma: different clinical behavior among pT3 tumors. *Endocrine* **53**:3, 754-760. [Crossref]

2624. Paolo Goffredo, Timothy J. Robinson, Linda M. Youngwirth, Sanziana A. Roman, Julie A. Sosa. 2016. Intensity-modulated radiation therapy use for the localized treatment of thyroid cancer: Nationwide practice patterns and outcomes. *Endocrine* **53**:3, 761-773. [Crossref]

2625. Hasan Gucer, Pelin Bagci, Recep Bedir, Ibrahim Sehitoglu, Ozgur Mete. 2016. The Value of HBME-1 and Claudin-1 Expression Profile in the Distinction of BRAF-Like and RAS-Like Phenotypes in Papillary Thyroid Carcinoma. *Endocrine Pathology* **27**:3, 224-232. [Crossref]

2626. Tao Wang, Ian Blumer, Scott Boerner, Sylvia L. Asa. 2016. Synchronous Papillary Carcinoma of Thyroid and Lung. *Endocrine Pathology* **27**:3, 268-270. [Crossref]

2627. S. Bernardi, F. Stacul, M. Zecchin, C. Dobrinja, F. Zanconati, B. Fabris. 2016. Radiofrequency ablation for benign thyroid nodules. *Journal of Endocrinological Investigation* **39**:9, 1003-1013. [Crossref]

2628. Marc Pusztaszeri, Esther Diana Rossi, Manon Auger, Zubair Baloch, Justin Bishop, Massimo Bongiovanni, Ashish Chandra, Beatrix Cochand-Priollet, Guido Fadda, Mitsuyoshi Hirokawa, SoonWong Hong, Kennichi Kakudo, Jeffrey F. Krane, Ritu Nayar, Sareh Parangi, Fernando Schmitt, William C. Faquin. 2016. The Bethesda System for Reporting Thyroid Cytopathology: proposed modifications and updates for the second edition from an international panel. *Journal of the American Society of Cytopathology* **5**:5, 245-251. [Crossref]

2629. Carolina Franco Uliaque, Francisco Javier Pardo Berdún, Ricardo Laborda Herrero, Carmen Pérez Lórenz. 2016. Utilidad de la ecografía en la evaluación de los nódulos tiroideos. *Radiología* **58**:5, 380-388. [Crossref]

2630. C. Franco Uliaque, F.J. Pardo Berdún, R. Laborda Herrero, C. Pérez Lórenz. 2016. Usefulness of ultrasonography is the evaluation of thyroid nodules. *Radiología (English Edition)* **58**:5, 380-388. [Crossref]

2631. C. Franco Uliaque, F.J. Pardo Berdún, R. Laborda Herrero, C. Pérez Lórenz. 2016. Usefulness of semiquantitative elastography in predicting malignancy in thyroid nodules. *Radiología (English Edition)* **58**:5, 366-372. [Crossref]

2632. Laura Y. Wang, Iain J. Nixon, Snehal G. Patel, Frank L. Palmer, R. Michael Tuttle, Ashok Shaha, Jatin P. Shah, Ian Ganly. 2016. Operative management of locally advanced, differentiated thyroid cancer. *Surgery* **160**:3, 738-746. [Crossref]

2633. Xiaoyun Liu, Lijun Zhu, Zhixiao Wang, Dai Cui, Huanhuan Chen, Yu Duan, Meiping Shen, Hui Lu, Zhihong Zhang, Jiawei Chen, Erik K. Alexander, Tao Yang, Xiaodong Wang. 2016. Evolutionary features of thyroid cancer in patients with thyroidectomies from 2008 to 2013 in China. *Scientific Reports* **6**:1. . [Crossref]

2634. Rachel Q. Liu, Sam M. Wiseman. 2016. Quality indicators for thyroid cancer surgery: current perspective. *Expert Review of Anticancer Therapy* **16**:9, 919-928. [Crossref]

2635. Christoph Reiners, Rita Schneider, Makoshi Akashi, Eli A. Akl, Jean-René Jourdain, Chunsheng Li, Christoph Murith, Lodewijk Van Bladel, Shunichi Yamashita, Hajo Zeeb, Paolo Vitti, Zhanat Carr. 2016. The First Meeting of the WHO Guideline Development Group for the Revision of the WHO 1999 Guidelines for Iodine Thyroid Blocking. *Radiation Protection Dosimetry* **171**:1, 47-56. [Crossref]

2636. Byeong-Cheol Ahn. 2016. Reinforcing the Ability of 99mTcO4 Scintigraphy for Identifying Differentiated Thyroid Cancer by TSH Stimulation. *Clinical Nuclear Medicine* **41**:9, e412-e413. [Crossref]

2637. Pedro Weslley Rosario, Gabriela Franco Mourão, Maria Regina Calsolari. 2016. Low postoperative nonstimulated thyroglobulin as a criterion for the indication of low radioiodine activity in patients with papillary thyroid cancer of intermediate risk 'with higher risk features'. *Clinical Endocrinology* **85**:3, 453-458. [Crossref]

2638. Taciana Padilha de Castro, William Waissmann, Taynãna César Simões, Rossana Corbo R. de Mello, Denise P. Carvalho. 2016. Predictors for papillary thyroid cancer persistence and recurrence: a retrospective analysis with a 10-year follow-up cohort study. *Clinical Endocrinology* **85**:3, 466-474. [Crossref]

Downloaded by Memorial Sloan Kettering from www.liebertpub.com at 08/14/19. For personal use only.

2639. Gi Hyeon Seo, Young Jun Chai, Hyung Jin Choi, Kyu Eun Lee. 2016. Incidence of permanent hypocalcaemia after total thyroidectomy with or without central neck dissection for thyroid carcinoma: a nationwide claim study. *Clinical Endocrinology* **85**:3, 483-487. [Crossref]

2640. Tatiana Kelil, Abhishek R. Keraliya, Stephanie A. Howard, Katherine M. Krajewski, Marta Braschi-Amirfarzan, Jason L. Hornick, Nikhil H. Ramaiya, Sree Harsha Tirumani. 2016. Current Concepts in the Molecular Genetics and Management of Thyroid Cancer: An Update for Radiologists. *RadioGraphics* **36**:5, 1478-1493. [Crossref]

2641. Adnan R. Zayadeen, Monzer Abu-Yousef, Kevin Berbaum. 2016. JOURNAL CLUB: Retrospective Evaluation of Ultrasound Features of Thyroid Nodules to Assess Malignancy Risk: A Step Toward TIRADS. *American Journal of Roentgenology* **207**:3, 460-469. [Crossref]

2642. Pan Chen, Hui-juan Feng, Wei Ouyang, Ju-qing Wu, Jing Wang, Yun-gang Sun, Jia-lang Xian, Liu-hua Huang. 2016. RISK FACTORS FOR NONREMISSION AND PROGRESSION-FREE SURVIVAL AFTER I-131 THERAPY IN PATIENTS WITH LUNG METASTASIS FROM DIFFERENTIATED THYROID CANCER: A SINGLE-INSTITUTE, RETROSPECTIVE ANALYSIS IN SOUTHERN CHINA. *Endocrine Practice* **22**:9, 1048-1056. [Crossref]

2643. Roberto Cesareo, Anda Naciu, Antonio Barberi, Valerio Pasqualini, Giuseppe Pelle, Silvia Manfrini, Gaia Tabacco, Angelo Lauria Pantano, Giuseppe Campagna, Roberto Cianni, Andrea Palermo. 2016. A Rare and Severe Complication Following Thyroid Fine Needle Aspiration: Retropharyngeal Cellulitis. *International Journal of Endocrinology and Metabolism* **14**:4. . [Crossref]

2644. Jolanta Krajewska, Aleksandra Kukulska, Barbara Jarzab. 2016. Efficacy of lenvatinib in treating thyroid cancer. *Expert Opinion on Pharmacotherapy* **17**:12, 1683-1691. [Crossref]

2645. Venessa H. M. Tsang, Bruce G. Robinson, Diana L. Learoyd. 2016. The safety of vandetanib for the treatment of thyroid cancer. *Expert Opinion on Drug Safety* **15**:8, 1107-1113. [Crossref]

2646. Malhi Harshawn, Grant Edward. 2016. Both TIRADS and the ATA Guidelines Provide Effective Malignancy Risk Stratification for
Thyroid Nodules. *Clinical Thyroidology* **28**:8, 238-240. [Citation] [Full Text] [PDF] [PDF Plus]

2647. White Michael G., Cipriani Nicole A., Abdulrasool Layth, Kaplan Sharone, Aschebrook-Kilfoy Briseis, Angelos Peter, Kaplan Edwin L., Grogan Raymon H., Onel Kenan. 2016. Radiation-Induced Differentiated Thyroid Cancer Is Associated with Improved Overall Survival but Not Thyroid Cancer–Specific Mortality or Disease-Free Survival. *Thyroid* **26**:8, 1053-1060. [Abstract] [Full Text] [PDF] [PDF Plus] [Supplementary Material]

2648. Hirsch Dania, Shohat Tzippy, Gorshtein Alex, Robenshtok Eyal, Shimon Ilan, Benbassat Carlos. 2016. Incidence of Nonthyroidal Primary Malignancy and the Association with 131I Treatment in Patients with Differentiated Thyroid Cancer. *Thyroid* **26**:8, 1110-1116. [Abstract] [Full Text] [PDF] [PDF Plus]

2649. Shrestha Rupendra T., Evasovich Maria R., Amin Khalid, Radulescu Angela, Sanghvi Tina S., Nelson Andrew C., Shahi Maryam, Burmeister Lynn A.. 2016. Correlation Between Histological Diagnosis and Mutational Panel Testing of Thyroid Nodules: A Two-Year Institutional Experience. *Thyroid* **26**:8, 1068-1076. [Abstract] [Full Text] [PDF] [PDF Plus]

2650. Anderson Kevin L. Jr., Youngwirth Linda M., Scheri Randall P., Stang Michael T., Roman Sanziana A., Sosa Julie A.. 2016. T1a Versus T1b Differentiated Thyroid Cancers: Do We Need to Make the Distinction?. *Thyroid* **26**:8, 1046-1052. [Abstract] [Full Text] [PDF] [PDF Plus]

2651. Campennì Alfredo, Giovanella Luca, Siracusa Massimiliano, Alibrandi Angela, Pignata Salvatore A., Giovinazzo Salvatore, Trimarchi Francesco, Ruggeri Rosaria M., Baldari Sergio. 2016. 99mTc-Methoxy-Isobutyl-Isonitrile Scintigraphy Is a Useful Tool for Assessing the Risk of Malignancy in Thyroid Nodules with Indeterminate Fine-Needle Cytology. *Thyroid* **26**:8, 1101-1109. [Abstract] [Full Text] [PDF] [PDF Plus]

2652. Valderrabano Pablo, Klippenstein Donald L., Tourtelot John B., Ma Zhenjun, Thompson Zachary J., Lilienfeld Howard S., McIver Bryan. 2016. New American Thyroid Association Sonographic Patterns for Thyroid Nodules Perform Well in Medullary Thyroid Carcinoma: Institutional Experience, Systematic Review, and Meta-Analysis. *Thyroid* **26**:8, 1093-1100. [Abstract] [Full Text] [PDF] [PDF Plus]

2653. Carrie C. Lubitz, Julie A. Sosa. 2016. The changing landscape of papillary thyroid cancer: Epidemiology, management, and the implications for patients. *Cancer* . [Crossref]

2654. Jieun Koh, Hee Jung Moon, Eun-Kyung Kim, Jin Young Kwak, Jung Hyun Yoon. 2016. The 5-tiered categorization system for reporting cytology is sufficient for management of patients with thyroid nodules compared to the 6-tiered Bethesda system. *Endocrine* **53**:2, 489-496. [Crossref]

2655. Gustav Stenson, Inga-Lena Nilsson, Ninni Mu, Catharina Larsson, Catharina Ihre Lundgren, C. Christofer Juhlin, Anders Höög, Jan Zedenius. 2016. Minimally invasive follicular thyroid carcinomas: prognostic factors. *Endocrine* **53**:2, 505-511. [Crossref]

Downloaded by Memorial Sloan Kettering from www.liebertpub.com at 08/14/19. For personal use only.

2656. Mnahi Bin Saeedan, Ibtisam Musallam Aljohani, Ayman Omar Khushaim, Salwa Qasim Bukhari, Salahudin Tayeb Elnaas. 2016. Thyroid computed tomography imaging: pictorial review of variable pathologies. *Insights into Imaging* **7**:4, 601-617. [Crossref]

2657. Q. Zhao, G. Tian, D. Kong, T. Jiang. 2016. Meta-analysis of radiofrequency ablation for treating the local recurrence of thyroid cancers. *Journal of Endocrinological Investigation* **39**:8, 909-916. [Crossref]

2658. L. Rosato, C. De Crea, R. Bellantone, M. L. Brandi, G. De Toma, S. Filetti, P. Miccoli, F. Pacini, M. R. Pelizzo, A. Pontecorvi, N. Avenia, L. De Pasquale, M. G. Chiofalo, A. Gurrado, N. Innaro, G. La Valle, C. P. Lombardi, P. L. Marini, G. Mondini, B. Mullineris, L. Pezzullo, M. Raffaelli, M. Testini, M. De Palma. 2016. Diagnostic, therapeutic and health-care management protocol in thyroid surgery: a position statement of the Italian Association of Endocrine Surgery Units (U.E.C. CLUB). *Journal of Endocrinological Investigation* **39**:8, 939-953. [Crossref]

2659. Michael Canfarotta, Rebecca Riba-Wolman, Andrea D. Orsey, Fabiola Balarezo, Christine Finck. 2016. DICER1 syndrome and thyroid disease. *Journal of Pediatric Surgery Case Reports* **11**, 31-34. [Crossref]

2660. Marina Muzza, Carla Colombo, Valentina Cirello, Michela Perrino, Leonardo Vicentini, Laura Fugazzola. 2016. Oxidative stress and the subcellular localization of the telomerase reverse transcriptase (TERT) in papillary thyroid cancer. *Molecular and Cellular Endocrinology* **431**, 54-61. [Crossref]

2661. Marialuisa Sponziello, Francesca Rosignolo, Marilena Celano, Valentina Maggisano, Valeria Pecce, Roberta Francesca De Rose, Giovanni Enrico Lombardo, Cosimo Durante, Sebastiano Filetti, Giuseppe Damante, Diego Russo, Stefania Bulotta. 2016. Fibronectin-1 expression is increased in aggressive thyroid cancer and favors the migration and invasion of cancer cells. *Molecular and Cellular Endocrinology* **431**, 123-132. [Crossref]

2662. Yong Sub Song, Ji-hoon Kim, Dong Gyu Na, Hye Sook Min, Jae-Kyung Won, Tae Jin Yun, Seung Hong Choi, Chul-Ho Sohn. 2016. Ultrasonographic Differentiation Between Nodular Hyperplasia and Neoplastic Follicular-Patterned Lesions of the Thyroid Gland. *Ultrasound in Medicine & Biology* **42**:8, 1816-1824. [Crossref]

2663. Tianpeng Hu, Zhaowei Meng, Guizhi Zhang, Qiang Jia, Jian Tan, Wei Zheng, Renfei Wang, Xue Li, Na Liu, Pingping Zhou, Arun Upadhyaya. 2016. Influence of the first radioactive iodine ablation on peripheral complete blood count in patients with differentiated thyroid cancer. *Medicine* **95**:35, e4451. [Crossref]

2664. Andrew J. Bauer, Gary L. Francis. 2016. Evaluation and management of thyroid nodules in children. *Current Opinion in Pediatrics* **28**:4, 536-544. [Crossref]

2665. Pedro Weslley Rosário, Maria Regina Calsolari. 2016. Thyroid nodules with highly suspicious ultrasonographic features, but with benign cytology on two occasions: is malignancy still possible?. *Archives of Endocrinology and Metabolism* **60**:4, 402-404. [Crossref]

2666. Vijay Yerubandi, Jenny K. Hoang. 2016. Reply to "Thyroid Nodule Characterization Using Combined Fine-Needle Aspiration and 99m Tc-Sestamibi Scintigraphy Strategy". *American Journal of Roentgenology* **207**:2, W22-W22. [Crossref]

2667. Dana Chanes Manuel, Jessica Lee Betancourt, Nitin DK Puthanveedu, Sergey Kachur, Sandra F. Williams, Jose M. Cabral, Carmen V. Villabona, Tessey C. Jose. 2016. SHOULD FNA BE PERFORMED IN PATIENTS WITH A MULTINODULAR GOITER AND COMPRESSIVE SYMPTOMS?. *Endocrine Practice* **22**:8, 970-973. [Crossref]

2668. Cari M. Kitahara, Julie A. Sosa. 2016. The changing incidence of thyroid cancer. *Nature Reviews Endocrinology* **12**:11, 646-653. [Crossref]

2669. Carol Evans, Sarah Tennant, Petros Perros. 2016. Serum thyroglobulin in the monitoring of differentiated thyroid cancer. *Scandinavian Journal of Clinical and Laboratory Investigation* **76**:sup245, S119-S123. [Crossref]

2670. Joseph Singer, John W. Hanna, Jay Visaria, Tao Gu, Mark McCoy, Richard T. Kloos. 2016. Impact of a gene expression classifier on the long-term management of patients with cytologically indeterminate thyroid nodules. *Current Medical Research and Opinion* **32**:7, 1225-1232. [Crossref]

2671. Lee Seung Eun, Hwang Tae Sook, Choi Yoon-La, Han Hye Seung, Kim Wan Seop, Jang Min Hye, Kim Suk Kyeong, Yang Jung Hyun. 2016. Prognostic Significance of TERT Promoter Mutations in Papillary Thyroid Carcinomas in a BRAFV600E Mutation–Prevalent Population. *Thyroid* **26**:7, 901-910. [Abstract] [Full Text] [PDF] [PDF Plus]

2672. Goldfarb Melanie, Casillas Jacqueline. 2016. Thyroid Cancer–Specific Quality of Life and Health-Related Quality of Life in Young Adult Thyroid Cancer Survivors. *Thyroid* **26**:7, 923-932. [Abstract] [Full Text] [PDF] [PDF Plus] [Supplementary Material]

2673. Wong Kristine S., Angell Trevor E., Strickland Kyle C., Alexander Erik K., Cibas Edmund S., Krane Jeffrey F., Barletta Justine A.. 2016. Noninvasive Follicular Variant of Papillary Thyroid Carcinoma and the Afirma Gene-Expression Classifier. *Thyroid* **26**:7, 911-915. [Abstract] [Full Text] [PDF] [PDF Plus]

2674. Tseng Wen-Chun, Pei Yu-Cheng, Wong Alice M. K., Li Hsueh-Yu, Fang Tuan-Jen. 2016. Distinct Disease and Functional Characteristics of Thyroid Surgery–Related Vocal Fold Palsy. *Thyroid* **26**:7, 943-950. [Abstract] [Full Text] [PDF] [PDF Plus]

Downloaded by Memorial Sloan Kettering from www.liebertpub.com at 08/14/19. For personal use only.

2675. Mujammami Muhammad, Hier Michael P., Payne Richard J., Rochon Louise, Tamilia Michael. 2016. Long-Term Outcomes of Patients with Papillary Thyroid Cancer Undergoing Remnant Ablation with 30 milliCuries Radioiodine. *Thyroid* **26**:7, 951-958. [Abstract] [Full Text] [PDF] [PDF Plus]

2676. Hodak Steven, Tuttle R. Michael, Maytal Guy, Nikiforov Yuri E., Randolph Gregory. 2016. Changing the Cancer Diagnosis: The Case of Follicular Variant of Papillary Thyroid Cancer—Primum Non Nocere and NIFTP. *Thyroid* **26**:7, 869-871. [Citation] [Full Text] [PDF] [PDF Plus]

2677. Daniels Gilbert H.. 2016. Follicular Variant of Papillary Thyroid Carcinoma: Hybrid or Mixture?. *Thyroid* **26**:7, 872-874. [Citation] [Full Text] [PDF] [PDF Plus]

2678. Soo-Yeon Kim, Eun-Kyung Kim, Hee Jung Moon, Jung Hyun Yoon, Hyeong Ju Kwon, Mi Kyung Song, Jin Young Kwak. 2016. Combined use of conventional smear and liquid-based preparation versus conventional smear for thyroid fine-needle aspiration. *Endocrine* **53**:1, 157-165. [Crossref]

2679. Teng Zhao, Jun Liang, Zhenqing Guo, Jiao Li, Yansong Lin. 2016. Serum thyrotropin level of 30 μIU/mL is inadequate for preablative thyroglobulin to serve as a prognostic marker for differentiated thyroid cancer. *Endocrine* **53**:1, 166-173. [Crossref]

2680. Emmanuel Labourier. 2016. Efficiency versus effectiveness: impact of molecular testing on healthcare costs and clinical outcome of patients with indeterminate thyroid nodules. *Medical Oncology* **33**:7. . [Crossref]

2681. Michael T. Stang, Syed Ammer Shah, Julie A. Sosa. 2016. Management of the Central and Lateral Neck in Patients with Differentiated Thyroid Cancer. *Current Surgery Reports* **4**:7. . [Crossref]

2682. Diogo Sousa, Miguel Allen, Ana Cruz, Diogo Marinho, Andreia Ferreira, Daniel Costa Santos, André Mateus, Pierpaolo Cusati, Vítor Rocha, José Augusto Martins. 2016. Avaliação da implementação de uma consulta de cirurgia endócrina no litoral alentejano. *Revista Portuguesa de Endocrinologia, Diabetes e Metabolismo* **11**:2, 258-261. [Crossref]

2683. Lester DR Thompson. 2016. Ninety-four cases of encapsulated follicular variant of papillary thyroid carcinoma: A name change to Noninvasive Follicular Thyroid Neoplasm with Papillary-like Nuclear Features would help prevent overtreatment. *Modern Pathology* **29**:7, 698-707. [Crossref]

2684. Soo Yeon Hahn, Jung Hee Shin, Young Lyun Oh, Young-Ik Son. 2016. Discrepancies between the ultrasonographic and gross pathological size of papillary thyroid carcinomas. *Ultrasonography* **35**:3, 220-225. [Crossref]

2685. KRZYSZTOF KALISZEWSKI, BEATA WOJTCZAK, MARTA STRUTYŃSKA-KARPIŃSKA, TADEUSZ ŁUKIEŃCZUK, ZDZISŁAW FORKASIEWICZ, PAWEŁ DOMOSŁAWSKI. 2016. Incidental and non-incidental thyroid microcarcinoma. *Oncology Letters* **12**:1, 734-740. [Crossref]

2686. Shen-Ling Zhu, Yu-Xin Jiang, Xiao Yang, Qiong Wu, Rui-Na Zhao, Jian-Chu Li, Ru-Yu Liu, Bo Zhang. 2016. "Onion Skin-liked Sign" in Thyroid Ultrasonography. *Chinese Medical Journal* **129**:13, 1533-1537. [Crossref]

2687. Roger Kulstad. 2016. DO ALL THYROID NODULES >4 CM NEED TO BE REMOVED? AN EVALUATION OF THYROID FINE-NEEDLE ASPIRATION BIOPSY IN LARGE THYROID NODULES. *Endocrine Practice* **22**:7, 791-798. [Crossref]

2688. So Yoon Park, Soo Yeon Hahn, Jung Hee Shin, Eun Young Ko, Young Lyun Oh. 2016. The Diagnostic Performance of Thyroid US in Each Category of the Bethesda System for Reporting Thyroid Cytopathology. *PLOS ONE* **11**:6, e0155898. [Crossref]

2689. Hershman Jerome M.. 2016. Noninvasive Encapsulated Follicular Variant of Papillary Thyroid Cancer May Not Be a Cancer. *Clinical Thyroidology* **28**:6, 163-166. [Citation] [Full Text] [PDF] [PDF Plus]

2690. Parangi Sareh. 2016. Reclassification of Noninvasive Follicular Variant of Papillary Thyroid Carcinoma As a Benign Condition Will Reduce the Incidence of Malignancy in the Indeterminate FNA Categories. *Clinical Thyroidology* **28**:6, 167-170. [Citation] [Full Text] [PDF] [PDF Plus]

2691. Kluijfhout Wouter P., Pasternak Jesse D., Lim James, Kwon Julie S., Vriens Menno R., Clark Orlo H., Shen Wen T., Gosnell Jessica E., Suh Insoo, Duh Quan-Yang. 2016. Frequency of High-Risk Characteristics Requiring Total Thyroidectomy for 1–4 cm Well-Differentiated Thyroid Cancer. *Thyroid* **26**:6, 820-824. [Abstract] [Full Text] [PDF] [PDF Plus]

2692. Kloos Richard T., Monroe Robert J., Traweek S. Thomas, Lanman Richard B., Kennedy Giulia C.. 2016. A Genomic Alternative to Identify Medullary Thyroid Cancer Preoperatively in Thyroid Nodules with Indeterminate Cytology. *Thyroid* **26**:6, 785-793. [Abstract] [Full Text] [PDF] [PDF Plus] [Supplementary Material]

2693. Kim Brian W., Yousman Wina, Wong Wei Xiang, Cheng Cheng, McAninch Elizabeth A.. 2016. Less is More: Comparing the 2015 and 2009 American Thyroid Association Guidelines for Thyroid Nodules and Cancer. *Thyroid* **26**:6, 759-764. [Abstract] [Full Text] [PDF] [PDF Plus] [Supplementary Material]

2694. Nockel Pavel, Millo Corina, Keutgen Xavier, Klubo-Gwiezdzinska Joanna, Shell Jasmine, Patel Dhaval, Nilubol Naris, Herscovitch Peter, Sadowski Samira M., Kebebew Electron. 2016. The Rate and Clinical Significance of Incidental Thyroid Uptake as Detected

Downloaded by Memorial Sloan Kettering from www.liebertpub.com at 08/14/19. For personal use only.

by Gallium-68 DOTATATE Positron Emission Tomography/Computed Tomography. *Thyroid* **26**:6, 831-835. [Abstract] [Full Text] [PDF] [PDF Plus]

2695. Frederik A. Verburg, Cumali Aktolun, Arturo Chiti, Savvas Frangos, Luca Giovanella, Martha Hoffmann, Ioannis Iakovou, Jasna Mihailovic, Bernd J. Krause, Werner Langsteger, Markus Luster. 2016. Why the European Association of Nuclear Medicine has declined to endorse the 2015 American Thyroid Association management guidelines for adult patients with thyroid nodules and differentiated thyroid cancer. *European Journal of Nuclear Medicine and Molecular Imaging* **43**:6, 1001-1005. [Crossref]

2696. Laurent Dercle, Désirée Deandreis, Marie Terroir, Sophie Leboulleux, Jean Lumbroso, Martin Schlumberger. 2016. Evaluation of 124I PET/CT and 124I PET/MRI in the management of patients with differentiated thyroid cancer. *European Journal of Nuclear Medicine and Molecular Imaging* **43**:6, 1006-1010. [Crossref]

2697. Laszlo Hegedüs. 2016. Down-sizing the overzealous search for low-risk thyroid malignancy. *Endocrine* **52**:3, 408-410. [Crossref]

2698. Semen Onder, Sule Ozturk Sari, Gulcin Yegen, Ismail Cem Sormaz, Ismail Yilmaz, Sukran Poyrazoglu, Yasemin Sanlı, Yasemin Giles Senyurek, Yersu Kapran, Ozgur Mete. 2016. Classic Architecture with Multicentricity and Local Recurrence, and Absence of TERT Promoter Mutations are Correlates of BRAF V600E Harboring Pediatric Papillary Thyroid Carcinomas. *Endocrine Pathology* **27**:2, 153-161. [Crossref]

2699. Josef Machac. 2016. Thyroid Cancer in Pediatrics. *Endocrinology and Metabolism Clinics of North America* **45**:2, 359-404. [Crossref]

2700. Colleen M. Kiernan, Cameron Schlegel, Sandra Kavalukas, Chelsea Isom, Mary F. Peters, Carmen C. Solórzano. 2016. Does concomitant thyroidectomy increase risks of parathyroidectomy?. *Journal of Surgical Research* **203**:1, 34-39. [Crossref]

2701. E. Anda, J. Pineda, M. Toni, J.C. Galofré. 2016. Enfermedad nodular tiroidea. *Medicine - Programa de Formación Médica Continuada Acreditado* **12**:13, 713-721. [Crossref]

2702. E. Anda, A. Ernaga. 2016. Protocolo de manejo clínico del nódulo tiroideo. *Medicine - Programa de Formación Médica Continuada Acreditado* **12**:13, 754-757. [Crossref]

2703. G. Gutiérrez Buey, J.C. Galofré. 2016. Protocolo del manejo de la disfunción tiroidea en el paciente anciano. *Medicine - Programa de Formación Médica Continuada Acreditado* **12**:13, 763-767. [Crossref]

2704. Teng Zhao, Jun Liang, Zhenqing Guo, Tianjun Li, Yansong Lin. 2016. In Patients With Low- to Intermediate-Risk Thyroid Cancer, a Preablative Thyrotropin Level of 30 μIU/mL Is Not Adequate to Achieve Better Response to 131I Therapy. *Clinical Nuclear Medicine* **41**:6, 454-458. [Crossref]

2705. O. Wise, M. R. Howard. 2016. Thyroid cytology: a review of current international reporting systems and emerging developments. *Cytopathology* **27**:3, 161-167. [Crossref]

2706. Sunil Dutt Sharma, Gaurav Kumar, Karen Guner, Hesham Kaddour. 2016. Hyperthyroidism in Patients with Thyroid Cancer. *Ear, Nose & Throat Journal* **95**:6, 236-239. [Crossref]

2707. Leonard Wartofsky. 2016. A rose by any name surely does smell just as sweetly: The controversy over revised nomenclature for encapsulated follicular variant papillary carcinoma. *Journal of Translational Internal Medicine* **4**:2, 55-57. [Crossref]

2708. Douglas Van Nostrand. 2016. Festina Lente and the "Crab and the butterfly". *Journal of Translational Internal Medicine* **4**:2, 58-60. [Crossref]

2709. Karen T. Le, Mark P. Sawicki, Marilene B. Wang, Jerome M. Hershman, Angela M. Leung. 2016. HIGH PREVALENCE OF AGENT ORANGE EXPOSURE AMONG THYROID CANCER PATIENTS IN THE NATIONAL VA HEALTHCARE SYSTEM. *Endocrine Practice* **22**:6, 699-702. [Crossref]

2710. Selcuk Yaylaci, Onder Tosun, Orhan Sahin, Ahmet Bilal Genc, Ercan Aydin, Gokhan Demiral, Fatma Karahalil, Serdar Olt, Hasan Ergenc, Ceyhun Varim. 2016. Lack of Variation in Inflammatory Hematological Parameters between Benign Nodular Goiter and Papillary Thyroid Cancer. *Asian Pacific Journal of Cancer Prevention* **17**:4, 2321-2323. [Crossref]

2711. Mohamed Abdelgadir Adam, Michael T. Stang, Julie Ann Sosa, Sanziana A. Roman. 2016. Is lymph node involvement associated with mortality risk in younger patients with papillary thyroid cancer?. *Expert Review of Endocrinology & Metabolism* **11**:3, 233-234. [Crossref]

2712. Bekir Kuru, Aysegul Atmaca, Mehmet Kefeli. 2016. Malignancy rate associated with Bethesda category III (AUS/FLUS) with and without repeat fine needle aspiration biopsy. *Diagnostic Cytopathology* **44**:5, 394-398. [Crossref]

2713. Brian Hung-Hin Lang, Tony W.H. Shek, Koon Yat Wan. 2016. Does microscopically involved margin increase disease recurrence after curative surgery in papillary thyroid carcinoma?. *Journal of Surgical Oncology* **113**:6, 635-639. [Crossref]

2714. Lutske Lodewijk, Wouter P. Kluijfhout, Jakob W. Kist, Inge Stegeman, John T. M. Plukker, Els J. Nieveen van Dijkum, H. Jaap Bonjer, Nicole D. Bouvy, Abbey Schepers, Johannes H. W. de Wilt, Romana T. Netea-Maier, Jos A. van der Hage, Jacobus W. A. Burger, Gavin Ho, Wayne S. Lee, Wen T. Shen, Anna Aronova, Rasa Zarnegar, Cassandre Benay, Elliot J. Mitmaker, Mark S. Sywak, Ahmad M. Aniss, Schelto Kruijff, Benjamin James, Raymon H. Grogan, Laurent Brunaud, Guillaume Hoch, Chiara

Downloaded by Memorial Sloan Kettering from www.liebertpub.com at 08/14/19. For personal use only.

Pandolfi, Daniel T. Ruan, Michael D. Jones, Marlon A. Guerrero, Gerlof D. Valk, Inne H. M. Borel Rinkes, Menno R. Vriens. 2016. Characteristics of contralateral carcinomas in patients with differentiated thyroid cancer larger than 1 cm. *Langenbeck's Archives of Surgery* **401**:3, 365-373. [Crossref]

2715. Jin Young Kwak. 2016. Thyroid ultrasonography for personalized approach at thyroid nodules. *Endocrine* **52**:2, 181-182. [Crossref]

2716. Lester D.R. Thompson. 2016. Update on follicular variant of papillary thyroid carcinoma with an emphasis on new terminology: noninvasive follicular thyroid neoplasm with papillary-like nuclear features. *Diagnostic Histopathology* **22**:5, 171-178. [Crossref]

2717. M.A. Muros de Fuentes, M. Mitjavila Casanovas, M. Estorch Cabrera, B. Lecumberri Santamaria, E. Navarro González. 2016. Utilidad de la 18F-FDG PET/TC en el cáncer de tiroides. *Revista Española de Medicina Nuclear e Imagen Molecular* **35**:3, 186-192. [Crossref]

2718. M.A. Muros de Fuentes, M. Mitjavila Casanovas, M. Estorch Cabrera, B. Lecumberri Santamaria, E. Navarro González. 2016. Usefulness of 18 F-FDG PET/CT in thyroid carcinoma. *Revista Española de Medicina Nuclear e Imagen Molecular (English Edition)* **35**:3, 186-192. [Crossref]

2719. A L Mitchell, A Gandhi, D Scott-Coombes, P Perros. 2016. Management of thyroid cancer: United Kingdom National Multidisciplinary Guidelines. *The Journal of Laryngology & Otology* **130**:S2, S150-S160. [Crossref]

2720. Alexis Lacout, Carole Chevenet, Pierre Yves Marcy. 2016. Recurrence in Patients with Classic Papillary Thyroid Carcinoma: Highlight on Power Doppler US. *Radiology* **279**:2, 653-654. [Crossref]

2721. Motoyuki Igata, Kaku Tsuruzoe, Junji Kawashima, Daisuke Kukidome, Tatsuya Kondo, Hiroyuki Motoshima, Seiya Shimoda, Noboru Furukawa, Takeshi Nishikawa, Nobuhiro Miyamura, Eiichi Araki. 2016. Coexistence of resistance to thyroid hormone and papillary thyroid carcinoma. *Endocrinology, Diabetes & Metabolism Case Reports* . [Crossref]

2722. Pablo Valderrabano, Marino E Leon, Barbara A Centeno, Kristen J Otto, Laila Khazai, Judith C McCaffrey, Jeffery S Russell, Bryan McIver. 2016. Institutional prevalence of malignancy of indeterminate thyroid cytology is necessary but insufficient to accurately interpret molecular marker tests. *European Journal of Endocrinology* **174**:5, 621-629. [Crossref]

2723. Cynthia J Herrick, Jeffrey F Moley. 2016. New systemic therapies for locally advanced and metastatic thyroid cancer. *International Journal of Endocrine Oncology* **3**:2, 143-159. [Crossref]

2724. Anita K Ying, Thomas W Feeley, Michael E Porter. 2016. Value-based healthcare: implications for thyroid cancer. *International Journal of Endocrine Oncology* **3**:2, 115-129. [Crossref]

2725. M Sara Rosenthal, Peter Angelos, Keith Bible, Cheryl Ann Fassler, Stuart Finder, Loren Wissner Greene, Mark Tulchinsky. 2016. Informed consent for low-risk thyroid cancer. *International Journal of Endocrine Oncology* **3**:2, 131-142. [Crossref]

2726. Lutske Lodewijk, Menno R. Vriens, Wessel M.C.M. Vorselaars, Nick T.M. van der Meij, MANP, Jakob W. Kist, Maarten W. Barentsz, Helena M. Verkooijen, Inne H.M. Borel Rinkes, Gerlof D. Valk. 2016. SAME-DAY FINE-NEEDLE ASPIRATION CYTOLOGY DIAGNOSIS FOR THYROID NODULES ACHIEVES RAPID ANXIETY DECREASE AND HIGH DIAGNOSTIC ACCURACY. *Endocrine Practice* **22**:5, 561-566. [Crossref]

2727. Grace C. Haser, R. Michael Tuttle, Henry K. Su, Eran E. Alon, Donald Bergman, Victor Bernet, Elise Brett, Rhoda Cobin, Eliza H. Dewey, Gerard Doherty, Laura L. Dos Reis, Jeffrey Harris, Joshua Klopper, Stephanie L. Lee, Robert A. Levine, Stephen J. Lepore, Ilya Likhterov, Mark A. Lupo, Josef Machac, Jeffrey I. Mechanick, Saral Mehra, Mira Milas, Lisa A. Orloff, Gregory Randolph, Tracey A. Revenson, Katherine J. Roberts, Douglas S. Ross, Meghan E. Rowe, Robert C. Smallridge, David Terris, Ralph P. Tufano, Mark L. Urken. 2016. ACTIVE SURVEILLANCE FOR PAPILLARY THYROID MICROCARCINOMA: NEW CHALLENGES AND OPPORTUNITIES FOR THE HEALTH CARE SYSTEM. *Endocrine Practice* **22**:5, 602-611. [Crossref]

2728. Nosheen Fatima, Maseeh uz Zaman, Areeba Zaman, Unaiza Zaman, Rabia Tahseen. 2016. Comparable Ablation Efficiency of 30 and 100 mCi of I-131 for Low to Intermediate Risk Thyroid Cancers Using Triple Negative Criteria. *Asian Pacific Journal of Cancer Prevention* **17**:3, 1115-1118. [Crossref]

2729. Spaulding Stephen W.. 2016. Does Metformin Protect the Bone Marrow of Patients with Diabetes Treated with 131I for Thyroid Cancer?. *Clinical Thyroidology* **28**:4, 121-123. [Citation] [Full Text] [PDF] [PDF Plus]

2730. Hershman Jerome M.. 2016. Is BRAF(V600E) Mutation Predictive of Recurrence in Papillary Thyroid Microcarcinoma?. *Clinical Thyroidology* **28**:4, 124-125. [Citation] [Full Text] [PDF] [PDF Plus]

2731. Sabra Mona M., Ghossein Ronald, Tuttle R. Michael. 2016. Time Course and Predictors of Structural Disease Progression in Pulmonary Metastases Arising from Follicular Cell–Derived Thyroid Cancer. *Thyroid* **26**:4, 518-524. [Abstract] [Full Text] [PDF] [PDF Plus]

2732. Na Dong Gyu, Baek Jung Hwan, Sung Jin Yong, Kim Ji-Hoon, Kim Jae Kyun, Choi Young Jun, Seo Hyobin. 2016. Thyroid Imaging Reporting and Data System Risk Stratification of Thyroid Nodules: Categorization Based on Solidity and Echogenicity. *Thyroid* **26**:4, 562-572. [Abstract] [Full Text] [PDF] [PDF Plus]

Downloaded by Memorial Sloan Kettering from www.liebertpub.com at 08/14/19. For personal use only.

2733. Urken Mark L., Haser Grace C., Likhterov Ilya, Wenig Bruce M.. 2016. The Impact of Metastatic Lymph Nodes on Risk Stratification in Differentiated Thyroid Cancer: Have We Reached a Higher Level of Understanding?. *Thyroid* **26**:4, 481-488. [Abstract] [Full Text] [PDF] [PDF Plus]

2734. Dennis Wylie, Sylvie Beaudenon-Huibregtse, Brian C. Haynes, Thomas J. Giordano, Emmanuel Labourier. 2016. Molecular classification of thyroid lesions by combined testing for miRNA gene expression and somatic gene alterations. *The Journal of Pathology: Clinical Research* **2**:2, 93-103. [Crossref]

2735. Brian H.-H. Lang, Tony W.H. Shek, Koon Yat Wan. 2016. Impact of microscopic extra-nodal extension (ENE) on locoregional recurrence following curative surgery for papillary thyroid carcinoma. *Journal of Surgical Oncology* **113**:5, 526-531. [Crossref]

2736. Behzad Salari, Yin Ren, Dipti Kamani, Gregory W. Randolph. 2016. Revision neural monitored surgery for recurrent thyroid cancer: Safety and thyroglobulin response. *The Laryngoscope* **126**:4, 1020-1025. [Crossref]

2737. Corinna Wicke, Arnold Trupka. 2016. Aktuelle Aspekte der chirurgischen Therapie. *HNO Nachrichten* **46**:2, 27-32. [Crossref]

2738. M. Sollini, C. Rossetti, A. Chiti. 2016. Comments on the Italian Society of Endocrinology recommendations on post-surgical thyroid ablation in differentiated thyroid cancer. *Journal of Endocrinological Investigation* **39**:4, 485-486. [Crossref]

2739. Santiago Zund, Karina Patané, Inés Califano, Matías Calabretta, Ezequiel Lupo. 2016. Carcinoma papilar de tiroides localmente invasivo en tráquea. Tratamiento oncológico y posterior traqueoplastia alejada por dehiscencia de anastomosis traqueal. *Revista Argentina de Endocrinología y Metabolismo* **53**:2, 73-76. [Crossref]

2740. Athanasios Bikas, Mark Schneider, Sameer Desale, Frank Atkins, Mihriye Mete, Kenneth D. Burman, Leonard Wartofsky, Douglas Van Nostrand. 2016. Effects of Dosimetrically Guided I-131 Therapy on Hematopoiesis in Patients With Differentiated Thyroid Cancer. *The Journal of Clinical Endocrinology & Metabolism* **101**:4, 1762-1769. [Crossref]

2741. Arivarasan Karunamurthy, Federica Panebianco, Susan J Hsiao, Jennie Vorhauer, Marina N Nikiforova, Simion Chiosea, Yuri E Nikiforov. 2016. Prevalence and phenotypic correlations of EIF1AX mutations in thyroid nodules. *Endocrine-Related Cancer* **23**:4, 295-301. [Crossref]

2742. Laura Y Wang, Ian Ganly. 2016. Nodal metastases in thyroid cancer: prognostic implications and management. *Future Oncology* **12**:7, 981-994. [Crossref]

2743. 2016. Thyroid Nodules. *New England Journal of Medicine* **374**:13, 1294-1295. [Crossref]

2744. Aleksandr N. Bubnov, Roman A. Chernikov, Il'ja V. Slepcov, Arsenij A. Semenov, Chinchuk I. Konstantinovich, Viktor A. Makar'in, Anna A. Uspenskaja, Natal'ja I. Timofeeva, Konstantin J. Novokshonov, Julija V. Karelina, Elisej A. Fedorov, Jurij N. Maljugov, Jurij N. Fedotov. 2016. Comments to the project of Russian clinical practice guidelines for diagnosis and treatment of differentiated thyroid cancer. *Endocrine Surgery* **10**:1, 23. [Crossref]

2745. Spaulding Stephen W.. 2016. Is the Absence of Suspicious Features on Ultrasound Sufficiently Reliable That No Biopsy Is Needed for an 18FFDG-Positive Thyroid Nodule Found Incidentally on PET–CT?. *Clinical Thyroidology* **28**:3, 65-67. [Citation] [Full Text] [PDF] [PDF Plus]

2746. Hershman Jerome M.. 2016. Falling Levels of Thyroglobulin Antibody After Treatment for DTC Predict No Structural Recurrence. *Clinical Thyroidology* **28**:3, 79-81. [Citation] [Full Text] [PDF] [PDF Plus]

2747. De Napoli Luigi, Bakkar Sohail, Ambrosini Carlo Enrico, Materazzi Gabriele, Proietti Agnese, Macerola Elisabetta, Basolo Fulvio, Miccoli Paolo. 2016. Indeterminate Single Thyroid Nodule: Synergistic Impact of Mutational Markers and Sonographic Features in Triaging Patients to Appropriate Surgery. *Thyroid* **26**:3, 390-394. [Abstract] [Full Text] [PDF] [PDF Plus]

2748. Heaton Chase M., Chang Jolie L., Orloff Lisa A.. 2016. Prognostic Implications of Lymph Node Yield in Central and Lateral Neck Dissections for Well-Differentiated Papillary Thyroid Carcinoma. *Thyroid* **26**:3, 434-440. [Abstract] [Full Text] [PDF] [PDF Plus]

2749. Suh Chong Hyun, Baek Jung Hwan, Lee Jeong Hyun, Choi Young Jun, Kim Jae Kyun, Sung Tae-Yon, Yoon Jong Ho, Shong Young Kee. 2016. The Role of Core-Needle Biopsy as a First-Line Diagnostic Tool for Initially Detected Thyroid Nodules. *Thyroid* **26**:3, 395-403. [Abstract] [Full Text] [PDF] [PDF Plus] [Supplementary Material]

2750. Elizabeth N. Pearce, Stephanie L. Lee, Richard Weiss, James Magner, Jeffrey R. Garber, F.X. Campion, Angela M. Leung. 2016. Unique obstacles to establishing thyroid cancer registries. *Journal of Clinical & Translational Endocrinology* **3**, 12-13. [Crossref]

2751. Keith C. Bible, Mabel Ryder. 2016. Evolving molecularly targeted therapies for advanced-stage thyroid cancers. *Nature Reviews Clinical Oncology* **13**:7, 403-416. [Crossref]

2752. Alev Selek, Berrin Cetinarslan, Emine Kıvrakoğlu, Duygu Temiz Karadağ, Ilhan Tarkun, Zeynep Canturk, Ozlem Zeynep Akyay. 2016. Histologic outcome of thyroid nodules with repeated diagnosis of atypia in thyroid fine-needle aspiration biopsy. *Future Oncology* **12**:6, 801-805. [Crossref]

Downloaded by Memorial Sloan Kettering from www.liebertpub.com at 08/14/19. For personal use only.

2753. Lee Lawrence, Mitmaker Elliot J., Chabot John A., Lee James A., Kuo Jennifer H.. 2016. Cost-Effectiveness of Diagnostic Lobectomy Versus Observation for Thyroid Nodules >4 cm. *Thyroid* **26**:2, 271-279. [Abstract] [Full Text] [PDF] [PDF Plus]

2754. Chen Yufei, Sadow Peter M., Suh Hyunsuk, Lee Kyu Eun, Choi June Young, Suh Yong Joon, Wang Tracy S., Lubitz Carrie C.. 2016. BRAFV600E Is Correlated with Recurrence of Papillary Thyroid Microcarcinoma: A Systematic Review, Multi-Institutional Primary Data Analysis, and Meta-Analysis. *Thyroid* **26**:2, 248-255. [Abstract] [Full Text] [PDF] [PDF Plus]

2755. Pitoia Fabián, Miyauchi Akira. 2016. 2015 American Thyroid Association Guidelines for Thyroid Nodules and Differentiated Thyroid Cancer and Their Implementation in Various Care Settings. *Thyroid* **26**:2, 319-321. [Citation] [Full Text] [PDF] [PDF Plus]

2756. Rosalia do Prado Padovani. 2016. Radioiodine for thyroid cancer: sometimes, less is best. *Archives of Endocrinology and Metabolism* **60**:1, 2-4. [Crossref]

2757. Brito Juan P., Ito Yasuhiro, Miyauchi Akira, Tuttle R. Michael. 2016. A Clinical Framework to Facilitate Risk Stratification When Considering an Active Surveillance Alternative to Immediate Biopsy and Surgery in Papillary Microcarcinoma. *Thyroid* **26**:1, 144-149. [Abstract] [Full Text] [PDF] [PDF Plus]

2758. Gerard M. Doherty. Thyroid Nodules and Cancer Risk: Surgical Management 331-333. [Crossref]

2759. Jason A. Wexler. Bone Metastases from Differentiated Thyroid Carcinoma 723-733. [Crossref]

2760. Leonard Wartofsky. Follicular Thyroid Carcinoma 769-778. [Crossref]

2761. Merica Shrestha, Henry B. Burch. Follow-Up Strategy in Follicular Thyroid Cancer 793-796. [Crossref]

2762. Steven G. Waguespack, Andrew J. Bauer. Follicular Thyroid Cancer: Special Aspects in Children and Adolescents 801-805. [Crossref]

2763. Douglas W. Ball, Leonard Wartofsky. Clinical Aspects of Medullary Thyroid Carcinoma 853-863. [Crossref]

2764. Giuseppe Esposito. Radionuclide Imaging of Medullary Carcinoma 873-880. [Crossref]

2765. Rossella Elisei, Laura Agate, Sara Mazzarri, Valeria Bottici, Federica Guidoccio, Eleonora Molinaro, Giuseppe Boni, Marco Ferdeghini, Giuliano Mariani. Diagnostic Applications of Nuclear Medicine: Thyroid Tumors 1-40. [Crossref]

2766. Federica Orsini, Sara Mazzarri, Erinda Puta, Federica Guidoccio, Alice Lorenzoni, Giuliano Mariani. Radiopharmaceuticals for Therapy 1-16. [Crossref]

2767. Rossella Elisei, Laura Agate, Sara Mazzarri, Valeria Bottici, Federica Guidoccio, Eleonora Molinaro, Giuseppe Boni, Marco Ferdeghini, Giuliano Mariani. Radionuclide Therapy of Thyroid Tumors 1-47. [Crossref]

2768. Catherine F. Sinclair, William S. Duke, Anca M. Barbu, Gregory W. Randolph. Laryngeal Exam Indications and Techniques 17-29. [Crossref]

2769. Furio Pacini, Maria Grazia Castagna, Martin Schlumberger. Differentiated Thyroid Carcinoma of Follicular Origin 1-26. [Crossref]

2770. E. Papini, R. Guglielmi, G. Bizzarri, A. Frasoldati. Non-isotopic Thyroid Imaging 1-36. [Crossref]

2771. Michael P. Wissmeyer. Integrated Imaging of Thyroid Disease 281-288. [Crossref]

2772. Javier López-Gómez, Ma. Alejandra Salazar-Álvarez, Martin Granados-Garcia. 2016. Papillary carcinoma of hyoid. *International Journal of Surgery Case Reports* **28**, 241-245. [Crossref]

2773. Ian D. Hay, Tammi R. Johnson, Geoffrey B. Thompson, Thomas J. Sebo, Megan S. Reinalda. 2016. Minimal extrathyroid extension in papillary thyroid carcinoma does not result in increased rates of either cause-specific mortality or postoperative tumor recurrence. *Surgery* **159**:1, 11-21. [Crossref]

2774. Alex Stagnaro-Green, Joanne Rovet. 2016. Maternal thyroid function in pregnancy — a tale of two tails. *Nature Reviews Endocrinology* **12**:1, 10-11. [Crossref]

2775. Dong Gyu Na, Young Hen Lee. 2016. Ultrasonography Diagnosis of Thyroid Nodules and Cervical Metastatic Lymph Nodes. *International Journal of Thyroidology* **9**:1, 1. [Crossref]

2776. Sung Hye Kong, Seo Young Lee, Ye Seul Yang, Jae Hoon Moon. 2016. Papillary Thyroid Carcinoma Presented as a Hot Nodule with Hyperthyroidism. *International Journal of Thyroidology* **9**:1, 47. [Crossref]

2777. Choon-Young Kim, Seung Hyun Son, Ji-hoon Jung, Chang-Hee Lee, Ju Hye Jeong, Shin Young Jeong, Sang-Woo Lee, Byeong-Cheol Ahn, Jaetae Lee. 2016. Pathological N1b Node Metastasis Itself Can Be Still a Valid Prognostic Factor in PTC after High Dose RAI Therapy. *International Journal of Thyroidology* **9**:2, 159. [Crossref]

2778. Hye-Seon Oh, Eyun Song, Dong Eun Song, Won Bae Kim. 2016. Incidental Detection of Struma Ovarii on the Whole Body Scan in a Differentiated Thyroid Cancer Patient. *International Journal of Thyroidology* **9**:2, 180. [Crossref]

Downloaded by Memorial Sloan Kettering from www.liebertpub.com at 08/14/19. For personal use only.

2779. Ka Hee Yi, Eun Kyung Lee, Ho-Cheol Kang, Yunwoo Koh, Sun Wook Kim, In Joo Kim, Dong Gyu Na, Kee-Hyun Nam, So Yeon Park, Jin Woo Park, Sang Kyun Bae, Seung-Kuk Baek, Jung Hwan Baek, Byung-Joo Lee, Ki-Wook Chung, Yuh-Seog Jung, Gi Jeong Cheon, Won Bae Kim, Jae Hoon Chung, Young-Soo Rho. 2016. 2016 Revised Korean Thyroid Association Management Guidelines for Patients with Thyroid Nodules and Thyroid Cancer. *International Journal of Thyroidology* **9**:2, 59. [Crossref]

2780. Byeong-Cheol Ahn. 2016. Personalized Medicine Based on Theranostic Radioiodine Molecular Imaging for Differentiated Thyroid Cancer. *BioMed Research International* **2016**, 1-9. [Crossref]

2781. Márcia Faria, Liliana Capinha, Joana Simões-Pereira, Maria João Bugalho, Ana Luísa Silva. 2016. Extending the Impact of RAC1b Overexpression to Follicular Thyroid Carcinomas. *International Journal of Endocrinology* **2016**, 1-6. [Crossref]

2782. Pablo Florenzano, Francisco J. Guarda, Rodrigo Jaimovich, Nicolás Droppelmann, Hernán González, José M. Domínguez. 2016. Radioactive Iodine Administration Is Associated with Persistent Related Symptoms in Patients with Differentiated Thyroid Cancer. *International Journal of Endocrinology* **2016**, 1-6. [Crossref]

2783. I. Rachinsky, M. Rajaraman, W. D. Leslie, A. Zahedi, C. Jefford, A. McGibbon, J. E. M. Young, K. A. Pathak, M. Badreddine, S. De Brabandere, H. Fong, S. Van Uum. 2016. Regional Variation across Canadian Centers in Radioiodine Administration for Thyroid Remnant Ablation in Well-Differentiated Thyroid Cancer Diagnosed in 2000–2010. *Journal of Thyroid Research* **2016**, 1-9. [Crossref]

2784. Tae Kwun Ha, Dong Wook Kim, Ha Kyoung Park, Jin Wook Baek, Yoo Jin Lee, Young Mi Park, Do Hun Kim, Soo Jin Jung, Ki Jung Ahn. 2016. The Effect of Levothyroxine Discontinuation Timing on Postoperative Hypothyroidism after Hemithyroidectomy for Papillary Thyroid Microcarcinoma. *International Journal of Endocrinology* **2016**, 1-6. [Crossref]

2785. Mandana Moosavi, Stuart Kreisman. 2016. A Case Report of Dramatically Increased Thyroglobulin after Lymph Node Biopsy in Thyroid Carcinoma after Total Thyroidectomy and Radioiodine. *Case Reports in Endocrinology* **2016**, 1-4. [Crossref]

2786. Robert M. Wolfson, Irina Rachinsky, Deric Morrison, Al Driedger, Tamara Spaic, Stan H. M. Van Uum. 2016. Recombinant Human Thyroid Stimulating Hormone versus Thyroid Hormone Withdrawal for Radioactive Iodine Treatment of Differentiated Thyroid Cancer with Nodal Metastatic Disease. *Journal of Oncology* **2016**, 1-6. [Crossref]

2787. Andri Christou, Evridiki Papastavrou, Anastasios Merkouris, Savvas Frangos, Panayiota Tamana, Andreas Charalambous. 2016. Clinical Studies of Nonpharmacological Methods to Minimize Salivary Gland Damage after Radioiodine Therapy of Differentiated Thyroid Carcinoma: Systematic Review. *Evidence-Based Complementary and Alternative Medicine* **2016**, 1-11. [Crossref]

2788. Ashwini Aithal Padur, Naveen Kumar, Anitha Guru, Satheesha Nayak Badagabettu, Swamy Ravindra Shanthakumar, Murlimanju Bukkambudhi Virupakshamurthy, Jyothsna Patil. 2016. Safety and Effectiveness of Total Thyroidectomy and Its Comparison with Subtotal Thyroidectomy and Other Thyroid Surgeries: A Systematic Review. *Journal of Thyroid Research* **2016**, 1-6. [Crossref]

2789. Rodrigo Moreno-Reyes, Aglaia Kyrilli, Maria Lytrivi, Carole Bourmorck, Rayan Chami, Bernard Corvilain. 2016. Is there still a role for thyroid scintigraphy in the workup of a thyroid nodule in the era of fine needle aspiration cytology and molecular testing?. *F1000Research* **5**, 763. [Crossref]

2790. Yasuhiro Ito, Hitomi Oda, Akira Miyauchi. 2016. Insights and clinical questions about the active surveillance of low-risk papillary thyroid microcarcinomas [Review]. *Endocrine Journal* **63**:4, 323-328. [Crossref]

2791. Pierpaolo Trimboli, Marco Centanni, Camilla Virili. 2016. Liquid liothyronine to obtain target TSH in differentiated thyroid cancer patients. *Endocrine Journal* **63**:6, 563-567. [Crossref]

2792. Yasuhiro Ito, Shinichi Suzuki, Ken-ichi Ito, Tsuneo Imai, Takahiro Okamoto, Hiroya Kitano, Iwao Sugitani, Kiminori Sugino, Hidemitsu Tsutsui, Hisato Hara, Akira Yoshida, Kazuo Shimizu. 2016. Tyrosine-kinase inhibitors to treat radioiodine-refracted, metastatic, or recurred and progressive differentiated thyroid carcinoma [Review]. *Endocrine Journal* **63**:7, 597-602. [Crossref]

2793. Kyoung Sik Park. 2016. TSH Suppression after Differentiated Thyroid Cancer Surgery and Osteoporosis. *Korean Journal of Endocrine Surgery* **16**:1, 1. [Crossref]

2794. Woo Ree Koh, Byung Joo Chae, Ja Seong Bae, Byung Joo Song, Yong Hwa Eom, Sohee Lee. 2016. Transaxillary Endoscopic Thyroidectomy versus Conventional Open Thyroidectomy for Papillary Thyroid Cancer: 5-year Surgical Outcomes. *Korean Journal of Endocrine Surgery* **16**:2, 42. [Crossref]

2795. Byeong-Ho Ghong, Dong-Ju Kim, Ok-Jun Lee, Jin-Woo Park. 2016. Supplementary Role of Ultrasonography and Intraoperative Frozen Section Analysis in Diagnosis of Follicular Variant of Papillary Thyroid Carcinomas. *Korean Journal of Endocrine Surgery* **16**:3, 57. [Crossref]

2796. Young Hun Kim, Yoo Seok Kim, Kweon Cheon Kim. 2016. Factors Influencing Central Neck Lymph Node Metastasis in Patients with Papillary Thyroid Microcarcinoma. *Korean Journal of Endocrine Surgery* **16**:3, 64. [Crossref]

2797. Byeong-Ho Ghong, Jin-Woo Park, Seunguk Bang, Dongju Kim. 2016. Can We Omit Prophylactic Central Lymph Node Dissection in Patients with Clinically LN Negative Papillary Thyroid Microcarcinoma?. *Korean Journal of Endocrine Surgery* **16**:3, 79. [Crossref]

Downloaded by Memorial Sloan Kettering from www.liebertpub.com at 08/14/19. For personal use only.

2798. Kaoru KOBAYASHI. 2016. Thyroid tumors and ultrasonic diagnosis; incidentally detected by imaging studies such as ultrasonography, CT, MR, and PET. *Choonpa Igaku* **43**:3, 427-434. [Crossref]

2799. Yoon Young Cho, Sejong Chun, Soo-Youn Lee, Jae Hoon Chung, Hyung-Doo Park, Sun Wook Kim. 2016. Performance Evaluation of the Serum Thyroglobulin Assays With Immunochemiluminometric Assay and Immunoradiometric Assay for Differentiated Thyroid Cancer. *Annals of Laboratory Medicine* **36**:5, 413. [Crossref]

2800. Lan Yun, Tae hyun Lee, Dong hee Park. 2016. Added Value of Thyroglobulin Measurement in the Fine-Needle Aspiration Washout to Diagnose Cervical Metastatic Lymphadenopathy from Papillary Thyroid Cancer. *Journal of the Korean Society of Radiology* **75**:5, 363. [Crossref]

2801. Jung Hee Shin, Jung Hwan Baek, Jin Chung, Eun Joo Ha, Ji-hoon Kim, Young Hen Lee, Hyun Kyung Lim, Won-Jin Moon, Dong Gyu Na, Jeong Seon Park, Yoon Jung Choi, Soo Yeon Hahn, Se Jeong Jeon, So Lyung Jung, Dong Wook Kim, Eun-Kyung Kim, Jin Young Kwak, Chang Yoon Lee, Hui Joong Lee, Jeong Hyun Lee, Joon Hyung Lee, Kwang Hui Lee, Sun-Won Park, Jin Young Sung. 2016. Ultrasonography Diagnosis and Imaging-Based Management of Thyroid Nodules: Revised Korean Society of Thyroid Radiology Consensus Statement and Recommendations. *Korean Journal of Radiology* **17**:3, 370. [Crossref]

2802. Eun Ju Ha, Won-Jin Moon, Dong Gyu Na, Young Hen Lee, Nami Choi, Soo Jin Kim, Jae Kyun Kim. 2016. A Multicenter Prospective Validation Study for the Korean Thyroid Imaging Reporting and Data System in Patients with Thyroid Nodules. *Korean Journal of Radiology* **17**:5, 811. [Crossref]

2803. Eun-Kyung Kim. 2016. RE: Papillary Thyroid Carcinoma Treated with Radiofrequency Ablation in a Patient with Hypertrophic Cardiomyopathy: A Case Report. *Korean Journal of Radiology* **17**:6, 965. [Crossref]

2804. Sanam Lathief, Avin Pothuloori, Xiaoying Liu, Sushela Chaidarun. 2016. Advances and practical use of the molecular markers for thyroid cancer. *Advances in Cellular and Molecular Otolaryngology* **4**:1, 33948. [Crossref]

2805. H. Ilhan, M. Mustafa, P. Bartenstein, T. Kuwert, D. Schmidt. 2016. Rate of elimination of radioiodine-avid lymph node metastases of differentiated thyroid carcinoma by postsurgical radioiodine ablation. *Nuklearmedizin* **55**:6. . [Crossref]

2806. Ka Hee Yi. 2016. The Revised 2016 Korean Thyroid Association Guidelines for Thyroid Nodules and Cancers: Differences from the 2015 American Thyroid Association Guidelines. *Endocrinology and Metabolism* **31**:3, 373. [Crossref]

2807. Mijin Kim, Min Ji Jeon, Won Gu Kim, Jong Jin Lee, Jin-Sook Ryu, Eun-Jung Cho, Dae-Hyun Ko, Woochang Lee, Sail Chun, Won-Ki Min, Tae Yong Kim, Young Kee Shong, Won Bae Kim. 2016. Comparison of Thyroglobulin Measurements Using Three Different Immunoassay Kits: A BRAMHS Tg-Plus RIA Kit, a BRAMHS hTg Sensitive Kryptor Kit, and a Beckman Coulter ACCESS Immunoassay Kit. *Endocrinology and Metabolism* **31**:3, 462. [Crossref]

2808. Yoko OMI, Kento HANIU, Momoko SAKURAI, Erin NAGAI, Hiroki TOKUMITSU, Yusaku YOSHIDA, Akiko SAKAMOTO, Kiyomi HORIUCHI, Takahiro OKAMOTO, Kenji FUKUSHIMA, Koichiro ABE. 2016. Radioiodine Ablation as a Post-operative Adjuvant Therapy for Thyroid Cancer. *Nihon Rinsho Geka Gakkai Zasshi (Journal of Japan Surgical Association)* **77**:12, 2875-2880. [Crossref]

2809. 2016. *Nippon Jibiinkoka Gakkai Kaiho* **119**:12, 1496-1503. [Crossref]

2810. 2016. *Nippon Jibiinkoka Gakkai Kaiho* **119**:5, 689-695. [Crossref]

2811. Ru-Qiang Li, Ge-Heng Yuan, Ming Chen, Yi-Min Shao, Sai-Nan Zhu, Jun-Qing Zhang, Xiao-Hui Guo. 2016. Evaluation of Diagnostic Efficiency of Ultrasound Features on Malignant Thyroid Nodules in Chinese Patients. *Chinese Medical Journal* **129**:15, 1784. [Crossref]

2812. Jin-Woo Park, Jae-Soo Yoo, Jin-Kyung Yun, Byoung-Hoon Kim, Yeon-Woo Noh, Dong-Ju Kim. 2016. An online questionnaire survey on preferred timing for the diagnosis and management of thyroid carcinoma in general population in Korea. *Annals of Surgical Treatment and Research* **90**:6, 297. [Crossref]

2813. Hui Huang, Shao-Yan Liu, Song Ni, Zong-Min Zhang, Xiao-Lei Wang, Zhen-Gang Xu. 2016. Treatment Outcome of Papillary Carcinoma Confined to the Thyroid Isthmus. *Journal of Cancer Therapy* **07**:12, 963-969. [Crossref]

2814. V. A. Makarin, A. A. Uspenskaya, N. I. Timofeeva, I. V. Sleptcov, A. A. Semenov, R. A. Chernikov, I. K. Chinchuk, U. V. Karelina, K. U. Novokshonov, E. A. Fedorov, Y. N. Malugov, V. F. Rusakov, P. S. Kniazeva, V. A. Malkov, T. S. Pridvigkina, E. A. Valdina, Y. N. Fedotov, A. N. Bubnov. 2015. Is it advisable to perform preoperativelaryngoscopy in all patients due to undergo the thyroid and parathyroid surgery?Analysis of 5172 preoperative laryngoscopies. *Endocrine Surgery* **9**:4, 5. [Crossref]

2815. Dong Gyu Na, Ji-hoon Kim, Dea Sik Kim, Soo Jin Kim. 2015. Thyroid nodule with minimally cystic change has a low malignancy risk. *Ultrasonography* . [Crossref]

2816. Maria E. Cabanillas, Ramona Dadu, Mimi I. Hu, Charles Lu, Gary Brandon Gunn, Elizabeth G. Grubbs, Stephen Y. Lai, Michelle D. Williams. 2015. Thyroid Gland Malignancies. *Hematology/Oncology Clinics of North America* **29**:6, 1123-1143. [Crossref]

Downloaded by Memorial Sloan Kettering from www.liebertpub.com at 08/14/19. For personal use only.

2817. Erik K. Alexander, William C. Faquin, Jeffrey F. Krane. 2015. Highlights for the cytology community from the 2015 American Thyroid Association clinical guidelines on the management of thyroid nodules and well-differentiated thyroid cancer. *Cancer Cytopathology* n/a-n/a. [Crossref]

2818. Iain J. Nixon. 2015. The Surgical Approach to Differentiated Thyroid Cancer. *F1000Research* **4**, 1366. [Crossref]

Downloaded by Memorial Sloan Kettering from www.liebertpub.com at 08/14/19. For personal use only.